

# Penile fracture: Institutional experience of 14 cases

Rajendra K. Shimpi, Pranay J. Patel, Suraj T. Bhondave

Department of Urology, Ruby Hall Clinic, Pune, Maharashtra, India

## Abstract

**Background:** Penile fracture due to various causes is urological emergency condition, which can be diagnosed on history and clinical examination of the patient. Appropriate management in each case prevents patients from future physical and psychological consequences.

**Materials and Methods:** Fourteen patients were included in the study. The study was carried out at Ruby Hall Clinic, Pune, India, between January 1, 2016, and December 31, 2019. All patients were evaluated by history and clinical examination and radiographic investigation in suspected urethral injury.

**Results:** Fourteen patients with penile fracture, between 20 and 50 years, were in the study. The most common mechanism of injury was abnormal positional coital activity. About 85.71% of patients were diagnosed with a history and clinical examination. Ninety-three percent of patients were treated surgically and had a successful outcome. One patient had associated urethral injury. All patients had good sexual function posttreatment except one who later recovered well on medical management.

**Conclusion:** Early diagnosis and treatment of patients with penile fracture depend on the history and clinical examination with less role of radiological investigations. The appropriate treatment gives a good outcome.

**Keywords:** Penile fracture, retrograde urethrography, tunica albuginea

**Address for correspondence:** Dr. Suraj T. Bhondave, Department of Urology, Ruby Hall Clinic, Pune - 411 001, Maharashtra, India.

E-mail: dr.surajb@gmail.com

**Received:** 16.03.2020, **Accepted:** 02.11.2020, **Published:** 23.06.2021

## INTRODUCTION

Fracture penis is a rare injury due to rupture of the corpora cavernosal tunica albuginea that is commonly seen with tumescence. During abnormal positional sexual intercourse, rolling over the bed, masturbation, or fall onto the erect penis are usual causes which cause abrupt bending of the erect penis by blunt trauma.<sup>[1,2]</sup> Audible “cracking” sound, immediate detumescence, pain, and swelling are the classic triad present in penile fracture, which makes diagnosis easy. History and clinical examination reveal the typical symptoms and signs of penile fracture, which helps in early diagnosis.<sup>[3,4]</sup> However, fear and embarrassment for a patient cause delay in the requirement of medical

treatment, which may result in poor outcomes in terms of his voiding and sexual function.<sup>[5]</sup>

Fracture penis results in “eggplant deformity” of the penis due to hematoma, bruising, and deformity.<sup>[1,2]</sup> Fair number of patients have associated urethral injuries.<sup>[2,6,7]</sup> When there is difficulty in diagnosing such cases, imaging techniques like ultrasonography with Doppler, retrograde urethrography (RGU) help to confirm diagnosis.<sup>[8-10]</sup> Cases of penile fracture if not managed properly may have severe physical and functional complications.<sup>[11]</sup> The current standard protocol for the treatment of fracture penis includes immediate surgical exploration of penis involving degloving of the penis, hematoma evacuation, and suturing

Access this article online	
Quick Response Code:	Website: www.urologyannals.com
	DOI: 10.4103/UA.UA_27_20

This is an open access journal, and articles are distributed under the terms of the Creative Commons Attribution-NonCommercial-ShareAlike 4.0 License, which allows others to remix, tweak, and build upon the work non-commercially, as long as appropriate credit is given and the new creations are licensed under the identical terms.

**For reprints contact:** WKHLRPMedknow\_reprints@wolterskluwer.com

**How to cite this article:** Shimpi RK, Patel PJ, Bhondave ST. Penile fracture: Institutional experience of 14 cases. *Urol Ann* 2021;13:351-5.

**Table 1: Age-wise distribution of patients**

Age group	Number of patients (%)
20-30	6 (42.9)
31-40	7 (50)
41-50	1 (7.1)

**Table 2: Causes of penile fracture**

Activity	Number of patients (%)
Abnormal positional coital activity	8 (57.14)
Masturbation	3 (21.43)
Rolling over erect penis during sleep	3 (21.43)

**Table 3: Sites of tunical tear**

Site of penile fracture	Number of patients (%)
Right corpus	8 (57)
Left corpus	6 (57)
Proximal shaft	8 (57)
Mid shaft	6 (57)
Corporeal fracture with urethral rupture	1 (7.1)

of rent in tunica albuginea with nonabsorbable suture. Associated urethral injury can be managed conservatively or surgically, depending on the situation.<sup>[7,12,13]</sup> Complications of penile fracture include penile curvature related to late treatment of the condition, feeling of nodular swelling, urethral stricture, and urethral cutaneous fistula.<sup>[7,14]</sup>

We present our experience in the management of 14 cases of penile fracture, including their presentation, causes, treatment, and complications.

## MATERIALS AND METHODS

This was prospective study. Between January 1, 2016, and December 31, 2019, 14 patients with blunt trauma to the erect penis were included in the study after prior informed consent. Each patient underwent thorough evaluation, including history taking, examination, RGU (retrograde urethrography) for suspected urethral injury and cavernosography in doubt. A standard operative management technique was adopted for all patients, including careful examination of all the three corpora and urethra through a subcoronal degloving incision, thorough wound toilet, and corporal and tunical repair with interrupted inverted nonabsorbable sutures. Foley's catheterization was done in all patients. It was removed on the 2<sup>nd</sup> postoperative day except in one patient who underwent urethral repair catheter was removed on the 7<sup>th</sup> postoperative day. All patients were followed up after 1, 3, 6, and 12 months for postoperative complications like wound-related complications, penile curvature, nodule, as well as for voiding and sexual function status.

## RESULTS

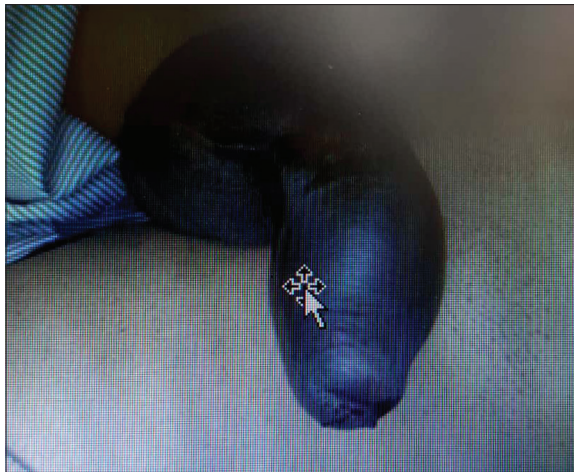
The study included 14 patients who were prospectively evaluated over a period of 3 years. Age distribution of patients, Youngest patient in the present series was 23 years old and oldest was 46 years of age. The maximum number of patients was in the age group of 31–40 years. The mean age was 33 years [Table 1].

### Etiology of fracture penis

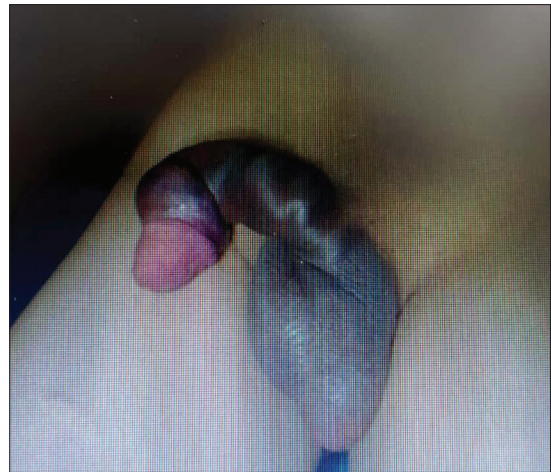
Out of 14 patients 2 were unmarried and 12 were married. The etiology of fracture was coital activity in 8 (57.14%) cases, masturbation in 3 (21.43%) cases and rolling over erect penis during sleep in 3 (21.43%) cases [Table 2]. The time between occurrence of fracture and presentation varied between 2 h and 48 h (an average of 8 h) [Figure 1]. Thirteen (92.9%) patients had a typical history of popping sound followed by pain, rapid detumescence, and development of swelling and discoloration. One (7.1%) patient had bleeding per-urethra, deviation of the penis to the opposite side of the fracture and palpable swelling. Urethral bleeding and blood at meatus were recorded in 2 (14.29%) cases [Figures 2 and 3].

Twelve (85.71%) patients underwent surgical exploration depending on the basis of clinical diagnosis. One patient was conservatively managed with Foley's catheter and perineal tight dressing. Co-existing corpora-spongiosal and the urethral injury was reported in one case with the help of RGU, which was also conservatively managed. All patients managed surgically were explored through circumcoronal degloving incision [Figure 4]. Tunical tear was found in the right corpus in 8 (57%) patients and the left corpus in 6 (43%) patients [Figures 5 and 6]. The site of tear was proximal in 8 (57%) patients and midshaft in 6 (57%) patients. One patient had both corporeal fracture with urethral rupture [Table 3].

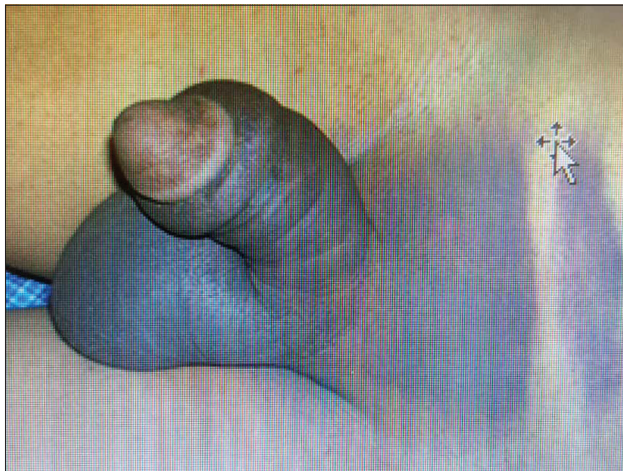
Tunical defect was repaired in a single layer, interrupted, inverted with nonabsorbable suture ethylon 4-0. Intraoperative complications were not reported. All patients were catheterized with 14 Fr foley's catheter. One patient who had tunical tear with urethral transection, the urethra repaired with vicryl 4-0 interrupted suture over a 14 Fr Foley's catheter [Figure 7]. All patients had catheter removed on the 2<sup>nd</sup> postoperative day except the one who underwent urethral repair in whom catheter was removed on the 7<sup>th</sup> postoperative day [Figure 8]. Only one patient had immediate wound infection, which healed by secondary intention. All patients were discharged on the post-operative day 3 except one who had wound infection he was discharged on the postoperative day 5. All patients



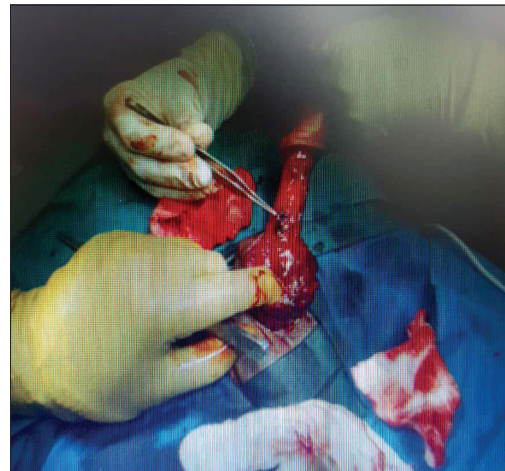
**Figure 1:** Case of fracture penis



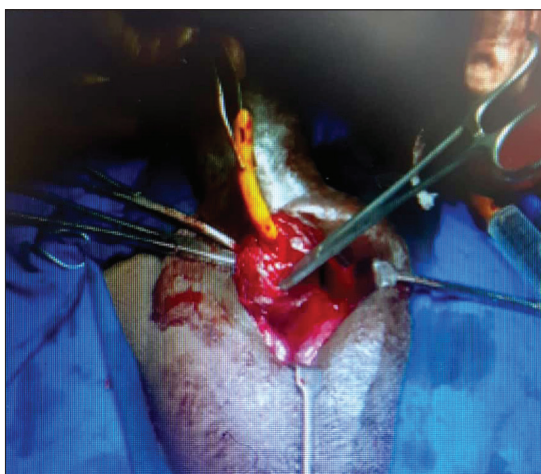**Figure 2:** Case of fracture penis



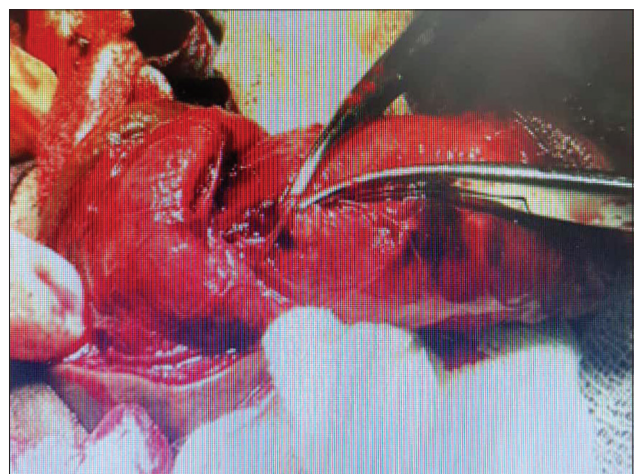**Figure 3:** Case of fracture penis showing haematoma



**Figure 4:** Intraoperative finding of cavernosal defect



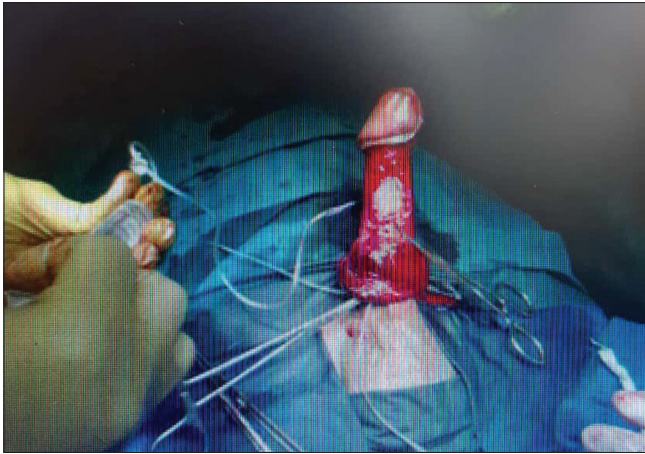
**Figure 5:** Intraoperative findings of penile fracture



**Figure 6:** Intraoperative findings of fracture penis

were followed up after 4 weeks. Clinically 1 (7.1%) patient was found to have small nodule, while 4 (29%) patients had minimal penile deviation. Sexual function was evaluated

with the IIEF-5 questionnaire. 13 (93%) patients were satisfied with their sexual life with erection sufficient for intercourse. One patient who was conservatively managed



**Figure 7:** Saline test

had erectile dysfunction (ED), was given medical treatment in the form of tadalafil and he recovered well.

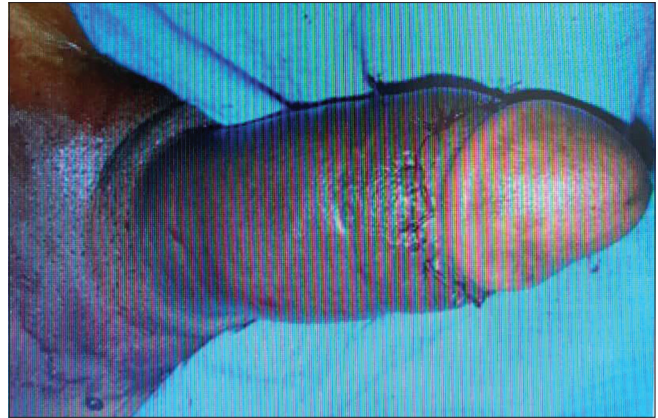## DISCUSSION

The first patient of penile fracture was described by Malis and Zur in 1924 in the modern medical literature.<sup>[15]</sup> Arab physician Abu-al-Qasim al-Zahrawi documented the first report of penile fracture >1000 years of age in Cordoba.<sup>[16]</sup> The usual mechanism of penile fracture is related to specific sexual activities that an individual engages in, masturbation, and socio-cultural customs.

In a study by Kumar *et al.*, 45% of patients were in the age group of 30–40 years of age.<sup>[16]</sup> In a study by Mahapatra *et al.*, 40% of patients of penile fracture were in the age group of 21–30 years of age.<sup>[14]</sup> In our study also, 50% of patients were in the age group of 31–40 years of age.

Coital activity is found to be the most common cause of the penile fracture. In a study by Kumar *et al.* 90% of the patients cause of penile fracture was coital trauma.<sup>[16]</sup> In Mahapatra *et al.* 50% of patients had penile fracture due to vaginal intercourse, 25% due to masturbation and 25% due to rolling over erect penis during sleep.<sup>[14]</sup> In our study, 57% of patients had penile fracture due to coital activity, while rest of the patients, it was due to masturbation and rolling over the erect penis during sleep.

Many a times, only patients' history and physical examination are all that is required to make a correct diagnosis of penile fracture. In a study by Mahapatra *et al.*, 95% of cases were diagnosed through proper history and physical examination.<sup>[14]</sup> In a study by Kumar *et al.*, 85% of patients had undergone immediate surgical exploration depending on history and examination findings.<sup>[16]</sup> In



**Figure 8:** Postoperative picture

our study, 92.9% of patients were clinically diagnosed of penile fracture, depending on history and clinical examination.

The time of presentation of patients with penile fracture plays an important role in postmanagement morbidity. In Kumar *et al.* mean time of presentation was 28.9 h (range 2 h to 7 days).<sup>[16]</sup> In Mahapatra *et al.* time interval from injury to the presentation was 6 h to 156 h (37.6 h).<sup>[14]</sup> In our study, the time occurrence of fracture and presentation to hospital was between 2 h and 48 h (average 8 h).

In Kumar *et al.* penile fracture associated with urethral injury was found in 15% of patients.<sup>[16]</sup> In Mahapatra *et al.* 10% of patients had associated urethral injury with penile fracture.<sup>[14]</sup> In our study, 7% of patients had urethral injury associated with penile fracture detected by retrograde urethrogram (RGU).

Penile fracture most commonly occurs on venterolateral aspect of the proximal part of the penis and on the right side. In Kumar *et al.* most of the tear involved the proximal part of the penis. About 5% of patients have associated urethral transection along with tunical tear.<sup>[16]</sup> In Mahapatra *et al.*, 60% of patients had tear in the proximal third of the penis.<sup>[14]</sup> In our study, 57% of patients had tear in the proximal part of the penis and on the right side.

Felter and Gartmen in 1936 first described the surgical repair of penile fracture. In surgically treated patients, studies showed that the complication rate was reduced from 30% to 4%. Surgical and conservative treatments were compared by Muentener *et al.* and found a success rate of 92% and 59%, respectively.<sup>[11]</sup> Yapanoglu *et al.*<sup>[17]</sup> and Gamal *et al.*<sup>[18]</sup> also found that immediate surgical repair resulted in good outcomes and was superior to conservative management. In Kumar *et al.*, 90% of patients were explored immediately who had good outcomes.<sup>[16]</sup>

In Mahapatra *et al.*, 95% of patients underwent surgical management and recovered well.<sup>[14]</sup> In our study, 93% of patients underwent immediate surgical exploration and had successful outcome.

Postoperative outcomes have been different in various case series. In Mahapatra *et al.*, 10% of patients had mild skin infections and 10% of patients had distal skin necrosis. 10% of patients had nontender palpable nodule, which disappeared later on.<sup>[14]</sup> In Kumar *et al.*, 11% of patients had short-term postoperative complications.<sup>[16]</sup> In this study, 7% of patients had small nodule, which regressed later, while 29% of patients had minimal penile deviation. About 7% of patients had ED, which had improved on medical treatment.

Surgical treatment should be offered in most of the patients with penile fracture, as early intervention gives good outcomes in such patients. Inappropriately selected patients, conservative management should be reserved.

## CONCLUSION

To conclude, early diagnosis and treatment of patients of the penile fracture depends on the history and clinical examination with less role of radiological investigations. Appropriate treatment gives a good outcome. Still, it deserves a large-scale study and longer follow-up to determine the consequences of penile fracture.

## Financial support and sponsorship

Nil.

## Conflicts of interest

There are no conflicts of interest.

## REFERENCES

- Zargooshi J. Penile fracture in Kermanshah, Iran: Report of 172 cases. *J Urol* 2000;164:364-6.
- Morey AF, Dugi DD 3<sup>rd</sup>. Genital and lower urinary tract trauma. In: Wein AJ, Kavoussi LR, Partin AW, Nowick AC, editors. *Campbell-Walsh Urology*. 10<sup>th</sup> ed. Philadelphia: Elsevier-Saunders, Co.; 2012. p. 2507, 2520.
- Ozen HA, Erkan I, Alkibay T, Kendi S, Remzi D. Fracture of the penis and long-term results of surgical treatment. *Br J Urol* 1986;58:551-2.
- Fedel M, Venz S, Andressen R, Sudhoff F, Loening SA. The value of magnetic resonance imaging in the diagnosis of suspected penile fracture with atypical clinical findings. *J Urol* 1996;155:1924-7.
- Kamdar C, Mooppan UM, Kim H, Gulmi FA. Penile fracture: Preoperative evaluation and surgical technique for optimal patient outcome. *BJU Int* 2008;102:1640-4.
- Walton JK. Fracture of the penis with laceration of the urethra. *Br J Urol* 1979;51:308-9.
- Eke N. Fracture of the penis. *Br J Surg* 2002;89:555-65.
- Derouiche A, Belhaj K, Hentati H, Hafsia G, Slama MR, Chebil M, *et al.* Management of penile fractures complicated by urethral rupture. *Int J Impot Res* 2008;20:111-4.
- Koga S, Saito Y, Arakaki Y, Nakamura N, Matsuoka M, Saita H, *et al.* Sonography in fracture of the penis. *Br J Urol* 1993;72:228-9.
- Miller S, McAninch JW. Penile fracture and soft tissue injury. In: McAninch JW, editor. *Traumatic and Reconstructive Urology*. Philadelphia: W. B. Saunders; 1996. p. 693-8.
- Muentener M, Suter S, Hauri D, Sulser T. Long-term experience with surgical and conservative treatment of penile fracture. *J Urol* 2004;172:576-9.
- Jack GS, Garraway I, Reznichuk R, Rajfer J. Current treatment options for penile fractures. *Rev Urol* 2004;6:114-20.
- Agarwal MM, Singh SK, Sharma DK, Ranjan P, Kumar S, Chandramohan V, *et al.* Fracture of the penis: A radiological or clinical diagnosis? A case series and literature review. *Can J Urol* 2009;16:4568-75.
- Mahapatra RK, Ray RP, Mishra S, Pal DK. Urethrocutaneous fistula following fracture penis. *Urol Ann* 2014;6:392-4.
- Malis J, Zur K. Der fractura penis. *Arch Klin Chir* 1924;129:651.
- Kumar L, Tiwari R, Arya MC, Sandhu A, Vasudeo V, Baid M. A tertiary center experience of fracture penis: Early surgical management with a clinical diagnosis. *Urol Sci* 2018;29:298-302.
- Yapanoglu T, Aksoy T, Adanur S, Kabadayi B, Ozturk G, Ozbey I. Seventeen years experience of penile fracture: Conservative vs. surgical treatment. *J Sex Med* 2009;6:2058-63.
- Gamal WM, Osman MM, Hammady A, Aldahshoury MZ, Hussein MM, Saleem M, *et al.* Penile fracture: Long-term results of surgical and conservative management. *J Trauma* 2011;71:491-3.