



Clinical Case Studies

Septic cavernous sinus thrombosis secondary to halo vest pin site infection [☆]Abolfazl Rahimizadeh^{*}, Walter Williamson, Shaghayegh Rahimizadeh, Naser Asgari

Pars Advanced and Minimally Invasive Medical Manners Research Center, Pars Hospital, Iran University of Medical Sciences, Tehran, Iran

ARTICLE INFO

Keywords:

Anticoagulants
Cavernous sinus thrombosis
Halo vest orthosis
Upper cervical spine

ABSTRACT

Background: Pin site infection is one of the frequent complications of the halo crown application which can be easily handled if addressed early. However, if this issue is neglected then serious infectious events may quickly transpire. Among all of the medical literature that the previously described scenarios have illuminated; we did not encounter a case involving infectious cavernous sinus thrombosis.

Case description: The authors present a middle age man who arrived at our clinic with an acute left peri-orbital swelling, proptosis, and ophthalmoplegia which had occurred subsequent to an untreated halo pine site infection. With a diagnosis of septic cavernous sinus thrombosis (CST), appropriate antibiotics and anticoagulant therapies were administered.

Outcome: With the continuation of this conservative treatment regimen, he was successfully managed with no residual neurological consequences.

Conclusion: Halo vest orthosis is an appropriately tolerated upper cervical spinal stabilizing device that is a commonly used worldwide. Septic CST that is secondary to a halo vest pin site infection has not been previously described within medical literature. In the case of a neglected pin site infection, with demonstration of ipsilateral eyelid edema and proptosis, septic CST should be immediately considered and treated vigorously with antibiotics and anticoagulant therapies.

1. Introduction

Septic cavernous sinus thrombosis (CST) was initially described by Debase in 1778 and was later reported by Duncan in 1821 as a rare and late complication of facial infections [1–4]. Septic CST is generally a fulminant process with high rates of mortality and lifelong morbidity [1,2,4–8].

One of the most common complications of halo vest orthosis is a pin site infection [9–11]. Herein, we describe a case of septic CST that is secondary to a halo pin site infection which eventually had a favorable outcome.

2. Case report

A 48-year old man was admitted to our facility with an acute swelling and protrusion of the left eye. He had previously developed a hangman fracture for which halo crown vest orthosis was undertaken 5 weeks earlier. A week prior to admission he noticed an enlarging infection

around the left frontal pin site which was neglected for one week. On admission, the examination revealed left eye-ball protrusion in association with engorgement of the veins of the corresponding sclera. The left eye protrusion was associated with impaired eye movements and a dilated pupil (Fig. 1). As the first attempt, a culture from the infected pin site was obtained, then the Halo vest was removed and replaced by a Philadelphia collar. Brain MR venography (MRV) showed an engorged and enlarged superior ophthalmic vein (Fig. 2).

With respect to the result of the culture which showed Staphylococcus Aureus; initially intravenous Vancomycin 1 g twice daily was started with the simultaneous administration of low molecular weight heparin. Both therapies were continued for a duration of 3 weeks. Following this time period, low molecular weight heparin and Vancomycin were switched to Rivaroxaban 10 mg daily and Rifampicin 300 mg twice a day respectively. These medications were continued for an additional 6 weeks. A new brain MRI was conducted 6 weeks after the onset of CST and showed heterogeneity within the left petrosal vein compatible with petrosal vein thrombosis within axial T2-weighted images. Surprisingly,

[☆] Consent: Written Consent was obtained from the first two patients to publish the history and their corresponding radiological images. From two brothers written consent was taken to write the summary of their history, age, sex and clinical features, but didn't permit to publish their imaging features.

^{*} Corresponding author.

E-mail address: a_rahimizadeh@hotmail.com (A. Rahimizadeh).

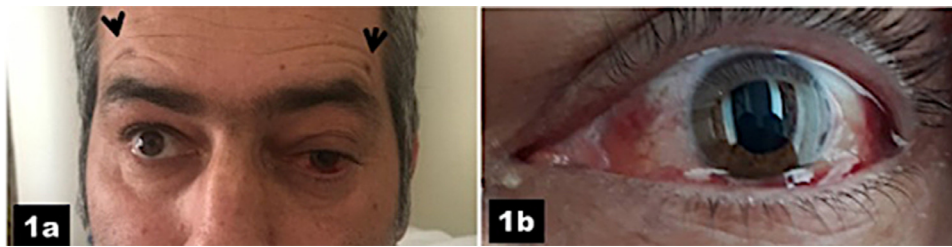


Fig. 1. Digital photograph two weeks after admission (a,b) showing a man with left eye lid edema, proptosis, and a ptosis and external deviation of the left, note the scars of pin sites (black arrow heads). (b) Note dilated pupil which is due to third nerve palsy.

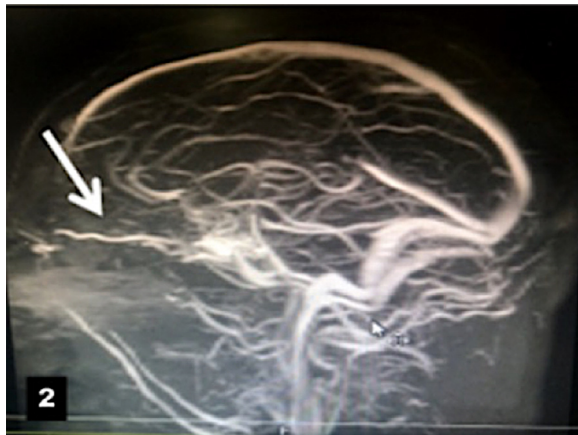

Fig. 2. MR venogram showing enlarged left ophthalmic vein indicating the obstruction of the cavernous sinus.

the enlargement of the ophthalmic vein had disappeared in a subsequent MR venogram (Fig. 3).

Nine weeks after the onset, the protrusion and full range movements of the left eye as well as the pupil size had returned to normal (Fig. 4). Two weeks later, oral antibiotics were discontinued, but Rivaroxaban was advised for an additional 12 weeks in order to allow for the complete recanalization of the petrosal veins. A year after his initial presentation, the patient is doing well, without any neurological deficit.

3. Discussion

Pin site infection is regarded as a frequent complication of halo crown vest orthosis [9-11]. This complication can be reduced by means of proper pin site daily care. A clean cotton tip applicator or gauze with removal of any crusts that may form around the pins should be used for each individual pin site. Cleaning should be started with normal saline and then with Chlorhexidine solution. Finally, the pin site should be wrapped with normal-saline-soaked gauze for 10 to 15 min and wiped dry following the removal of the gauze [9,11]. Training for the care givers should be a necessary addendum in the undertaking of the Halo procedure in order to ensure the best overall outcome for the patient.

With appearance of pus drainage at the pin site, an oral antibiotic should be administered blindly after a culture is taken, but it should be later switched to the most appropriate antibiotic. Simultaneously, the involved pin should be promptly removed, but prior to removal, new pin should be inserted in a new anchoring site [9,11]. If pin site infection is neglected, rare complications such as osteomyelitis of the cranium, the epidural, subdural or brain abscesses may occur [12-18]. Septic CST is a rare pathology that results from the spread of infection from the face, mouth, nose, teeth, paranasal sinuses, and ear via the valve-less veins of the face to the ipsilateral cavernous sinus via the petrosal veins [1,8]. Clinically, septic CST presents with the sudden onset of headache, orbital pain, fever, unilateral periorbital swelling, and possible conjunctival swelling. Within a few days; chemosis, proptosis, ptosis, double vision, dilated pupil may appear [1,2,4-8]. Rarely, the infection may spread to the contralateral cavernous sinus [1,2,4-8,19-23].

In the majority of cases, the pathologic microorganism is Staphylococcus aureus followed by Streptococcus pneumoniae, Gram-negative bacilli, and anaerobes [1,2,4-8,19-26].

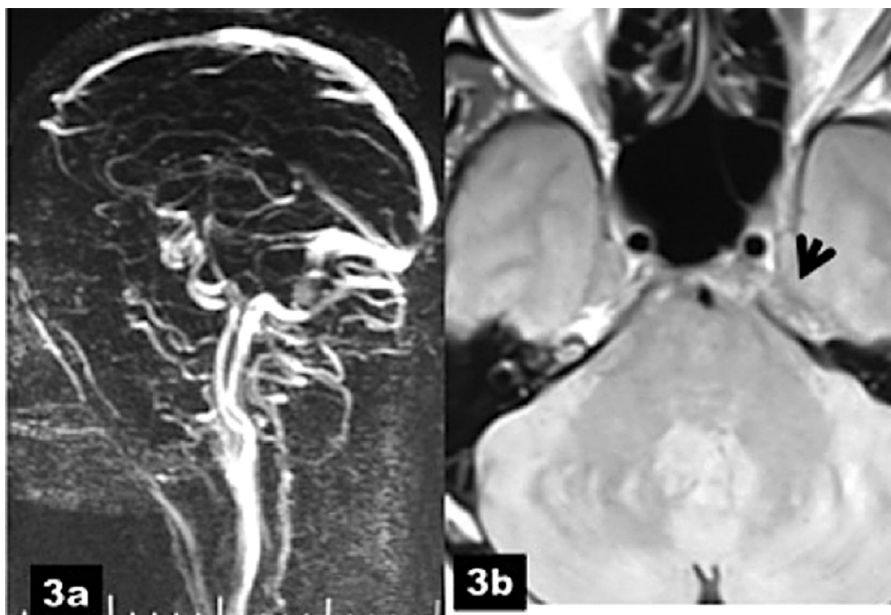


Fig. 3. (a) In brain MR venography, there is no longer any engorgement and enlargement of ophthalmic vein present. (b) MRI of the brain shows the enlargement of left petrosal vein, note heterogeneous features inside this vein indicating a partial resorption of the thrombus and its recanalization (black arrow head).



Fig. 4. Digital photograph 4 months after the onset, (a–d) demonstrates the recovery of proptosis and ptosis. Note that eye movements in all directions are normalized.

Magnetic resonance imaging (MRI) is not always conclusive in septic CST [7,22,23]. However, an enlarged and dilated superior ophthalmic vein, in magnetic resonance venogram (MRV) is an important feature of CST which is indicative of the obstruction of the cavernous sinus [22,23].

With respect to the culture, an appropriate empirical antibiotic should be quickly administered and continued for at least three weeks [1,2,4–8,20]. Simultaneously, for the resolution of the thrombus; anti-coagulant therapy should be initiated [19,21,24,26]. Both of these medications should be switched to oral ones and continued for additional 6 weeks [19,21].

Even with modern treatment, the mortality rate is around 15% [20,25] However, with a delay in diagnosis and from diagnosis to treatment; a mortality rate of 50% can be expected [1,2,4–8,22,25].

Recently, for those resistant to medical treatment, endovascular thrombolysis and recanalization have been proposed [24].

4. Conclusion

Cavernous sinus thrombosis is a potentially fatal scenario that should be added to the sequels of neglected halo pin site infection. Diagnosis of septic CST requires a high degree of clinical suspicion. Painful proptosis after an infection at the territory of the face is septic CST unless proven otherwise. Institution of timely and aggressive treatments is required to prevent permanent neurological disability.

Declaration of Competing Interest

The authors declare that they have no known competing financial interests or personal relationships that could have appeared to influence the work reported in this paper.

Funding

None!

Ethical approval

Approved!

References

- [1] Arian M, Kamali A, Tabatabaiechehr M, et al. Septic cavernous sinus thrombosis: a case report. *Iran Red Crescent Med J* 2016;18(8). doi:10.5812/ircmj.34961.
- [2] Colbert S, Cameron M, Williams J. Septic thrombosis of the cavernous sinus and dental infection. *Br J Oral Maxillofac Surg* 2011;49:e25–ee6.
- [3] Duncan A. Contributions to Morbid Anatomy. No. II. *Edinb Med Surg J* 1821;17:321.
- [4] Ebright JR, Pace MT, Niazi AF. Septic thrombosis of the cavernous sinuses. *Arch Intern Med* 2001;161:2671–6.
- [5] Lizé F, Verillaud B, Vironneau P, et al. Septic cavernous sinus thrombosis secondary to acute bacterial sinusitis: a retrospective study of seven cases. *Am J Rhinol Allergy* 2015;29:e7–e12.
- [6] Pannu AK, Saroch A, Sharma N. Danger triangle of face and septic cavernous sinus thrombosis. *J Emerg Med* 2017;53:137–8.
- [7] Visvanathan V, Uppal S, Prowse S. Reminder of important clinical lesson: ocular manifestations of cavernous sinus thrombosis. *BMJ Case Rep* 2010. doi:10.1136/bcr.08.2009.2225.
- [8] Weerasinghe D, Lueck CJ. Septic cavernous sinus thrombosis: case report and review of the literature. *Neuro-Ophthalmology* 2016;40:263–76.
- [9] Garfin SR, Botte MJ, Waters RL, et al. Complications in the use of the halo fixation device. *J Bone Joint Surg Am* 1986;68:320–5.
- [10] Rahimizadeh A, Mollahousaini R, Soufiani H, Hassani V, Rahimizadeh A. Odontoid synchondrosis fracture in preschool children: Report of two cases with special reference to a new reduction/fixation Technique. *World Spinal Column J (WScJ)* 2016;2016(2):150–8.
- [11] Rahimizadeh A, Williamson W, Ra-himizadeh S, et al. Halo-vesting in pre-school aged children with synchon-drosis fracture: a case series which explores the current techniques asso-ciated with this procedure. *Orthop Res Traumatol Open J* 2017;2:40–9.
- [12] Dennis GC, Clifton GL. Brain abscess as a complication of halo fixation. *Neurosurgery* 1982;10:760–1.
- [13] Goodman ML, Nelson PB. Brain abscess complicating the use of a halo orthosis. *Neurosurgery* 1987;20:27–30.
- [14] Hioki A, Miyamoto K, Inoue T, et al. Successful antibiotic treatment for subdural empyema and seizure due to methicillin-resistant *Staphylococcus aureus* as a complication of halo orthosis usage: a case report. *Eur J Orthop Surg/Traumatol* 2012;22:25–8.
- [15] Kameyama O, Ogawa K, Suga T, et al. Asymptomatic brain abscess as a complication of halo orthosis: report of a case and review of the literature. *J Orthop Sci* 1999;4:39–41.
- [16] Müller E, Wick M, Muhr G. Subdural abscess as a complication of halo fixator. *Der Unfallchirurg* 1998;101:655–7.
- [17] Papagelopoulos PJ, Sapkas GS, Kateros KT, et al. Halo pin intracranial penetration and epidural abscess in a patient with a previous cranioplasty: case report and review of the literature. *Spine* 2001;26:E463–E4E7.
- [18] Saeed MU, Dacucy MAC, Kennedy DJ. Halo pin insertion-associated brain abscess: case report and review of literature. *Spine* 2007;32:E271–E2E4.
- [19] Bhatia K, Jones N. Septic cavernous sinus thrombosis secondary to sinusitis: are anti-coagulants indicated? A review of the literature. *J Laryngol Otol* 2002;116:667–76.
- [20] Desa V, Green R. Cavernous sinus thrombosis: current therapy. *J Oral Maxillofac Surg* 2012;70:2085–91.
- [21] Levine SR, Twyman RE, Gilman S. The role of anticoagulation in cavernous sinus thrombosis. *Neurology* 1988;38:517.

- [22] Press CA, Lindsay A, Stence NV, et al. Cavernous sinus thrombosis in children: imaging characteristics and clinical outcomes. *Stroke* 2015;46:2657–60.
- [23] Tang Y, Booth T, Steward M, et al. The imaging of conditions affecting the cavernous sinus. *Clin Radiol* 2010;65:937–45.
- [24] Bauer J, Kansagra K, Chao KH, et al. Transfemoral thrombectomy in the cavernous sinus and superior ophthalmic vein. *J Neurointerv Surg* 2018;10 e8–ee.
- [25] van der Poel NA, Mourits MP, de Win MM, et al. Prognosis of septic cavernous sinus thrombosis remarkably improved: a case series of 12 patients and literature review. *Eur Arch Otorhinolaryngol* 2018;275:2387–95.
- [26] Zuurbier SM, Coutinho JM, Stam J, et al. Clinical outcome of anticoagulant treatment in head or neck infection-associated cerebral venous thrombosis. *Stroke* 2016;47:1271–7.