

## Madelung disease (multiple symmetric lipomatosis)

Linda Ferreira Maximiano<sup>a</sup>, Márcio Teodoro Gaspar<sup>b</sup>, Evelyn Sue Nakahira<sup>c</sup>

**How to cite:** Maximiano LF, Gaspar MT, Nakahira ES. Madelung disease (multiple symmetric lipomatosis). Autops Case Rep [Internet]. 2018;8(3):e2018030. <https://doi.org/10.4322/acr.2018.030>

### ABSTRACT

Madelung disease or multiple symmetric lipomatosis (MSL) is a rare entity among the overgrowth syndromes. It is characterized by painless non-encapsulated and symmetric fatty deposits in the neck, torso, mammary, and abdominal areas, and in the upper and lower limbs. The etiology of the disease is still unknown. Chronic alcohol consumption may play a role in adipocyte hyperplasia in genetically susceptible individuals. Besides the overgrowth of adipose tissue, patients with MSL present features of metabolic syndrome. Patients seek medical attention usually for esthetic reasons. We present the case of a middle-aged man who sought the outpatient clinic complaining of bulging masses in the posterior upper part of the thorax, the occipital area, and the neck. The masses grew over a period of 2 years. The physical examination and imaging study revealed the presence of symmetric lipomatosis. A two-step surgical treatment was undertaken for the excision of the lipomatous tissue. The postoperative outcome was uneventful with satisfactory esthetic results.

### Keywords

Cell Proliferation; Lipomatosis; Multiple Symmetrical.

### CASE REPORT

A 45-year-old male patient sought medical attention because of a growing mass. The lesion was in the anterior cervical region initially, but over the last 2 years it also appeared in the occipital and dorsal regions. At the time of medical evaluation, the lesions caused him esthetic embarrassment. He also had type 2 diabetes mellitus and asymptomatic chronic pancreatitis. He had a history of alcoholic abuse of 1 liter/day for 10 years. He denied other comorbidities. He had worked as a bricklayer; however, due to the deformation caused by the masses, he was unemployed.

The physical evaluation revealed bulging masses of soft consistency in the anterior cervical region, in the

pre- and post-auricular regions bilaterally, and on the back (Figure 1). The computed tomography imaging study showed a prominent unencapsulated excess of cervical adipose tissue (Figure 2A-C). There was no sign of airway obstruction, hoarseness, cervical, or cervical venous engorgement. The mediastinum was not involved with the lipomatosis (Figure 3D).

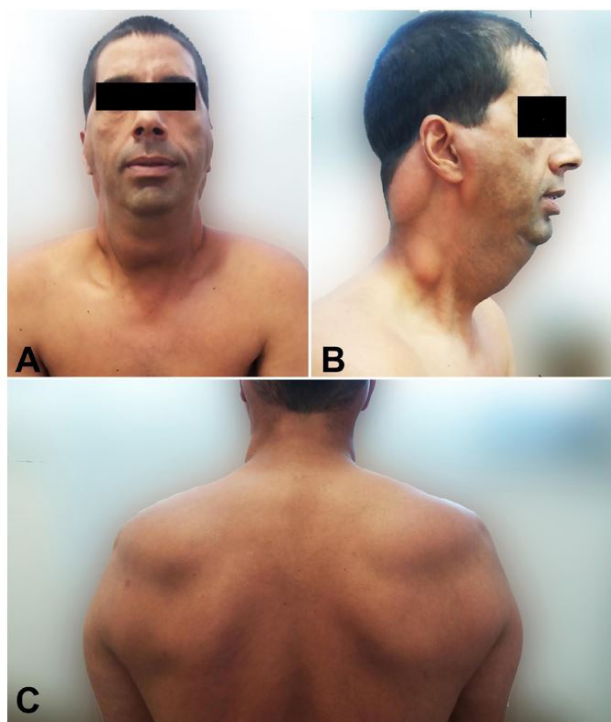A two-step surgical treatment was scheduled. In the first procedure, the anterior cervical mass was resected followed by closed vacuum system drainage. The occipital mass was resected with similar drainage after 1 month in a second surgery. In both surgeries, no dissection plan was identified between the adipose mass and the surrounding structures.

<sup>a</sup> Universidade de São Paulo (USP), Hospital Universitário, Surgical Clinics Division. São Paulo, SP, Brazil.

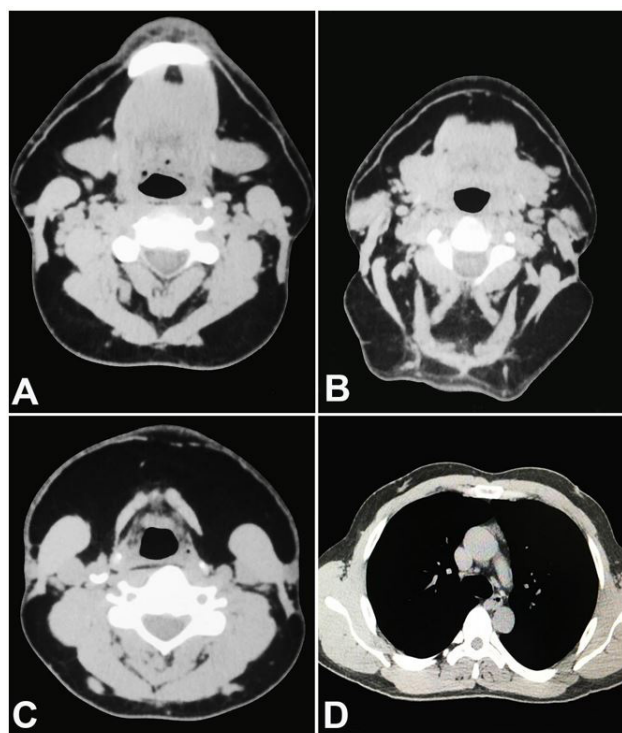
<sup>b</sup> Hospital Múltiplo, Surgery Department. Luanda, Angola.

<sup>c</sup> Universidade de São Paulo (USP), Faculty of Medicine. São Paulo, SP, Brazil.





**Figure 1.** Pre-operative examination. Note the tumors in **A** and **B** – the anterior cervical submandibular regions, and pre- and post-auricular regions; and **C** – in the back.



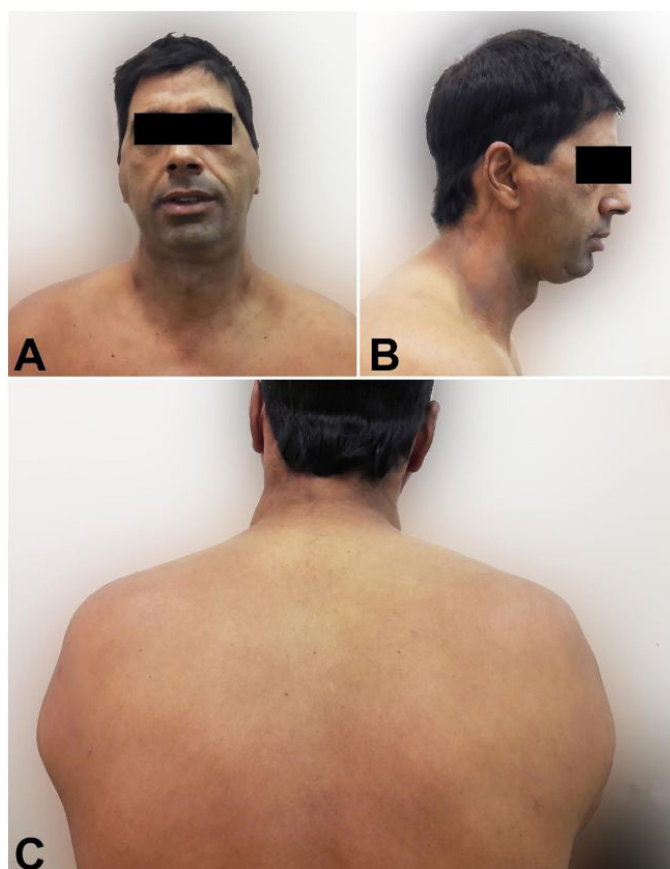**Figure 2.** Pre-operative cervical computed tomography (**A**, **B**, and **C**) showing the bilateral and symmetric increase of the adipose tissue of the submandibular (**A** and **C**) and posterior cervical (**B**) regions, which is consistent with the diagnosis of lipomatosis. Note the lack of lipomatosis in the mediastinum (**D**).

The anatomopathological study of the masses showed a mature adipocyte proliferation, which was compatible with lipomatosis.

Both procedures had a favorable outcome (Figure 3) and after 1 year of follow-up the final esthetic result was satisfactory. After 1 year, the patient was able to look for employment.

## DISCUSSION

MSL—which is called Madelung disease, Launois–Bensaude disease, or benign symmetrical lipomatosis—was first described by Benjamin Brodie in 1846, followed by reports by Madelung, and Launois and Bensaude, in 1898. MSL is a rare disease of fat metabolism. The subcutaneous unencapsulated fatty tissue overgrowth is painless and symmetrically involves mainly the head, neck, and upper torso, and eventually the upper extremities.<sup>1</sup> MSL typically presents between the third and the fifth decade of life and is more prevalent in males,<sup>1,2</sup> with the male to



**Figure 3.** Early post-operative examination showing a favorable esthetic result in both the cervical region (**A** and **B**) and the back (**C**).

female ratio ranging from 15:1 to 30:1. The disease is more common in the Mediterranean or in people with this ancestry than in the general population, and shows an incidence of 1:25,000 in the Italian population.<sup>2</sup>

MSL does not have a completely defined pathophysiology. The adipogenesis is not a result of energy excess, but is an active proliferation of the adipose tissue. The suggested mechanisms comprise a defect of the respiratory chain, and deletions, and mutations of mitochondrial DNA.<sup>3,4</sup> Lipomatous fat deposits may originate from functionally defective brown adipose tissue.<sup>2</sup> The tumor fatty cells have an anomalous metabolic behavior, which is characterized by a defect of the catecholamine's acute lipolytic action, and by the long-acting physiological mechanisms regulating lipid mobilization in adipose tissue.<sup>5-8</sup> Alcoholic abuse is present in more than 90% of the cases.<sup>9</sup> A decrease in the beta-adrenergic receptors and disturbance in the mitochondrial DNA may be an explication of the pathogenic alcohol mechanism.<sup>10</sup>

The history, epidemiology, and clinical features are the basis of MSL diagnosis.<sup>10</sup> However, the diagnosis, in some cases, may be challenging and frequently dismissed due to the high frequency of obesity.<sup>1,4</sup> Patients with MSL often present concomitantly metabolic syndrome features as type 2 diabetes mellitus or glucose intolerance, hypertension, hyperlipidemia, and hyperuricemia. Diseases related to alcohol abuse, such as hepatopathy, macrocytic anemia, and peripheral neuropathy, are also common in MSL patients.<sup>11</sup>

In 1984, Enzi<sup>12</sup> classified MSL into two types according to the site of the fat overgrowth. MSL type I is characterized by symmetric, circumscribed, protruding fat masses. The lesions can be predominantly distributed in the parotid glands (hamster cheeks), cervical region (horse collar), posterior neck (buffalo hump), submental region (Madelung collar), shoulders, supraclavicular triangle, and proximal upper limbs. In MSL type II, the lipomatous tissue is diffusely deposited in the subcutaneous tissue of the abdomen and thighs. The appearance resembles an obesity type of fat distribution.<sup>10,13</sup> A congenital form, in which the lipomatosis deposition occurs around the trunk, was suggested by Carlsen and Thomsen<sup>14</sup> as type III. In 1991, Donhauser et al.<sup>15</sup> added the type III or gynecoid type to Enzi's classification, which became defined as relating to fat deposits mainly located in

the pelvic region.<sup>10,16</sup> Our patient was a middle-aged man—a heavy drinker—with lipomatosis restricted to the anterior and posterior neck, the parotid region, and the upper back torso; therefore, he represented MSL type I.

The malignant transformation of MSL is rare.<sup>17-19</sup> Complications are also rare and result from compression of the cervical structures by the fatty deposits causing dysphagia,<sup>20</sup> odynophagia, and hoarseness. Mediastinal and retroperitoneal lipomatosis can progress causing venous compression.<sup>1,21,22</sup> Imaging exams, such as computed tomography and magnetic resonance imaging, are useful for the evaluation of (i) the extension of the adipose tissue deposition; (ii) the tracheal compression; (iii) the presence of blood vessels within the adipose mass; and (iv) the malignant transformation.<sup>1</sup> The natural history of the disease shows progressive growth of the fat masses, with periods of rapid evolution (generally in the early stages of the disease), and periods of slow progression or a steady phase for a long period; however, no spontaneous regression occurs.<sup>10</sup>

The differential diagnoses of MSL include obesity, Cushing syndrome, angioliomatosis, encapsulated fibromas, neurofibromatosis, myxoid liposarcoma, lymphoma, salivary gland disease, Frölich syndrome, and lipomatosis in patients with HIV.<sup>10,23,24</sup>

Although alcohol withdrawal and weight loss are recommended, these measures are not effective to reverse or to stop the progression of the disease. Currently, surgery is the only treatment available, so the removal of the fat masses remains the only therapy of choice. However, the overall recurrence rate is up to 63%.<sup>10,21</sup>

## CONCLUSION

Despite the high recurrence rate, the surgical approach still needs to be considered. MSL causes not only biological disturbances, but also social loss (e.g. difficulty maintaining or acquiring a job)—the latter of which can be so deleterious that surgery is practically imperative.

The patient signed the informed consent declaration to permit the publication of this case report.

## REFERENCES

1. Tadisina KK, Mlynek KS, Hwang LK, Riazi H, Papay FA, Zins JE. Syndromic lipomatosis of the head and neck: a review of the literature. *Aesthetic Plast Surg*. 2015;39(3):440-8. <http://dx.doi.org/10.1007/s00266-015-0478-8>. PMID:25860506.
2. Enzi G, Busetto L, Sergi G, et al. Multiple symmetric lipomatosis: a rare disease and its possible links to brown adipose tissue. *Nutr Metab Cardiovasc Dis*. 2015;25(4):347-53. <http://dx.doi.org/10.1016/j.numecd.2015.01.010>. PMID:25770761.
3. Plummer C, Spring PJ, Marotta R, et al. Multiple symmetrical lipomatosis—a mitochondrial disorder of brown fat. *Mitochondrion*. 2013;13(4):269-76. <http://dx.doi.org/10.1016/j.mito.2013.03.003>. PMID:23524250.
4. Suresh Chandran CJ, Godge YR, Oak PJ, Ravat SH. Madelung's disease with myopathy. *Ann Indian Acad Neurol*. 2009;12(2):131-2. <http://dx.doi.org/10.4103/0972-2327.53086>. PMID:20142863.
5. Enzi G, Inelmen E, Baritussio A, Dorigo P, Prosdocimi M, Mazzoleni F. Multiple symmetric lipomatosis—a defect in adrenergic-stimulated lipolysis. *J Clin Invest*. 1977;60(6):1221-9. <http://dx.doi.org/10.1172/JCI108881>. PMID:199616.
6. Conroy JP. Airway management: a patient with Madelung disease. *AANA J*. 2006;74(4):281-4. PMID:16918119.
7. Ramos S, Pinheiro S, Diogo C, Cabral L, Cruzeiro C. Madelung disease: a not-so-rare disorder. *Ann Plast Surg*. 2010;64(1):122-4. <http://dx.doi.org/10.1097/SAP.0b013e31819bd729>. PMID:20023459.
8. Palacios E, Neitzschman HR, Nguyen J. Madelung disease: multiple symmetric lipomatosis. *Ear Nose Throat J*. 2014;93(3):94-6. PMID:24652555.
9. Shibusaki Í, Shibusaki HI, Nakamoto TS, Bacchan FS, Raposo LS. Multiple symmetrical lipomatosis (Madelung's disease). *Braz J Otorhinolaryngol*. 2014;80(1):90-1. <http://dx.doi.org/10.5935/1808-8694.20140018>. PMID:24626899.
10. Pinto CI, Carvalho PJ, Correia MM. Madelung's disease: revision of 59 surgical cases. *Aesthetic Plast Surg*. 2017;41(2):359-68. <http://dx.doi.org/10.1007/s00266-016-0759-x>. PMID:28032179.
11. Zuber M, Pittasch D. Benign symmetric lipomatosis (Launois-Bensaude syndrome)—a rare cause of muscular weakness. *Eur J Med Res*. 2006;11(4):174-7. PMID:16720284.
12. Enzi G. Multiple symmetric lipomatosis: an updated clinical report. *Medicine (Baltimore)*. 1984;63(1):56-64. <http://dx.doi.org/10.1097/00005792-198401000-00004>. PMID:6318013.
13. John DG, Fung HK, van Hasselt CA, King WW. Multiple symmetrical lipomatosis in the neck. *Eur Arch Otorhinolaryngol*. 1992;249(5):277-8. <http://dx.doi.org/10.1007/BF00714492>. PMID:1524810.
14. Carlsen A, Thomsen M. Different clinical types of lipomatosis. Case report. *Scand J Plast Reconstr Surg*. 1978;12(1):75-9. <http://dx.doi.org/10.3109/02844317809010484>. PMID:663569.
15. Donhauser G, Vieluf D, Ruzicka T, Braun-Falco O. Benign symmetric Launois-Bensaude type III lipomatosis and Bureau-Barrière syndrome. *Hautarzt*. 1991;42(5):311-4. PMID:1874620.
16. Sharma N, Hunter-Smith DJ, Rizzitelli A, Rozen WM. A surgical view on the treatment of Madelung's disease. *Clin Obes*. 2015;5(5):288-90. <http://dx.doi.org/10.1111/cob.12111>. PMID:26246230.
17. González-García R, Rodríguez-Campo FJ, Sastre-Pérez J, Muñoz-Guerra MF. Benign symmetric lipomatosis (Madelung's disease): case reports and current management. *Aesthetic Plast Surg*. 2004;28(2):108-12, discussion 113. <http://dx.doi.org/10.1007/s00266-004-3123-5>. PMID:15164232.
18. Borriello M, Lucidi A, Carbone A, Iannone V, Ferrandina G. Malignant transformation of Madelung's disease in a patient with a coincidental diagnosis of breast cancer: a case report. *Diagn Pathol*. 2012;7(1):116. <http://dx.doi.org/10.1186/1746-1596-7-116>. PMID:22937763.
19. Tizian C, Berger A, Vykoupil KF. Malignant degeneration in Madelung's disease (benign lipomatosis of the neck): case report. *Br J Plast Surg*. 1983;36(2):187-9. [http://dx.doi.org/10.1016/0007-1226\(83\)90089-9](http://dx.doi.org/10.1016/0007-1226(83)90089-9). PMID:6831098.
20. Nisi G, Sisti A. Images in clinical medicine. Madelung's Disease. *N Engl J Med*. 2016;374(6):572. <http://dx.doi.org/10.1056/NEJMicm1503861>. PMID:26863358.
21. Enzi G, Busetto L, Ceschin E, Coin A, Digito M, Pigozzo S. Multiple symmetric lipomatosis: clinical aspects and outcome in a long-term longitudinal study. *Int J Obes Relat Metab Disord*. 2002;26(2):253-61. <http://dx.doi.org/10.1038/sj.ijo.0801867>. PMID:11850759.
22. Jang JH, Lee A, Han SA, Ryu JK, Song JY. Multiple symmetric lipomatosis (Madelung's disease) presenting as bilateral huge gynecomastia. *J Breast Cancer*. 2014;17(4):397-400. <http://dx.doi.org/10.4048/jbc.2014.17.4.397>. PMID:25548590.
23. Ardeleanu V, Chicos S, Georgescu C, Tutunaru D. Multiple benign symmetric lipomatosis: differential diagnosis of obesity. *Chirurgia*. 2013;108(4):580-3. PMID:23958107.
24. Meningaud JP, Pitak-Arnop P, Bertrand JC. Multiple symmetric lipomatosis: case report and review of the literature. *J Oral Maxillofac Surg*. 2007;65(7):1365-9. <http://dx.doi.org/10.1016/j.joms.2005.10.045>. PMID:17577504.



**Authors contribution:** Maximiano LF was the surgeon in charge of the surgical procedure, supervised and oriented the manuscript conception and is responsible for the patient's longitudinal follow-up. Gaspar MT helped the surgical procedure. Nakahira ES wrote the manuscript and gathered the bibliographic data. All the authors proofread and approved the manuscript for publication.

**Conflict of interest:** None

**Financial support:** None

**Submitted on:** March 9<sup>th</sup>, 2018

**Accepted on:** May 8<sup>th</sup>, 2018

**Correspondence**

Linda Ferreira Maximiano

Surgical Clinics Division - Hospital Universitário - Universidade de São Paulo (USP)

Av. Prof. Lineu Prestes 2565 – Butantã – São Paulo/SP – Brazil

CEP: 05508-000

Phone: +55 (11) 3091-9291

[linda@usp.br](mailto:linda@usp.br)