

Electrocardiographic and echocardiographic findings in children with dengue infection

Santoshi Nerella¹, Uttam K. Sarkar², Hema Namdeo³

¹Department of Pediatric Medicine, SSKMH, Kolkata, West Bengal, ²Department of Pediatric Medicine, North Bengal Medical College, Siliguri, West Bengal, ³Department of Pediatric Medicine, All India Institute of Medical Sciences, Raipur, Chhattisgarh, India

ABSTRACT

Background: The mechanism of myocardial damage in dengue could be the release of inflammatory mediators or the direct action of the dengue virus on myocytes leading to myocarditis. The release of inflammatory mediators is more in a severe form of the disease that correlates to the higher incidence of cardiac manifestations in patients with severe dengue. **Aim:** To determine the electrocardiographic and two-dimensional (2D)-echocardiographic findings in children with dengue infection and to find a correlation with disease severity. **Materials and Methods:** A total of 150 children between 1 month and 12 years of age seropositive for dengue Non-specific antigen 1 (NS1) Enzyme linked immunosorbent assay (ELISA) or dengue Immunoglobulin M (IgM) ELISA were studied in the Department of Pediatric Medicine of a tertiary care government hospital. The patients were undertaken for 12 lead electrocardiograms (ECGs) and echocardiograms. **Results:** Out of the 150 dengue seropositive cases, 61 cases were of mild dengue, 67 cases were of dengue with warning signs (DWSS), and 22 cases were severe dengue cases. Abnormal ECG was found in 78 cases (52%) in a total of 150 cases in terms of rate, prolonged PR interval (interval between atrial depolarization and ventricular activation), ST (ventricular repolarisation)-segment depression, and low-voltage complexes. Abnormal 2D- echocardiography (ECHO) was found in 70 (46.6%) out of 150 in terms of the ejection fraction (EF) <55%, Early diastole/atrial contraction (E/A) ratio <1, and the presence of pericardial effusion. **Conclusion:** Nearly 50% of the patients have abnormal ECG and ECHO findings, more so in the severe dengue group. There is a statistically significant association of the EF between mild dengue, DWSS with severe dengue ($P=0.001$).

Keywords: Dengue, echocardiography, electrocardiography, infection, severe dengue

Introduction

Dengue fever is a very common seasonal acute infection in a developing country like India caused by the dengue virus, a member of the flavivirus genus in the Flaviviridae family; a single-stranded enveloped Ribonucleic acid (RNA) virus.^[1] The dengue infection occurs among all age groups and the pediatric age group was found to have a high risk of morbidity and mortality if not correctly identified and treated at the appropriate time.^[2] The dengue fever typically has an abrupt onset of a high

fever that usually lasts for 2–7 days. Dengue is a disease with a wide clinical spectrum ranging from undifferentiated viral prodrome to more severe forms such as dengue hemorrhagic fever and dengue shock syndrome.^[3]

The exact pathophysiology of cardiac manifestations in dengue is not well established in the literature. The mechanism of myocardial damage in dengue could be the release of inflammatory mediators and/or the direct action of the virus on the myocyte leading to myocarditis.^[4] The dengue virus causes plasma leakage by damaging the endothelial cell lining through the pro-inflammatory cytokine release. Myocardial interstitial edema and myocarditis are the proposed mechanisms of cardiac dysfunction.^[3,4] Most of the mortality in dengue is because of cardiac dysfunction. The clinical manifestations of cardiac

Address for correspondence: Dr. Uttam K. Sarkar, Department of Pediatric Medicine, North Bengal Medical College, Sushantanagar, Thiknikata, Siliguri - 734 012, West Bengal, India. E-mail: uttamks-1964@gmail.com

Received: 28-06-2021

Revised: 08-10-2021

Accepted: 21-10-2021

Published: 30-06-2022

Access this article online

Quick Response Code:



Website:
www.jfmpc.com

DOI:
10.4103/jfmpc.jfmpc_1280_21

This is an open access journal, and articles are distributed under the terms of the Creative Commons Attribution-NonCommercial-ShareAlike 4.0 License, which allows others to remix, tweak, and build upon the work non-commercially, as long as appropriate credit is given and the new creations are licensed under the identical terms.

For reprints contact: WKHLRPMedknow_reprints@wolterskluwer.com

How to cite this article: Nerella S, Sarkar UK, Namdeo H. Electrocardiographic and echocardiographic findings in children with dengue infection. J Family Med Prim Care 2022;11:2334-9.

complications in dengue vary considerably. At one end of the clinical spectrum, patients have mild cardiac symptoms despite relative bradycardia, transient atrioventricular (AV) block, and/or ventricular arrhythmia. At the other severe end, patients may experience acute pulmonary edema and/or cardiogenic shock with left ventricular failure in the form of both systolic and diastolic functional impairment.^[5]

A diverse range of electrocardiogram (ECG) abnormalities has also been reported with dengue. 2D-ECHO is a reliable tool of investigation. Systolic dysfunction in the form of low ejection fraction (EF), diastolic dysfunction in the form of abnormal E/A ratio, and pericardial effusion was reported in the echocardiography.^[6] The correlation of the inferior vena cava (IVC) collapsibility with hematocrit has also been documented as directly proportional.^[7]

The present study was planned to assess the ECG and 2D-ECHO findings of dengue infection and to correlate with the disease severity. This study highlights the importance of detecting cardiac function in dengue-infected children and suggests that timely detection of cardiac decompensation is the key to preventing mortality.

Materials and Methods

The current hospital-based prospective observational study was conducted in the Department of Pediatric Medicine of a tertiary care government hospital in Kolkata. The institutional ethical committee approved the study with reference no. BCH/ME/PR/3778A dated 16.12.2016.

A total of 170 children between 1 month and 12 years seropositive for dengue NS1 ELISA or dengue IgM ELISA during January 2017 to June 2018 were included in the study. Five of them received either fluid boluses or packed Red blood cell (RBC) transfusions for disease severity, 5 of them did not give consent, and in 10 of them, ECHO could not be performed within 48 h of admission. The children co-infected with malaria, enteric fever, tuberculosis, pneumonia, and children with a previous history of any type of cardiac illness were excluded from the study, therefore, the effective study population was 150 children. The children who presented to us within 5 days of fever were subjected to NS1 antigen testing, and then, later confirmed by IgM testing, and those who presented after 5 days of fever were subjected to dengue IgM ELISA.

The cases are classified according to the latest National Guidelines for Clinical Management of Dengue Fever (2015) into mild dengue, dengue with warning signs (DWSS), and severe dengue according to the clinical features and blood counts. Both the stable and unstable patients underwent ECG and 2D-ECHO within 48 h of admission. All ECGs were done by an ECG technician on Clarity ECG 100-C with a paper speed of 25 mm/s. In 12 lead ECGs, the parameters taken were rate, rhythm, voltage, PR interval, and ST-segment. PR interval is

considered prolonged if it is more than 0.14 s in children less than 1 year, more than 0.15 s for children of 1–5 years, more than 0.16 s for children of 5–8 years, and more than 0.17 s for children aged 8–12 years.^[8]

All echocardiograms were done by a single pediatric cardiologist of the department on a Philips HD7 XE machine using a 2–4 MHz phased array pediatric transducer. The parameters studied were systolic and diastolic functions. The systolic function is represented by the EF ratio. The diastolic function is represented by the E/A ratio. An M mode scan of the left ventricular (LV) is obtained from a standard parasternal long-axis view at the level of the mitral valve (MV) tip in all patients. The EF (Teichholz) was calculated using standard formulas. The LV function was considered mildly reduced if the EF was 54–45%, moderately reduced if the EF was 44–31%, and significantly reduced if it was less than 30%. Transmitral pulsed-wave Doppler velocities (peak E- and A-wave velocities) were measured in the apical four-chamber view with the sample volume positioned at the MV. The E/A ratio <1 and >2 is considered abnormal in terms of diastolic dysfunction. The examination of the IVC was done from the subcostal view below the level of the hepatic veins. The diameter of the IVC was measured with the patient in the supine position at 1.0–2.0 cm from the junction with the right atrium (RA), using the long-axis view. The IVC collapsibility index is calculated using the formula: Maximum diameter – minimum diameter/maximum diameter × 100 in spontaneously breathing patients and max diameter – min diameter/min diameter × 100 for ventilated patients. The IVC collapsibility of more than 50% and less than 20% is considered to be abnormal.

All data were compiled and tabulated using the Microsoft Excel sheet. The analysis of the data was performed by using the statistical software SPSS version 22. The ECG and ECHO parameters were reported in the form of categorical variables. The comparison and correlation of the categorical variables were analyzed by the Chi-square tests. The differences between the categories of the dengue infection groups were analyzed by Analysis of variance (ANOVA) with *post hoc* Tukey tests. A probability (*P*) value less than or equal to 0.05 at a 95% confidence interval has been considered statistically significant.

Results

The present study was done on 150 children with dengue seropositivity, out of which 61 cases were of mild dengue, 67 cases were of DWSS, and 22 were severe dengue cases. The study population consisted of 3 children within 1 year, 55 children in the 1–6-year age group, and 92 children in the 7–12-year age group. The mortality rate in the present study was 1.3% (two cases).

After the analysis, it was observed that out of the 150 cases, 78 cases [Table 1] had abnormal ECG findings in the form of heart rate >180/min (7, 4.6%), heart rate <60/min (20, 13.3%) [Table 1], first-degree AV block (4, 2.6%) [Table 1], second-degree AV block (1, 0.6%) [Table 1], low-voltage complexes (41, 27.3%)

cases [Table 2], and non-specific ST-segment changes (5, 3.3%) cases [Table 2]. All the above-mentioned abnormalities in the electrocardiogram were found more so in the severe dengue group. Further, the details are reasserted in the dengue case classification categories.

Abnormal ECHO findings were found in 22 cases (36% of the 61 cases) of mild dengue, 26 cases (38.8% of the 67 cases) of DWWS, and 21 cases (95.4% of the 22 cases) of severe dengue [Table 3]. Multiple comparisons among mild dengue,

DWWS, and severe dengue were done by using the *post hoc* Tukey test for EF, E/A ratio, and IVC collapsibility.

There is no statistically significant association of EF between mild dengue and DWWS ($P=0.865$) [Table 3]. But there is a significant statistical association between mild dengue and DWWS with severe dengue ($P=0.001$, $P=.000$, respectively) [Table 3]. It can be, thus, inferred that there is a significant statistical association of low EF with disease severity [Figure 1].

Table 1: Distribution of dengue cases according to rhythm abnormalities in ECG

| ECG Rhythm | Mild Dengue (%) | DWWS (%) | Severe Dengue (%) | Total (%) |
|-----------------------------|-----------------|-----------|-------------------|-----------|
| Normal rhythm | 48 (78.6) | 38 (56.7) | 02 (9) | 88 (58.6) |
| Sinus Tachycardia | 08 (13.1) | 15 (22.3) | 05 (22.7) | 28 (18.6) |
| Sinus Bradycardia | 05 (8.1) | 13 (19.4) | 11 (50) | 29 (19.3) |
| First-degree AV block | 0 | 01 (1.4) | 03 (13.6) | 04 (2.6) |
| Type second-degree AV block | 0 | 0 | 01 (4.5) | 01 (0.6) |
| Third-degree AV block | 0 | 0 | 0 | 0 |
| Total | 61 | 67 | 22 | 150 |

*DWWS - Dengue with warning signs, *ECG - Electrocardiogram

Table 2: Distribution of dengue cases according to various changes in ECG

| ECG Parameters | Mild Dengue (%) | DWWS (%) | Severe Dengue (%) | Total |
|----------------|-----------------|-----------|-------------------|------------|
| PR interval | | | | |
| Normal | 61 (100) | 66 (98.5) | 18 (81.8) | 145 (96.6) |
| Prolonged | 0 | 01 (1.4) | 03 (13.6) | 04 (2.6) |
| ST-segment | | | | |
| Normal | 61 (100) | 66 (98.5) | 18 (81.8) | 145 (96.6) |
| Depression | 0 | 01 (1.4) | 04 (13.6) | 05 (3.3) |
| Voltage | | | | |
| Normal | 51 (83.6) | 47 (70.1) | 11 (50) | 109 (72.6) |
| Low | 10 (16.3) | 20 (29.8) | 11 (50) | 41 (27.3) |
| Heart rate | | | | |
| <60 | 02 (3.2) | 10 (14.9) | 08 (36.3) | 20 (13.3) |
| 60-90 | 12 (19.6) | 11 (16.4) | 08 (36.3) | 31 (20.6) |
| 91-180 | 46 (75.4) | 40 (59.7) | 06 (27.2) | 92 (61.3) |
| >180 | 01 (1.6) | 06 (8.9) | 0 | 07 (4.6) |

*DWWS - Dengue with warning signs, *ECG - Electrocardiogram

Table 3: Distribution of patient population according to abnormalities in 2D ECHO

| 2D ECHO | Mild Dengue (%) | DWWS (%) | Severe Dengue (%) | Total (%) |
|-------------------------------------|-----------------|------------|-------------------|------------|
| Systolic dysfunction | | | | |
| EF $\geq 55\%$ (normal) | 39 (63.9) | 39 (58.2) | 9 (40.9) | 87 (58) |
| EF 54-45% (mild abnormality) | 21 (34.4) | 22 (32.8) | 8 (36.3) | 51 (34) |
| EF 31-44% (moderate abnormality) | 1 (1.6) | 4 (5.9) | 4 (18.1) | 09 (6) |
| EF $\leq 30\%$ (severe abnormality) | 0 | 2 (2.9) | 1 (4.5) | 03 (2) |
| Diastolic dysfunction | | | | |
| E/A <1 | 0 | 7 (10.4) | 8 (36) | 15 (10) |
| E/A 1-1.4 | 12 (19.6) | 30 (44.7) | 12 (54) | 54 (36) |
| E/A ratio ≥ 1.5 | 49 (80.3) | 30 (44.7) | 2 (9) | 81 (54) |
| E/A >2 | 0 | 0 | 0 | 0 |
| Volume indicator | | | | |
| <20% | 0 | 1 (1.4%) | 0 | 1 (1.4%) |
| IVC collapsibility | | | | |
| 20-30% | 19 (31.1%) | 33 (49.2%) | 3 (13.6%) | 55 (36.6) |
| 31-50% | 36 (59%) | 25 (37.3%) | 5 (22.7%) | 66 (44) |
| >50% | 6 (9.8%) | 8 (11.9%) | 14 (63.6%) | 31 (20.6) |
| Pericardial Effusion | | | | |
| Present | 0 | 05 (7.4) | 06 (27.2) | 11 (7.3) |
| Absent | 61 (100) | 62 (92.5) | 16 (72.7) | 139 (92.6) |

*DWWS - Dengue with warning signs, *2D-ECHO - Two-dimensional echocardiography, *EF - Ejection fraction, *IVC- inferior vena cava

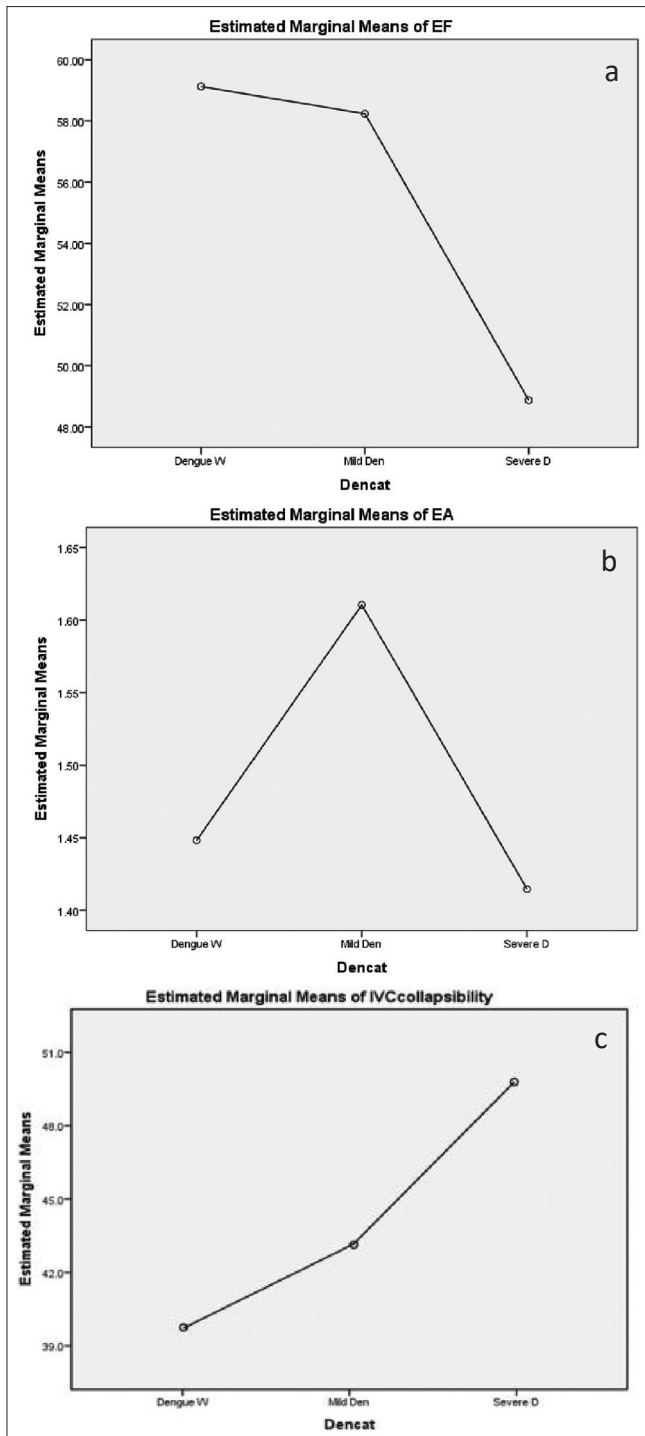


Figure 1: Showing means of systolic dysfunction (EF) (a) Diastolic dysfunction (E/A Ratio) (b) and IVC collapsibility (c) in various dengue infection cases

There is no statistically significant association of the E/A ratio between mild dengue versus DWWS ($P = 0.092$), Mild dengue and DWWS versus severe dengue ($P = 0.044$, $P = .930$, respectively) [Table 3]. There is a significant statistical association of IVC collapsibility between mild dengue versus severe dengue ($P = .001$) and DWWS versus severe dengue ($P = .018$) [Table 3]. But there is no statistically significant association between mild

dengue versus DWWS ($P = .126$) [Table 3]. It can be, thus, inferred that there is a significant statistical association of IVC collapsibility with disease severity [Figure 1].

Discussion

Depression of myocardial function is frequent in dengue hemorrhagic fever and dengue shock syndrome. The dengue-related shock syndrome is due to increased vascular permeability and hypovolemia.^[5,7,9]

A diverse range of ECG abnormalities has been reported with dengue, including rate and rhythm abnormalities, heart block, waveform abnormalities, and voltage abnormalities. Electrocardiogram abnormalities have been observed in as many as 44–75% of the patients with severe dengue [Table 1]. Similar observations were reported by Kumar AS, et al.^[10] (2014). Shandana Tarique et al.^[11] (2013) in their study found 7 (6%) out of 116 cases of ST-segment depression, 4.9% in dengue fever, and 7.2% in dengue hemorrhagic fever (DHF). Kularatne et al.^[12] (2007) have also described ST-segment depression in 3 (2.5%) out of 120 patients of dengue infection. Wali JP, et al.^[13] (1998) also showed, in their study, ST and T-wave abnormalities in 29.4% of the 17 patients. In the present study, 41 (27.3%) cases of low-voltage complexes were found. A study done by Siddappa FD, et al.^[14] (2017) showed that 5% of the cases had low-voltage QRS (Ventricular activation complex) complexes.

In our study, 67 cases (44.6%) out of 150 were spotted to have abnormal echocardiographic findings [Table 3]. Our study results are confirmative with the study done by Kirawittaya T, et al.^[15] (2015) which reported abnormal cardiac functional abnormalities in 40% of their cases. Yacoub et al.^[16] (2012) showed 45% systolic and 42% diastolic cardiac dysfunction. Gupta VK, et al.^[17] (2010) reported mild diastolic dysfunction in their study in 4 out of 28 (14.2%) cases, which is more than that found in our study. Khongphatthanayothin et al.^[18] (2007), in their study found EF <50% in 6.7% dengue fever (DF), 13.8% DHF, and 36% dengue shock syndrome (DSS) patients. Sheetal S, et al.^[19] (2013) had reported 3% cases of pericardial effusion in the dengue patients near about to our study.

The findings of the present study are in conformity with Abhinayaa J^[20] (2021), where 62 patients (47.7%) had ECG changes, the majority of which belonged to the DWSS group. Twenty-seven patients had abnormal echocardiography findings, including pericardial effusion ($n = 23$, 85%) followed by left ventricular EF. Their findings for cardiac involvement were significantly associated with the severity of dengue ($P < 0.0001$) and significant co-relation was noted between the ECG findings and the severity of dengue ($P = 0.022$).

In a study done by Mansangan C, et al.^[21] (2021), cardiac involvement was found in 22.2% of the patients: three (3.70%) had left ventricular systolic dysfunction, three (3.70%) had transient diastolic dysfunction, six (7.41%) had increased levels of at least one cardiac biomarker (troponin-T or CK-MB), and six (7.41%) had small pericardial effusion.

Menwal U, *et al.*^[22] (2020) in their study demonstrated tachycardia as the most common finding (45%) followed by bradycardia (10%) on ECG. Decreased EF is noted in 10% of their patients with DWSS. The association between ECHO and the severity of dengue was found to be highly significant ($P = 0.000$).

Changes in the ECG point toward the myocardial involvement and give clues for further deterioration, hence, early referral to a higher center can bring better outcomes. One of the main causes of mortality in dengue is fluid overload and pulmonary edema, which is seen during the transition from the critical to the convalescence phase. Fluid restriction and maintenance of hemodynamics by the inotropes at this stage is of utmost importance during this time which can be better titrated with echocardiography rather than just relying on clinical features.

The present study has some limitations as this is a single-center study conducted in a tertiary care hospital, therefore, extrapolation to the general population is difficult. Echocardiography and ECG were done on a single occasion and could not be repeated or followed up.

Conclusion

Nearly 50% of the patients had ECG and 2D-ECHO findings in the form of low-voltage complexes, rhythm abnormalities, low EF, pericardial effusion, more so in children with severe dengue. Considering the findings of this study, it can be concluded that there are noteworthy changes in the cardiac functions and more often they are found in a severe dengue group. We often do not use echocardiography in assessing the patient's condition in a dengue infection or any other infectious disease per se, but this study emphasizes the fact that there are obvious cardiac changes according to the severity of the disease. Hence, this study mandates the use of ECG and echocardiography in dengue patients and timely assessing the cardiac function for appropriate fluid therapy. Therefore, on a closing note, echocardiography to assess the myocardial function should be considered, if there is clinical deterioration or suspicion of disease progression.

Take home message

Wherever available, echocardiography may be considered in patients with dengue, particularly with severe disease and refractory shock to tailor their fluid management.

What new this study adds

Most of the studies on cardiac dysfunction in dengue are based on the adult population. The incidence of cardiac dysfunction in dengue varies that from the adult population. Of the pediatric studies on the incidence of ECG and ECHO abnormalities, many are limited to developed countries, and often retrospective, and none from the northeast part of India. Hence, the current study gives valuable information on cardiac dysfunction parameters from the northeastern part of India.

Summary of the key points

1. In our study of 150 children with dengue seropositivity, 61 cases (40%) were mild dengue, 67 cases (45%) were DWSS, and 22 (15%) were severe dengue cases.
2. The study population consists of three children within 1 year, 55 children in the age group of 1–6 years, and 92 children in the 7–12-year age group.
3. The mortality rate in the present study was 1.3% (two cases).
4. Out of 150 cases, 78 cases (52%) had abnormal ECG findings.
5. Bradycardia with a heart rate <60/min is the predominant finding in ECG (25%).
6. Abnormal ECHO findings were found in 46% of our study population.
7. Systolic dysfunction in terms of low EF <54% was the predominant finding among other findings.
8. Low EF and decreased IVC collapsibility were seen more in the severe dengue group.

Declaration of patient consent

The authors certify that they have obtained all appropriate patient consent forms. In the form the patient (s) has/have given his/her/their consent for his/her/their images and other clinical information to be reported in the journal. The patients understand that their names and initials will not be published and due efforts will be made to conceal their identity, but anonymity cannot be guaranteed.

Acknowledgments

We thank all the patients for their co-operation, we thank the ECG technician, lab personnel for timely help. We are indebted to Dr. Sumit Periwal for helping in understanding Echocardiography and Dr. Rahul Biswas for the statistical help.

Financial support and sponsorship

Nil.

Conflicts of interest

There are no conflicts of interest.

References

1. World Health Organization. Dengue: Guidelines for Diagnosis, Treatment, Prevention and Control. New edition. Geneva: World Health Organization; 2009. ISBN 978 92 4 1547871.
2. Nelson ER, Bierman HR, Chulajata R. Hematologic phagocytosis in postmortem bone marrows of dengue hemorrhagic fever. (Hematologic phagocytosis in Thai hemorrhagic fever). *Am J Med Sci* 1966;252:68-74.
3. Marcdante K, Kliegman RM. Nelson Essentials of Pediatrics-E-Book: First South Asia Edition. Elsevier Health Sciences; 2016.
4. Kliegman RM, Stanton BF, St Geme JW III, Schor NF, editors. Nelson Text Book of Pediatrics: First South Asia Edition. Vol. 2. New Delhi: Elsevier; 2016.

5. Yantie NP, Gunawijaya E, Suradipa IW, Gustawan IW. Asymptomatic cardiac rhythm abnormality in children with dengue virus infection. *Bali Med J* 2016;5:177-82.
6. Yacoub S, Wertheim H, Simmons CP, Screaton G, Wills B. Cardiovascular manifestations of the emerging dengue pandemic. *Nat Rev Cardiol* 2014;11:335-45.
7. Kabra SK, Juneja R, Madhulika, Jain Y, Singhal T, Dar L, *et al.* Myocardial dysfunction in children with dengue hemorrhagic fever. *Natl Med J India* 1998;11:59-61.
8. Rijnbeek PR, Witsenburg M, Schrama E, Hess J, Kors JA. New normal limits for the paediatric electrocardiogram. *Eur Heart J* 2001;22:702-11.
9. Salgado DM, Eltit JM, Mansfield K, Panqueba C, Castro D, Vega MR, *et al.* Heart and skeletal muscle are targets of dengue virus infection. *Pediatr Infect Dis J* 2010;29:238-42.
10. Kumar AS, Sibia RS. Atypical presentations in dengue viral infection: Experiences at a tertiary care centre in North India. *Acad Med J India* 2014;2:92-4.
11. Tarique S, Murtaza G, Asif S, Qureshi IH. ECG manifestations in dengue infection. *Ann King Edw Med Univ* 2013;19:282-5.
12. Kularatne SA, Pathirage MM, Kumarasiri PV, Gunasena S, Mahindawanse SI. Cardiac complications of a dengue fever outbreak in Sri Lanka, 2005. *Trans R Soc Trop Med Hyg* 2007;101:804-8.
13. Wali JP, Biswas A, Chandra S, Malhotra A, Aggarwal P, Handa R, *et al.* Cardiac involvement in dengue hemorrhagic fever. *Int J Cardiol* 1998;64:31-6.
14. FD S, H K, Ratageri VH, Wari PK. Cardiac manifestations of Dengue fever in children. *Pediatric Oncall J* 2017;14:82-4.
15. Kirawittaya T, Yoon IK, Wichit S, Green S, Ennis FA, Gibbons RV, *et al.* Evaluation of cardiac involvement in children with dengue by serial echocardiographic studies. *PLoS Negl Trop Dis* 2015;9:e0003943.
16. Yacoub S, Griffiths A, Chau TT, Simmons CP, Wills B, Hien TT, *et al.* Cardiac function in Vietnamese patients with different dengue severity grades. *Crit Care Med* 2012;40:477-83.
17. Gupta VK, Gadpayle A. Subclinical cardiac involvement in dengue hemorrhagic fever. *J Indian Acad Clin Med* 2010;11:107-1.
18. Khongphatthanayothin A, Lertsapcharoen P, Supachokchaiwattana P, La-Orkhun V, Khumtonvong A, Boonlarptaveechoke C, *et al.* Myocardial depression in dengue hemorrhagic fever: Prevalence and clinical description. *Pediatr Crit Care Med* 2007;8:524-9.
19. Sheetal S, Jacob EA. A study on the cardiac manifestations of dengue. *J Assoc Physicians India* 2016;64:30-4.
20. Abhinayaa J, James S, Jebaraj R, Vinoth PN. Incidence of cardiac manifestations in children with dengue fever: A cross-sectional study. *Rambam Maimonides Med J* 2021;12:e0014.
21. Mansanguan C, Hanboonkunupakarn B, Muangnoicharoen S, Huntrup A, Poolcharoen A, Mansanguan S, *et al.* Cardiac evaluation in adults with dengue virus infection by serial echocardiography. *BMC Infect Dis* 2021;21:940.
22. Menwal U, Rawat A, Rawat A, Chandar V. Cardiac manifestations of dengue fever in pediatrics age group. *Indian J Child Health* 2020;7:363-5.