



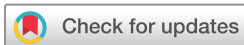Statin treatment for unruptured intracranial aneurysms study: a study protocol for a double-blind, placebo-controlled trial

Wenqiang Li,¹ Yisen Zhang,¹ Zhongbin Tian,¹ Wei Zhu,¹ Jian Liu ,¹ Ying Zhang,¹ Xinjian Yang,¹ De-Cai Tian ^{2,3,4}

To cite: Li W, Zhang Y, Tian Z, *et al.* Statin treatment for unruptured intracranial aneurysms study: a study protocol for a double-blind, placebo-controlled trial. *Stroke & Vascular Neurology* 2020;**5**: e000353. doi:10.1136/svn-2020-000353

WL and YZ are joint first authors.

Received 16 February 2020
Revised 5 April 2020
Accepted 15 April 2020
Published Online First
6 May 2020



© Author(s) (or their employer(s)) 2020. Re-use permitted under CC BY-NC. No commercial re-use. See rights and permissions. Published by BMJ.

¹Department of Interventional Neuroradiology, Beijing Neurosurgical Institute and Beijing Tiantan Hospital, Capital Medical University, Beijing, China

²Department of Neurology, Beijing Tiantan Hospital, Capital Medical University, Beijing, China

³Advanced Innovation Center for Human Brain Protection, Capital Medical University, Beijing, China

⁴China National Clinical Research Center for Neurological Diseases, Beijing, China

Correspondence to

Dr De-Cai Tian;
decaitian@hotmail.com

Dr Xinjian Yang;
yangxinjian@voiceoftiantan.org

ABSTRACT

Background and purpose A large proportion of patients with unruptured intracranial aneurysm (IA) are not suitable for surgical clipping and endovascular treatment. For these patients, anti-inflammatory medications are worth exploring due to inflammation of aneurysmal wall being a major factor in higher risk of rupture. Statin has been proven to reduce inflammation of atherosclerosis and maybe a suitable candidate. This study aimed to evaluate whether atorvastatin will reduce inflammatory of the aneurysm wall measured by the signal index of aneurysm wall enhancement.

Methods and analysis The Statin Treatment for UnruptureD Intracranial aneurysms Study is a single-centre, phase 2, randomised, controlled, double-blind clinical trial. 60 patients with unruptured IAs with aneurysm wall enhancement will be enrolled in Beijing Tiantan Hospital. The patients will be randomised to receive atorvastatin 20 mg or placebo orally per day for 12 months. The primary outcome will be the change in aneurysm wall enhancement measured by the signal index during the 12 months treatment with atorvastatin. The secondary study outcomes will be the change in aneurysm wall enhancement measured by the signal index at 3 months, the changes in aneurysmal morphology and inflammation-related factors (C reactive protein, tumour necrosis factor- α , interleukin-1 β and interleukin-6) at 3 and 12 months. This study is the first to explore the role of atorvastatin in reducing inflammation in unruptured IA, which could lay the groundwork for future phase III trial.

Ethics and dissemination Beijing Tiantan Hospital's Ethics committee approved the research and written informed consents would be obtained from all participant or representative included in this study.

Trial registration number NCT04149483

STRENGTHS AND LIMITATIONS OF THIS STUDY

This is the first prospective registry, randomised controlled trial to confirm the safety and the efficacy of statins in the prevention and treatment of unruptured intracranial aneurysms, which inhibit aneurysm growth and rupture by reduce inflammation in the aneurysmal wall. However, several limitations of the present study must be addressed. This registry focuses on the high-resolution vessel

wall imaging results, while lack the validation with histological finding to confirmed the inflammation change in the aneurysmal wall.

BACKGROUND

Intracranial aneurysms (IAs) are cerebrovascular disorders affecting 3%–5% of the general population.¹ The mortality rate associated with aneurysmal subarachnoid haemorrhage is around 30%–40%, and more than one-third of surviving patients have major neurological deficits.^{2,3} Two modalities are available for prevent aneurysm rupture: surgical clipping and endovascular treatment. Preventive interventions for unruptured IAs might be important to decrease the risk of subarachnoid haemorrhage. However, the morbidity and mortality related to treatment procedures cannot neglectable.⁴ The overall annual risk of aneurysmal rupture is very low, ranging from 0.70% to 0.95%.⁵ Regular imaging scans are recommended to monitoring unruptured IA that are not suitable for surgical clipping and endovascular treatment. Conservative treatment strategy might be recommended for patients with a low risk of rupture. This conservative treatment includes controlling rupture-related risk factors such as hypertension and smoking. No drug treatment to arrest aneurysm growth and subsequent rupture has been established to date.

At the pathological and molecular levels of IA development, the first step seems to be disruption of the elastic laminae and death of the medial smooth muscle cells.⁶ This is followed by aneurysmal outbulging of the arterial wall and inflammatory cell infiltration.⁷ The aneurysmal sac continues to grow until a balance is achieved between ongoing vessel wall repair and extracellular matrix degradation, and inflammatory cell promote the degradation of the matrix.⁸ Further dysfunction or apoptosis of endothelial cells

and vascular smooth muscle cells promotes inflammatory responses in the IA wall, which can ultimately result in aneurysm rupture.^{9 10} Inflammation, thus, seems to be a reaction to the formation, growth and rupture processes of IAs.

High-resolution vessel wall imaging (HR-VWI) by MRI has emerged as a valuable tool in assessing the aneurysmal wall of unruptured IAs. HR-VWI has the potential to identify smaller or more subtle areas of signal enhancement and change, which might provide a more precise representation of the pathological composition. Shimonaga *et al*¹¹ demonstrated that avid wall enhancement of the aneurysm with HR-VWI was correlated with inflammatory cell infiltration. Several studies have suggested that aneurysms with wall enhancement on HR-VWI are frequently unstable (changing morphology, symptomatic or ruptured).^{12 13} Thus, the characterisation of aneurysm wall enhancement is a promising biomarker of aneurysm growth and rupture.

Statins (3-hydroxy-3-methylglutaryl coenzyme A reductase inhibitors) are widely used cholesterol-lowering drugs. In addition to their cholesterol-lowering effect, statins exert pleiotropic effects to protect the vasculature.^{14–16} Statins can reduce the inflammation of the vessel wall and mobilise endothelial progenitor cells for aneurysmal endothelial cell repair.¹⁶ Statins can also inhibit the expression of several matrix metalloproteinases by smooth muscle cells and macrophages.^{17 18} Atorvastatin also inhibits vascular endothelial growth factor and reduces the inflammatory reaction.¹⁵ Thus, we hypothesise that atorvastatin can reduce inflammation in the aneurysmal wall, mobilise endothelial progenitor cells for vascular repair, and further inhibit aneurysm growth and rupture. The present study protocol was designed to test this hypothesis.

METHODS AND DESIGN

Study goals and objectives

The primary outcomes of this study will be the change in aneurysm wall enhancement in patients who receive atorvastatin as measured by HR-VWI at 12 months compared with that in patients who receive placebo. The secondary study outcomes will be changes in aneurysmal morphology and inflammation-related factors (C reactive protein (CRP), tumour necrosis factor- α (TNF- α), interleukin (IL)-1 β , and IL-6) at 3 and 12 months.

STUDY DESIGN

This single-centre, randomised, controlled, double-blind (participants and outcome assessors) clinical trial was designed in accordance with the standard protocol items.¹⁹ This study will enrol 60 eligible patients with unruptured IAs showing aneurysm wall enhancement in Beijing Tiantan Hospital. Study recruitment began in November 2019, and the estimated primary completion date is February 2020.

METHODOLOGY

Patients

Inclusion criteria

1. Male or female aged ≥ 18 years.
2. Unruptured IA of ≥ 3 mm identified on imaging (CT, MRI or digital subtraction angiography).
3. Aneurysm wall enhancement identified by HR-VWI before treatment.
4. Ability to understand the objective of the trial with provision of written informed consent.

Exclusion criteria

1. MRI contraindications (metallic implant, contrast allergy, claustrophobia, etc).
2. Planned treatment of the aneurysm within 12 months.
3. Dyslipidaemia.
4. Current treatment with drugs that might have an anti-inflammatory effect (aspirin, statins, immunosuppressive drugs, etc).
5. Severely impaired liver or renal function.
6. Retreatment of recurrent aneurysm.
7. Pregnant or lactating women.
8. Malignant diseases (liver disease, kidney disease, congestive heart failure, malignant tumours, etc).
9. Poor compliance.

Study description

Ethics approval was obtained from the respective institutional review boards. The study protocol adheres to the international quality standards provided in the Good Clinical Practice guidelines. After informed consent from the patients or their next-of-kin is obtained, the patients will be randomised to receive either 20 mg of atorvastatin (one 20 mg tablet) or 20 mg of placebo (one 20 mg tablet) orally per day for 12 months. The atorvastatin and placebo pills were made by the same laboratory, are composed of starch, and have the same colour, texture and other characteristics.

Outcome measures and follow-up

Primary outcome measures

The primary outcome measure will be the change in aneurysm wall inflammation as measured by MRI HR-VWI. If the aneurysm wall signal intensity is equal, the wall enhancement index and the contrast ratio of the circumference of the aneurysm wall against the stalk (CR_{stalk}) on MRI HR-VWI will be compared between the treatment and placebo groups at the end of 12 months.

Secondary outcome measures

The secondary outcome measures will be as follows:

1. The change in aneurysm wall enhancement measured by the signal index during the 3 months treatment with atorvastatin.
2. Change in aneurysmal morphology from before treatment to the 3 months follow-up. A maximum diameter increases of ≥ 1 mm or the appearance of a daughter sac will be defined as a change in aneurysmal morphology.

3. Change in aneurysmal morphology from before treatment to the 12 months follow-up.
4. Changes in CRP, TNF- α , IL-1 β and IL-6 in patients with unruptured IAs from before treatment to the 3 and 12 months follow-up. The CRP, TNF- α , IL-1 β and IL-6 levels will be measured twice: before treatment and at the 3 months follow-up. Turbidimetric immunoassay will be performed for measurement of the CRP level. ELISA will be performed for measurement of the TNF- α , IL-1 β and IL-6 levels. A blood sample will be drawn from the brachial vein at a fixed time in the morning before breakfast.
5. Changes in CRP, TNF- α , IL-1 β and IL-6 in patients with unruptured IAs from before treatment to the 12 months follow-up.

Randomisation

Random numbers will be generated by an independent third party using the SAS PLAN Procedure (SAS Institute, Cary, North Carolina, USA) for random sequence generation to protect the blinding and integrity of the study. Once the eligibility criteria have been fulfilled, a permuted block randomisation will be carried out. The study drug assignments will be concealed in sealed envelopes. These envelopes will be opened only by on-site study investigators not involved in the clinical management of the recruited patients. The allocation ratio will be 1:1. Both the clinical team (medical and nursing) and the patients will be blinded to the study drug allocation.

Sample size

The wall enhancement index was higher in ruptured aneurysms than unruptured aneurysms (1.70 ± 1.06 vs 0.89 ± 0.88).²⁰ We assumed the atorvastatin have the effect to decrease the wall enhancement index of ruptured aneurysms to unruptured. We estimated that at least 24 patients per group will be required to detect a $\geq 5\%$ difference in the effects of atorvastatin or placebo on the aneurysm wall enhancement index, with a 5% α value and a 20% β value. We assumed that 10%–20% of the patients would not complete the study, and each group is expected to be maximum 30 patients.

HR-VWI MRI protocol

All examinations will be performed on a 3T Siemens Skyra scanner (Siemens Medical Systems, Erlangen, Germany). A standard 20-channel receiver head/neck coil will be used. All patients will undergo higher-resolution three-dimensional black-blood fast spin-echo imaging with a variable flip angle sampling train termed Sampling Perfection with Application-optimised Contrasts using different flip angle Evolutions (SPACE). The sequence parameters will be set following those used in previous studies.¹¹ The spatial resolution will be 0.5 mm isotropic. The following parameters will be used: repetition time/echo time (TR/TE)=1000/17, slice thickness=0.5 mm, number of slices=288, acquisition plane=sagittal, field of view (FOV)=18 \times 18 cm, matrix=360 \times 360, echo train

length=60, echo spacing=5.55 ms, echo train duration=333 ms, bandwidth=400 Hz/pixel, partial Fourier=7/8, and generalized autocalibrating partially parallel acquisitions (GRAPPA) factor=2. Following the SPACE sequence, a higher-resolution contrast-enhanced MR angiography (CE-MRA) study will be performed in the same orientation and centre location as the SPACE sequence. The CE-MRA will be acquired using 20 mL of gadolinium-diethylenetriamine pentaacetic acid (Gd-DTPA) injected at 2 mL/s with a spatial resolution of 0.7 mm isotropic and a total acquisition time of 30 s. The following parameters will be used: TR/TE=2.6/1.2, flip angle=20°, FOV=23 \times 18 cm, matrix=320 \times 200, slab thickness=64 mm and number of partitions=94. The timing delay between contrast injection and initiation of the CE-MRA scan will be determined from low-resolution three-dimensional volumes collected at 1 s intervals using a 2 mL test bolus run. Immediately following the CE-MRA, the SPACE sequence will be repeated.

Image analysis

After the MR images are obtained, multiplanar reformatting will be performed on both the precontrast and postcontrast studies. Images will be generated in three orthogonal planes with identical locations and orientations of the SPACE and CE-MRA data. Viewing the two studies side by side will allow rapid identification of the territory of interest from the CE-MRA and represents an approach that would be useful in the clinical setting.^{20–22}

Two neuroradiologists (with >10 years and >5 years of experience in vascular neuroimaging, respectively), who will be blinded to the clinical data but aware of the patients' aneurysm location(s), will independently review the images with a workstation (syngo workstation; Siemens Healthineers, Erlangen, Germany). Qualitative wall enhancement scores and quantitative parameters will be assigned. For patients with two IAs, each aneurysm will be evaluated separately.

Aneurysm wall signal intensity equal to or greater than that of the pituitary infundibulum will be regarded as enhancement. A scale of 0–5 will be used to grade the aneurysm wall enhancement, with 0 signifying that the aneurysm wall has significant artefacts and/or it is not possible to determine whether the vessel wall is enhanced,²² 1 signifying no enhancement, 2 signifying aneurysm wall enhancement over <25% of the aneurysm surface, 3 signifying wall enhancement over 25%–50% of the aneurysm surface, 4 signifying wall enhancement over 50%–75% of the aneurysm surface and 5 signifying wall enhancement over >75% of the aneurysm surface.

The wall enhancement index and the CR_{stalk} will be used to characterise the extent of enhancement along the aneurysm wall. The details of the procedure are described elsewhere.^{20–21} For estimation of intraobserver and interobserver variability, the parameters on matched precontrast and postcontrast imaging will be remeasured by the reviewer and then measured again by a different

reviewer, who will also be blinded to the clinical data but aware of the aneurysm location.

DISCUSSION

Our study would reinforce evidence suggesting an anti-inflammatory effect on the aneurysm wall of statins in unruptured IA patients, and might be inhibit the process of IA growth and rupture.

Unruptured IAs can remain unchanged for a long time before undergoing episodes of rapid growth, which they are more prone to rupture, suggest that aneurysm growth is discontinuous and stochastic rather than linear.¹⁰ The overall annual risk of aneurysm growth and rupture is so low that it is difficult or long follow-up periods are needed to observe aneurysm changing. Three-dimensional HR-VWI techniques have recently increased in utilisation for VWI.¹² HR-VWI has the potential to identify small or subtle areas of signal change or enhancement, more precisely delineate aneurysm wall thickness, and provide a more precise representation of the pathological composition. Several studies have suggested that have confirmed wall enhancement on HR-VWI with the presence of inflammatory changes on histopathological specimens. Aneurysmal wall enhancement on HR-VWI might help in identifying unruptured IAs with a higher risk of rupture, and could serve as imaging biomarkers to predict the growth and rupture of aneurysms. In the present study, we will perform HR-VWI for all patients to evaluate the wall enhancement of aneurysm before and after statin, and compared with the placebo control group. Our study will provide prospectively validated data of HR-VWI to help in making clinical treatment decisions for patients with unruptured IAs.

Statin has been confirmed to suppress the stimulation of inflammation reaction, as well as play a role in treating inflammatory diseases. However, the relationship between statin use and risk of IA rupture has been a matter of debate in recent years. In several animal studies, Aoki *et al*¹⁸ found that treatment with statins suppresses the development of IAs by inhibiting inflammatory reactions in the aneurysmal walls and has a preventive effect on the progression of preexisting IAs. In contrast, Tada *et al*²³ found bidirectional effects of statins on IAs in that statins could reduce endothelial damage and inhibit aneurysm formation while also promoting aneurysmal growth and inducing aneurysmal rupture. However, no prospective clinical data are available, and several retrospective studies also have controversial results. Can *et al*²⁴ and Yoshimura *et al*²⁵ found an inverse relationship between use of statins and cerebral aneurysm rupture, while Marbacher *et al*²⁶ suggested that statins may have no significant beneficial effect on IA suppression in humans. Thus, a prospective randomised clinical trial is necessary to confirm the safety of statins in the prevention and treatment of IAs. In addition, for the dosage of statin, long-term high-dose statin therapy was also increased risk of side effect, especially in Asian descent.^{27 28} Several studies

have demonstrated that the dose of 20 mg of atorvastatin could provide anti-inflammatory effect with decrease inflammatory biomarkers and inflammatory cell content in vascular wall.^{29 30} For the safety and efficacy of statin, we selected the dose of 20 mg of atorvastatin as rational intervention in this study.

TRIAL STATUS

This is an ongoing study. The trial was in the recruitment stage at the time of submission of this manuscript.

SAFETY CONSIDERATIONS

Drug-related morbidities, including rhabdomyolysis and hepatitis, are rare. The plasma levels of creatinine phosphokinase, alanine aminotransferase, and aspartate aminotransferase will be monitored for early signs of hepatitis or myositis every 7 days or on clinical suspicion. Administration of the study drug will cease if alanine aminotransferase or aspartate aminotransferase is more than three times the normal level of 180 U/L or the creatinine phosphokinase level is ≥ 1000 U/L. In addition, fatal bleeding and primary intracranial haemorrhage will be major safety end points.

FOLLOW-UP

Patients will be followed up for 3 and 12 months with clinic visits. HR-VWI MRI and blood tests will be performed at the follow-up visits to evaluate the disease status. Additionally, contact information will be provided to the enrolled patients for questions or possible adverse event reporting during the study period.

DATA MANAGEMENT AND STATISTICAL ANALYSIS

Data management

Final data capture and storage will be done via electronic case report forms using an electronic database that is fully compliant with privacy regulations (Health Insurance Portability and Accountability Act/Personal Information Protection and Electronic Documents Act). In addition to the electronic case report forms, data will be retained along with relevant supporting documentations such as scans, progress notes, nursing notes and blood work. All records and documents pertaining to the study will be retained at all participating study trial sites for at least 10 years after completion of the study, and these data will be available for inspection by the research ethics board, quality assurance board and other regulatory bodies. Hard copy study files (consent forms, questionnaires and coordinator source notes from the participants' research charts) will be kept secured within the Department of Neurosurgery. All computerised files will be password protected.

Statistical analysis

The association between independent parameters will be evaluated using the χ^2 test or Fisher's exact test for



categorical variables and the non-parametric Mann-Whitney U test for continuous variables. The Wilcoxon signed-ranks test will be used to compare the pretreatment and post-treatment variables. The bivariate nonparametric correlation between HR-VWI wall enhancement on MRI and blood inflammatory markers will be tested using Spearman's r coefficient. Statistical significance will be established at two-tailed $p < 0.05$.

Quality assurance

The data safety and monitoring board will monitor the progress of the study to ensure the patient safety and the highest standards of ethics. Annual monitoring will be performed by an independent clinical monitor within the hospital. Interim progress reports will be sent to the local medical ethics review board and to the funding agency. The principal investigator and coordinating investigator have successfully completed the course on Good Clinical Practice, and the study will be carried out in accordance with these guidelines.

Expected outcomes of the study

This study will clarify whether oral atorvastatin is more effective than placebo in reduction of aneurysmal wall enhancement of IAs. This effect may be important in reducing the growth and rupture of unruptured IAs in terms of neurological outcomes and cost-effectiveness.

Duration of the project

We plan to enrol 60 patients with a maximum 12 months follow-up period for each patient.

Project management

The study steering committee is being led by the principal investigators. The committee is responsible for the study design, study implementation, ethics and health authority applications, protocol amendments, eventual data interpretation and dissemination of the results. The statistical design and randomisation are being supervised by the China National Clinical Research Center for Neurological Diseases. The site study investigators are responsible for recruiting patients, reporting adverse events and completing the data collection.

Contributors WL performed the manuscript writing. DT and YisZ made critical revision to the manuscript for important intellectual content. WL, ZT, WZ, JL, YinZ and YisZ participated in the final design of the study. DT and XY conceived and designed the research, and handled funding and supervision. All authors read and approved the final manuscript.

Funding This work was supported by National Key Research and Development Plan of China (grant number: 2016YFC1300800), the National Natural Science Foundation of China (grant numbers: 81220108007, 81801156, 81801158, 81471167, 81801199 and 81671139) and the Special Research Project for Capital Health Development (grant number: 2018-4-1077). Beijing Hospitals Authority Youth Programme (code: QML20190503).

Competing interests None declared.

Patient consent for publication Not required.

Ethics approval The study has been approved by the Ethics Committee of Beijing Tiantan Hospital. This clinical trial will be conducted in accordance with the principles laid down by the 18th World Medical Assembly (Declaration of Helsinki, 1964) and

all applicable amendments laid down by the World Medical Assemblies and the International Conference on Harmonisation Guidelines for Good Clinical Practice.

Provenance and peer review Not commissioned; externally peer reviewed.

Data availability statement Data are available on reasonable request.

Open access This is an open access article distributed in accordance with the Creative Commons Attribution Non Commercial (CC BY-NC 4.0) license, which permits others to distribute, remix, adapt, build upon this work non-commercially, and license their derivative works on different terms, provided the original work is properly cited, appropriate credit is given, any changes made indicated, and the use is non-commercial. See: <http://creativecommons.org/licenses/by-nc/4.0/>.

ORCID iDs

Jian Liu <http://orcid.org/0000-0002-5454-2847>

De-Cai Tian <http://orcid.org/0000-0002-5153-2491>

REFERENCES

- Macdonald RL, Schweizer TA. Spontaneous subarachnoid haemorrhage. *Lancet* 2017;389:655–66.
- Nieuwkamp DJ, Setz LE, Algra A, *et al.* Changes in case fatality of aneurysmal subarachnoid haemorrhage over time, according to age, sex, and region: a meta-analysis. *Lancet Neurol* 2009;8:635–42.
- Stegmayr B, Eriksson M, Asplund K. Declining mortality from subarachnoid hemorrhage: changes in incidence and case fatality from 1985 through 2000. *Stroke* 2004;35:2059–63.
- Brown RD, Broderick JP. Unruptured intracranial aneurysms: epidemiology, natural history, management options, and familial screening. *Lancet Neurol* 2014;13:393–404.
- The UCAS Japan Investigators. The natural course of unruptured cerebral aneurysms in a Japanese cohort. *N Engl J Med Overseas Ed* 2012;366:2474–82.
- Frösen J, Tulamo R, Paetau A, *et al.* Saccular intracranial aneurysm: pathology and mechanisms. *Acta Neuropathol* 2012;123:773–86.
- Jamous MA, Nagahiro S, Kitazato KT, *et al.* Endothelial injury and inflammatory response induced by hemodynamic changes preceding intracranial aneurysm formation: experimental study in rats. *J Neurosurg* 2007;107:405–11.
- Meng H, Tutino VM, Xiang J, *et al.* High WSS or low WSS? complex interactions of hemodynamics with intracranial aneurysm initiation, growth, and rupture: toward a unifying hypothesis. *AJNR Am J Neuroradiol* 2014;35:1254–62.
- Frösen J. Smooth muscle cells and the formation, degeneration, and rupture of saccular intracranial aneurysm wall—a review of current pathophysiological knowledge. *Transl Stroke Res* 2014;5:347–56.
- Etmninan N, Rinkel GJ. Unruptured intracranial aneurysms: development, rupture and preventive management. *Nat Rev Neurol* 2016;12:699–713.
- Shimonaga K, Matsushige T, Ishii D, *et al.* Clinicopathological insights from vessel wall imaging of unruptured intracranial aneurysms. *Stroke* 2018;49:2516–9.
- Lehman VT, Brinjikji W, Mossa-Basha M, *et al.* Conventional and high-resolution vessel wall MRI of intracranial aneurysms: current concepts and new horizons. *J Neurosurg* 2018;128:969–81.
- Samaniego EA, Roa JA, Hasan D. Vessel wall imaging in intracranial aneurysms. *J Neurointerv Surg* 2019;11:1105–12.
- Bellosta S, Ferri N, Bernini F, *et al.* Non-lipid-related effects of statins. *Ann Med* 2000;32:164–76.
- Jiang R, Zhao S, Wang R, *et al.* Safety and efficacy of atorvastatin for chronic subdural hematoma in Chinese patients: a randomized Clinical Trial. *JAMA Neurol* 2018;75:1338–46.
- Potey C, Ouk T, Petrault O, *et al.* Early treatment with atorvastatin exerts parenchymal and vascular protective effects in experimental cerebral ischaemia. *Br J Pharmacol* 2015;172:5188–98.
- Aikawa M, Rabkin E, Sugiyama S, *et al.* An HMG-CoA reductase inhibitor, cerivastatin, suppresses growth of macrophages expressing matrix metalloproteinases and tissue factor in vivo and in vitro. *Circulation* 2001;103:276–83.
- Aoki T, Kataoka H, Ishibashi R, *et al.* Simvastatin suppresses the progression of experimentally induced cerebral aneurysms in rats. *Stroke* 2008;39:1276–85.
- Chan A-W, Tetzlaff JM, Götzsche PC, *et al.* Spirit 2013 explanation and elaboration: guidance for protocols of clinical trials. *BMJ* 2013;346:e7586.
- Omodaka S, Endo H, Niizuma K, *et al.* Circumferential wall enhancement on magnetic resonance imaging is useful to identify rupture site in patients with multiple cerebral aneurysms. *Neurosurgery* 2018;82:638–44.

- 21 Omodaka S, Endo H, Niizuma K, *et al.* Quantitative assessment of circumferential enhancement along the wall of cerebral aneurysms using MR imaging. *AJNR Am J Neuroradiol* 2016;37:1262–6.
- 22 Tian B, Toossi S, Eisenmenger L, *et al.* Visualizing wall enhancement over time in unruptured intracranial aneurysms using 3D vessel wall imaging. *J Magn Reson Imaging* 2019;50:193–200.
- 23 Tada Y, Kitazato KT, Yagi K, *et al.* Statins promote the growth of experimentally induced cerebral aneurysms in estrogen-deficient rats. *Stroke* 2011;42:2286–93.
- 24 Can A, Castro VM, Dligach D, *et al.* Lipid-Lowering agents and high HDL (high-density lipoprotein) are inversely associated with intracranial aneurysm rupture. *Stroke* 2018;49:1148–54.
- 25 Yoshimura Y, Murakami Y, Saitoh M, *et al.* Statin use and risk of cerebral aneurysm rupture: a hospital-based case-control study in Japan. *J Stroke Cerebrovasc Dis* 2014;23:343–8.
- 26 Marbacher S, Schläppi J-A, Fung C, *et al.* Do statins reduce the risk of aneurysm development? A case-control study. *J Neurosurg* 2012;116:638–42.
- 27 Mancini GBJ, Baker S, Bergeron J, *et al.* Diagnosis, prevention, and management of statin adverse effects and intolerance: Canadian consensus Working group update (2016). *Can J Cardiol* 2016;32:S35–65.
- 28 Stroes ES, Thompson PD, Corsini A, *et al.* Statin-associated muscle symptoms: impact on statin therapy-European atherosclerosis Society consensus panel statement on assessment, aetiology and management. *Eur Heart J* 2015;36:1012–22.
- 29 Kajimoto K, Miyauchi K, Kasai T, *et al.* Short-Term 20-mg atorvastatin therapy reduces key inflammatory factors including c-Jun N-terminal kinase and dendritic cells and matrix metalloproteinase expression in human abdominal aortic aneurysmal wall. *Atherosclerosis* 2009;206:505–11.
- 30 Komukai K, Kubo T, Kitabata H, *et al.* Effect of atorvastatin therapy on fibrous cap thickness in coronary atherosclerotic plaque as assessed by optical coherence tomography: the EASY-FIT study. *J Am Coll Cardiol* 2014;64:2207–17.