

Terminalia Chebula Attenuates DMBA/Croton Oil-Induced Oxidative Stress and Inflammation in Swiss Albino Mouse Skin

Ferial Majed, Sana Nafees, Summya Rashid, Nemat Ali, Syed Kazim Hasan, Rashid Ali, Ayaz Shahid, Sarwat Sultana

Department of Medical Elementology and Toxicology, Faculty of Science, Section of Molecular Carcinogenesis and Chemoprevention, Jamia Hamdard (Hamdard University), Hamdard Nagar, New Delhi, India

ABSTRACT

Objective: The present study was designed to investigate underlying molecular mechanism for antitumorigenic potential of *Terminalia chebula* (TC) against chemically-induced skin tumorigenesis in Swiss albino mice. It is used as herbal medicine because it exhibits antioxidant, anti-inflammatory, and anticarcinogenic activity. However, the précised underlying mechanism remains to be elucidated. **Materials and Methods:** In light of the important role of nuclear factor-kappaB (NF-κB), cyclooxygenase-2 (COX-2), inducible nitric oxide synthase (i-NOS), ornithine decarboxylase (ODC), proinflammatory cytokines, oxidative stress in carcinogenesis, chemopreventive efficacy of TC against 7,12-dimethylbenz[a] anthracene (DMBA), and croton oil-induced 2-stage skin carcinogenesis was studied in terms of cytoprotective antioxidant enzymes activity, lipid peroxidation (LPO), inflammatory responses, and expression of various molecular markers in skin tissues. **Results:** We found that topical application of TC at dose of 30 mg/kg b. wt. mouse effectively suppressed oxidative stress and deregulated activation of inflammatory mediators and tumorigenesis. Histological findings further supported the protective effects of TC against DMBA/croton oil-induced cutaneous damage. **Conclusion:** The findings of the present study suggest that the chemopreventive effect of TC is associated with upregulation of endogenous cytoprotective machinery and downregulation of inflammatory mediators (interleukin (IL)-6, COX-2, i-NOS, ODC, and NF-κB).

Key words: Cytokines, inflammation, proinflammatory markers, *Terminalia chebula*, Skin carcinogenesis

INTRODUCTION

Skin cancer is mainly caused by various environmental carcinogens, inflammatory agents, ultraviolet (UV) irradiation and/or tumor promoters. Murine skin

Address for correspondence: Dr. Sarwat Sultana, Department of Medical Elementology and Toxicology, Faculty of Science, Section of Molecular Carcinogenesis and Chemoprevention, Jamia Hamdard (Hamdard University), Hamdard Nagar, New Delhi - 110 062, India.
E-mail: sarwat786@rediffmail.com

tumorigenesis is an excellent *in vivo* model to study the chemopreventive activity of natural/synthetic agents.^[1] Tumor development can also be caused by multiple applications of croton oil, a tumor promoter, which is a slow and reversible process and leads to skin tumors in mouse by inducing hyperplasia and inflammatory responses.^[2,3] 7,12-dimethylbenz[a] anthracene (DMBA), a carcinogen, initiates skin tumorigenesis which is a rapid and irreversible process. The croton oil is the most widely used

This is an open access article distributed under the terms of the Creative Commons Attribution-NonCommercial-ShareAlike 3.0 License, which allows others to remix, tweak, and build upon the work non-commercially, as long as the author is credited and the new creations are licensed under the identical terms.

For reprints contact: reprints@medknow.com

How to cite this article: Majed F, Nafees S, Rashid S, Ali N, Hasan SK, Ali R, *et al.* Terminalia chebula attenuates DMBA/Croton Oil-Induced oxidative stress and inflammation in Swiss albino mouse skin. *Toxicol Int* 2015;22:21-9.

Access this article online

Quick Response Code:



Website:

www.toxicologyinternational.com

DOI:

10.4103/0971-6580.172252

distinguished promoting agent to understand the cellular and molecular alterations associated with promotion stage and also a well-known model to understand the role of inflammation, generation of reactive oxygen species (ROS), and hyperplasia in cancer promotion.^[4,5]

Inflammatory responses play an important role in all the stages of carcinogenesis, including; initiation, promotion, malignant conversion, invasion, and metastasis.^[6] Various observations reveal that inflammation is one of the key events inducing cancer development by various mechanisms, such as production of ROS. ROS and free radicals play a significant role in induction of many diseases such as cancer, ageing, atherosclerosis, asthma, and diabetes.^[7,8] However, uncontrolled production of ROS or change in intracellular antioxidants level causes damage or modification of cellular macromolecules,^[9] which on activation produce these kinds of free radicals to kill the pathogens.

Aberrant production of inflammatory mediators like proinflammatory cytokines such as tumor necrosis factor (TNF)- α , interleukin (IL)-6, IL-1 β , and NO have critical role in multistage cancer development. Cytokines, chemokines, and eicosanoids are the inflammatory mediators known to have important role at promotion phase of carcinogenesis inflammatory responses including expression of cyclooxygenase-2 (COX-2) enzyme and ROS. These factors play a critical role in carcinogenesis stage.^[6,10] Ornithine decarboxylase (ODC) enzyme activity and thymidine incorporation into DNA synthesis can be used as biomarkers of skin tumorigenesis.^[11] Nuclear factor-kappa B (NF- κ B) is one of the most important transcription factor known to regulate the expression of genes involved in inflammation, cell proliferation, and survival. One of the downstream targets of NF- κ B is COX-2. Uncontrolled expression of COX-2 has been observed in different premalignant as well as in malignant stage.^[12] TC, commonly known as the king of medicine, is a plant of Combretaceae family which is used in number for ayurvedic productions.^[13] Naturally occurring phenolics are richly found in edible vegetables, nuts, and fruits and constitute an important part of the human diet. TC has been reported to exhibit a variety of biological effects, for example, antioxidant, anticancer, and antimutagenic.^[14] In antioxidant patterns, the active constituents of TC are gallic acid, ellagic acid, tannic acid, ethyl gallate, chebulagic acid, chebulinic acid, etc.

The present study was designed to investigate the preventive effects of TC on DMBA/croton oil-induced initial and promotional changes in mouse skin and explore the underlying molecular mechanism. To test this possibility, we have studied the preventive effects of TC on the DMBA/croton oil-induced activation of NF- κ B and its downstream target COX-2, ODC, and inducible nitric oxide synthase (i-NOS) via cutaneous oxidative stress, inflammation, and IL-6 production.

MATERIALS AND METHODS

Chemicals

Reduced glutathione (GSH), glutathione reductase (GR), oxidized glutathione (GSSG), 1-chloro-2,4-dinitrobenzene (CDNB), 5,50-dithiobis-(2-nitrobenzoic acid) (DTNB), reduced nicotinamide adenine dinucleotide phosphate (NADPH), ethylenediamine tetraacetic acid (EDTA), sulfosalicylic acid, horseradish peroxidase (HRP), hydrogen peroxide, xanthine, xanthine oxidase (XO), acetone, DMBA, *Terminalia chebula* (TC), and croton oil were purchased from Sigma-Aldrich Co. (St Louis, MO, USA). All the other reagents used were of analytical grade and highest purity.

Animals

Female Swiss albino mice 6–8-weeks-old, weighing 20-30 g, were obtained from the Central Animal House Facility of Hamdard University. Animals received humane care in accordance with the guidelines of the Committee for the Purpose of Control and Supervision of Experiments on Animals (CPCSEA), Government of India, and prior permission was sought from the Institutional Animal Ethics Committee (IAEC) of the university.

Treatment regimen

To observe the effect of TC on DMBA/croton oil-induced cutaneous oxidative and inflammatory responses, animals were divided into four groups (I–IV) of 10 animals ($n = 10$) each. Dorsal skin of all the animals was shaved with the electric clipper 2 days prior to the start of the experiment. Only mice that showed no signs of hair regrowth were included in the experiments. All the treatments were done topically onto the shaved area of dorsal skin.

Group I: Animals of this group served as control and were given topical application of vehicle (0.2 ml acetone).

Group II: Animals were given a single topical application of DMBA (50 μ g) in 0.2 ml acetone. One week after the initiation, croton oil (1%) in 0.2ml acetone was applied twice a week for 20 consecutive weeks.

Group III: Animals were given a single topical application of DMBA (50 μ g) in 0.2 ml acetone. After 1 week of pretreatment of TC at the dose 30 mg/kg b. wt., in 0.2 ml acetone 30 min before croton oil (1% in 0.2 ml acetone) was given topically twice a week until the termination of the experiment at 20 weeks.

Group IV: Animals were given topical application of TC (30 mg/Kg b. wt.) in 0.2 ml acetone up to the termination of the experiment at 20 weeks.

At the end of 20 weeks, all the animals were euthanized by light ether anesthesia and exsanguinations. Their skin

was quickly removed and processed for various molecular, histopathological, and immunohistochemical studies.

Biochemical studies

Assay for lipid peroxidation (LPO), catalase (CAT), GSH, glutathione peroxidase (GPx), GR, glutathione-S-transferase (GST), XO, hydrogen peroxide (H₂O₂), and protein estimation was done by the method as described by Khan *et al.*^[15]

Assay for IL-6 level

Level of all the proinflammatory cytokines was measured with commercially available kits. Tissue was homogenized and measured by enzyme-linked immunosorbent assay (ELISA) kit (eBioscience Inc, San Diego, USA). Analysis was performed according to the manufacturer's instruction.

Immunohistochemistry

Skin sections on polylysine coated slides obtained were fixed in neutral buffered formalin, embedded in paraffin, and was treated for NF-κB, COX-2, ODC, and iNOS antibody for immunohistochemical analysis. The procedure was processed according to the manufacturer's protocol with slight modifications.

Histological investigation

The skin were quickly removed after sacrifice and preserved in 10% neutral buffered formalin for histopathological processing. The skin were embedded in paraffin wax and longitudinally sectioned with a microtome. Hematoxylin and eosin staining of the sections was observed under an Olympus microscope.

Morphological assessment

Observed and measured at weekly interval percentage of tumor incidence, tumor bearing mouse, body weight, and cumulative number of papillomas. Only tumors, those persisted more than 2 week with diameter greater than 1 mm were taken into consideration for evaluation of the data. Percentage of tumor incidence was calculated by dividing the number of tumor-bearing mice with the total

number of mice in a particular group and multiplied with 100%.

Statistical analysis

The data from individual groups were presented as the mean ± standard error of the mean (SEM). Differences between groups were analyzed using analysis of variance (ANOVA) and minimum criterion for statistical significance was set at $P < 0.05$.

RESULTS

Effect of TC on DMBA/croton oil-induced oxidative stress in mouse skin

Exposure of DMBA and croton oil resulted in significant increase in the level of MDA in Group II as compared Group I ($P < 0.001$). In Group III, it significantly ($P < 0.001$) inhibited the formation of MDA as compared to Group II. There was no significant change observed in the level of MDA between Groups I and IV [Figure 1a]. Skin H₂O₂ content was measured and the results were shown in Figure 1b. There was significant increase between Groups I and II ($P < 0.001$). We have observed that in Group III, it significantly inhibited H₂O₂ formation ($P < 0.001$) as compared to Group II ($P < 0.001$). There is no significant difference between Groups I and IV. Also, elevation of XO activity was observed in Group II when compared with Group I ($P < 0.001$). We have observed that topical application of TC was significantly effective in the reduction of XO activity in Group III when compared with Group II ($P < 0.001$). There was no significant difference observed between Groups I and IV as far as XO activity is concerned [Figure 1c]. It was found effective in restoration of endogenous antioxidant CAT activity. There was significant depletion in the level of CAT activity in Group II as compared to Group I ($P < 0.001$). Group III showed significant increase in the level of CAT ($P < 0.001$) as compared to Group II. There was no significant difference in CAT level between Groups I and IV [Figure 2a and Table 1]. It has been observed that the level of reduced GSH was significantly depleted in Group II as compared with Group I ($P < 0.001$). Group III showed significant increase in the

Table 1: Effect of TC on the antioxidant enzymes

Groups	Glutathione reductase nmol NADPH Oxidised/min/mg protein	Glutathione peroxidase nmol NADPH protein oxidized/min/mg protein	Glutathione-S-transferase nmol CDNB protein conjugate	Catalase n mole H ₂ O Consumed/min/mg protein formed/min/mg protein
I	40.7±0.207	30.1±0.009	92.5±0.273	70.6±0.062
II	20.1±0.032***	20.0±0.009***	49.5±0.153***	30.4±0.085***
III	30.5±0.161###	25.0±0.227###	72.4±2.580###	40.4±0.045###
IV	40.7±0.206	30.1±0.206	92.0±0.028	79.1±0.045

Values are expressed as mean±SEM (n=10). *** $P < 0.001$ shows significant depletion in the activities of different antioxidant enzymes in DMBA/croton oil-treated group II as compared to vehicle-treated group I (0.2 ml acetone). ### $P < 0.001$ shows significant restoration in the activities of these enzymes in TC pretreatment group III (TC (30 mg) + DMBA/croton oil (1%)) as compared to DMBA/croton oil-treated group II (croton oil (1%)). SEM=Standard error of the mean, DMBA=7,12-dimethylbenz [a] anthracene, TC=*Terminalia chebula*, CDNB=1-chloro-2,4-dinitrobenzene, NADPH=reduced nicotinamide adenine dinucleotide phosphate

level of GSH ($P < 0.001$) as compared to Group II. There was no significant difference in GSH level between Groups I and IV [Figure 2b]. Also, depletion in the activities of different antioxidant enzymes was examined and the results are shown in Table 1. We have observed that there was a significant ($P < 0.001$) decrease in the activity of different antioxidant enzymes in Group II as compared to Group I. However, Group III significantly ($P < 0.001$) restored

the activity of antioxidant enzymes when compared with Group II. There was no significant difference observed between Groups I and IV.

Effect of TC on IL-6

IL-6 levels in the skin tissue of Group II was significantly elevated ($P < 0.001$) as compared to Group I. TC

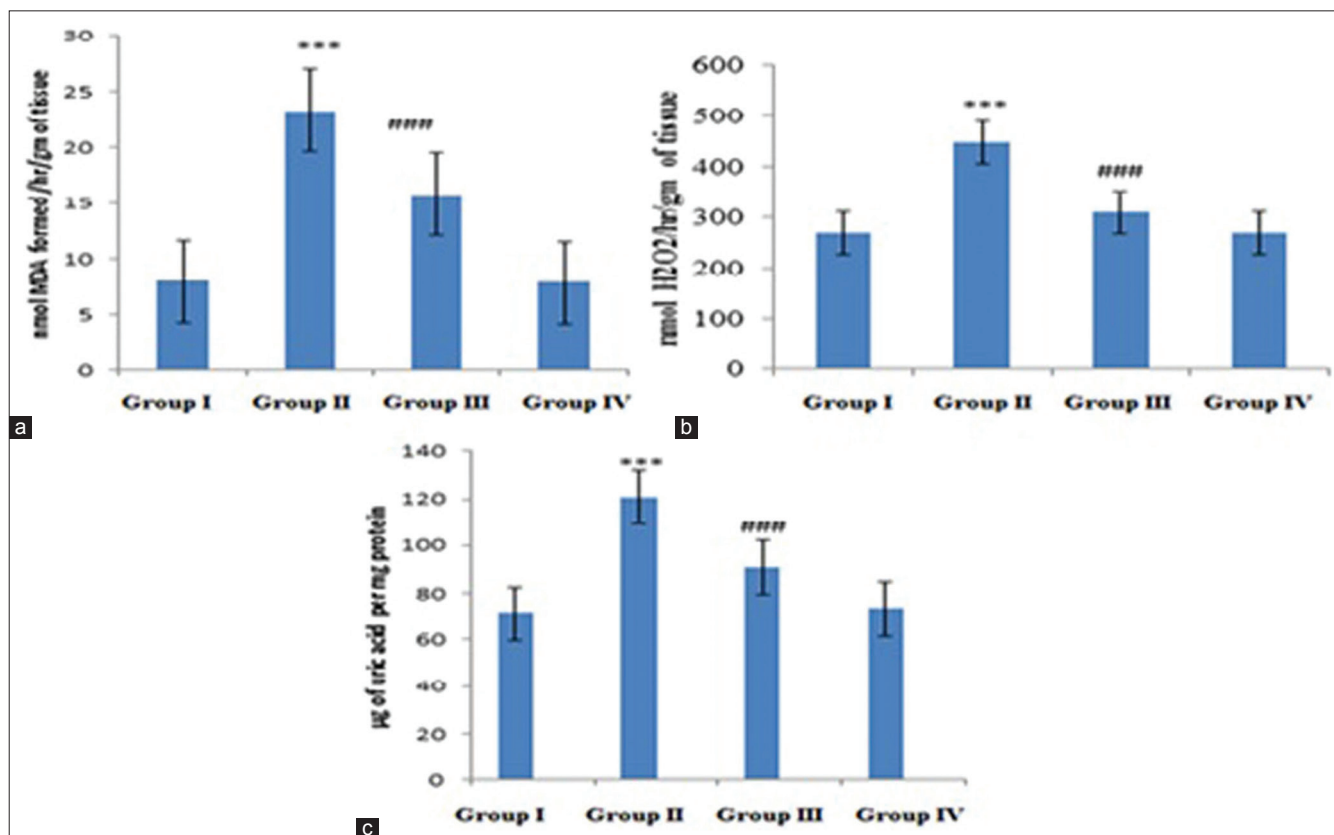


Figure 1: Effect of *Terminalia chebula* (TC) on DMBA/croton oil-induced (a) lipid peroxidation, (b) H₂O₂ production, and (c) xanthine oxidase activity in skin of mice from different treatment groups. Values are expressed as means±SEM ($n=10$) of nmol MDA formed/h/g of tissue, nmol H₂O₂/h/g of tissue, and µg uric acid/mg protein, respectively. *** $P < 0.001$ shows significant difference in Group II when compared with Group I. ### $P < 0.001$, ### $P < 0.001$ shows significant difference in the Group III when compared with Group II. SEM=Standard error of the mean, DMBA = 7, 12-dimethylbenz[a]anthracene

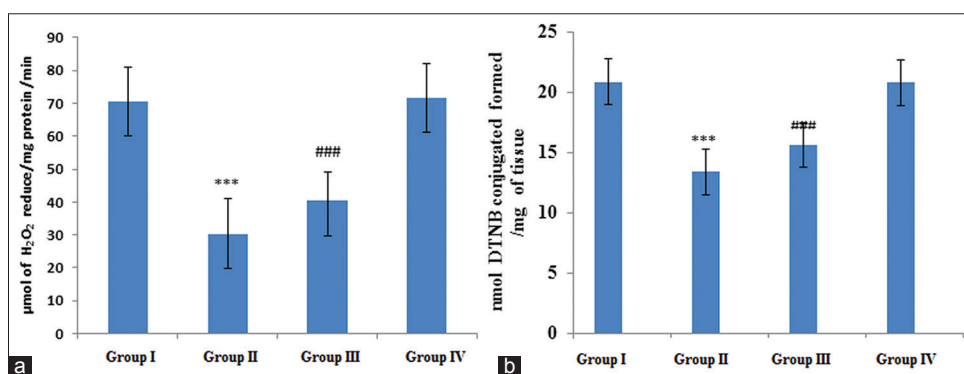


Figure 2: Effect of TC pretreatment on DMBA/croton oil-induced cutaneous (a) CAT and (b) GSH level. Values are expressed as mean±SEM ($n=10$). *** $P < 0.001$ shows significant difference in Group II (DMBA/croton oil (1%) in 200 µl acetone) when compared with Group I. ### $P < 0.001$ shows significant difference in Group III (TC (30 mg) + DMBA/croton oil (1%)) when compared with DMBA/croton oil-treated Group II. CAT = catalase, GSH = reduced glutathione

administration showed a significant reduction of IL-6 levels production in Group III when compared with Group II ($P < 0.001$). There was no significant difference found between Groups I and IV as far as release of IL-6 is concerned. There was no significant difference found between Groups I and IV as far as release of IL-6 is concerned [Figure 3].

Effect of TC on tumor incidence and histopathological observations in tumor study

Topical application of TC was further observed for cutaneous histological alteration caused by DMBA + croton oil application with reference to neutrophil infiltration and epidermal hyperplasia as shown in Figure 4. We found an increase in the leukocyte infiltration and epidermal thickening in Group II [Figure 4b] as compared to Group I [Figure 4a]. In Group III, diminished leukocyte infiltration as well as hyperplasia was observed [Figure 4c]. There was no distinguished change observed between Groups I and IV [Figure 4d] as far as leukocyte infiltration and hyperplasia is concerned. Tumors begin to appear on the skin from week 9 to 20, during the promotion period. Protective effects of TC on skin carcinogenesis are shown in Table 2. Animals of Groups I and IV did not show

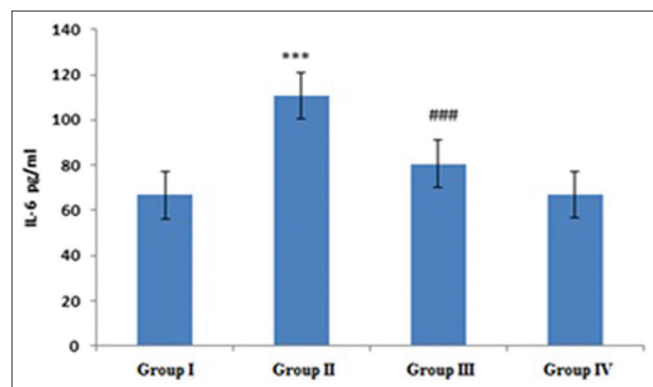


Figure 3: Effect of TC pretreatment on DMBA/croton oil-induced cutaneous IL-6 cytokines. Values are expressed as mean \pm SEM ($n=10$). *** $P < 0.001$ shows significant difference in Group II (DMBA/croton oil (1%) in 200 ml acetone) when compared with Group I (vehicle alone), ### $P < 0.001$ shows significant difference in the Group III (TC (30 mg) + DMBA/croton oil (1%)) when compared with DMBA/croton oil-treated Group II

any significant variation in body weight during the entire experiment and there was no mortality. No noticeable signs of weight loss and papilloma were detected in the mice of Groups IV and I, but was found significant in Groups II and III. The incidence of papilloma was different in Group II (100%) as compared to Group III (40%). Cumulative number of papillomas was 118 in Group II, which was significantly reduced to 21 in Group III.

Effect of TC on expression of i-NOS, COX-2, ODC, and NF- κ B of skin

Cutaneous expression of the above mentioned proteins are shown in Figures 5-8, respectively. They show the epidermal cells of the papilloma with very good positive staining for having COX-2, ODC, i-NOS, and NF- κ B expression in Group II as compared to that of Group I. In Group III, showing the epidermal cells of the papilloma with very weak positive staining for having expression of NF- κ B, COX-2,

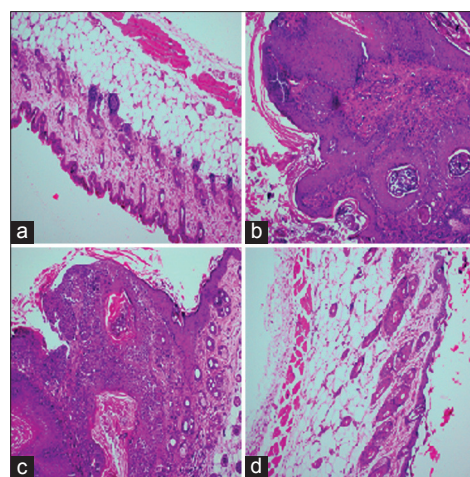


Figure 4: Effect of TC pretreatment on skin histological alterations caused by DMBA/croton oil application. (a) Skin of the acetone vehicle control group reflects normal skin architecture with no change in epidermis and dermis region. (b) Skin of the DMBA/croton oil-treated animals. There is marked swelling and thickening of the epidermis as compared to the control. (c) Skin of the animals pretreated with TC before DMBA/croton oil shows improved skin architecture as far as neutrophil infiltration and epidermal thickness is concerned. (d) Shows the skin of the group treated with dose of TC only with no significant change as compared to the control. Original magnification, $\times 10$

Table 2: Effect of TC on DMBA/croton oil-induced carcinogenesis in mice

Group	Body weight		No. of mice	No. of tumor bearing mice	Tumor incidence (%)	Cumulative number of papillomas
	Initial	Final				
I	27.13 \pm 0.07	35.40 \pm 0.09	10	0	0	Nil
II	26.29 \pm 0.11	46.03 \pm 0.16***	10	10	100	118
III	25.32 \pm 0.11	37.44 \pm 0.16###	10	4	40	21
IV	26.35 \pm 0.15	35.59 \pm 0.06	10	0	0	Nil

Values expressed as mean \pm SEM ($n=10$). Significance levels between vehicle group (group I) and DMBA/croton oil group (group II) at $P < 0.001$; significance levels between treated TC group (group IV) and DMBA/croton oil group (group II) at $P < 0.001$; significance levels between DMBA/croton oil group (group II) and DMBA/croton oil + treated TC group (group III) at $P < 0.001$. Tumor incidence (%) is expressed as the percentage of animals with one or more confirmed tumors. Tumor bearing mice; cumulative number of papillomas in these mice was treated with DMBA/croton oil and TC. SEM=Standard error of the mean, DMBA=7,12-dimethylbenz[a] anthracene, TC=*Terminalia chebula*. Significance between Group I and II is *** $P < 0.001$, Significance between Group II and IV is *** $P < 0.001$, Significance between Group III and IV is ### $P < 0.001$

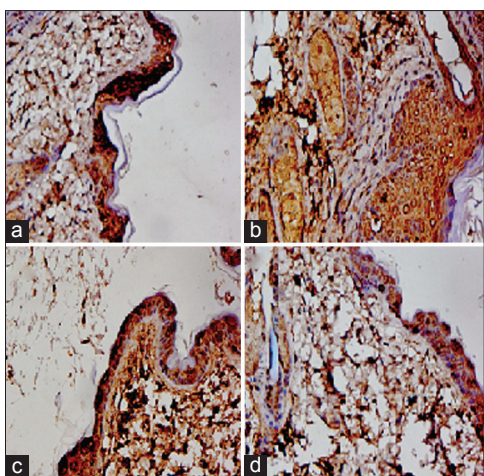


Figure 5: Effect of TC pretreatment on COX-2 expression. DMBA/croton oil-treated Group II has more COX-2 positive cells as compared to acetone-treated Group I (a and b). Pretreatment of TC in the Group III (DMBA/croton oil + TC; C) and TC-treated Group IV, (c and d) have less staining as compared to Group II. COX = Cyclooxygenase

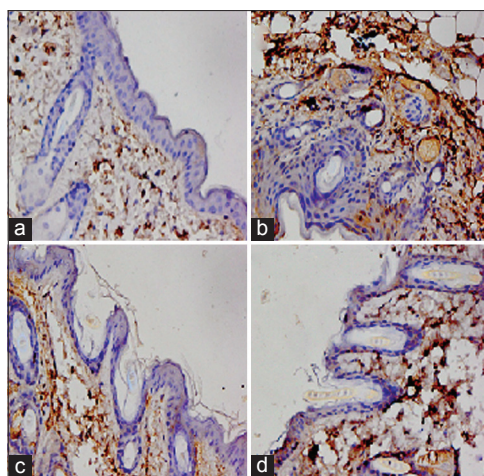


Figure 6: Effect of TC pretreatment on i-NOS expression. DMBA/croton oil-treated group II has more i-NOS positive cells as compared to acetone-treated Group I (a and b). Pretreatment of TC in Group III (DMBA/croton oil + TC; C) and TC-treated group IV (c and d) have less staining as compared to Group II. However, there was no significant difference in Groups I and IV (a and d) as far as staining is concerned. i-NOS = Inducible nitric oxide synthase

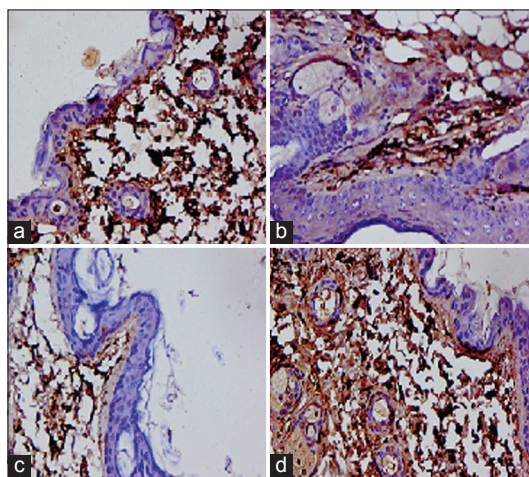


Figure 7: Effect of TC pretreatment on DMBA/ croton oil-induced cutaneous NF-κB expression. Representative photomicrographs (magnification: × 40), (a) only vehicle (Group I), (b) DMBA/croton oil (Group II), (c) TC + DMBA/croton oil (Group III), and (d) only TC Group IV). DMBA/croton oil-treated group (Group II) shows more NF-κB immunopositive cells as compared to vehicle-treated group (Group I). TC pretreatment (Group III) reduces NF-κB immunopositive cells as compared to Group II. However, there was no significant difference in the NF-κB immunostaining in Group IV as compared to Group I. NF-κB = nuclear factor-kappa B

and i-NOS and has less immunopositive cells with weak staining as compared to Group II.

DISCUSSION

The mice model of skin carcinogenesis represents one of the best means to study malignant transformation, including the multistage nature of tumor development and the molecular mechanism that contribute to the development

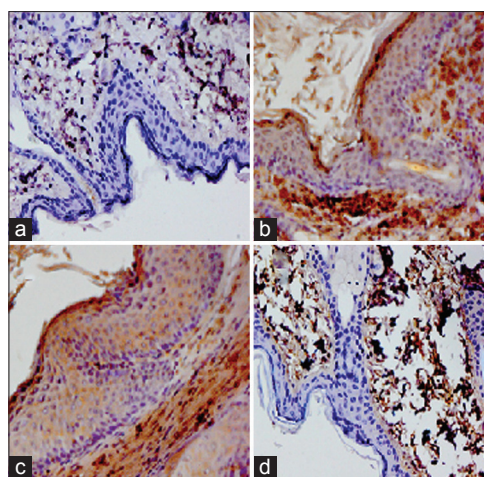


Figure 8: Effect of TC pretreatment on DMBA/croton oil-induced cutaneous ODC expression. Representative photomicrographs (magnification: ×40), (a) only vehicle (Group I), (b) DMBA/croton oil (Group II), (c) TC + DMBA/croton oil (Group III), and (d) only TC (Group IV). DMBA/croton oil-treated group (Group II) shows more ODC immunopositive cells as compared to vehicle-treated group (Group I). TC pretreatment (Group III) reduces ODC immunopositive cells as compared to Group II. However, there was no significant difference in the ODC immunostaining in Group IV as compared to Group I. ODC = Ornithine decarboxylase

of human epithelial cancers. It has been found to be a very good test system for investigating the influence of dietary and chemoprevention, both mechanistically and operationally.^[16]

TC has high phenolic content and strong biological activities, including anticancer, anti-LPO, and antioxidant activity.^[17,18] Further, evaluation of antitumorigenic potential of TC on DMBA-initiated and croton oil-promoted mouse

skin carcinogenesis showed that pretreatment with TC significantly prolongs the formation of tumors in skin and reduced the tumor incidence and cumulative number of papillomas. In this study, it has been reported that the attenuative effects of TC with reference to croton oil-induced inflammatory responses, which is critically associated with the promotion phase of cancer development and their mediators, are recognized as an important regulator of tumor promotion.

The results of the present study showed that TC inhibits DMBA and croton oil-induced cutaneous LPO. It is a major cellular macromolecules which leads to improper functioning of various inter- and intracellular signaling pathways and has critical association with the promotion stage of cancer development.^[19] The level of MDA had elevated after DMBA and croton oil topical administration. Pretreatment with TC reduced MDA formation which suggests the strong antitumor promotional potential of TC. Further, it was observed that TC also upregulates the levels and activities of the major endogenous antioxidants viz., GSH, catalase, GR, and GPx; and therefore, confirms its antioxidant potential.

The data of present study suggested that antioxidants and detoxifying enzymes play critical role in croton oil-induced early tumor promotional events and pretreatment with TC repressed the oxidative damages possibly by supporting endogenous antioxidant defense machinery via triggering their transcriptional upregulation, which is in accordance with previous findings. TC indirectly scavenges the oxygen free radicals, as evidenced by the activities of CAT, GPx, GR, GST, and levels of GSH and LPO.^[20] DMBA and croton oil-induced inflammatory responses (leukocytes infiltration, increase production of ROS, and hyperplasia) increased proinflammatory cytokines production and over expression of COX-2 and i-NOS, which are closely related with skin tumor promotion.^[21]

NF- κ B plays a critical role in regulation of cell survival genes and coordinates the expressions of proinflammatory enzymes and cytokines such as i-NOS, COX-2, ODC, and IL-6. Since the expressions of these proinflammatory mediators are modulated by NF- κ B. The chief molecular factors involved in inflammation are prostaglandins, cytokines, NF- κ B, chemokines, and angiogenic factors.^[22] These cytokines play critical roles in tumor growth and progression of tumor development. Chebulagic acid from TC showed potent inhibition activity against COX-2.^[23] The expression of i-NOS and COX-2 appear to be regulated by NF- κ B in mouse skin with DMBA and croton oil-induced cutaneous inflammation and observed several chemopreventive phytochemicals have been shown to inhibit COX-2 and i-NOS expression by blocking improper NF- κ B activation; and they are associated with cutaneous inflammation, cell proliferation, and skin tumor promotion.^[24]

Present study demonstrates that TC strongly suppress the activation of NF- κ B that might be mediated via inhibition of the phosphorylation or degradation of I κ B, as previous findings implicate that natural antioxidants inhibit NF- κ B activation by blocking modification of I κ B.^[25] NO and i-NOS show overexpression during inflammatory responses and are believed to be responsible for enhancing carcinogenesis and tumor progression, stimulation of angiogenesis, and promotion of metastasis.^[26] Thus, inhibition of i-NOS and NO may serve as anticancer target. TC inhibited DMBA/croton oil-induced inflammatory responses, such as leukocyte infiltration; proinflammatory cytokines production expression of COX-2, i-NOS, and ODC; and activation of NF- κ B.^[18]

IL-6 is an important proinflammatory agent and signaling messenger which plays the key role in promotion stage of carcinogenesis. Their role in production of growth factors, eicosanoids, NO, and activation of the NF- κ B is also well established.^[27] Increased production of IL-6 have been associated with promotion phase of skin carcinogenesis and was confirmed by the previous observation that mouse deficient in IL-6 is resistant to skin tumor formation.^[28] ROS play an important role in tumor initiation by enhancing or facilitating the metabolic activation and/or initiating effects of carcinogens and induction of epidermal ODC.^[17,29] Topically treated croton oil animals show enhanced ODC, a key enzyme in the polyamine synthesis pathway and is overexpressed in a variety of cancers.^[11] The present study showed that TC reduced ODC expression in DMBA and croton oil-treated mouse skin. In a recent study, topical exposure of TC prior to that of DMBA and croton oil resulted in a significant inhibition of DMBA and croton oil-mediated, and pretreatment with TC on ODC expression shows that it inhibits DMBA and croton oil-mediated induction of epidermal ODC.^[30] The ODC, i-NOS, and COX-2 proteins were highly expressed in mouse skin with hyperplasia, compared to mice treated with vehicle alone. The increased expression of these biomarkers was maintained during the development of papilloma with dysplasia. Histological examination of mouse skin after DMBA and croton oil application showed marked cellular anomalies like epidermal thickness, disorganization of epithelium, presence of necrotic cells, and focal proliferative area. Inflammatory cell infiltration of the dermis and intercellular edema in the epidermis were also observed. Similarly, hematoxylin and eosin stained sections showed pronounced preventive effects of TC on DMBA and croton oil-induced changes in animal's skin. They also found a decrease in tumor incidence, cumulative number of papillomas, and body weight. Further, the findings of the present study demonstrate that TC has strong antitumorigenic potential against DMBA-initiated and croton oil-promoted mouse skin tumorigenesis; and the underlying mechanism may involve inhibition of croton oil-induced inflammatory responses, hyperproliferation,

oxidative stress, and endogenous proinflammatory cytokines. Induction of various antioxidant enzymes also provides substantial evidence for the antitumorogenic potential of TC.

CONCLUSION

The findings of the present study showed that TC strongly suppressed cutaneous tumorigenesis via boosting of endogenous antioxidant defense system, inhibition of oxidative stress, and inflammation. Inhibition of COX-2 expression, i-NOS expression, and proinflammatory cytokine production activation of NF- κ B and ODC by TC provide the molecular basis of the antitumor promotional potential of TC. These findings suggest the strong anticarcinogenic potential of TC, and hence may serve as one of the important strategies for the prevention of skin cancer.

Acknowledgment

Dr. Sarwat Sultana is thankful to Ministry of Higher Education Republic of Iraq to provide fellowship to one of the authors (Ms. Ferial Majed) to carry out this research work at Jamia Hamdard (Hamdard University), New Delhi, India.

Financial support and sponsorship

Nil.

Conflicts of interest

There are no conflicts of interest.

REFERENCES

- Afaq F, Saleem M, Krueger CG, Reed JD, Mukhtar H. Anthocyanin and hydrolyzable tannin-rich pomegranate fruit extract modulates MAPK and NF- κ B pathways and inhibits skin tumorigenesis in CD-1mice. *Int J Cancer* 2005;113:423-33.
- DiGiovanni J. Modification of multistage skin carcinogenesis in mice. *Prog Exp Tumor Res* 1991;33:192-229.
- Dibyajyoti S, Milan H. An ontological design: Two stage mouse skin carcinogenesis induced by DMBA and promoted by croton oil. *Asian J Res Pharm Sci* 2012;2:1-3.
- Ha HY, Kim Y, Ryoo ZY, Kim TY. Inhibition of the TPA induced cutaneous inflammation and hyperplasia by EC-SOD. *Biochem Biophys Res Commun* 2006;348:450-8.
- Sharma S, Sultana S. Modulatory effect of soy isoflavones on biochemical alterations mediated by TPA in mouse skin model. *Food Chem Toxicol* 2004;42:1669-75.
- Balkwill F, Mantovani A. Inflammation and cancer: Back to Virchow? *Lancet* 2002;357:539-45.
- Lin WW, Karin MA. Cytokine-mediated link between innate immunity, inflammation and cancer. *J Clin Invest* 2007;117:1175-83.
- Finkel T, Holbrook NJ. Oxidants, oxidative stress and biology of ageing. *Nature* 2000;408:239-47.
- Reuter S, Gupta SC, Chaturvedi MM, Aggarwal BB. Oxidative stress, inflammation, and cancer: How are they linked? *Free Radic Biol Med* 2010;49:1603-16.
- Bicker DR, Athar M. Oxidative stress in the pathogenesis of skin disease. *J Invest Dermatol* 2006;126:2565-75.
- Tabib A, Bachrach U. Role of polyamines in mediating malignant transformation and oncogene expression. *Int J Biochem Cell Biol* 1999;31:1289-95.
- Karin M, Delhase M. The I kappa B kinase (IKK) and NF-kappa B: Key elements of proinflammatory signalling. *Semin Immunol* 2000;12:85-98.
- Pratibha S, Hema N, Raut A, Renuka S, Wagh A, Hemalata M, et al. Purification and characterization of an antioxidant protein (16 kDa) from *Terminalia chebula* fruit. *Food Chem* 2012;131:141-8.
- Saleem A, Husheem M, Harkonen P, Pihlaja K. Inhibition of cancer cell growth by crude extract and the phenolics of *Terminalia chebula* Retz fruit. *J Ethnopharmacol* 2002;81:327-36.
- Khan AQ, Khan R, Qamar W, Lateef A, Ali F, Tahir M, et al. Caffeic acid attenuates 12-O-tetradecanoyl-phorbol-13-acetate (TPA)-induced NF- κ B and COX-2 expression in mouse skin: Abrogation of oxidative stress, inflammatory responses and proinflammatory cytokine production. *Food Chem Toxicol* 2012;50:175-83.
- Kausar S, Schallreuter KU, Thody AJ, Gummer C, Tobin DJ. Regulation of human epidermal melanocyte biology by beta-endorphin. *J Invest Dermatol* 2003;120:1073-80.
- Bajpai M, Pande A, Tewari SK, Prakash D. Phenolic contents and antioxidant activity of some food and medicinal plants. *Int J Food Sci Nutr* 2005;56:287-91.
- Cheng HY, Lin TA, Yu KH, Yang CM, Lin CC. Antioxidant and free radical scavenging activities of *Terminalia chebula*. *Biol Pharm Bull* 2003;26:1331-5.
- Bartsch H, Nair J. Oxidative stress and lipid peroxidation-derived DNA lesions in inflammation driven carcinogenesis. *Cancer Detect Prev* 2004;28:385-91.
- Zhao J, Sharma Y, Agarwal R. Significant inhibition by the flavonoid antioxidant silymarin against 12-O-tetradecanoylphorbol-13-acetate-caused modulation of antioxidant and inflammatory enzymes, and cyclooxygenase-2 and interleukin-1alpha expression in SENCAR mouse epidermis: Implications in the prevention of stage I tumour promotion. *Mol Carcinog* 1999;26:321-33.
- DiGiovanni J. Multistage carcinogenesis in mouse skin. *Pharmacol Ther* 1992;54:63-128.
- Federico A, Morgillo F, Tuccillo C, Ciardiello F, Loguercio C. Chronic inflammation and oxidative stress in human carcinogenesis. *Int J Cancer* 2007;121:2381-6.
- Reddy DB, Reddy TC, Jyotsna G, Sharan S, Priya N, Lakshmi pathi V, et al. Chebulagic acid, a COX-LOX dual inhibitor isolated from the fruits of *Terminalia Chebula* Retz., induces apoptosis in COLO-205 cell line. *J Ethnopharmacol* 2009;124:506-12.
- Surh YJ, Chun KS, Cha HH, Han SS, Keum YS, Park KK, et al. Molecular mechanisms underlying chemopreventive activities of anti-inflammatory phytochemicals: Down-regulation of COX-2 and iNOS through suppression of NF- κ B activation. *Mutat Res* 2001;480-1:243-68.
- Surh YJ, Na HK. NF-kappa B and Nrf2 as prime molecular targets for chemoprevention and cytoprotection with anti-inflammatory and antioxidant phytochemicals. *Genes Nutr* 2008;2:313-7.

26. Thomas DD, Miranda KM, Colton CA, Citrin D, Espey MG, Wink DA. Heme proteins and nitric oxide (NO): The neglected, eloquent chemistry in NO redox signalling and regulation. *Antioxid Redox Signal* 2003;5:307-17.
27. Kundu JK, Surh YJ. Inflammation: Gearing the journey to cancer. *Mutat Res* 2003;659:15-30.
28. Vidal-Vanaclocha F, Fantuzzi G, Mendoza L, Fuentes AM, Anasagasti MJ, Martín J, *et al.* IL-18 regulates IL-1beta-dependent hepatic melanoma metastasis via vascular cell adhesion molecule-1. *Proc Natl Acad Sci USA* 2000;97:734-9.
29. Athar M. Oxidative stress and experimental carcinogenesis. *Indian J Exp Biol* 2002;40:656-67.
30. Feith DJ, Bol DK, Carboni JM, Lynch MJ, Sass-Kuhn S, Shoop PL, *et al.* Induction of ornithine decarboxylase activity is a necessary step for mitogen-activated protein kinase kinase-induced skin tumorigenesis. *Cancer Res* 2005;65:572-8.

Author Help: Online submission of the manuscripts

Articles can be submitted online from <http://www.journalonweb.com>. For online submission, the articles should be prepared in two files (first page file and article file). Images should be submitted separately.

1) **First Page File:**

Prepare the title page, covering letter, acknowledgement etc. using a word processor program. All information related to your identity should be included here. Use text/rtf/doc/pdf files. Do not zip the files.

2) **Article File:**

The main text of the article, beginning with the Abstract to References (including tables) should be in this file. Do not include any information (such as acknowledgement, your names in page headers etc.) in this file. Use text/rtf/doc/pdf files. Do not zip the files. Limit the file size to 1 MB. Do not incorporate images in the file. If file size is large, graphs can be submitted separately as images, without their being incorporated in the article file. This will reduce the size of the file.

3) **Images:**

Submit good quality color images. Each image should be less than 4096 kb (4 MB) in size. The size of the image can be reduced by decreasing the actual height and width of the images (keep up to about 6 inches and up to about 1800 x 1200 pixels). JPEG is the most suitable file format. The image quality should be good enough to judge the scientific value of the image. For the purpose of printing, always retain a good quality, high resolution image. This high resolution image should be sent to the editorial office at the time of sending a revised article.

4) **Legends:**

Legends for the figures/images should be included at the end of the article file.