

A Rare Case of Intestinal Taeniasis Presenting With Hematochezia and Iron Deficiency Anemia

Kyle Yuquimpo, DO¹, Sophia Warwick, MD¹, Christopher Koehn, MD², Brent Haurbaugh, DO³, Zelina Ardasenov, MD, PhD¹, and John A. Bonino, MD²

¹Department of Internal Medicine, University of Kansas Medical Center, Kansas City, KS

²Division of Gastroenterology, Hepatology, & Motility, University of Kansas Medical Center, Kansas City, KS

³Department of Pathology & Laboratory Medicine, University of Kansas Medical Center, Kansas City, KS

CASE REPORT

A 37-year-old male immigrant from Thailand presented to the emergency department with chest pain, fatigue, and hematochezia. Severe iron deficiency anemia was noted (Hgb 6 gm/dL, iron 11 μ g/dL, ferritin 2 ng/mL, total iron binding capacity (TIBC) 425 mcg/dL). Esophagogastroduodenoscopy with duodenal biopsies was unrevealing. Colonoscopy was remarkable for multiple, flat, ribbon-like structures (Figures 1 and 2). Specimens were collected for microscopic analysis and confirmed the structures to be *Taenia* proglottids (Figure 3). The patient had reported daily consumption of raw beef and pork before immigrating to the United States 10 years before his presentation. A single dose of praziquantel was provided with resolution of his symptoms and anemia at follow-up.

Visualization of proglottids during colonoscopy is extremely rare. A case report described *Taenia* proglottids identified during colon cancer screening in an asymptomatic patient.¹ Thailand is noted to have a high prevalence of taeniasis because of the fact that consumption of raw meats is a common practice in traditional cuisine.² The gold standard for diagnosis of *Taenia* is identification of proglottids or eggs on stool microscopy. In cases of iron deficiency anemia (IDA) with hematochezia, clinicians should consider appropriate stool testing for *Taenia* infection in patients presenting from countries where this infection is endemic.

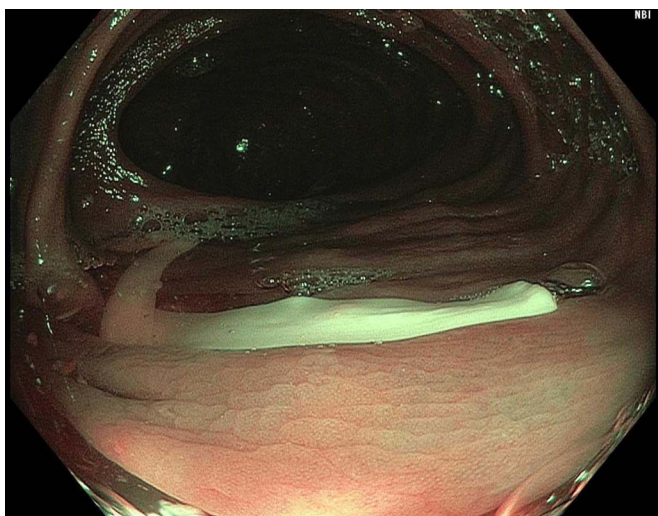


Figure 1. Multiple *Taenia* proglottids visualized on colonoscopy.

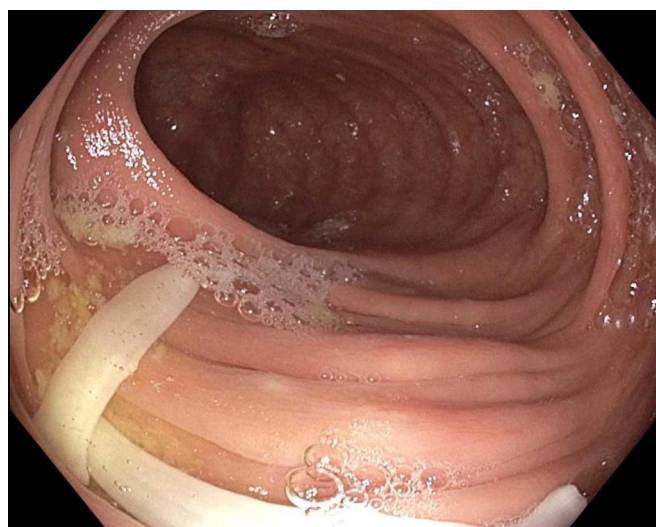


Figure 2. Multiple *Taenia* proglottids visualized on colonoscopy.

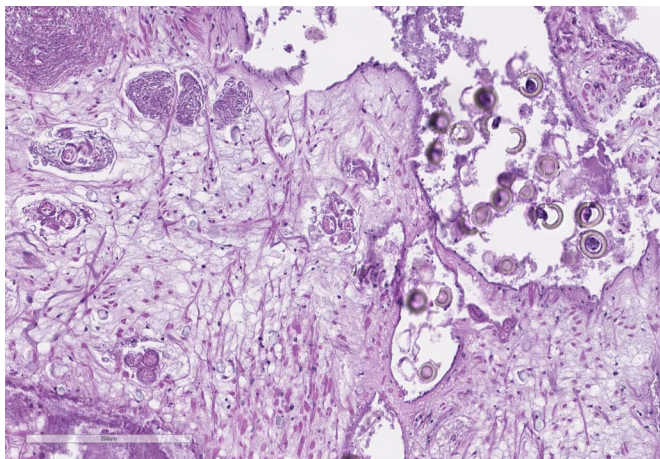


Figure 3. Microscopic analysis of biopsied proglottids using hematoxylin and eosin with identification of numerous eggs. Scale bar 200 μm .

DISCLOSURES

Author contributions: All authors contributed equally to the manuscript including data acquisition, interpretation, as well as

manuscript drafting, revision, and approval of the final manuscript. K. Yuquimpo is the author guarantor.

Financial disclosure: None to report.

Previous presentation: This case was presented at the 2021 ACG National Conference; October 22-27; Las Vegas.

Informed consent was obtained for this case report.

Received May 7, 2022; Accepted July 13, 2022

REFERENCES

1. Patel NM, Tatar EL. Unusual colonoscopy finding: *Taenia saginata* proglottid. *World J Gastroenterol.* 2007;13(41):5540-1.
2. Eichenberger RM, Thomas LF, Gabriel S, et al. Epidemiology of *Taenia saginata* taeniasis/cysticercosis: A systematic review of the distribution in East, Southeast and South Asia. *Parasit Vectors.* 2020;13(1):234.

Copyright: © 2022 The Author(s). Published by Wolters Kluwer Health, Inc. on behalf of The American College of Gastroenterology. This is an open access article distributed under the terms of the Creative Commons Attribution-Non Commercial-No Derivatives License 4.0 (CCBY-NC-ND), where it is permissible to download and share the work provided it is properly cited. The work cannot be changed in any way or used commercially without permission from the journal.