

Received: 2016.06.09  
Accepted: 2016.08.25  
Published: 2017.03.30

# Expression of Adiponectin Receptor-1 and Prognosis of Epithelial Ovarian Cancer Patients

Authors' Contribution:  
Study Design A  
Data Collection B  
Statistical Analysis C  
Data Interpretation D  
Manuscript Preparation E  
Literature Search F  
Funds Collection G

B **Xiahui Li\***  
CD **Zhe Yu\***  
DF **Liping Fang**  
EF **Fang Liu**  
AE **Kui Jiang**

Department of Oncology, The 2<sup>nd</sup> Affiliated Hospital of Dalian Medical University, Dalian, Liaoning, P.R. China

\* Co-first author

**Corresponding Author:** Kui Jiang, e-mail: kuijiang501@sina.com  
**Source of support:** Departmental sources

**Background:** Adiponectin receptor-1 (AdipoR1) has been reported to be associated with the risk of obesity-associated malignancies, including epithelial ovarian cancer (EOC). The aim of this study was to determine if AdipoR1 could serve as a prognosis indicator for patients with EOC.

**Material/Methods:** In this study, expression of AdipoR1 in 73 EOC patients consecutively admitted to our hospital was detected by immunohistochemical staining. Univariate and multivariate analyses were performed to assess the relationship between AdipoR1 expression level and progression-free survival (PFS) and overall survival (OS) rates in patients.

**Results:** A relatively lower expression of AdipoR1 in the cancerous tissues was detected compared to normal ovarian tissues, but the difference was not significant ( $p>0.05$ ). AdipoR1 expression level in EOC patients was negatively correlated with advanced FIGO stages in patients and tumor differentiation, but had no correlation with pathological types, presenting of ascites, shorter platinum-free interval (PFI), diabetes, preoperative and post-operative body mass index (BMI), or platelet counts ( $p>0.05$ ). Moreover, patients with AdipoR1 expression had a significantly longer PFS and OS compared to the negative expression group ( $p<0.001$ ).

**Conclusions:** Our findings suggest that AdipoR1 expression level in cancerous tissues might serve as an independent prognostic indicator in EOC patients and is associated with longer PFS and OS.

**MeSH Keywords:** **Adiponectin • Ovarian Neoplasms • Receptors, Adiponectin**

**Full-text PDF:** <http://www.medscimonit.com/abstract/index/idArt/899990>

 2167

 6

 3

 35



## Background

Ovarian cancer is the most lethal gynecologic malignancy among women, with an estimated 150 000 annual deaths worldwide [1]. However, due to the unspecific and inconspicuous symptoms in the early stage of ovarian cancer, there are no effective and accurate detection methods for this disease [2]. Moreover, although the initial response to surgical resection and platinum-based chemotherapy is relatively high, most patients still have recurrence and chemo-resistance to ovarian cancer [3]. As a result, diagnosis of most ovarian cancer cases occurs at advanced stages, which is associated with poor prognosis, as shown by the low 5-year overall survival rate [4]. Therefore, there is an urgent need for further investigation of potential markers for prognosis [5], mechanisms of ovarian carcinogenesis [6], and therapeutic targets for novel alternative treatments [7].

Accumulating evidence indicates that obesity is correlated with occurrence of ovarian cancer [8]. Obesity provides a unique adipose tissue microenvironment in which several cytokines, including adiponectin, are secreted exclusively by differentiated adipocytes [9]. Adiponectin is a 25-kDa adipocytokine composed of 244 amino acids and involved in insulin sensitivity and lipid metabolism [10]. In adults, the serum adiponectin level rises with decreased body fat percentage [10].

Recently, adiponectin has been reported to act as anti-tumor factor through inhibiting cancer cell growth, proliferation, and migration, as well as promoting apoptosis [11–13]. Binding its receptors by adiponectin could activate a variety downstream signaling pathways, such as 5'-AMP-activated protein kinase (AMPK) and Wnt signaling [14,15]. On the other hand, recent studies reported that AdipoR1 is positively correlated with the risk of obesity-associated malignancies such as endometrial, pancreatic, renal, colon, and breast carcinomas [16–19]. However, little is known about expression of AdipoR1 in epithelial ovarian cancer (EOC) and its pathological implications.

In this study, we analyzed the expression of AdipoR1 in human cancerous epithelial ovarian tissues by immunohistochemical assay. The pathological features, progression-free survival (PFS), and overall survival (OS) were further analyzed to investigate the relationship between AdipoR1 expression and prognostic outcomes of patients with EOC.

## Material and Methods

### Ethics statement and general information on patients

This was a retrospective study enrolled 73 patients diagnosed with EOC in the Second Affiliated Hospital, Dalian Medical

University from July 2008 to December 2014. All patients were consecutive admitted to our hospital. The protocol of this study was approved by the hospital Ethics Committee. All participating patients were formally informed for the purpose of this study and a letter of consent was signed by every individual involved.

All patients had been confirmed to have EOC and had received 4–6 rounds of postoperative platinum-based chemotherapy according to NCCN guidelines. Patients' ages ranged from 26 to 77 years, and the average age was  $59.96 \pm 10.19$  years. Among all patients, 67 (91.78%) had serous adenocarcinoma, 3 (4.11%) had endometrioid adenocarcinoma, 2 (2.73%) had clear cell adenocarcinoma, and 2 (2.73%) had mucous adenocarcinoma. The 73 EOC patients were divided into 2 groups: the Low-to-Medium Differentiation Group (28 with low differentiation and 29 with low-to-medium differentiation) and the Medium-to-High Differentiation Group (14 with medium differentiation, 1 with medium-to-high differentiation, and 1 with high differentiation).

### Immunohistochemical staining

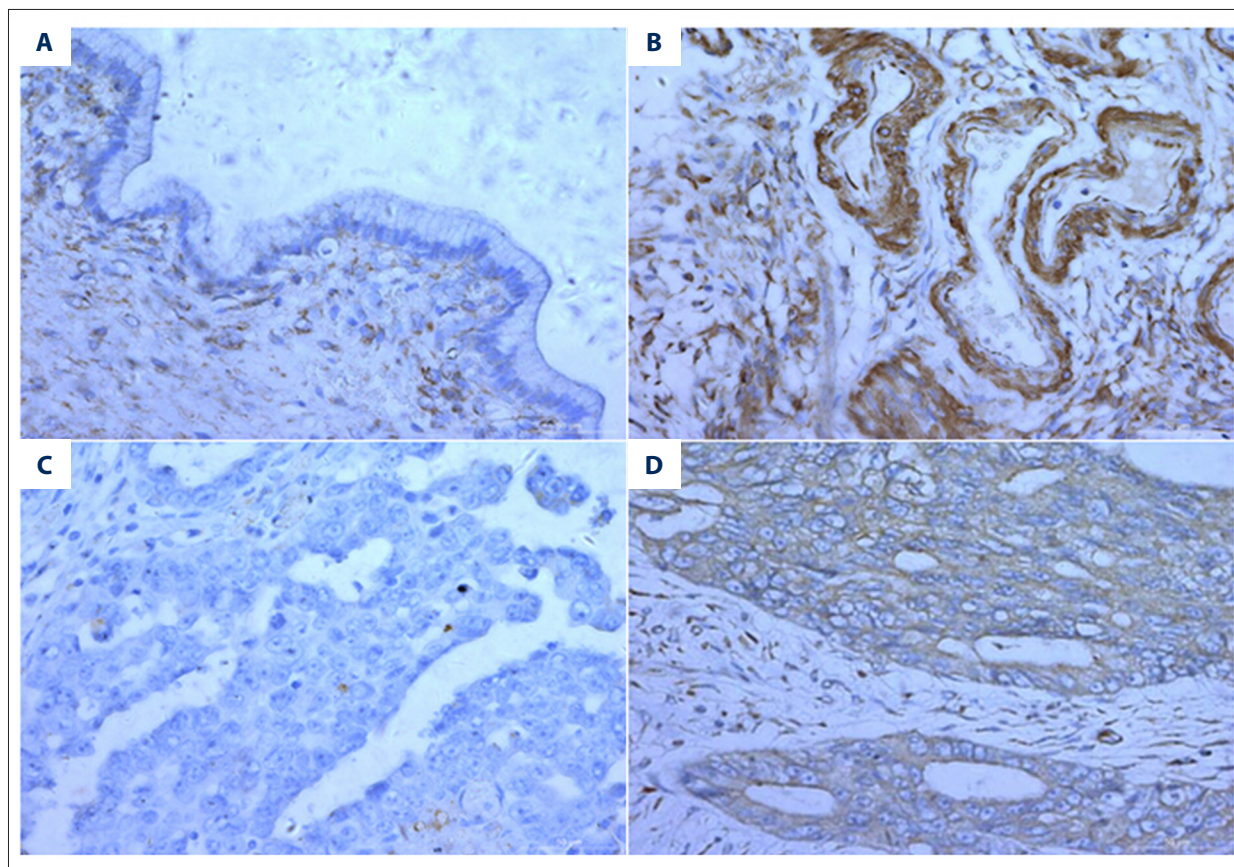
The expression level of AdipoR1 in ovarian cancer tissues was analyzed by immunohistochemical staining. All surgically obtained specimens were preserved in the Pathology Center of the Second Affiliated Hospital, Dalian Medical University for further analysis. We included 15 normal ovarian tissue samples from healthy individuals as controls. Samples were fixed in formalin, embedded in paraffin, and cut into 4- $\mu$ m sections. For antigen retrieval, tissue sections were treated in a microwave oven with citrate buffer solution (pH 6.0) for 20 min and blocked with normal goat serum for 1 h. After rinsing in PBS 3 times, the slides were incubated for 1 h with anti-human AdipoR1 antibody (ab126611, 1: 100; Abcam, Cambridge, UK) as the primary antibody. A HRP-conjugated goat anti-rabbit IgG H&L (ab6721, 1: 500; Abcam, Cambridge, UK) was used as the secondary antibody. The sections were then immersed in running water and hematoxylin was used for counterstaining.

### Analysis of immunohistochemical staining

All immunohistochemical-stained slides were independently evaluated by 2 pathologists who were blinded to the patients' medical records. Positivity of the samples was determined by the presence of brown or tan staining within the cytoplasmic membrane and/or cytoplasm. Sections that contained more than 5% stained cells were considered as AdipoR1-positive samples, otherwise slides were considered as negative samples. For the semi-quantitative analysis of immunohistochemical staining for AdipoR1 expression, a H-score based analysis was conducted, as previously described [20].

**Table 1.** Frequency of AdipoR1 expression in tissues from normal ovarium and EOC.

Groups	Number of cases	AdipoR1		$\chi^2$	P value
		Positive (n, %)	Negative (n, %)		
Normal ovarian tissue	15	11 (73.33%)	4 (26.67%)	0.002	0.966
Epithelial ovarian carcinoma	73	51 (69.86%)	22 (30.14%)		



**Figure 1.** Expression AdipoR1 in in normal ovarian tissues and cancerous tissues. Representative images of negative AdipoR1 immunohistochemical staining in normal ovarian tissues (A) and cancerous tissues (C). Representative positive-staining images were demonstrated in normal ovarian tissues (B) and cancerous (D) tissues. The original magnification was  $\times 400$ .

**Statistical analysis**

All statistical analyses were performed using the SPSS 13.0 software package (SPSS Inc., Chicago, IL). Correlations were analyzed using 2 independent-samples nonparametric tests. The survival data were analyzed using Kaplan-Meier survival curves. For multivariate analysis, Cox proportional hazards regression modeling was performed. The results were considered statistically significant when P value was  $<0.05$ .

**Result**

**AdipoR1 expression in cancerous ovarian tissues**

Out of the 15 normal ovarian tissue samples, AdipoR1 expression was observed in 11 samples (73.33%). In the 73 EOC patients, the expression of AdipoR1 was detected in 51 (69.86%). The frequency of AdipoR1 expression in normal ovarian tissues was higher than in EOC tissues; however, no significant difference between the 2 groups was observed ( $p=0.966$ ) (Table 1, Figure 1). Pathologic features of patients are summarized in Table 1.

**Table 2.** Correlation analysis of AdipoR1 expression and pathologic features in patients with EOC.

		Number of cases (n)	H-Score AdipoR1 expression	T value	P value
FIGO stage	Stage I~II	16	236.25±62.28	5.835	0.046*
	Stage III~IV	57	119.21±95.50		
Pathological type	Serous carcinoma	66	143.56±102.93	0.335	0.543
	Others	7	157.14±91.42		
Differentiation degree	Low to medium	57	130.26±89.94	2.002	0.023*
	Medium to high	16	196.88±124.24		
Ascites	Yes	39	110.13±98.61	3.350	0.697
	No	34	184.71±90.36		
Diabetes	Yes	14	90.71±82.51	2.287	0.121
	No	59	157.71±101.77		
Preoperative BMI (kg/m <sup>2</sup> )	≥24	37	138.65±96.99	0.528	0.246
	<24	36	151.25±106.70		
Postoperative BMI (kg/m <sup>2</sup> )	≥24	31	154.19±112.78	0.673	0.070
	<24	42	137.98±92.89		
Platelet count (×10 <sup>9</sup> /L)	≥350	34	138.68±100.67	0.484	0.460
	<350	39	150.26±102.99		
Platinum-free interval (month)	>6	46	184.35±93.61	5.021	0.246
	≤6	27	77.59±76.40		

Significant difference was marked as “\*” which means  $P < 0.05$

### Correlation between AdipoR1 expression and clinicopathological features

Two independent-samples nonparametric tests indicated that expression of AdipoR1 was negatively correlated with patient classification as being in the terminal stage of disease according to the International Federation of Gynecology and Obstetrics (FIGO) stages and degree of differentiation of ovarian tissue ( $p < 0.05$ ). However, AdipoR1 expression was not significantly associated with other pathologic features, including pathological types, ascites during initial manifestation, diabetes, preoperative or postoperative body mass index (BMI), platelet count, or PFI of less than 6 months (Table 2).

### Correlation between AdipoR1 expression and progression-free survival (PFS)

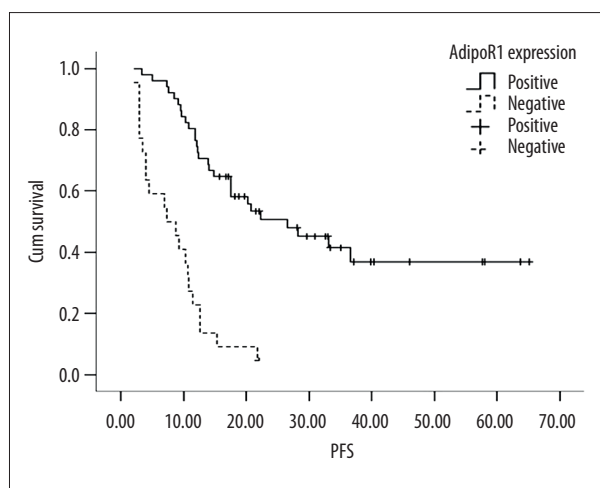
Univariate analysis indicated the median PFS of patients with positive expression of AdipoR1 was significantly higher than in patients with AdipoR1-negative expression (26.6 months vs. 7.4 months,  $p < 0.001$ ). The median PFS of patients within Stage

I to II and Stage III to IV was 31.0 months and 12.1 months, respectively, and the difference was statistically significant ( $p < 0.001$ ). Moreover, significant differences were observed in median PFS of patients with vs. without ascites (10.3 months vs. 33.2 months,  $p < 0.001$ ), presenting of diabetes (10.3 months in the diabetes group vs. 17.6 months in the non-diabetes group,  $p = 0.019$ ), and platelet count (11.9 months in patients with platelet count higher than  $350 \times 10^9/L$  vs. 26.6 months in patients with platelet count less than  $350 \times 10^9/L$ ,  $p = 0.026$ ). Other clinicopathological features, including different pathological types, tissue differentiation degree, and preoperative and postoperative BMI, were not associated with PFS in univariate analysis ( $p > 0.05$ , all) (Table 3, Figure 2).

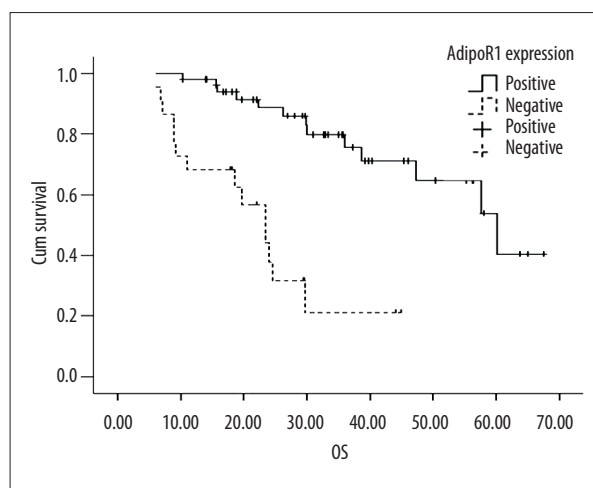
Cox proportional hazards regression modeling was used to evaluate the effects of various clinicopathological characteristics, including AdipoR1 expression, FIGO stage, ascites, diabetes, and platelet count on PFS of patients with EOC. The multivariate analyses identified AdipoR1 expression as an independent positive prognostic indicator of PFS. Other pathologic features, such as FIGO stages and ascites, also had a significant effect on PFS (Table 4).

**Table 3.** Univariate analysis for progression free survival of patients with EOC.

		Median PFS (months)	Chi-square value	P value
AdipoR1 expression	Positive	26.6	32.862	0.000
	Negative	7.4		
FIGO stage	Stage I-II	31.0	16.690	0.000
	Stage III-IV	12.1		
Pathological type	Serous carcinoma	14.1	0.556	0.456
	Other	33.2		
Differentiation degree	Low to medium	17.5	0.018	0.893
	Medium to high	10.8		
Ascites	Yes	10.3	17.065	0.000
	No	33.2		
Diabetes	Yes	10.3	5.502	0.019
	No	17.6		
Preoperative BMI (kg/m <sup>2</sup> )	≥24	20.3	0.657	0.418
	<24	12.6		
Postoperative BMI (kg/m <sup>2</sup> )	≥24	21.8	2.408	0.121
	<24	12.4		
Platelet count (×10 <sup>9</sup> /L)	≥350	11.9	4.963	0.026
	<350	26.6		



**Figure 2.** Survival curves for patients with EOC according to AdipoR1 expression. The progression-free survival of patients with AdipoR1 positivity was significantly longer than in the negative expression group.



**Figure 3.** Survival curves for patients with EOC according to AdipoR1 expression. The overall survival of patients with AdipoR1 positivity was significantly longer than in the negative expression group.

**Table 4.** Multivariate cox regression analysis of progression free survival of patients with EOC.

	PRC	SE	chi-square value	Variance	P value	OR value	95% CI	
							Lower limit	Upper limit
AdipoR1expression	-1.319	0.336	15.406	1	0.000	0.267	0.138	0.517
FIGO stage	-1.435	0.621	5.336	1	0.021	0.238	0.070	0.805
Ascites	-0.804	0.327	6.030	1	0.014	0.448	0.236	0.850
Diabetes	-0.445	0.376	1.406	1	0.236	0.641	0.307	1.337
Platelet count	0.052	0.316	0.027	1	0.869	1.053	0.567	1.956

**Table 5.** Univariate analysis for overall survival of patients with EOC.

		Median OS (month)	Chi-square value	P value
AdipoR1 expression	Positive	60.2	22.327	0.000
	Negative	23.5		
FIGO stage	Stage I~II	60.2	4.320	0.038
	Stage III~IV	38.7		
Pathological type	Serous carcinoma	25.4	3.430	0.064
	Other	45.0		
Differentiation degree	Low to medium	27.7	0.311	0.577
	Medium to high	29.9		
Ascites	Yes	29.7	6.579	0.010
	No	60.2		
Diabetes	Yes	29.7	5.212	0.022
	No	57.7		
Preoperative BMI (kg/m <sup>2</sup> )	≥24	60.2	0.729	0.393
	<24	38.7		
Postoperative BMI (kg/m <sup>2</sup> )	≥24	60.2	3.164	0.075
	<24	36.0		
Platelet count (×10 <sup>9</sup> /L)	≥350	47.3	0.606	0.436
	<350	57.7		

**Table 6.** Multivariate cox regression analysis of overall survival of patients with EOC.

	PRC	SE	chi-square value	Variance	P value	OR value	95% CI	
							Lower limit	Upper limit
AdipoR1expression	-1.614	0.471	11.735	1	0.001	0.199	0.079	0.501
FIGO stage	-0.431	0.664	0.442	1	0.516	0.650	0.177	2.389
Ascites	-0.761	0.449	2.870	1	0.090	0.467	0.194	1.127
Diabetes	-0.074	0.498	0.022	1	0.882	0.929	0.350	2.463

### Correlation between AdipoR1 expression and overall survival (OS)

Our data indicated that AdipoR1 expression, FIGO stage, ascites, and diabetes were correlated with OS of EOC patients (Table 5). The median OS of AdipoR1-positive EOC patients was 60.2 months, which was significantly higher than the 23.5 months found in the AdipoR1-negative group ( $p < 0.001$ ). Moreover, the median OS of patients with ascites as initial manifestation was 29.7 months, which was significantly shorter than in patients without ascites (60.2 months). Furthermore, presenting of diabetes also reduced the OS from 57.7 months to 29.7 months ( $p = 0.022$ ). However, other clinicopathological variables, including different pathological types, tissue differentiation degree, preoperative and postoperative BMI, and platelet count, had no correlation with OS of patients with EOC in univariate analysis ( $p > 0.05$ , all) (Figure 3, Table 6). Taken together, the multivariate analyses revealed that AdipoR1 expression could be an independent positive prognostic indicator of OS of EOC patients (Table 6).

### Discussion

Obesity is currently regarded as a risk factor for ovarian cancer, but it is still unclear how obesity contributes to ovarian carcinogenesis. Adiponectin, a protein hormone that regulates many metabolic processes, has been recently reported to be a crucial mediator during the progression of several malignancies associated with obesity, and adiponectin receptor 1 (AdipoR1) expression in several cancers has been found to be associated with favorable prognosis for patients.

Recent studies showed that AdipoR1 was detected in both cancerous and normal tissues. However, the role of AdipoR1 in carcinogenesis is controversial because expression level of AdipoR1 varies greatly among different cancers. Compared to normal tissue samples, there was a significant increase in the expression of AdipoR1 in pancreatic cancer and oesophageal adenocarcinoma [17,21]; in contrast, the percentage of AdipoR1-positive cells was significantly lower in endometrial carcinoma. Moreover, in a recent study, the mRNA levels of adiponectin and AdipoR1 were significantly lower in cancerous ovaries than in normal ovaries [22], which is consistent with our observation.

In our study, AdipoR1 immunostaining tended to be less intense in cancerous epithelial ovarian tissues compared with normal ovarian tissue, but the difference was not significant, suggesting that AdipoR1 is involved in the carcinogenesis and progression of ovarian cancer. A previous report suggested that adiponectin and its receptors can decrease neoplasm metastasis and repress angiogenesis through activation of mitogen-activated

protein kinase (MAPK) [23]. An *in vitro* study based on 6 gastric cancer cell lines showed that adiponectin treatment can induce apoptosis and inhibit the proliferation of gastric cancer cell lines [24]. Moreover, siRNA knock-down of AdipoR1 suppressed the growth inhibitory effects of adiponectin in gastric cancer cell lines [24]. Taken together, these data show the potential role AdipoR1 plays in the development and prognosis of cancer, which may also apply to ovarian carcinogenesis.

Tiwari et al. reported that the expression of adiponectin and AdipoR1 was detectable in EOC tissues and ovarian cancer-derived cell lines [22]. To investigate the relationship between AdipoR1 and ovarian cancer, we evaluated the correlation between AdipoR1 expression and clinicopathological features in ovarian cancer patients. Advance FIGO stage, ascites, and short platinum-free intervals were confirmed to be correlated with AdipoR1 expression in EOC patients. A retrospective study revealed that FIGO stage is one of the most reliable predictors of the prognosis of patients with EOC [25]. Our data showed that AdipoR1-positive staining in EOC tissues was negatively correlated with advanced FIGO stage in EOC patients, which is in agreement with previous reports. Moreover, data from colorectal cancer also showed that AdipoR1 expression was negatively associated with tumor grade [26], and patients with negative expression of AdipoR1 were shown to be more prone to occurrence of extrathyroidal invasion and multicentricity in thyroid cancer [27].

Presentation of ascites is frequently associated with carcinogenesis of ovarian cancer at the end-stage of disease, and affects the progression of neoangiogenesis [28,29]. However, we found no correlation between AdipoR1 expression and ascites in our study, indicating that expression of AdipoR1 is of great importance in delaying carcinogenesis in EOC patients. However, the details of the mechanisms involved need further investigation in larger prospective studies.

Recent studies indicated that AdipoR1-positive expression significantly contributed to improvement of prognosis in different cancers [30–32]. Accordingly, AdipoR1 was proposed as a potential quantitative biomarker for clinical outcomes of EOC patients. Moreover, due to the important role AdipoR1 plays in mediating the carcinogenesis and progression of EOC, it might be as a promising anti-tumor therapeutic target. More detailed research on the cellular and molecular functions of AdipoR1 in EOC is needed. Moreover, in survival analysis, EOC patients with AdipoR1-positive expression had significantly longer survival than those with AdipoR1-negative expression. Accumulating data demonstrate that PFI is a reliable predictor of response and survival after platinum-based chemotherapy for patients with recurrent carcinomas [33,34]. Patients with more than 12 months of PFI had significantly longer PFS and OS compared to patients with less than 6 months of PFI.

However, no significant correlation between AdipoR1 expression and PFI was observed in patients in our study. On the other hand, the enrolled patients had disproportional representation of cancer types and FIGO stages: there were fewer cases of low-to-medium vs. medium-to-high differentiation and FIGO stages I-II vs. III-IV cases, which is a limitation of our study. It was reported that epithelial ovarian cancers account for 85–90% of ovarian cancers, with a subset of epithelial ovarian cancers and high-grade serous ovarian cancers (HGSOs) representing nearly 70% of all ovarian cancer cases [35]. Moreover, most patients are not diagnosed until the disease is at an advanced stage [2]. Therefore, there were more serous ovarian cancers and FIGO III-IV cases in our study. To further confirm our observation, a large-scale investigation

with equal distribution of cases based on differentiation and FIGO stage is needed.

## Conclusions

Our study results suggest that the expression of AdipoR1 is an independent prognostic indicator in patients with EOC and is associated with longer PFS and OS. EOC patients with AdipoR1-positive expression had longer survival than AdipoR1-negative patients.

## Conflict of interest

None.

## References:

1. Torre LA, Bray F, Siegel RL et al: Global cancer statistics, 2012. *Cancer J Clin*, 2015; 65: 87–108
2. Otsuka I, Kameda S, Hoshi K: Early detection of ovarian and fallopian tube cancer by examination of cytological samples from the endometrial cavity. *Br J Cancer*, 2013; 109: 603–9
3. Husseinzadeh N, Husseinzadeh HD: mTOR inhibitors and their clinical application in cervical, endometrial and ovarian cancers: A critical review. *Gynecol Oncol*, 2014; 133: 375–81
4. Mirandola L, J Cannon M, Cobos E et al: Cancer testis antigens: Novel biomarkers and targetable proteins for ovarian cancer. *Int Rev Immunol* 2011; 30: 127–37
5. Tang MK, Wong AS: Exosomes: Emerging biomarkers and targets for ovarian cancer. *Cancer Lett*, 2015; 367: 26–33
6. Lozneau L, Cojocar E, Giusca SE et al: Lesser-known molecules in ovarian carcinogenesis. *Biomed Res Int*, 2015; 2015: 321740
7. Matsuzaki S, Yoshino K, Ueda Y et al: Potential targets for ovarian clear cell carcinoma: a review of updates and future perspectives. *Cancer Cell Int*, 2015; 15: 117
8. Nagle CM, Dixon SC, Jensen A et al: Obesity and survival among women with ovarian cancer: Results from the Ovarian Cancer Association Consortium. *Br J Cancer*, 2015; 113: 817–26
9. Park J, Morley TS, Kim M et al: Obesity and cancer – mechanisms underlying tumour progression and recurrence. *Nat Rev Endocrinol*, 2014; 10: 455–65
10. Hajer GR, van Haeften TW, Visseren FL: Adipose tissue dysfunction in obesity, diabetes, and vascular diseases. *Eur Heart J*, 2008; 29: 2959–71
11. Tan PH, Tyrrell HE, Gao L et al: Adiponectin receptor signaling on dendritic cells blunts antitumor immunity. *Cancer Res*, 2014; 74: 5711–22
12. Gao Q, Zheng J: Adiponectin-induced antitumor activity on prostatic cancers through inhibiting proliferation. *Cell Biochem Biophys*, 2014; 70: 461–65
13. Dieudonne MN, Bussiere M, Dos Santos E et al: Adiponectin mediates anti-proliferative and apoptotic responses in human MCF7 breast cancer cells. *Biochem Biophys Res Commun*, 2006; 345: 271–79
14. Luo Z, Saha AK, Xiang X, Ruderman NB: AMPK, the metabolic syndrome and cancer. *Trends Pharmacol Sci*, 2005; 26: 69–76
15. Ford CE, Henry C, Llamas E et al: Wnt signalling in gynaecological cancers: A future target for personalised medicine? *Gynecol Oncol*, 2016; 140: 345–51
16. Nagaraju GP, Rajitha B, Aliya S et al: The role of adiponectin in obesity-associated female-specific carcinogenesis. *Cytokine Growth Factor Rev*, 2016 [Epub ahead of print]
17. Dalamaga M, Migdalis I, Fargnoli JL et al: Pancreatic cancer expresses adiponectin receptors and is associated with hypoleptinemia and hyperadiponectinemia: A case-control study. *Cancer Causes Control*, 2009; 20: 625–33
18. Dalamaga M, Diakopoulos KN, Mantzoros CS: The role of adiponectin in cancer: A review of current evidence. *Endocr Rev*, 2012; 33: 547–94
19. Byeon JS, Jeong JY, Kim MJ et al: Adiponectin and adiponectin receptor in relation to colorectal cancer progression. *Int J Cancer*, 2010; 127: 2758–67
20. Romani AA, Soliani P, Desenzani S et al: The associated expression of Masp1 and Bax proteins as a potential prognostic factor in intrahepatic cholangiocarcinoma. *BMC Cancer*, 2006; 6: 255
21. Ogunwobi OO, Beales IL: Globular adiponectin, acting via adiponectin receptor-1, inhibits leptin-stimulated oesophageal adenocarcinoma cell proliferation. *Mol Cell Endocrinol*, 2008; 285: 43–50
22. Tiwari A, Ocon-Grove OM, Hadley JA et al: Expression of adiponectin and its receptors is altered in epithelial ovarian tumors and ascites-derived ovarian cancer cell lines. *Int J Gynecol Cancer*, 2015; 25: 399–406
23. Hebbard L, Ranscht B: Multifaceted roles of adiponectin in cancer. *Best Pract Res Clin Endocrinol Metab*, 2014; 28: 59–69
24. Ishikawa M, Kitayama J, Yamauchi T et al: Adiponectin inhibits the growth and peritoneal metastasis of gastric cancer through its specific membrane receptors AdipoR1 and AdipoR2. *Cancer Sci*, 2007; 98: 1120–27
25. Fu Y, Wang X, Pan Z, Xie X: Clinical outcomes and prognostic factors of patients with epithelial ovarian cancer subjected to first-line treatment: A retrospective study of 251 cases. *Front Med*, 2014; 8: 91–95
26. Sakellariou S, Fragkou P, Levidou G et al: Clinical significance of AGE-RAGE axis in colorectal cancer: Associations with glyoxalase-I, adiponectin receptor expression and prognosis. *BMC Cancer*, 2016; 16: 174
27. Cheng SP, Liu CL, Hsu YC et al: Expression and biologic significance of adiponectin receptors in papillary thyroid carcinoma. *Cell Biochem Biophys*, 2013; 65: 203–10
28. Saada E, Follana P, Peyrade F et al: [Pathogenesis and management of refractory malignant ascites]. *Bull Cancer*, 2011; 98: 679–87 [in French]
29. Sangisetty SL, Miner TJ: Malignant ascites: A review of prognostic factors, pathophysiology and therapeutic measures. *World J Gastrointest Surg*, 2012; 4: 87–95
30. Tsukada T, Fushida S, Harada S et al: Adiponectin receptor-1 expression is associated with good prognosis in gastric cancer. *J Exp Clin Cancer Res*, 2011; 30: 107
31. Shin E, Yu YD, Kim DS, Won NH: Adiponectin receptor expression predicts favorable prognosis in cases of hepatocellular carcinoma. *Pathol Oncol Res*, 2014; 20: 667–75
32. Abdul-Ghafar J, Oh SS, Park SM et al: Expression of adiponectin receptor 1 is indicative of favorable prognosis in non-small cell lung carcinoma. *Tohoku J Exp Med*, 2013; 229: 153–62
33. Nagao S, Nishio S, Michimae H et al: Applicability of the concept of “platinum sensitivity” to recurrent endometrial cancer: The SGSG-012/GOTIC-004/Intergroup study. *Gynecol Oncol*, 2013; 131: 567–73
34. Takekuma M, Kuji S, Tanaka A et al: Platinum sensitivity and non-cross-resistance of cisplatin analogue with cisplatin in recurrent cervical cancer. *J Gynecol Oncol*, 2015; 26: 185–92
35. Botesteanu DA, Lee JM, Levy D: Modeling the dynamics of high-grade serous ovarian cancer progression for transvaginal ultrasound-based screening and early detection. *PLoS One*, 2016; 11: e0156661