

Available online at [www.sciencedirect.com](http://www.sciencedirect.com)

ScienceDirect

journal homepage: [www.e-jds.com](http://www.e-jds.com)

## Correspondence

# Combination of restoration with root coverage procedure at non-carious cervical lesions with gingival recession: A case report



Excessive toothbrushing may cause gingival recession, and root abrasion may occur as the roots become exposed. The above episode results in non-carious cervical lesions (NCCLs). At the same time, cervical dentin hypersensitivity often occurs with root dentin defect and is accompanied by tooth pain arising from root exposure.

The classical operation of root coverage procedure is subepithelial connective tissue graft. However, the subepithelial connective tissue graft at sites with both gingival recession and NCCLs will encounter the following complications: a deep enamel/root discrepancy between the connective tissue graft and the dentin will lead to poor stabilization of the graft and affect the prognosis of root coverage;<sup>1</sup> root coverage alone is limited in resolving cervical dentin hypersensitivity that results from NCCLs. The combination of restoration with subepithelial connective tissue graft not only restores esthetics but also decreases cervical dentin hypersensitivity. However, previous literature pointed out doubts regarding the filling material being able to cause damage to the graft and cause an unhealthy gingiva situation.

A 40-year-old male patient presented with Miller's class I gingival recession associated with composite resin filling at teeth 34 and 35, with recession depths of 2 mm and 3 mm on the facial aspects, respectively. We operated combination of restoration with root coverage procedure on his teeth 34 and 35 (Fig. 1). After a healing period of one month, neither gingival inflammation nor bleeding on probing was found. The patient was satisfied with the final esthetics and had no further complaints of cervical dentin hypersensitivity.

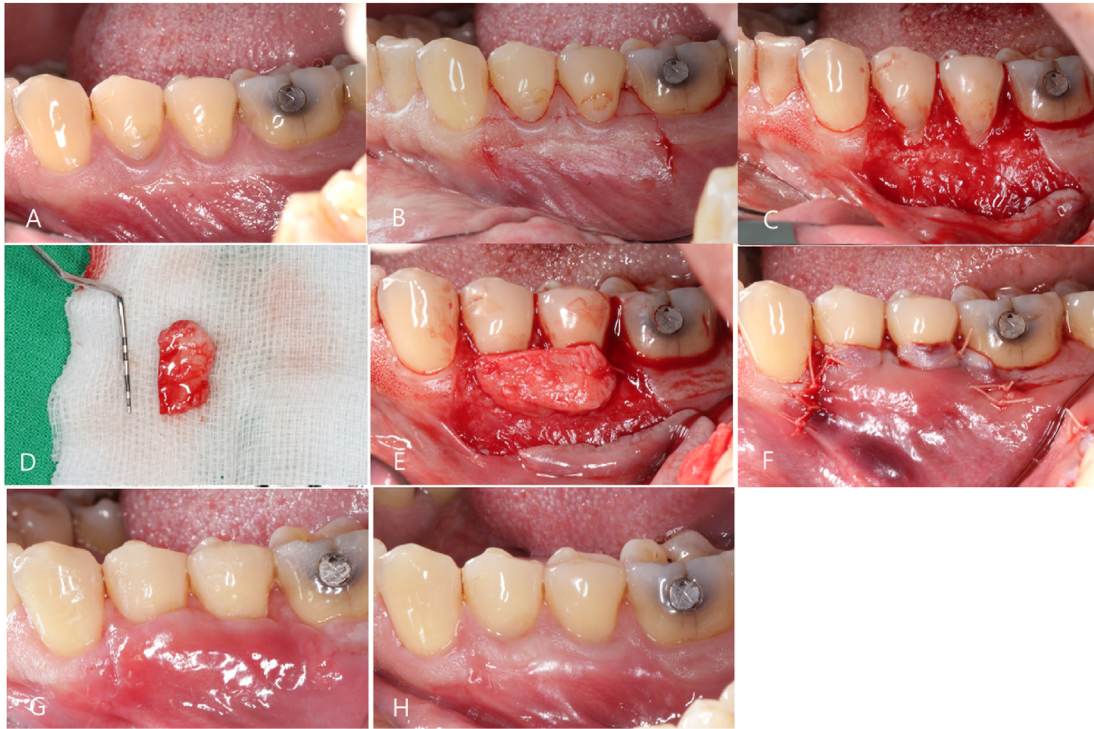
Gingival recession may lead to esthetic problems, dentin hypersensitivity, root caries, and NCCLs. Miller's class I & II gingival recession can be predictably resolved with a root coverage procedure by coronally positioned flap with

connective tissue graft. However, gingival recession is frequently associated with cervical wear. In many situations, it may cause esthetic and sensitivity problems. In terms of relief of cervical dentin hypersensitivity, a combination of subepithelial connective tissue graft and resin restoration has better outcomes than connective tissue graft alone.<sup>2</sup> Dental materials for cervical abrasion restoration are needed, but the controversy of interaction between periodontics and restorative dentistry still existed in the last two decades. According to Cairo and Pini-Prato,<sup>1</sup> the outcomes that combined restorative and periodontal treatments maintained good esthetic results and minimal inflammation over a 2-year follow-up.<sup>2</sup> Regardless of resin or resin-modified glass ionomer, the restoration did not affect periodontal health for the root coverage procedure. In 2009, Santamaria concluded that glass ionomer cement restoration did not affect the result of root coverage by connective tissue graft.<sup>2</sup> Moreover, during the wound healing process at the subgingival margin, both epithelium and connective tissue adhered to the resin-ionomer restorative materials, as seen in histological examination.<sup>3</sup> Blank et al. showed that a well-finished and contoured subgingival composite resin does not adversely affect the health of the gingiva.<sup>4</sup> However, Paolantonio et al. found that composite resin significantly increased total bacterial counts in the gingival sulcus,<sup>5</sup> and the bacteria included: *A. israelii*, *B. capillosus*, *F. mortiferum*, *P. gingivalis* and *P. oralis*, which are putative periodontal pathogens.

Hence, routine supportive periodontal treatment that changes the microbiological environment of the gingiva sulcus is needed to maintain periodontal health at subgingival restoration sites. The result of this case report indicates that teeth with Miller's class I gingival recessions associated with NCCLs can be successfully treated with an

<https://doi.org/10.1016/j.jds.2022.03.008>

1991-7902/© 2022 Association for Dental Sciences of the Republic of China. Publishing services by Elsevier B.V. This is an open access article under the CC BY-NC-ND license (<http://creativecommons.org/licenses/by-nc-nd/4.0/>).



**Figure 1** Clinical photographs of our case. (A) Preoperative clinical photograph showing teeth 34 and 35 with 2 mm and 3 mm gingival recession, respectively. (B) Incision lines were made at teeth 34 and 35 interdental areas horizontally, tooth 33 distal line angle vertically, and tooth 36 mesial line angle vertically. (C) Gingival flap was elevated and root planing was performed. (D) A free connective tissue graft. (E) Fixation of free connective tissue graft with interrupted suture to periosteum. (F) The coronally positioned flap was sutured to cover the 2 mm above the cemento enamel junction. (G) Two-week post-operation clinical photograph revealing well-healed wound. (H) Nine-month post-operation clinical photograph demonstrating complete root coverage.

integrated periodontal and restorative dentistry approach. This can be expected to solve the cervical dentin hypersensitivity, increase the width of the keratinized gingiva, and restore aesthetics.

### Declaration of Competing Interest

The authors declare no conflicts of interest relevant to this article.

### References

1. Cairo F, Pini-Prato GP. A technique to identify and reconstruct the cemento enamel junction level using combined periodontal and restorative treatment of gingival recession. A prospective clinical study. *Int J Periodontics Restor Dent* 2010;30:573–81.
2. Santamaria MP, da Silva Feitosa D, Nociti Jr FH, Casati MZ, Sallum AW, Sallum EA. Cervical restoration and the amount of soft tissue coverage achieved by coronally advanced flap: a 2-year follow-up randomized-controlled clinical trial. *J Clin Periodontol* 2009;36:434–41.
3. Dragoo MR. Resin-ionomer and hybrid-ionomer cements: part II, human clinical and histologic wound healing responses in specific periodontal lesions. *Int J Periodontics Restor Dent* 1997;17:75–87.

4. Blank LW, Caffesse RG, Charbeneau GT. The gingival response to well-finished composite resin restorations. *J Prosthet Dent* 1979;42:626–32.
5. Paolantonio M, D’Ercole S, Perinetti G, et al. Clinical and microbiological effects of different restorative materials on the periodontal tissues adjacent to subgingival class V restorations. *J Clin Periodontol* 2004;31:200–7.

Yu-Ping Chen  
Division of Periodontics, Department of Dentistry,  
Kaohsiung Medical University Hospital, Kaohsiung, Taiwan

Kai-Fang Hu  
Division of Periodontics, Department of Dentistry,  
Kaohsiung Medical University Hospital, Kaohsiung, Taiwan  
Institute of Clinical Medicine, National Yang Ming Chiao  
Tung University, Taipei, Taiwan

Jiang-Huei Jeng  
School of Dentistry, College of Dental Medicine, Kaohsiung  
Medical University, Kaohsiung, Taiwan  
Department of Dentistry, National Taiwan University  
Hospital and School of Dentistry, National Taiwan  
University Medical College, Taipei, Taiwan  
Department of Dentistry, Kaohsiung Medical University  
Hospital, Kaohsiung, Taiwan

Yu-Hsiang Chou\*  
*School of Dentistry, College of Dental Medicine, Kaohsiung  
Medical University, Kaohsiung, Taiwan  
Division of Periodontics, Department of Dentistry,  
Kaohsiung Medical University Hospital, Kaohsiung, Taiwan*

\*Corresponding author. School of Dentistry, College of  
Dental Medicine, Kaohsiung Medical University, Kaohsiung,  
Taiwan and Division of Periodontics, Department of

Dentistry, Kaohsiung Medical University Hospital, No.100,  
Tzyou 1st Rd., Sanmin Dist., Kaohsiung 80756, Taiwan.  
*E-mail address: [yuhshang@gmail.com](mailto:yuhshang@gmail.com) (Y.-H. Chou)*

Received 17 March 2022  
Final revision received 20 March 2022  
Available online 4 April 2022