

Second Anterior Cruciate Ligament Injuries After Anterior Cruciate Ligament Reconstruction in Professional Sumo Wrestlers

A Case Series

Sadanori Shimizu,^{*,†} MD, PhD, Tsuyoshi Nagase,[†] MD, PhD, Tomohiko Tateishi,[†] MD, PhD, Teruhiko Nakagawa,[†] MD, PhD, and Masamitsu Tsuchiya,[†] MD, PhD

Investigation performed at the Department of Orthopaedic Surgery, Arthroscopy and Sports Medicine Center, The Fraternity Memorial Hospital, Tokyo, Japan

Background: Anterior cruciate ligament (ACL) injury is one of the most common traumatic injuries in professional sumo wrestlers. Further, ipsilateral reinjuries or contralateral ACL injuries after ACL reconstruction can occur in sumo wrestlers. The incidence of ipsilateral reinjury and contralateral ACL injury after ACL reconstruction ranges from 3% to 13% in a healthy athletic population.

Purpose: To investigate the current status of second ACL injuries after ACL reconstruction in sumo wrestlers.

Study Design: Case series; Level of evidence, 4.

Methods: Between 1988 and 2015, a total of 139 primary ACL reconstructions were performed in professional sumo wrestlers at our hospital. After exclusion of cases of multiple ligament knee reconstruction and patients in whom the contralateral ACL had been injured previously, 110 cases were included in this study. We investigated the number of second injuries, time from primary reconstruction to second injury, treatment method, and change in official sumo ranking after second injuries. The chi-square test, Student *t* test, and Fisher exact test were used for statistical analysis.

Results: Among 110 wrestlers who underwent ACL reconstruction, second injuries after primary ACL reconstruction occurred in 22 cases (20.0%). Among them, 14 cases (12.7%) entailed ipsilateral reinjury, 11 (10.0%) entailed contralateral injury, and 3 involved combined rerupture and contralateral injury. As for surgical treatment, 5 revision ACL reconstructions were performed for ipsilateral reinjury (35.7%), and 7 ACL reconstructions were performed for contralateral injury (63.6%). Surgical treatment was not performed for the remaining cases. Wrestlers who were treated by revision or contralateral ACL reconstruction after the second injury were demoted in rank for 3 to 4 tournaments but overtook the nonoperative treatment group in ranking by 2 years post-operatively; all athletes initially were demoted in rank after the second injury.

Conclusion: This study is the first to investigate instances of ipsilateral reinjuries and contralateral ACL injuries after ACL reconstruction in professional athletes in heavyweight combat sports. The incidences of ipsilateral reinjury and contralateral ACL injury after ACL reconstruction in professional sumo wrestlers were relatively higher than those reported in previous studies.

Keywords: anterior cruciate ligament; reinjury; contralateral injury; sumo wrestler

Sumo wrestling has a long history in Japan as a national sport, and recently it has become popular worldwide. A bout is won by forcing the opponent out of the inner circle or by throwing the opponent in the sumo ring, or *dohyo*. Unlike Western wrestling, sumo has no weight limits. A tournament lasts for 15 days, and 6 grand tournaments take place

per year. *Maku-uchi* and *juryo* division wrestlers fight once daily with a different opponent (15 bouts), and wrestlers at or below *makushita* rank fight every other day (7 bouts) in a tournament. After each grand tournament, official sumo rankings, which are called *banzuke* (Table 1), are revised, as the wrestlers are either promoted or demoted depending on their performance over the 15 days.

Anterior cruciate ligament (ACL) injury is a common traumatic injury in professional sumo wrestlers.⁹ From 1982 to 2014, there were 5483 incidences of sumo wrestling

TABLE 1
Official Sumo Rankings (*Banzuke*)

<i>Jo-no-kuchi</i> : the lowest rank
<i>Jo-ni-dan</i> : second grade
<i>San-dan-me</i> : third grade
<i>Makushita</i> : junior grade
<i>Juryo</i> : intermediate division
<i>Maku-uchi</i> : the highest division, includes the 4 highest ranks (<i>yokozuna</i> , <i>ozeki</i> , <i>sekiwake</i> , and <i>komusubi</i>)

injuries treated at our hospital; of these, 270 (4.9%) involved the ACL. In each case, we determined the type of treatment after discussion with the athlete and his wrestling coach. The percentage of ACL injuries treated non-operatively was approximately 50%. In the past 14 years (from 2004 to 2014), 90 professional sumo wrestlers (92 knees) were diagnosed with ACL injuries at our hospital. The average age and ranking were 22.7 years (range, 15-38 years) and *san-dan-me*, respectively. Among these individuals, 63 wrestlers (64 knees) were treated with surgical reconstruction (bone–patellar tendon–bone [BTB] graft), and the others were treated nonoperatively.⁸

In sumo wrestlers, as in other athletes, ipsilateral reinjuries or contralateral ACL injuries after ACL reconstruction can occur.⁴ In previous studies, the incidence of second ACL injury after ACL reconstruction has been reported to range from 3% to 13% in a healthy athletic population.^{2,3,5,6,10,11} Knowledge of instances of ipsilateral reinjuries and contralateral ACL injuries after ACL reconstruction is important for preventing these second injuries. Furthermore, understanding the cause of injury after revision or contralateral ACL reconstruction is valuable in determining the treatment method for the second ACL injury in sumo wrestlers. The primary purpose of this study was to investigate the current status of second ACL injuries after ACL reconstruction in sumo wrestlers. The secondary aim of this study was to determine the difference between rerupture and contralateral injury.

METHODS

After obtaining institutional review board approval, we identified all professional sumo wrestlers who were diagnosed with ACL injury at our hospital from 1988 to 2015. Among this population, wrestlers who underwent primary ACL reconstruction were included in this study. Those who underwent multiple ligament reconstructions and those with a previous contralateral ACL injury were excluded. Informed consent was obtained from all included patients.

We investigated and recorded the number of second injuries (ipsilateral reinjuries or contralateral ACL injuries), time from primary reconstruction to second injury, and treatment method from the patients' medical records. We identified second injuries by a patient return visit to our clinic and by using news services and medical certificates submitted to the Nihon Sumo Kyokai (Japan Sumo Association). In addition, we reviewed the transition in official ranking (Table 1) published by Nihon Sumo Kyokai after second injuries.

Statistical Analysis

The chi-square test was used to compare the number of second injuries. The Student *t* test was used to compare age at second injury, time from primary to second injury, and periods of tournament default (sumo wrestlers with ACL injury, especially those who select surgical treatment, have to withdraw from tournaments because of treatment and rehabilitation). The Fisher exact test was used to compare the number (ratio) of treatment methods. The statistical significance was set at $P < .05$. All statistical analyses of recorded data were performed using the Excel statistical software package (Ekuseru-Toukei 2015; Social Survey Research Information Co Ltd).

RESULTS

Between 1988 and 2015, a total of 255 professional sumo wrestlers were diagnosed as having ACL injury in The Fraternity Memorial Hospital, and we performed primary ACL reconstruction for 139 wrestlers. The ACL grafts used were as follows: 98 BTB grafts, 38 hamstring tendon grafts (semitendinosus and gracilis, single bundle), and 3 others. After the exclusion of multiple ligament knee reconstruction and previous contralateral ACL injury, 110 cases were included in this case series (Figure 1). The mean body mass index of these sumo wrestlers was 39.0 ± 6.4 kg/m². The mean follow-up duration after primary ACL reconstruction was 6.0 years (range, 0.4-16.8 years).

Second injuries after primary ACL reconstruction occurred in 22 cases (20.0%). Among the 110 wrestlers who underwent ACL reconstruction, 14 cases (12.7%) entailed ipsilateral reinjury, 11 cases (10.0%) involved contralateral injury, and 3 cases involved combined rerupture and contralateral injury. Age at second injuries and time from primary to second injuries were not significantly different between the reinjury and contralateral injury groups (Table 2). As for surgical treatment, 5 revision ACL reconstructions (BTB, 2; semitendinosus and gracilis, 3) were

*Address correspondence to Sadanori Shimizu, MD, PhD, Department of Orthopaedic Surgery, The Fraternity Memorial Hospital, 2-1-11 Yokoami, Sumida, Tokyo 130-8587, Japan (email: sadanorishimizu@jcom.home.ne.jp).

†Department of Orthopaedic Surgery, Arthroscopy and Sports Medicine Center, The Fraternity Memorial Hospital, Tokyo, Japan.

Final revision submitted November 4, 2019; accepted November 11, 2019.

The authors declared that there are no conflicts of interest in the authorship and publication of this contribution. AOSSM checks author disclosures against the Open Payments Database (OPD). AOSSM has not conducted an independent investigation on the OPD and disclaims any liability or responsibility relating thereto.

Ethical approval for this study was obtained from The Fraternity Memorial Hospital Institutional Review Board.

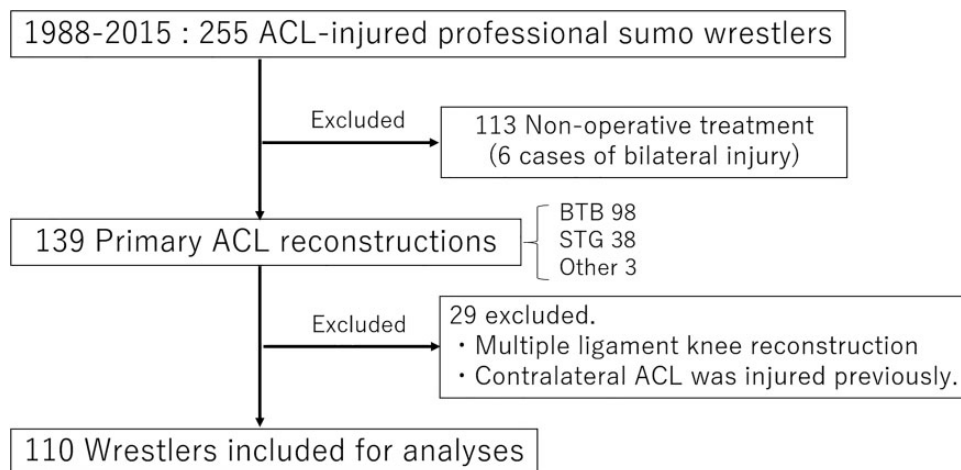


Figure 1. Flowchart of cases. ACL, anterior cruciate ligament; BTB, bone–patellar tendon–bone; STG, semitendinosus and gracilis.

TABLE 2

Summary of Second Injuries After Anterior Cruciate Ligament (ACL) Reconstruction (n = 22 reinjuries; 20.0%)

	Rerupture	Contralateral Injury	P
Second injuries, n (%)	14 (12.7)	11 (10.0)	.55 ^a
Age at second injury, y	22.4	24.1	.13 ^b
Time from primary to second injury, mo (range)	30.9 (7-75)	38.6 (6-84)	.39 ^b
Treatment method (No. of cases)	ACL revision (5)	ACL reconstruction (7)	

^aChi-square test.

^bt test.

performed for ipsilateral reinjury (35.7%), and 7 ACL reconstructions were performed for contralateral injury (63.6%). Surgical treatment was not administered in the remaining 13 cases. Most wrestlers who had a contralateral ACL injury underwent surgical treatment (7/11), whereas those with an ipsilateral reinjury tended to avoid revision surgery (9/14). In the nonsurgical program, the wrestlers performed basic sumo training techniques (*shiko* [repeated leg lifts], *suri-ashi* [sliding feet], *teppou* [strike wooden pole], etc), wore a brace after resolution of knee swelling, and were permitted to return to competitive sumo wrestling after adequate training with other wrestlers. All wrestlers returned to competitive sumo wrestling after the second ACL injury.

The time from primary to second injury was significantly longer in wrestlers who selected nonoperative treatment than in those who selected surgical treatment. Moreover, periods of tournament default (when the wrestler was absent from competitive sumo wrestling because of injury) were significantly longer in the surgical treatment group than in the nonoperative treatment group (Table 3). Consequently, wrestlers treated with revision or contralateral

TABLE 3

Comparison of Surgical Versus Nonsurgical Treatment for Ipsilateral Reinjuries and Contralateral Anterior Cruciate Ligament (ACL) Injuries

	Surgical Treatment ^a (n = 12)	Nonsurgical Treatment (n = 13)	P
Ipsilateral reinjury (n = 14)			
No. (%)	5 (35.7)	9 (64.3)	.29 ^b
Age at reinjury, y	21.6	22.9	.29 ^c
Time from primary to second injury, mo	15.4	39.6	<.01 ^c
No. of tournament defaults ^d	4.4	0.3	<.01 ^c
Time from primary ACL injury to retirement, y	9.0	6.9	.46 ^c
Time from ACL reinjury to retirement, y	7.6	3.8	.20 ^c
Contralateral ACL injury (n = 11)			
No. (%)	7 (63.6)	4 (36.4)	.37 ^b
Age at reinjury, y	23.8	24.5	.72 ^c
Time from primary to second injury, mo	25.9	61.0	.02 ^c
No. of tournament defaults ^d	2.6	0	<.01 ^c
Time from primary ACL injury to retirement, y	7.6	13.3	.07 ^c
Time from contralateral ACL injury to retirement, y	5.0	8.0	.23 ^c

^aThe surgical treatment was revision surgery for ipsilateral reinjury and ACL reconstruction for contralateral ACL injury.

^bFisher test.

^ct test.

^dThe tournament is held every 2 months.

ACL reconstruction after the second injury were demoted in rank for 3 or 4 tournaments, but their rankings became higher than the nonoperative treatment group by 2 years postoperatively. However, the increase in rankings of the revision ACL group was not statistically significantly higher than that of the nonoperative treatment group.

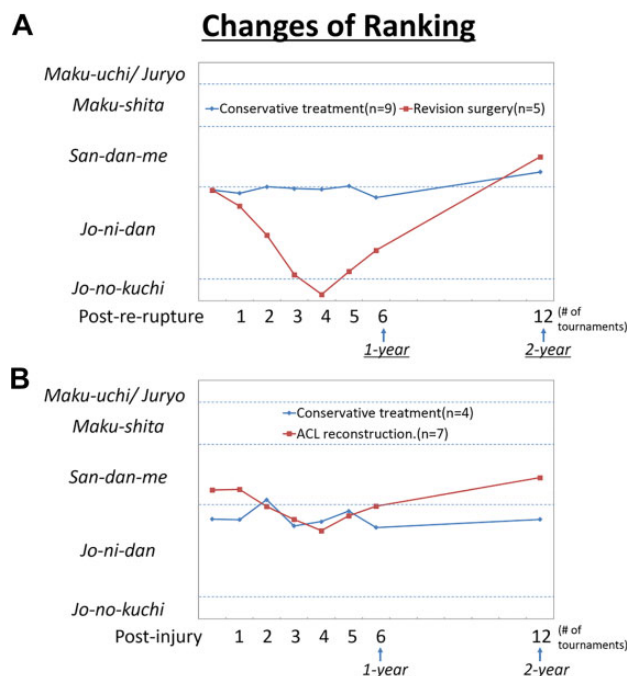


Figure 2. Changes of official sumo rankings. (A) Ipsilateral reinjuries. (B) Contralateral anterior cruciate ligament (ACL) injuries.

Conversely, few wrestlers who avoided surgical treatment were promoted a rank, although all wrestlers had an initial demotion in rank after their second ACL injury (Figure 2). In addition, the wrestlers' overall career length was not significantly affected by the type of treatment or whether they received a second ACL injury (Table 3).

DISCUSSION

In this study, we clarified the current status of second ACL injuries after ACL reconstruction in sumo wrestlers. In previous studies, the incidences of ipsilateral reinjury and contralateral ACL injury after ACL reconstruction have been reported to be 3% to 13% of cases in a healthy athletic population^{2,3,5,6,10,11} (Table 4). We found these numbers to be higher in professional sumo wrestlers. Since professional sumo wrestling is a type of combat sport that involves heavyweight athletes, it places a great deal of stress on the athletes' knees, especially when they step backward in the face of contact from the opposition.

Although we typically recommend surgical reconstruction for sumo wrestlers with primary ACL injuries, only 55% chose such treatment. This is in part because wrestlers who are absent from tournaments during any postoperative rehabilitation see their rank steadily decrease. Most wrestlers with an ACL injury decide on their treatment method in consultation with their wrestling coach. After nonoperative treatment for primary ACL injuries, most sumo wrestlers try to only step in the forward direction since they often experience apprehension when they step back, and

TABLE 4
Reports of the Rate of Second Injuries After Anterior Cruciate Ligament Reconstruction^a

Lead Author (Year)	% Rerupture	% Contralateral Injury	Follow-up, y	Sports Involved
Salmon ⁵ (2005)	6.4	5.7	5	Cycling, touch football, rugby, soccer
Wright ¹¹ (2007)	3.0	3.0	2	Unidentified
Shelbourne ⁶ (2009)	4.3	5.3	>5	Basketball, soccer, football
Ahldén ² (2012)	4.1	5.0	5	Soccer, floorball, Alpine skiing
Bourke ³ (2012)	11	13	15	Unidentified
Webster ¹⁰ (2014)	4.5	7.5	4.8	Unidentified
Current study	12.7	10.0	6	Sumo

^aA high risk of second injuries was reported in young people.^{3,6,10}

they try not to stand their ground with excessive force. Of interest, in the current study, long-term participation (the time period from ACL injury to retirement) was not different between athletes who had undertaken operative and nonoperative treatments.

Most wrestlers with ACL reinjury also decide their treatment method in consultation with their wrestling coach. Surgical treatment was performed in most cases of contralateral ACL injury, whereas wrestlers who had ipsilateral reinjury tended to avoid revision surgery. One reason for this is that revision surgery is associated with a longer time to return to wrestling because of a longer recommended rehabilitation period.¹ In each case of ipsilateral reinjury and contralateral ACL injury, the times from primary to second injuries were significantly longer in wrestlers who selected nonoperative treatment than in those who selected surgical treatment. As most wrestlers with a relatively early reinjury are fearful of their future wrestling career, they prefer surgical treatment. However, wrestlers with reinjury after a couple of years may be willing to compete on an ACL-deficient knee given their shorter remaining career. The main reason why sumo wrestlers select nonoperative treatment for ACL injury is that they worry about their rankings decreasing drastically in the short term rather than consider the long-term implications. For this reason, wrestlers often continue to compete regardless of symptoms.^{7,8}

Although temporary demotion of rank is inevitable, mid-term results were favorable in most wrestlers treated by revision or contralateral ACL reconstruction after second injury. To decrease the rate of second ACL injuries,

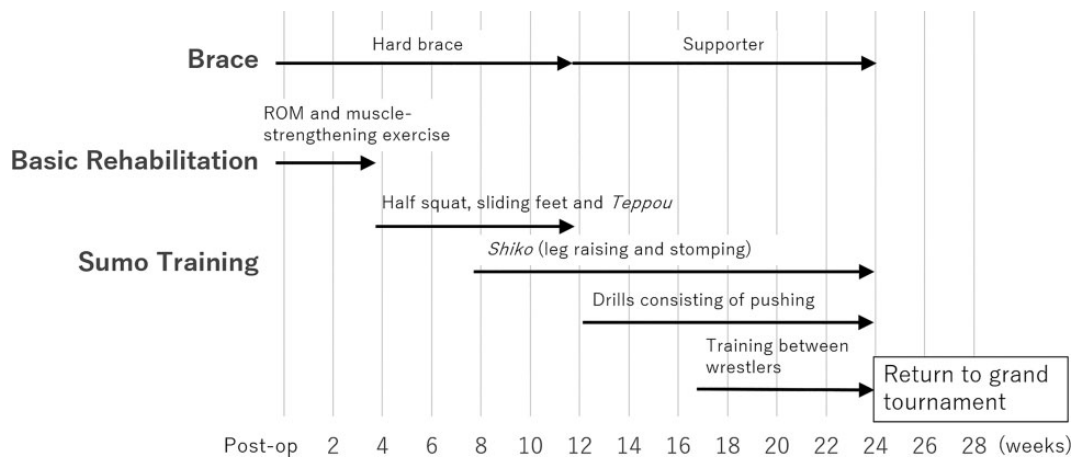


Figure 3. Program of return to wrestling for professional sumo wrestlers after anterior cruciate ligament reconstruction. ROM, range of motion.

cautious postoperative care after primary surgery and preventive rehabilitation are important.⁴ In recent years, we have helped professional sumo wrestlers return to wrestling after ACL reconstruction using a program shown in Figure 3. Traditional basic training of sumo wrestling⁶ (eg, *shiko*, *suri-ashi*, and *matawari*) is also beneficial for preventing ACL injury. We recommend that after ACL reconstruction, wrestlers return to tournament competition after they undergo adequate training with other wrestlers. However, a few wrestlers returned to the tournament sooner than we recommended.

Limitations

We acknowledge that this study has several limitations. First, for some wrestlers we did not evaluate long-term postoperative outcomes such as the Lachman test result, pivot-shift test result, and anterior knee laxity measurement using the KT-1000 arthrometer, nor did we assess concomitant injuries that could have affected the results of this study. Second, there is a possibility that some wrestlers did not visit any hospital after they were reinjured. Therefore, the actual rates of second injuries might be higher than those we reported. Third, another trauma or injuries other than ACL could have affected the changes in the official sumo rankings after reinjury. Fourth, since the focus of this study was second injuries after ACL reconstruction, we did not draw a comparison with a group of wrestlers treated nonoperatively after their initial ACL injury.

CONCLUSION

The incidences of ipsilateral reinjury and contralateral ACL injury after ACL reconstruction in professional sumo wrestlers were higher than those reported in previous studies on athletes in other sports. Surgical treatment was performed in most cases of contralateral ACL injury, whereas ipsilaterally reinjured wrestlers tended to avoid revision surgery. Although temporary demotion of rank was

inevitable, midterm results were favorable in most wrestlers treated by revision or contralateral ACL reconstruction after second injury.

REFERENCES

- Adams D, Logerstedt DS, Hunter-Giordano A, Axe MJ, Snyder-Mackler L. Current concepts for anterior cruciate ligament reconstruction: a criterion-based rehabilitation progression. *J Orthop Sports Phys Ther.* 2012;42(7):601-614.
- Ahlén M, Samuelsson K, Sernert N, Forssblad M, Karlsson J, Kartus J. The Swedish National Anterior Cruciate Ligament Register: a report on baseline variables and outcomes of surgery for almost 18,000 patients. *Am J Sports Med.* 2012;40(10):2230-2235.
- Bourke HE, Salmon LJ, Waller A, Patterson V, Pinczewski LA. Survival of the anterior cruciate ligament graft and the contralateral ACL at a minimum of 15 years. *Am J Sports Med.* 2012;40(9):1985-1992.
- Nagase T, Tateishi T, Shimizu S, et al. Analysis of complications and return to match after anterior cruciate ligament reconstruction for professional sumo wrestlers. *Jpn J Orthop Sports Med.* 2017;37(3):235-238.
- Salmon L, Russell V, Musgrove T, Pinczewski L, Refshauge K. Incidence and risk factors for graft rupture and contralateral rupture after anterior cruciate ligament reconstruction. *Arthroscopy.* 2005;21(8):948-957.
- Shelbourne KD, Gray T, Haro M. Incidence of subsequent injury to either knee within 5 years after anterior cruciate ligament reconstruction with patellar tendon autograft. *Am J Sports Med.* 2009;37(2):246-251.
- Shimakawa T, Tateishi T. Injuries in sumo wrestling. *Aspetar Sports Medicine Journal.* 2015;4(3):394-396.
- Shimizu S, Nagase T, Tateishi T, Saito R, Nakagawa T, Tsuchiya M. Return of sumo wrestlers after an anterior cruciate ligament injury—a study on the status of an official system for exempting injured players. *Jpn J Orthop Sports Med.* 2018;38(2):154-157.
- Shimizu S, Tateishi T, Nagase T, Motosugi N, Nakagawa T, Tsuchiya M. Study of anterior cruciate ligament injuries in professional sumo wrestlers. *Jpn J Orthop Sports Med.* 2010;30(2):119-123.
- Webster KE, Feller JA, Leigh WB, Richmond AK. Younger patients are at increased risk for graft rupture and contralateral injury after anterior cruciate ligament reconstruction. *Am J Sports Med.* 2014;42(3):641-647.
- Wright RW, Dunn WR, Amendola A, et al. Risk of tearing the intact anterior cruciate ligament in the contralateral knee and rupturing the anterior cruciate ligament graft during the first 2 years after anterior cruciate ligament reconstruction: a prospective MOON cohort study. *Am J Sports Med.* 2007;35(7):1131-1134.