



Review Article

Analgesia from percutaneous thermal ablation plus cementoplasty for cancer bone metastases

Yuandong Sun^{a,1}, Hao Zhang^{b,1}, Hui-rong Xu^b, Jing-zhou Liu^b, Jia Pan^c, Hui-zhuan Zhai^a, Chang-yan Lu^a, Xia Zhao^a, Ye-qiang Chen^a, Lin-lin Zhou^a, Jinming Yu^b, Jianjun Han^{b,*}

^a School of Medicine and Life Sciences, University of Jinan-Shandong Academy of Medical Sciences, Shandong Cancer Hospital and Institute, Jinan, 250117, PR China

^b Shandong Cancer Hospital and Institute, Shandong First Medical University, Shandong Academy of Medical Sciences, Jinan, 250117, PR China

^c Mudan District Central Hospital

ARTICLE INFO

Keywords:

Thermal ablation

Cementoplasty

Bone metastases

Analgesia

Pain management

Palliative care

ABSTRACT

Background: The purpose of this study was to review recent research related to the analgesic effect of ablation therapy combined with cementoplasty, as well as to identify the duration of analgesic effect and risk for cement leaks.

Methods: A systematic literature search using PubMed, Web of Science, and annual meeting proceedings of the oncology society and other organizations were conducted.

Results: Twelve retrospective studies met the inclusion criteria. Four of the studies included in the review assessed the changes immediately after treatment. Five studies were subjected to analyses of analgesic effect of combined percutaneous thermal ablation and Cementoplasty at 24 weeks after treatment. Incidences of leakage of bone cement during surgery were detected in 4 out of 12 studies. The change of mean pain scores at 1 days, at 1 week, and at 4 weeks, 12 weeks, and 24 weeks after treatment were -3.90 (95% CI: -4.80 to -3.00), -4.55 (95% CI: -5.46 to -3.64), -4.78 (95% CI: -5.70 to -3.86), -5.16 (95% CI: -6.39 to -3.92), and -5.91 (95% CI: -6.63 to -5.19). The relative risk of cement leakage was 0.10 (95% CI: -6.63 to -5.19).

Conclusions: Our systematic review suggested that thermal ablation combined with cementoplasty could be a safe and effective intervention for the management of bone metastases-induced pain.

1. Background

Bone is a common metastatic site amongst cancer patients with metastatic disease [1-3], with spine, ribs, and pelvis being the most common sites for such metastases [4]. It is estimated that approximately 26% to 45% of patients with advanced prostate, breast, lung, and thyroid cancer will develop bone metastasis [5-8]. As the number of patients being diagnosed with cancer rises, the incidence of bone metastases increases as well [9-11]. Extensive pain, distressing and insomnia caused by pathological bone fractures and spinal cord compression in patients with bone metastases are major factors which further deteriorate the quality of their life [3]. Hence, palliative care is of great importance.

Previous studies have shown that potential interventions to alleviate bone pain are radiotherapy and cementoplasty, as well as administration of opioids and/or bisphosphonates. However, none of these

methods can be used for extended periods of time.

Materials science and interventional medical technological revolutions have recently entered the clinics. The development of thermal ablation methods, including radiofrequency ablation, cryoablation and microwave ablation, provided clinicians with new treatment methods for patients with metastatic lesions in bones. Thermal ablation in combination with cementoplasty has also emerged as a novel intervention. Studies assessing the safety and efficacy of the ladder are largely based on a few prospective clinical trials, small retrospective studies, or even case reports. To date, no extensive and systematic review exists to assess relevant clinical outcomes. This article provides a systematic review of the literature related to pain management in patients with bone metastases.

* Corresponding author at: Department of Intervention, Shandong Cancer Hospital and Institute, Shandong First Medical University, Shandong Academy of Medical Sciences, No. 440 Jiyuan Road, Jinan, 250117, PR China.

E-mail address: Jieruheweichuan@163.com (J. Han).

¹ YDS and HZ contributed equally to this work.

<https://doi.org/10.1016/j.jbo.2019.100266>

Received 22 April 2019; Received in revised form 30 October 2019; Accepted 30 October 2019

Available online 05 November 2019

2212-1374/ © 2019 The Authors. Published by Elsevier GmbH. This is an open access article under the CC BY-NC-ND license (<http://creativecommons.org/licenses/by-nc-nd/4.0/>).

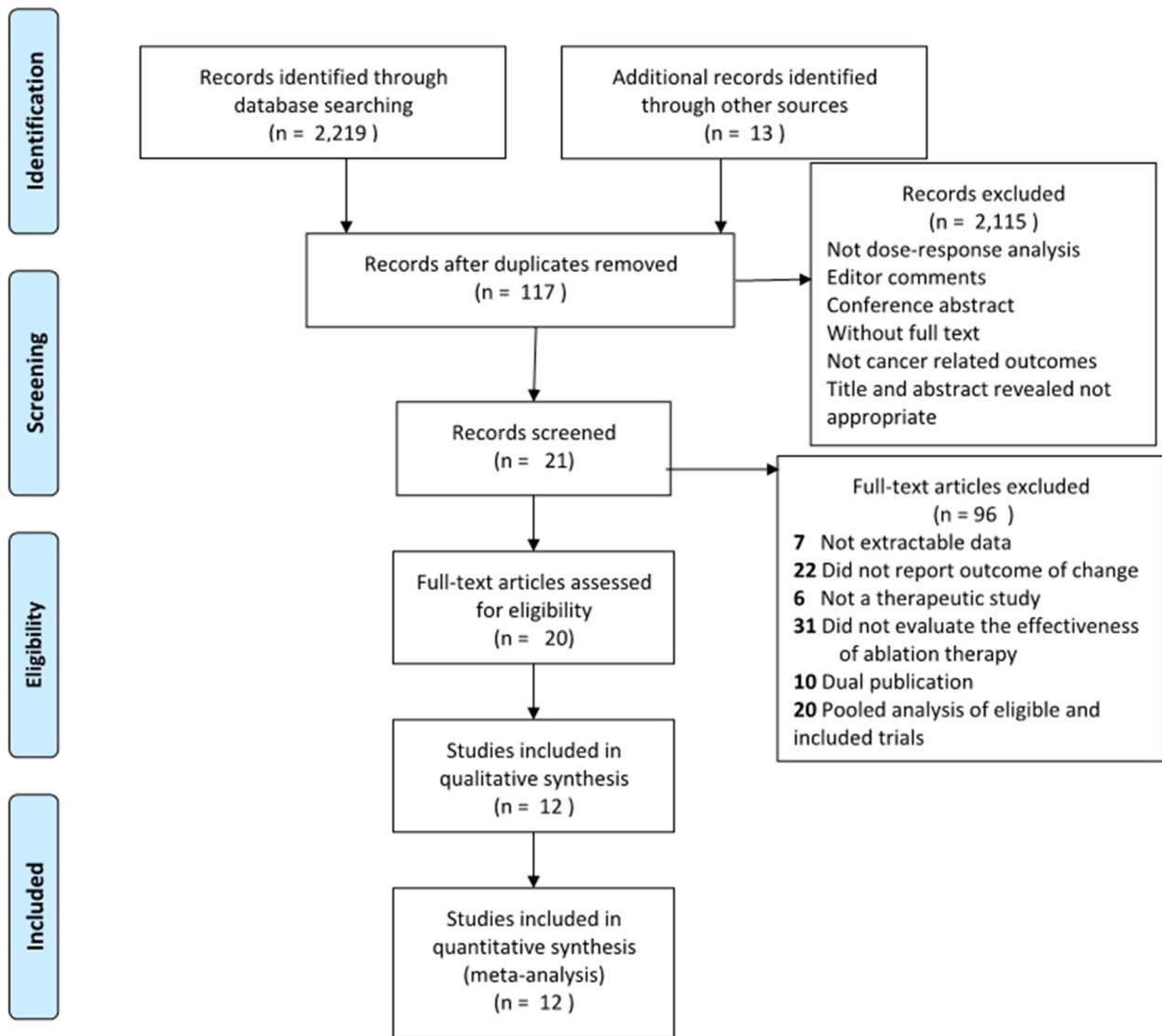


Fig. 1. Flow chart.

2. Material and methods

This systematic review was conducted as per Preferred Reporting Items for Systematic Reviews and Meta-Analyses (PRISMA) guidelines.

2.1. Search strategy

Using PubMed and Web of Science databases we searched for published literature in English between January 2013 and March 2019. Research was performed using the following keywords and subject headings: thermal ablation, radiofrequency ablation (RFA), microwave ablation (MWA), cryoablation, cementoplasty, percutaneous cementoplasty, bone metastases, percutaneous osteoplasty, and pain management. Abstracts were reviewed for relevance and all the potentially relevant articles were reviewed for inclusion. In addition, conference articles, abstracts, and posters from major oncology society and organization meetings from 2013 to 2018 were reviewed (by two researchers). We also reviewed annual meeting proceedings that took place between 2013 and 2018 from the following oncology societies and organizations: European Society for Medical Oncology (ESMO), American Society of Clinical Oncology (ASCO), Chinese Society of Clinical Oncology (CSCO) and American Association for Cancer Research (AACR). Additionally, reference lists were manually searched

for relevant publications. Any duplicate results from these searches were removed.

2.2. Criteria for study selection

Inclusion criteria: 1. All research hypotheses and methods were similar; 2. Patients were diagnosed with cancer bone pain; 3. Study specified the precise number of sample size; 4. Study provided complete pain data for analysis.

Exclusion criteria: We excluded review articles, repeated studies, non-clinical studies, letters, clinical studies without primary efficacy data, trial that did not involve combination treatment, and studies in patients without cancer-induced bone pain.

Two investigators independently reviewed titles and abstracts for eligibility. If either deemed a study potentially eligible, two investigators did full-text review independently, with any disagreements resolved by consensus.

2.3. Study quality assessment

Two reviewers assessed independently the quality of the original studies, and supplementary materials by using the criteria listed in Table 2. The adequacy of 8 aspects was assessed: clarity of study aim,

consecutiveness of patients, prospective data collection, appropriate endpoints, unbiased assessment, long-term follow-up, low loss to follow-up, and assessment criteria for bone metastases-induced pain (NRS or VAS). Each aspect was assigned an assessment index associated with the risk of bias classified as yes, no, or unclear. We evaluated the quality of studies quantitatively by using the quality scale.

2.4. Data extraction

All data were extracted from the text or calculated using available information by both researchers independently. Descriptive statistics, forest plot and trend chart were used to visualize our findings. OriginPro 2018 (64-bit) was used to analyze the raw data retrieved from Elizabeth's study. Statistical analysis was performed by SPSS software (version 19) and Stata SE (15.1).

The following formula from Cochrane Handbook 5.0.2 (16.1.3.2) was used to calculate the mean \pm SD change in pain before and after comprehensive treatment:

$$SDE, \text{ change} = \sqrt{SD_{E, \text{baseline}}^2 + SD_{E, \text{final}}^2 (2 * \text{Corr} * SD_{E, \text{baseline}} * SD_{E, \text{final}})}$$

$$\text{Corr} = 0.5$$

3. Results

3.1. Eligible studies

The flowchart summarizing the study selection process is shown in Fig. 1. We identified 2232 studies in the initial screening, and after evaluating abstracts and full texts, 20 publications were selected for full-text assessment. Eventually, 12 studies [12–23] were included in this systematic review (Fig. 2).

3.2. Study characteristics

329 cases of patients were included in the analysis. The baseline characteristics of the 12 studies are shown in Table 1. 54.4% of patients (179/329) were males, and the age of them ranged between 18 and 86 years. The spine was the most common site of bone metastasis, followed by pelvis and femur.

3.3. Quality assessment

Since the characteristics of interventional therapy were similar to those of non-randomized surgical studies, we evaluated the quality of the 12 selected studies using the methodological index for non-randomized studies (MINORS), and the results of the assessment are shown in Table 2.

3.4. Pain management

In order to assess the effects on pain management, we calculated the change in pain at day 1, post-operation, as well as after 1, 4, 12, and 24 weeks.

The changes in pain at day 1 post-treatment and after 1, 4, 12, and 24 weeks were -3.90 (95% CI: -4.80 to -3.00), -4.55 (95% CI: -5.46 to -3.64), -4.78 (95% CI: -5.70 to -3.86), -5.16 (95% CI: -6.39 to -3.92), and -5.91 (95% CI: -6.63 to -5.19) respectively.

Our analysis showed that the I2 values were very high (89.6%, 93.5%, 94.7%, 96.6%, and 90.3%), suggesting that the data from the original studies are highly heterogeneous. Due to the high heterogeneity, we used a random-effects model to further describe qualitatively the data. Despite the high heterogeneity in the data, the P-value for these results is less than 0.01, indicating statistical significance of these data. A formal meta-analysis was not feasible due to the

heterogeneity in patient cohorts and primary endpoints among different studies.

Six of the studies analyzed also reported the analgesic drugs-induced changes in pain, however, due to the fact that details of the studies were not uniform, these effects could not be analyzed.

3.5. Safety

The safety results are summarized in Fig 3. Importantly, 4 studies reported cement leaks and 15 cement leak events occurred in 131 treatments in 94 patients (Fig. 4).

3.6. Changing trends

Pain change was a main point of interest, as these treatments have a potential use for pain management. Our analysis indicated a profound trend of decreasing levels of pain after treatment. Pain score showed a slight increase 24 weeks after treatment, yet pain levels were still much reduced compared to pre-treatment levels. The pain progress upon combined treatment can be also seen in the tendency chart shown in Fig. 5. Again, this analysis again indicated a profound decrease in pain levels after intervention, suggesting a clear benefit of the treatment in patients with bone metastases.

4. Discussion

To our knowledge, there are only very few systematic literature reviews assessing the analgesic effect of thermal ablation techniques combined with cementoplasty for bone metastasis pain management. The findings of this study suggested a significant decrease in pain scores after receiving combination therapy, and that these analgesic effect could last as long as 24 weeks after intervention or longer.

Severe pain is a common factor impacting negatively the quality of life of patients with bone metastases. Evidence suggested that bone invasion by malignant cells, as well as the subsequent release of pro-inflammatory cytokines, were the most important factors causing pain. This is mainly mediated by nerve stimulation, periosteal stretching, pathologic fractures, invisible microfractures, and compression of adjacent nerves and soft tissues [24, 25]. The vast majority of patients reported that the extensive pain had tremendous negative effects and further deteriorated their quality of life. Their mental wellbeing and sleep patterns, as well as their ability for physical activities, work, and social interaction were impacted [26, 27]. As was pointed out in the introduction of this paper, the primary goal of palliative care is to improve quality of life, as well as to reduce the risk of subsequent fractures.

It is now well established by several studies that thermal ablation is a safe option for cancer patients. Among thermal ablation methods, RFA, MWA and cryoablation are the most widely used ones [22, 28]. Studies suggested that it is effective for hepatocellular carcinoma and thoracic cancer [29–31], and that it is becoming a very attractive option for palliative care for patients with bone metastasis [25, 32, 33]. Thermal ablation not only had burn cancer structure and nerves but also resulted in reduced levels of interleukins, colony-stimulating factors, and TNF- α , which are considered to be a main cause of metastasis-induced bone pain [34–36]. This is why NSAIDs drugs could also be used for mild pain in cancer patients with bone metastases [37]. Thermal ablation was also used as a means to eliminate cancer cells, inhibit or delay cancer cell invasion and delay the progression of metastatic lesions. However, the treatment of metastatic cancer with thermal ablation could not improve bone stability. On the contrary, it has been suggested that it has the potential to weakened bone structure and inclined to fracture [38, 39].

The results showed a significant decrease in pain levels after combination therapy with percutaneous thermal ablation and cementoplasty. Nevertheless, the possible interference with analgesic drugs

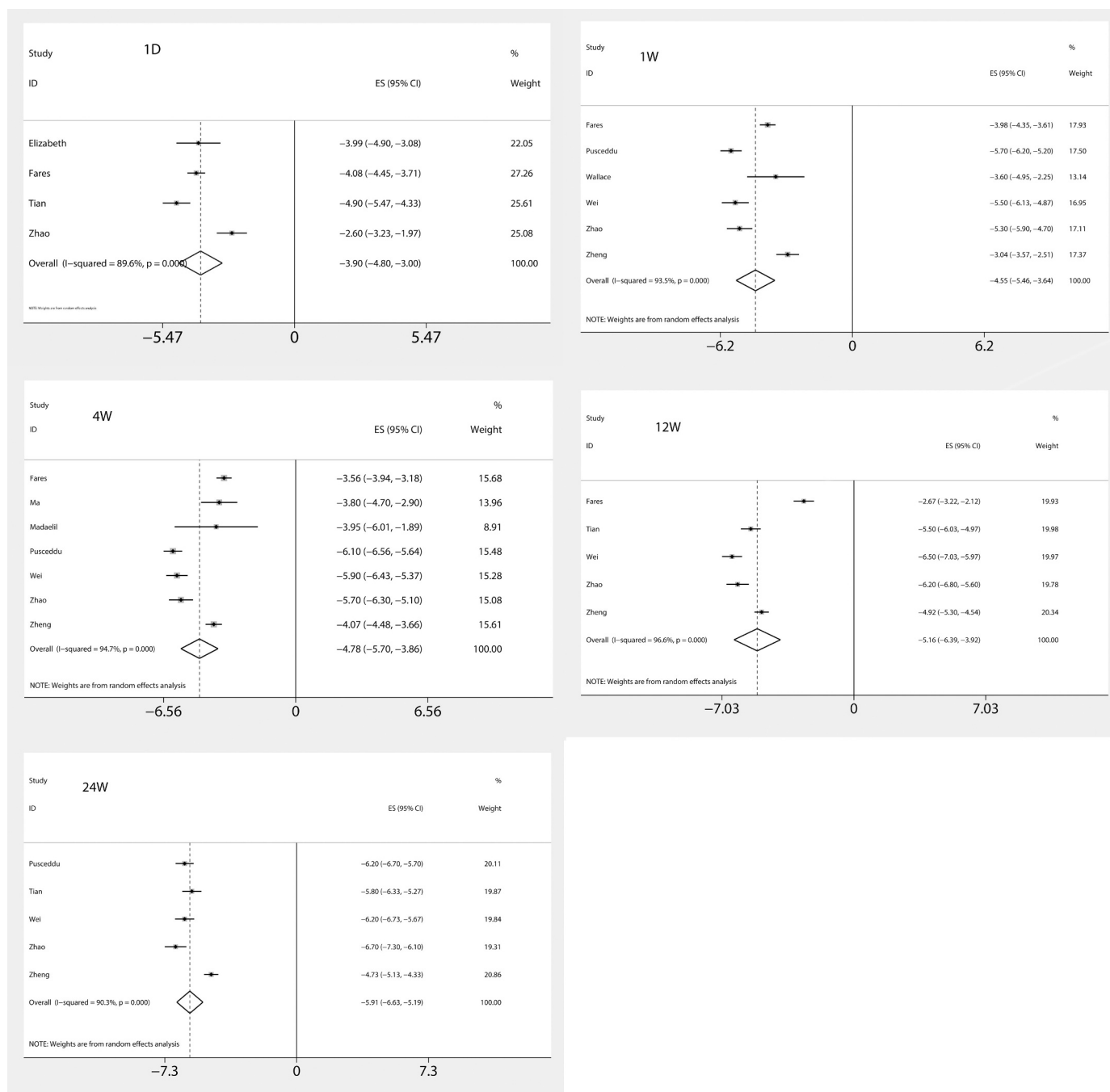


Fig. 2. Analysis of analgesic effect - forest plot. Analysis of changes in postoperative pain scores after 1 day, 1 week, 4 weeks, 12 weeks and 24 weeks of intervention.

could not be ruled out. Among all studies reviewed, only two patients were reported to be in need for higher doses of drugs for pain management, and many patients were already able to manage pain without analgesic drugs or other non-opioid palliative care. Pain induced by bone metastases has a considerable impact on the patients' quality of life and labor capacity, and it seriously affects patients' sleep patterns and quality, appetite, and general mental health. Combination therapy may alleviate cancer pain by affecting the cancer cells of the lesion and peripheral nerves. On the other hand, combination therapy may be reduced to the use of opioids and the level of AQA. Combination therapy is a very attractive palliative care method, especially in countries where strict opioids control legislation apply. Standardized analgesic treatment is an important part of clinical practice for cancer patients, as it is very effective in pain management and therefore in

improving patients' quality of life and behavior.

Regarding the safety of this intervention, only four studies reported risk of cement leakage. However, this needs to be interpreted with caution. The results here appear to support the assumption that the risk is low and acceptable and few seriously adverse reactions and deaths due to cement leakage. Bone cement is a common intervention used for bone injuries, fractures and bone cancer [40–42]. In a study conducted by Weill [43] showed that there were 75% of patients who still have reduced pain levels even three months after cementoplasty. Previous research has established that the analgesic mechanism of cementoplasty is presumptively based on the stabilization of intangible microfractures. Moreover, the heating effect of the cement can lead to damage in adjacent nerves and cancer lesions [44, 45]. Fractures could reduce the quality of life and increased hospitalization time and nursing cost.

Table 1
Characteristics of the eligible studies.

Author	Year	Country	No. of patients	No. of tumor	Age (mean)	Gender		Tumor location	Treatment method	Pre-procedure mean pain score
						Male	Female			
Elizabeth	2016	Canada	26	39	69.5	15	11	pelvis/ spine	RAF + cementoplasty	8.4 (VAS)
Fares	2018	Egypt	30	30	48.6	18	12	pelvis/femur/humerus /radius	RFA + cementoplasty	7.2 (VAS)
Hoffmann	2008	Germany	22	28	64	15	7	spine/sacrum/pelvis / femur/tibia	RFA + cementoplasty	8.5 (VAS)
Ma	2017	USA	45	75	63.6	18	27	upper extremity/ shoulder/ humerus / ribs / spine / pelvis / soft tissues	cryoablation/ MWA/RFA + cementoplasty	7.5 (NRS)
Madaeil	2016	USA	6	6	57.5	3	3	spine	RFA + cementoplasty	7.5 (NRS)
Pusceddu	2015	Italy	35	37	64	16	19	spine /femur/ pelvis	MWA + cementoplasty	6.8 (VAS)
Tian	2014	China	38	54	52.6	20	18	Ilium/acetabulum/femur/ischium/ tibia	RAF + cementoplasty	7.1 (VAS)
Tyler	2017	Canada	48	-	77.5	36	12	pelvis	cryoablation + cementoplasty	7.9 (NRS)
Wallace	2015	USA	11	-	57.4	7	4	pelvis	RFA + cementoplasty	7.0 (NRS)
Wei	2015	China	26	33	69.4	15	11	Ilium/acetabulum/femur/ischium/ tibia/ clavicle/ sacrum	MWA + cementoplasty	7.4 (VAS)
Zhao	2018	China	16	34	67.3	4	12	scapula/ sacrum/ spine	RFA + cementoplasty	8.7 (VAS)
Zheng	2014	China	26	38	59.3	12	14	spine	RFA + cementoplasty	7.7 (VAS)

RFA = radiofrequency ablation; MWA = microwave ablation; VAS = Visual Analogue Scale/Score; NRS = numerical rating scale; - = not clear.

Table 2
The methodological quality of eligible trials (MINORS).

Study	A	B	C	D	E	F	G	H	Total
Elizabeth	2	2	2	2	0	0	2	2	12
Fares	2	2	2	2	0	1	2	2	13
Hoffmann	2	2	2	2	0	1	2	2	13
Ma	2	2	2	2	0	1	2	2	13
Madaeil	2	2	2	2	0	1	2	2	13
Pusceddu	2	2	2	2	0	2	2	2	14
Tian	2	2	2	2	0	2	2	2	14
Tyler	2	2	2	1	0	0	2	2	11
Wallace	2	2	2	1	0	1	2	2	12
Wei	2	2	2	2	0	2	2	2	14
Zhao	2	2	2	2	0	2	2	2	14
Zheng	2	2	2	2	0	2	2	2	14

A. *A clearly stated aim*: the question addressed should be precise and relevant in the light of available literature; B. *Inclusion of consecutive patients*: all patients potentially fit for inclusion (satisfying the criteria for inclusion) have been included in the study during the study period (no exclusion or details about the reasons for exclusion); C. *Prospective collection of data*: data were collected according to a protocol established before the beginning of the study; D. *Endpoints appropriate to the aim of the study*: unambiguous explanation of the criteria used to evaluate the main outcome which should be in accordance with the question addressed by the study. Also, the endpoints should be assessed on an intention-to-treat basis; E. *Unbiased assessment of the study endpoint*: blind evaluation of objective endpoints and double-blind evaluation of subjective endpoints. Otherwise the reasons for not blinding should be stated; F. *Follow-up period appropriate to the aim of the study*: the follow-up should be sufficiently long to allow the assessment of the main endpoint and possible adverse events; G. *Loss to follow up less than 5%*: all patients should be included in the follow up. Otherwise, the proportion lost to follow up should not exceed the proportion experiencing the major endpoint; H. *Prospective calculation of the study size*: information about the size of detectable difference of interest with a calculation of 95% confidence interval, according to the expected incidence of the outcome event, and information about the level for statistical significance and estimates of power when comparing the outcomes.

Cement can strengthened the bone structure to prevent the risk of fracture and ensure the mobility capability for the patient [46]. In contrast, despite that analgesic drugs and thermal ablation have analgesic effects, they cannot prevent pathological bone fractures. Fractures of femur and spine may cause paralysis, and patients may lose their mobility [47]. Even though cement has several beneficial effects, it also entails some risks. Cement leakage is a common phenomenon during cementoplasty. In the majority of patients who had received therapy small cement emboli in their bodies could be found, even if

these emboli do not cause clinical manifestations [48]. The only way to identify such small circulating cement emboli is whole-body imaging examination, which is difficult and increased the cost of treatment. There are observed difference in the risk between the heart and pulmonary in some study was significant. Despite the fact that the risk of intracardiac cement embolism is small (3.9%) and symptomatic complications are rare (0.3%) [49], the incidence of cement lung embolism is significantly higher, ranging from 2.1% to 75% [50–52]. In one survey, small cement emboli were found in approximately 10% of the patients, as identified by chest CT examination [53]. Fortunately, it is believed that most small cement pulmonary embolisms do not cause serious harm to the patients [53]. In spinal bone metastases, cement leaks into a variety of anatomical compartments including pre-vertebral soft tissue (6% – 52.5%) have been reported. In addition, cement could also leak into the intervertebral disc, prevertebral veins, spinal canal, and epidural veins [54]. Cement entering the venous system and the spinal canal is the major potential risk [55,56]. In other parts of the body the leakage of the adhesive material entails less risks to damage the nerve, albeit it is more likely to enter the circulatory system, as embolization of the inferior vena cava or pulmonary artery. This may lead to the sudden death of the patient. Unexpected adhesive particles may compress the surrounding blood vessels, which can cause nerve damage and insufficient blood supply to the vertebral body. Clinicians can reduce the risk of cement leakage through strict patient selection criteria, radiographic guidance and individualized treatment strategies. The danger of cement emboli does not depend solely on its size and shape, as small emboli can also have serious consequences. Our analysis showed that the risk of leakage in combination therapy is significantly lower (only 10%). There are two possible reasons for this phenomenon: 1. Only four studies were analyzed and the results were highly skewed. 2. Blood vessels were destroyed by ablation and edema zone appeared in the surrounding tissues, which may have reduced the probability of cement embolus escape. At the same time, due to the damage of local nerves cause by thermal ablation, the cooperation of the patient during the injection of cement may also have been a reason for lower cement leakage.

Overall, combining thermal ablation and cementoplasty appears to be an attractive therapeutic intervention to manage pain. Thermal ablation is associated with an increased risk of fracture [57]. As a binder that can be hardened and shaped quickly, bone cement can be used to fill the ablated area after thermal ablation, it could enhance ablation efficacy and reduce the risk of subsequent fractures [58,59]. Notwithstanding RFA, MWA or cryoablation alone can relieve pain almost immediately, they cannot strengthen the bone damage caused by cancer

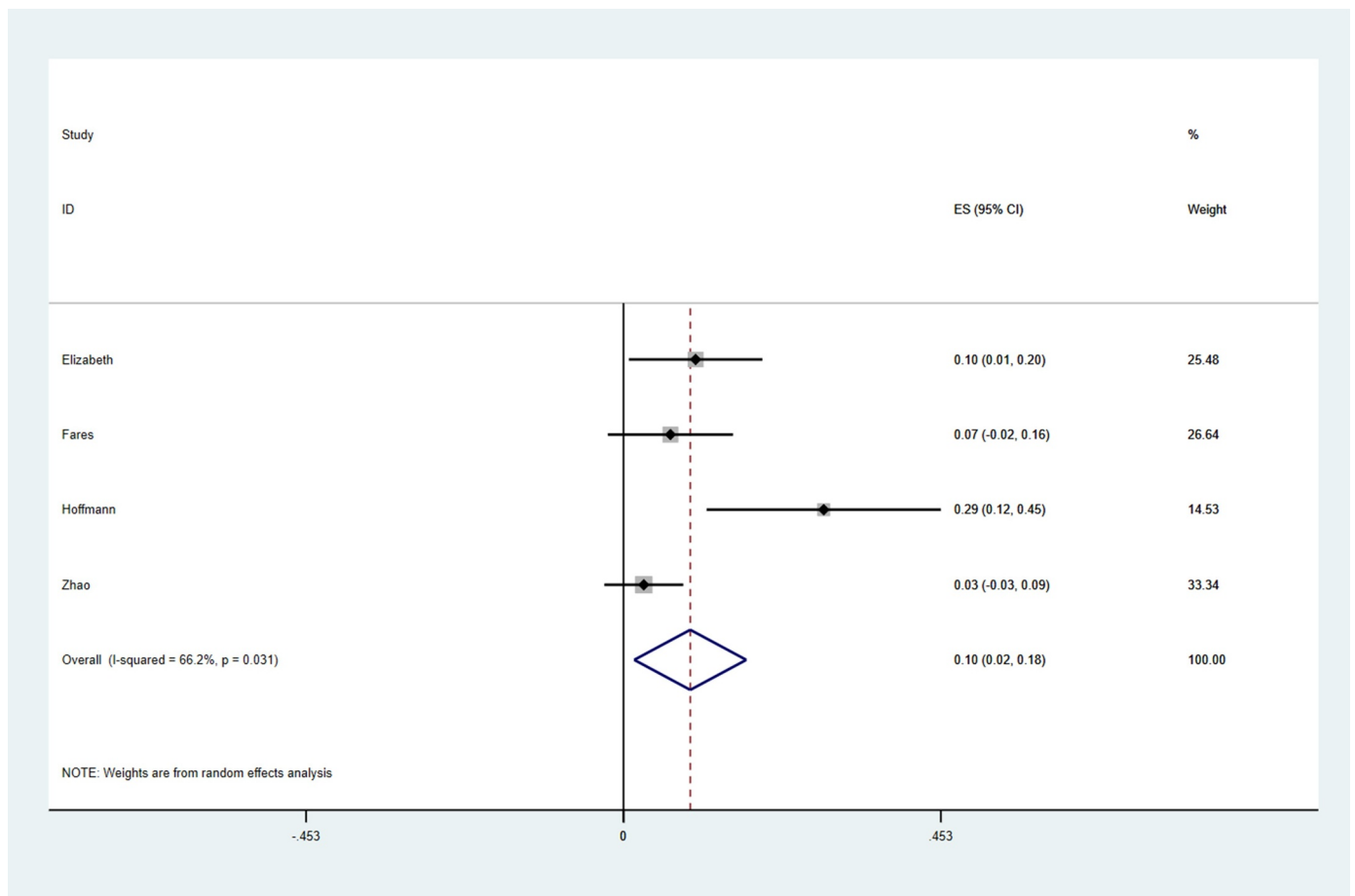


Fig. 3. Analysis of cement leakage risk. The analysis of the treatment of 131 lesions in 94 patients with bone metastases. There are some cement leaks in the combination therapy, but the incidence is very low and acceptable.

cell infiltration [14]. Cementoplasty, however, has the ability to stabilize bone microfractures, strengthened the bone lesion, and gain a "windfall": binder destroyed the surrounding nerves. Thermal ablation prior to cementoplasty damaged the cancer lesions. Due to tumor tissue being obliterated and the density of surrounding was change; cement could spread more easily in lesions. For these reasons, the combination of both therapies may have a synergistic effect. Our analysis revealed that the pain index was still far below the pain levels before treatment, even 24 weeks post-intervention. Moreover, we found several interesting reports [14,60,61] suggesting that injection of cement was more fluently after thermal ablation, and it displays statistically significant lower rates of leaks. Taking into consideration these results, it can be concluded that the combination of thermal ablation and cementoplasty is a safe and effective way to manage cancer-related pain [58,62]. Considering the long-lasting analgesic effect and lower risk of serious complications, percutaneous thermal ablation combined with cementoplasty is an attractive means of palliative care.

5. Limitations

There are some limitations to this study. Firstly, the inclusion of retrospective studies without a control group, which limited access to the clinical data and responses of patients, such as the requirements for analgesic drug, mobility change, and quality of life change. Another limitation is the disparate patient group. The patients included in our study had different primary lesions, as well as bony metastasis lesions. The third limitation of our study was the long-term follow-up. Only very few patients had a follow-up assessment 24 weeks post-treatment and there was no follow-up assessment of pain after that.

Another serious weakness of this study is the lack of analysis of post-operative quality of life. Only two studies have assessed the quality of life of the patients, and they only one provided EORTC QLQ-C30 (European Organization for Research and Treatment of Cancer Quality of Life Questionnaire) scores. Analgesic effects and fracture prevention exert significant effects on patients' quality of life. The lack of information has therefore undermined the value of this study. We expect more studies in the future to evaluate patients' quality of life.

Although several reports indicate significant improvements in pain management, larger long-term prospective studies and control experiments are necessary to demonstrate the benefits of the combination of the thermal ablation and cementoplasty.

6. Conclusions

Percutaneous thermal ablation combined with cementoplasty is a safe and effective potential palliative intervention for cancer patients with bone metastases.

Funding

This work was supported by the Natural Science Foundation of Shandong Province (No. ZR2017MH095) and Key R&D Program from Department of Science and Technology of Shandong Province (No. 2016CYJS01A03).

Declaration of Competing Interest

The authors declare that they have no competing interests.

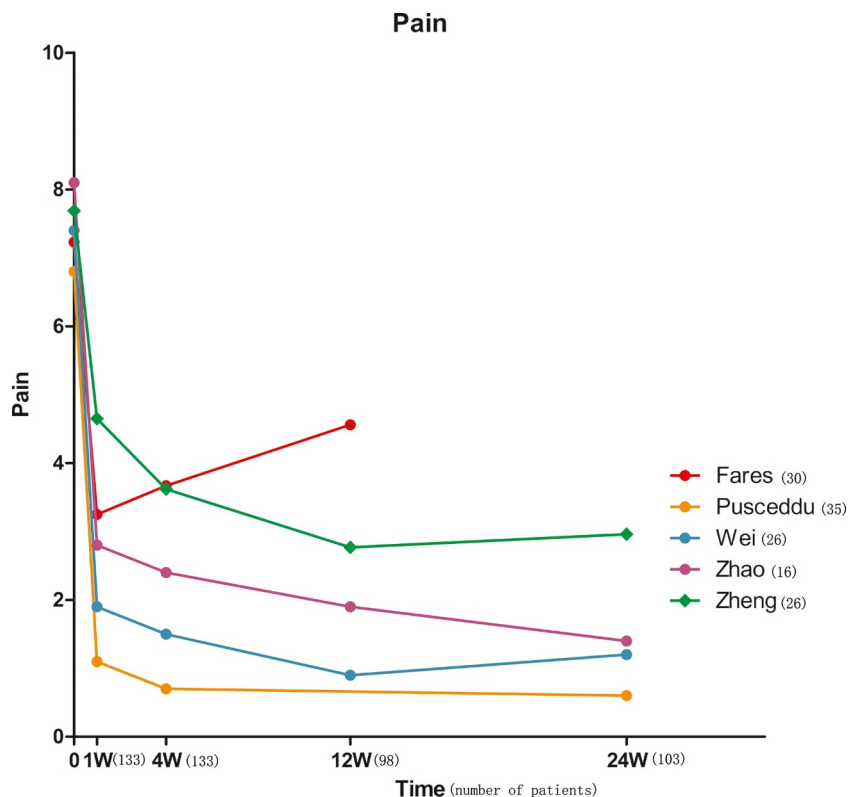


Fig. 4. Trend of long-term pain after treatment. Long-term follow-up studies showed that patients' pain scores declined rapidly and remained significantly lower even 24 weeks after treatment.

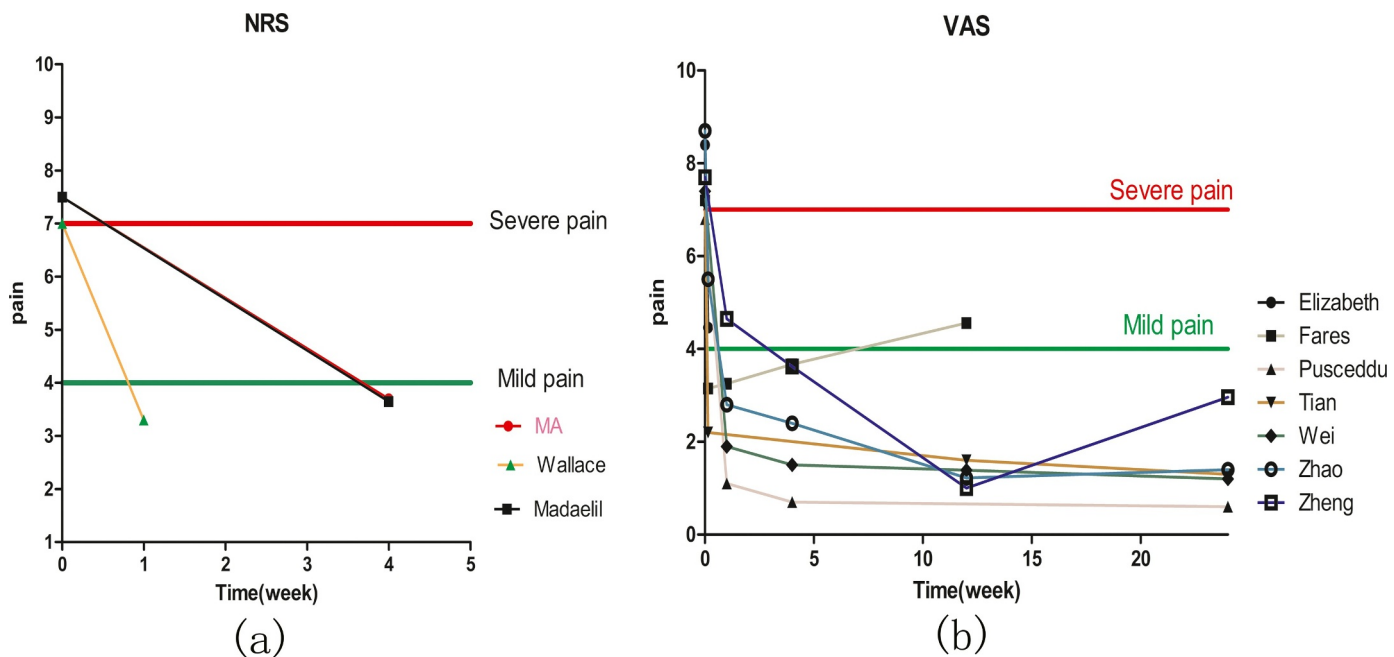


Fig. 5. The effect of pain changes on patients after combined treatment. (a) NRS: Mild pain = doesn't disrupt sleep; Severe pain = completely interferes with sleep. (b) VAS: Mild pain = not disrupt sleep; Severe pain = disrupts sleep and appetite. Pain: 0 to 3 = mild pain, 4 to 6 = moderate pain, and 7 to 10 = severe pain.

References

[1] J. Ahmedin, et al., Annual report to the nation on the status of cancer, 1975-2005, featuring trends in lung cancer, tobacco use, and tobacco control, *J. Natl. Cancer Inst.* 100 (23) (2008) 1672–1694.

[2] R.E. Coleman, Clinical features of metastatic bone disease and risk of skeletal morbidity, *Clin. Cancer Res.* 12 (2006) 6243s–6249s.

[3] D.J. Husband, Malignant spinal cord compression: prospective study of delays in referral and treatment, *BMJ* 317 (7150) (1998) 18–21.

[4] M.H. Priemel, et al., Bone tumours of the clavicle: histopathological, anatomical and epidemiological analysis of 113 cases, *J. Bone Oncol.* 16 (2019) 100229.

[5] K.L. Dorrepaal, Pain experience and pain management among hospitalized cancer patients. A clinical study, *Cancer* 63 (3) (1989) 593–598.

[6] C. Durante, et al., Long-term outcome of 444 patients with distant metastases from papillary and follicular thyroid carcinoma: benefits and limits of radioiodine therapy, *J. Clin. Endocrinol. Metab.* 91 (8) (2006) 2892–2899.

[7] K. Cetin, et al., Bone metastasis, skeletal-related events, and mortality in lung

- cancer patients: a danish population-based cohort study, *Lung Cancer* 86 (2) (2014) 247–254.
- [8] K. Fizazi, et al., Denosumab versus zoledronic acid for treatment of bone metastases in men with castration-resistant prostate cancer: a randomised, double-blind study, *Lancet* 377 (9768) (2011) 813–822.
- [9] M. Ueno, et al., CT temporal subtraction method for detection of sclerotic bone metastasis in the thoracolumbar spine, *Eur. J. Radiol.* 107 (2018) 54–59.
- [10] Y. Du, et al., Fusion of metabolic function and morphology: sequential [18F] fluorodeoxyglucose positron-emission tomography/computed tomography studies yield new insights into the natural history of bone metastases in breast cancer, *J. Clin. Oncol.* 25 (23) (2007) 3440–3447.
- [11] T. Hamaoka, et al., Bone imaging in metastatic breast cancer, *J. Clin. Oncol.* 22 (14) (2004) 2942–2953.
- [12] Elizabeth, et al., Initial single center experience: radiofrequency ablation assisted vertebroplasty and osteoplasty using a bipolar device in the palliation of bone metastases, *Ann. Palliat. Med.* 6 (2) (2017) 118–124.
- [13] A. Fares, et al., Combined percutaneous radiofrequency ablation and cementoplasty for the treatment of extraspinal painful bone metastases: a prospective study, *J. Egypt Natl. Canc. Inst.* 30 (3) (2018) 117–122.
- [14] R.T. Hoffmann, et al., Radiofrequency ablation in combination with osteoplasty in the treatment of painful metastatic bone disease, *J. Vasc. Interv. Radiol.* 19 (3) (2008) 419–425.
- [15] Y. Ma, et al., Percutaneous Image-Guided Ablation in the Treatment of Osseous Metastases from Non-small Cell Lung Cancer, *Cardiovasc. Intervent. Radiol.* 41 (5) (2018) 726–733.
- [16] T.P. Madaelil, Radiofrequency ablation alone or in combination with cementoplasty for local control and pain palliation of sacral metastases: preliminary results in 11 patients, *Skeletal Radiol.* 45 (9) (2016) 1213–1219.
- [17] C. Pusceddu, et al., Combined microwave ablation and cementoplasty in patients with painful bone metastases at high risk of fracture, *Cardiovasc. Intervent. Radiol.* 39 (1) (2016) 74–80.
- [18] Q.H. Tian, et al., Combination radiofrequency ablation and percutaneous osteoplasty for palliative treatment of painful extraspinal bone metastasis: a single-center experience, *J. Vascular. Intervent. Radiol.* 25 (7) (2014) 1094–1100.
- [19] T.M. Coupal, et al., The hopeless case? palliative cryoablation and cementoplasty procedures for palliation of large pelvic bone metastases, *Pain Physician* 20 (7) (2017) E1053–E1061.
- [20] A.N. Wallace, et al., Combination acetabular radiofrequency ablation and cementoplasty using a navigational radiofrequency ablation device and ultrahigh viscosity cement: technical note, *Skeletal Radiol.* 45 (3) (2016) 401–405.
- [21] Z. Wei, et al., Computed tomography-guided percutaneous microwave ablation combined with osteoplasty for palliative treatment of painful extraspinal bone metastases from lung cancer, *Skeletal Radiol.* 44 (10) (2015) 1485–1490.
- [22] L. Zheng, et al., A preliminary study of the safety and efficacy of radiofrequency ablation with percutaneous kyphoplasty for thoracolumbar vertebral metastatic tumor treatment, *Med. Sci. Monit.* 20 (2014) 556–563.
- [23] W. Zhao, et al., Palliative pain relief and safety of percutaneous radiofrequency ablation combined with cement injection for bone metastasis, *Jpn. J. Clin. Oncol.* 48 (8) (2018) 753–759.
- [24] K.O. Rove, Evolution of treatment options for patients with crpc and bone metastases: bone-targeted agents that go beyond palliation of symptoms to improve overall survival, *Oncology (Williston Park, N.Y.)* 25 (14) (2011) 1362–1370 1375–81, 1387.
- [25] A.S. Gdowski, Current concepts in bone metastasis, contemporary therapeutic strategies and ongoing clinical trials, *J. Exp. Clin. Cancer Res.* 36 (1) (2017) 108.
- [26] B.H. McCarberg, et al., The impact of pain on quality of life and the unmet needs of pain management: results from pain sufferers and physicians participating in an internet survey, *Am. J. Ther.* 15 (4) (2008) 312–320.
- [27] E. Prommer, Palliative oncology: denosumab, *Am. J. Hosp. Palliat. Care* 32 (5) (2015) 568–572.
- [28] C. Serra, et al., Assessment of radiofrequency ablation efficacy for hepatocellular carcinoma by histology and pretransplant radiology, *Liver Transplant. Soc.* 25 (1) (2019) 88–97.
- [29] W. Liu, et al., Microwave vs radiofrequency ablation for hepatocellular carcinoma within the milan criteria: a propensity score analysis, *Aliment. Pharmacol. Ther.* 48 (6) (2018) 671–681.
- [30] D.R. Wahl, et al., Outcomes after stereotactic body radiotherapy or radiofrequency ablation for hepatocellular carcinoma, *J. Clin. Oncol.* 34 (5) (2016) 452–459.
- [31] Y.D. Sun, et al., Efficacy of radiofrequency ablation and microwave ablation in the treatment of thoracic cancer: a systematic review and meta-analysis, *Thorac. Cancer* 10 (3) (2019) 543–550.
- [32] M.P. Goetz, et al., Percutaneous image-guided radiofrequency ablation of painful metastases involving bone: a multicenter study, *J. Clin. Oncol.* 22 (2) (2004) 300–306.
- [33] D. Stella, et al., Metastatic bone disease: pathogenesis and therapeutic options: update on bone metastasis management, *J. Bone Oncol.* 15 (2019) 004–4.
- [34] M. Schweizerhof, et al., Hematopoietic colony-stimulating factors mediate tumor-nerve interactions and bone cancer pain, *Nat. Med.* 15 (7) (2009) 802–807.
- [35] J. Zhang, et al., Neuroinflammation and central PI3K/Akt/mTOR signal pathway contribute to bone cancer pain, *Mol. Pain* 15 (2019) 1744806919830240undefined.
- [36] S. Liu, et al., Hedgehog signaling contributes to bone cancer pain by regulating sensory neuron excitability in rats, *Mol. Pain* 14 (2018) 1744806918767560undefined.
- [37] J.A. Paice, The management of cancer pain, *CA Cancer J. Clin.* 61 (3) (2011) 157–182.
- [38] A.N. Kurup, et al., Avoiding complications in bone and soft tissue ablation, *Cardiovasc. Intervent. Radiol.* 40 (2) (2017) 166–176.
- [39] E.F. Dierselhuys, et al., Hip fracture after radiofrequency ablation therapy for bone tumors: two case reports, *Skeletal Radiol.* 39 (11) (2010) 1139–1143.
- [40] J. Berenson, et al., Balloon kyphoplasty versus non-surgical fracture management for treatment of painful vertebral body compression fractures in patients with cancer: a multicentre, randomised controlled trial, *Lancet Oncol.* 12 (3) (2011) 225–235.
- [41] W. Clark, et al., Safety and efficacy of vertebroplasty for acute painful osteoporotic fractures (VAPOUR): a multicentre, randomised, double-blind, placebo-controlled trial, *Lancet* 388 (10052) (2016) 1408–1416.
- [42] R. Buchbinder, et al., A randomized trial of vertebroplasty for painful osteoporotic vertebral fractures, *The New England J. Med.* 361 (6) (2009) 557–568.
- [43] A. Weill, et al., Spinal metastases: indications for and results of percutaneous injection of acrylic surgical cement, *Radiology* 199 (1) (1996) 241–247.
- [44] G.C. Anselmetti, et al., Temperature measurement during polymerization of bone cement in percutaneous vertebroplasty: an in vivo study in humans, *Cardiovasc. Intervent. Radiol.* 32 (3) (2009) 491–498.
- [45] H. Deramond, Temperature elevation caused by bone cement polymerization during vertebroplasty, *Bone* 25 (1999) 175–215.
- [46] X.W. Liu, et al., Comparison of percutaneous long bone cementoplasty with or without embedding a cement-filled catheter for painful long bone metastases with impending fracture, *Eur. Radiol.* 27 (1) (2017) 120–127.
- [47] M.B.D.R. Oliveira, et al., Pathological fractures due to bone metastases from lung cancer: risk factors and survival, *Acta Ortop. Bras.* 26 (6) (2018) 388–393.
- [48] A. Venmans, et al., Percutaneous vertebroplasty and pulmonary cement embolism: results from vertos II, *AJNR Am. J. Neuroradiol* 31 (8) (2010) 1451–1453.
- [49] S. Fadili Hassani, et al., Intracardiac cement embolism during percutaneous vertebroplasty: incidence, risk factors and clinical management, *Eur. Radiol.* 29 (2) (2019) 663–673.
- [50] L.J. Wang, et al., Pulmonary cement embolism associated with percutaneous vertebroplasty or kyphoplasty: a systematic review, *Orthop. Surg.* 4 (3) (2012) 182–189.
- [51] T. Chong, et al., Pulmonary cement embolism after kyphoplasty, *Pain Practice* 11 (6) (2011) 570–573.
- [52] M. Agko, et al., Prevention of cardiopulmonary embolization of polymethylmethacrylate cement fragment after kyphoplasty with insertion of inferior vena cava filter, *J. Vasc. Surg.* 51 (1) (2010) 210–213.
- [53] M.T. Luetmer, et al., Asymptomatic and unrecognized cement pulmonary embolism commonly occurs with vertebroplasty, *AJNR Am. J. Neuroradiol.* 32 (4) (2011) 654–657.
- [54] S. D'Errico, Fatal cardiac perforation and pulmonary embolism of leaked cement after percutaneous vertebroplasty, *J. Forensic Leg. Med.* 63 (undefined) (2019) 48–51.
- [55] M. Grelat, et al., Rare complication of percutaneous technique: intradural cement leakage and its surgical treatment, *World Neurosurg.* 118 (2018) 97.
- [56] A. Saracen, Complications of percutaneous vertebroplasty: an analysis of 1100 procedures performed in 616 patients, *Medicine (Baltimore)* 95 (24) (2016) e3850.
- [57] J.P. Guenette, et al., Solitary painful osseous metastases: correlation of imaging features with pain palliation after radiofrequency ablation—a multicenter american college of radiology imaging network study, *Radiology* 268 (3) (2013) 907–915.
- [58] A.N. Wallace, Radiofrequency ablation and vertebral augmentation for palliation of painful spinal metastases, *J. Neurooncol.* 124 (1) (2015) 111–118.
- [59] J.D. Prologo, et al., Ablation zones and weight-bearing bones: points of caution for the palliative interventionalist, *J. Vasc. Interv. Radiol.* 25 (5) (2014) 769–775 e2.
- [60] P.L. Munk, et al., Combined cementoplasty and radiofrequency ablation in the treatment of painful neoplastic lesions of bone, *J. Vasc. Interv. Radiol.* 20 (7) (2009) 903–911.
- [61] M.D. Lane, et al., Combination radiofrequency ablation and cementoplasty for palliative treatment of painful neoplastic bone metastasis: experience with 53 treated lesions in 36 patients, *Skeletal Radiol.* 40 (1) (2011) 25–32.
- [62] M.R. Callstrom, et al., Painful metastases involving bone: feasibility of percutaneous CT- and US-guided radio-frequency ablation, *Radiology* 224 (1) (2002) 87–97.