

[CASE REPORT]

Efficacy and Safety of Chemotherapy Following Anti-PD-1 Antibody Therapy for Gastric Cancer: A Case of Sclerosing Cholangitis

Masashi Kono, Toshiharu Sakurai, Kazuki Okamoto, Shou Masaki, Tomoyuki Nagai, Yoriaki Komeda, Ken Kamata, Kosuke Minaga, Kentarou Yamao, Mamoru Takenaka, Tomohiro Watanabe, Naoshi Nishida and Masatoshi Kudo

Abstract:

Immunotherapy targeting programmed cell death-1 (PD-1) signaling is becoming the standard of care for advanced gastric cancer. We herein report a patient with gastric adenocarcinoma with peritoneal dissemination who was treated with nab-paclitaxel and ramucirumab following nivolumab and developed sclerosing cholangitis. Endoscopic retrograde cholangiography showed irregular narrowing and widening of the entire intrahepatic biliary system. Intriguingly, the patient receiving second-line chemotherapy with nab-paclitaxel plus ramucirumab prior to being administered nivolumab, however, he had experienced progressive disease. Thereafter, the administration of fourth-line chemotherapy with nab-paclitaxel and ramucirumab following nivolumab resulted in a clinical response. Nivolumab may enhance the efficacy of the subsequent chemotherapy regimens but also induce sclerosing cholangitis.

Key words: ramucirumab, nab-paclitaxel, nivolumab, immune checkpoint, cholecystitis

(Intern Med 58: 1263-1266, 2019)

(DOI: 10.2169/internalmedicine.1981-18)

Introduction

Immune checkpoint inhibitors targeting the programmed cell death-1 (PD-1) signaling pathway are revolutionary anti-cancer agents that are being rapidly approved for different malignancies, including gastric cancer. PD-1 blockade induces T cell cytotoxic immune responses against cancer tissue. Nivolumab is a humanized immunoglobulin G4 monoclonal antibody that binds to the PD-1 receptor expressed on T cells and blocks its interaction with the PD-1 ligands on tumor cells. The blockade of the PD-1 signaling pathway with nivolumab was found to induce a remarkable clinical responses in patients with gastric cancer (1). Anti-PD-1 therapy has elicited durable anti-tumor responses and tumor regression off-therapy in a subset of patients. These agents are not directly tumoricidal but work indirectly by activating anti-tumor immunity, which leads to delayed response kinet-

ics (2).

However, immune checkpoint inhibition can trigger effector T cells against self-antigens as well as tumor antigens, resulting in immune-related toxicities in normal organs, referred to as immune-related adverse events (irAEs). Like immune-related tumor responses, irAEs can present at any time, including after the cessation of immune checkpoint blockade therapy, and may wax and wane over time (3).

We herein report the first case of nivolumab-induced sclerosing cholangitis in a patient with gastric cancer.

Case Report

A 69-year-old woman was referred to our hospital because of epigastric discomfort. She was diagnosed with gastric cancer with peritoneal dissemination. Her history was unremarkable except for silent gallstones. Her family history was negative for liver disease or inflammatory bowel dis-

Table. Serum Laboratory Values on Admission and before the Event of Cholangitis.

Laboratory test	On admission	Before the event
Alkaline phosphatase (IU/L)	5,066	309
Aspartate aminotransferase (IU/L)	454	17
Bilirubin (total/direct) (mg/dL)	15.9/12.0	0.4/0.2
Gamma globulin (IgG/IgG4) (mg/dL)	1,051/20.2	NE
Immunoglobulin M (mg/dL)	91	NE
Albumin (g/dL)	2.7	3.1
Prothrombin time (seconds)	10.4	11.2
C-reactive protein (mg/dL)	2.57	1.03
White blood cell count (μ L)	14,670	5,620
Autoantibodies (antinuclear, antimitochondrial)	negative	NE
Anti-human immunodeficiency virus antibody	negative	NE

NE: not evaluated

ease.

The patient started chemotherapy with S-1 (80 mg/day, Day 1-14) and oxaliplatin (100 mg/m², Day 1) as first-line therapy, and then she was treated with nab-paclitaxel (100 mg/m², Day 1, 8, and 15) and ramucirumab (8 mg/kg, Day 1 and 15) as second-line chemotherapy. However, the disease progressed. She was taking nonsteroidal anti-inflammatory drugs but not narcotics for epigastric pain. Two months before admission, she commenced nivolumab treatment (3 mg/kg every 2 weeks). Despite two cycles of anti-PD-1 therapy, paracentesis was performed every two weeks due to refractory ascites. The patient was adamant that she received fourth-line chemotherapy with nab-paclitaxel and ramucirumab, which was the same as the second-line regimen. Thereafter, her abdominal distention started improving, and the patient had no need for paracentesis. Computed tomography (CT) revealed the reduction of ascites (Fig. 1), and decreased levels of tumor markers, such as CA19-9 (from 257 to 155 U/mL) and CA125 (from 169 to 113 U/mL), were also found. These data indicated that chemotherapy following nivolumab had achieved an anti-cancer effect.

After the second cycle of the fourth-line chemotherapy following PD-1 blockade, she was admitted to our hospital with a complaint of jaundice. On admission, blood tests revealed markedly elevated liver function tests in a cholestatic pattern and increased levels of C-reactive protein (Table). There was no evidence of underlying viral, metabolic, or autoimmune liver disease. Endoscopic retrograde cholangiography showed stenosis in the common hepatic duct and irregular narrowing and widening of the entire intrahepatic bile ducts (Fig. 2). Contrast-enhanced CT, abdominal ultrasound, endoscopic ultrasonography, and magnetic resonance imaging revealed intrahepatic cholestasis and wall thickening of the gallbladder (Fig. 1). No tumors or stones were found in the liver or bile ducts.

Based on the above findings, nivolumab-related sclerosing cholangitis was suspected. Following antibiotic therapy and endoscopic intervention, there was a substantial decrease in

cholestasis.

Discussion

Sclerosing cholangitis is a rare disease, characterized by bile duct inflammation, fibrosis, and strictures (4, 5). The present patient showed beading and irregular narrowing and widening of the entire intrahepatic biliary system, including the right and left hepatic ducts, which is a characteristic radiological feature of sclerosing cholangitis.

Nearly 70% of patients with primary sclerosing cholangitis (PSC) have coexisting inflammatory bowel disease (6). Our patient had no history of inflammatory bowel disease. Patients with PSC should show biochemical evidence of chronic cholestasis; as such, the diagnosis of PSC was unlikely in our case. The patient had no pus in the bile duct, and the serum procalcitonin level was within its normal range, suggesting that bacterial cholangitis was also unlikely. However, viral infection, such as cytomegalovirus infection, which augments the expression of the HLA antigen on the bile duct epithelium, may stimulate the immune response, leading to destruction of the bile ducts (7).

Biliary abnormalities found in ischemia, gallstones, or malignancy are usually confined to limited areas of the bile ducts, which completely contrasts with the findings observed in this case. Indeed, contrast-enhanced CT and endoscopic ultrasonography showed no stones or tumors in the liver or bile ducts. The time course of the disease suggests a causal link with nab-paclitaxel, anti-angiogenic agent ramucirumab, or nivolumab. Nivolumab is most likely to be the causal agent because nab-paclitaxel and ramucirumab were previously well tolerated when they were used as second-line therapy in our patient before third-line nivolumab treatment. In addition, previous reports of nivolumab-induced cholangitis have mentioned wall thickening of the gallbladder and cholangitis developing a few months after discontinuation of nivolumab (8-10), which is consistent with our case.

We encountered a rare case of sclerosing cholangitis induced after the cessation of anti-PD-1 therapy. While cases

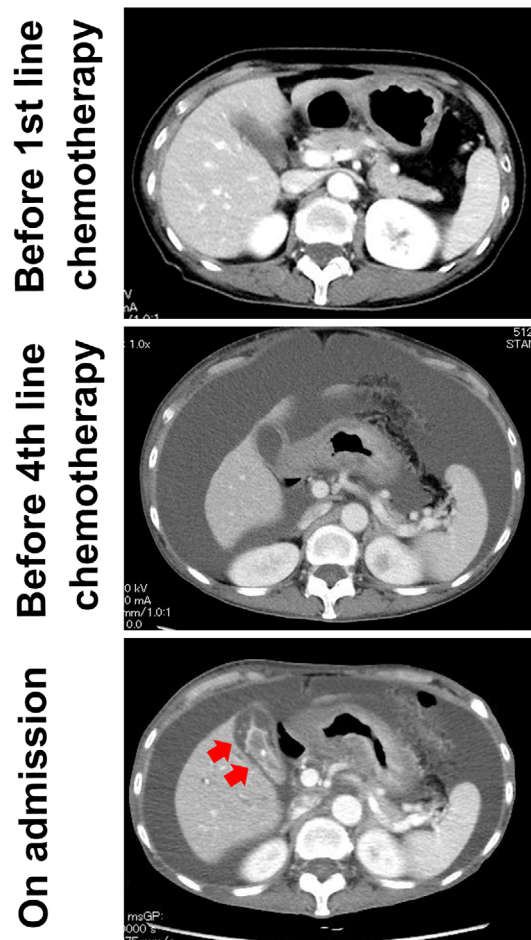


Figure 1. Diagnostic imaging of the liver. Contrast-enhanced computed tomography (CT) on admission showed diffuse intrahepatic cholestasis and normal-appearing parenchyma with no signs of malignant infiltration of the liver. Wall thickening of the gall bladder was apparent (arrows). Ascites was reduced on admission compared with before fourth-line chemotherapy.

of nivolumab-related cholangitis with abnormalities in either intra- or extra-hepatic bile ducts have been reported in lung cancer (8-12), this is the first report of diffuse biliary involvement in gastric cancer. In our case, cholangitis developed during chemotherapy with nab-paclitaxel and ramucirumab following anti-PD-1 therapy. Cholangitis similarly developed after cessation of nivolumab in one previous case (10). It has been reported that treatment with the anti-angiogenic agent bevacizumab caused sclerosing cholangitis in a patient with colorectal carcinoma after surgical treatment of liver metastases (13). Ischemia may be induced by prothrombotic antibody-mediated clot formation in the vessels supplying the bile ducts (14). Chemotherapy, including nab-paclitaxel, induced cholangitis in a patient with metastatic pancreatic cancer (15). In addition to nivolumab, nab-paclitaxel and ramucirumab might be involved in the pathogenesis of sclerosing cholangitis.

Nivolumab is known to have a long-lasting anti-cancer effect referred to as an immune-related response (16). In our case, anti-PD-1 therapy may have enhanced the efficacy of the subsequent chemotherapy by an immune-mediated

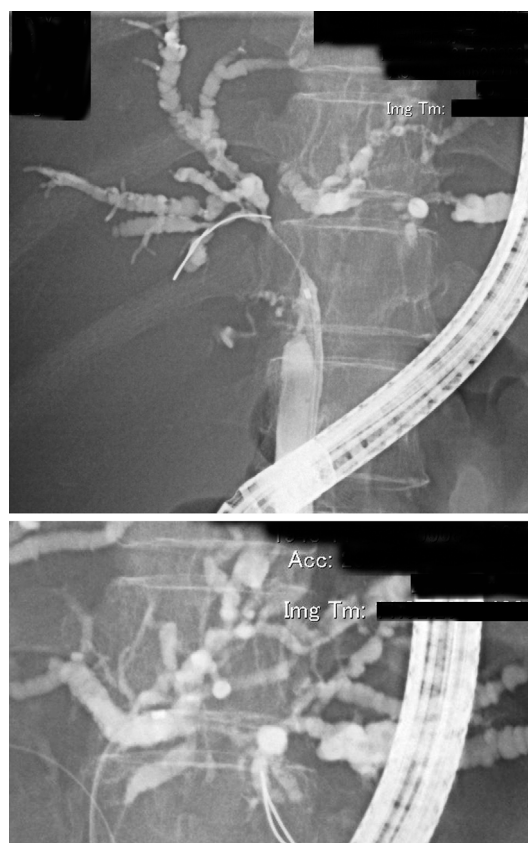


Figure 2. Diagnostic imaging of the biliary system. Endoscopic retrograde cholangiography showed the characteristic features of sclerosing cholangitis: beading and irregular narrowing and widening of the entire intrahepatic biliary system.

mechanism, as previously reported (17-20). At present in Japan, nivolumab is approved in the third-line setting for gastric cancer. PD-1 blockade might be more effective if used in earlier lines of therapy, although further studies that assess the long-term outcomes and patient prognosis in gastric cancer will be needed to confirm this notion. In addition, it would be essential to assess the cost-effectiveness and economic impact of early-line treatment with immune checkpoint inhibitors. Finally, it has been reported that the occurrence of irAEs may be correlated with the increased efficacy of the immune checkpoint inhibitor ipilimumab (21, 22), which is consistent with the findings in this report. However, the association between toxicity and efficacy remains to be clarified, and many patients achieve clinical responses to anti-PD-1 therapy without experiencing irAEs (23).

The authors state that they have no Conflict of Interest (COI).

Financial Support

This research was supported by grants from Japan Society for the Promotion of Science KAKENHI (17K09396 and 17H06404).

References

1. Kang YK, Boku N, Satoh T, et al. Nivolumab in patients with advanced gastric or gastro-oesophageal junction cancer refractory to, or intolerant of, at least two previous chemotherapy regimens (ONO-4538-12, ATTRACTION-2): a randomised, double-blind, placebo-controlled, phase 3 trial. *Lancet* **390**: 2461-2471, 2017.
2. Weber J. Review: anti-CTLA-4 antibody ipilimumab: case studies of clinical response and immune-related adverse events. *Oncologist* **12**: 864-872, 2007.
3. Kumar V, Chaudhary N, Garg M, et al. Current diagnosis and management of immune related adverse events (irAEs) induced by immune checkpoint inhibitor therapy. *Front Pharmacol* **8**: 49, 2017.
4. Abdalian R, Heathcote EJ. Sclerosing cholangitis: a focus on secondary causes. *Hepatology* **44**: 1063-1074, 2006.
5. Kulaksiz H, Heuberger D, Engler S, et al. Poor outcome in progressive sclerosing cholangitis after septic shock. *Endoscopy* **40**: 214-218, 2008.
6. Lindor KD, Wiesner RH, MacCarty RL, et al. Advances in primary sclerosing cholangitis. *Am J Med* **89**: 73-80, 1990.
7. O'Grady JG, Alexander GJ, Sutherland S, et al. Cytomegalovirus infection and donor/recipient HLA antigens: interdependent cofactors in pathogenesis of vanishing bile-duct syndrome after liver transplantation. *Lancet* **2**: 302-305, 1988.
8. Kashima J, Okuma Y, Shimizuguchi R, et al. Bile duct obstruction in a patient treated with nivolumab as second-line chemotherapy for advanced non-small-cell lung cancer: a case report. *Cancer Immunol Immunother* **67**: 61-65, 2018.
9. Gelsomino F, Vitale G, Ardizzoni A. A case of nivolumab-related cholangitis and literature review: how to look for the right tools for a correct diagnosis of this rare immune-related adverse event. *Invest New Drugs* **36**: 144-146, 2018.
10. Kawakami H, Tanizaki J, Tanaka K, et al. Imaging and clinicopathological features of nivolumab-related cholangitis in patients with non-small cell lung cancer. *Invest New Drugs* **35**: 529-536, 2017.
11. Kuraoka N, Hara K, Terai S, et al. Peroral cholangioscopy of nivolumab-related (induced) ulcerative cholangitis in a patient with non-small cell lung cancer. *Endoscopy* 2018.
12. Gelsomino F, Vitale G, D'Errico A, et al. Nivolumab-induced cholangitic liver disease: a novel form of serious liver injury. *Ann Oncol* **28**: 671-672, 2017.
13. Delis S, Triantopoulou C, Bakoyiannis A, et al. Sclerosing cholangitis in the era of target chemotherapy: a possible anti-VEGF effect. *Dig Liver Dis* **41**: 72-77, 2009.
14. Batts KP. Ischemic cholangitis. *Mayo Clin Proc* **73**: 380-385, 1998.
15. Martín AJ, Alfonso PG, Rupérez AB, Jiménez MM. Nab-paclitaxel plus gemcitabine as first-line palliative chemotherapy in a patient with metastatic pancreatic cancer with Eastern Cooperative Oncology Group performance status of 2. *Oncol Lett* **12**: 727-730, 2016.
16. Brahmer JR, Tykodi SS, Chow LQ, et al. Safety and activity of anti-PD-L1 antibody in patients with advanced cancer. *N Engl J Med* **366**: 2455-2465, 2012.
17. Park SE, Lee SH, Ahn JS, et al. Increased response rates to salvage chemotherapy administered after PD-1/PD-L1 inhibitors in patients with non-small cell lung cancer. *J Thorac Oncol* **13**: 106-111, 2018.
18. Aspeslagh S, Matias M, Palomar V, et al. In the immuno-oncology era, is anti-PD-1 or anti-PD-L1 immunotherapy modifying the sensitivity to conventional cancer therapies? *Eur J Cancer* **87**: 65-74, 2017.
19. Sukari A, Nagasaka M, Abdallah N. Responses in patients receiving sequential paclitaxel post progression on PD1 inhibitors. *Oral Oncol* **80**: 100-102, 2018.
20. Nadal R, Amin A, Geynisman DM, et al. Safety and clinical activity of vascular endothelial growth factor receptor (VEGFR)-tyrosine kinase inhibitors after programmed cell death 1 inhibitor treatment in patients with metastatic clear cell renal cell carcinoma. *Ann Oncol* **27**: 1304-1311, 2016.
21. Downey SG, Klapper JA, Smith FO, et al. Prognostic factors related to clinical response in patients with metastatic melanoma treated by CTL-associated antigen-4 blockade. *Clin Cancer Res* **13**: 6681-6688, 2007.
22. Attia P, Phan GQ, Maker AV, et al. Autoimmunity correlates with tumor regression in patients with metastatic melanoma treated with anti-cytotoxic T-lymphocyte antigen-4. *J Clin Oncol* **23**: 6043-6053, 2005.
23. Ascierto PA, Simeone E, Sileni VC, et al. Clinical experience with ipilimumab 3 mg/kg: real-world efficacy and safety data from an expanded access programme cohort. *J Transl Med* **12**: 116, 2014.

The Internal Medicine is an Open Access journal distributed under the Creative Commons Attribution-NonCommercial-NoDerivatives 4.0 International License. To view the details of this license, please visit (<https://creativecommons.org/licenses/by-nc-nd/4.0/>).