

Utilizing DICOM data to generate custom computer-aided designing and computer-aided machining polyetheretherketone healing abutments for an ear prosthesis

Mohit Dhiman¹, Sudhir Bhandari¹, Sunil Gaba²

¹Unit of Prosthodontics, Oral Health Sciences Centre, Postgraduate Institute of Medical Education and Research, Chandigarh, India
²Department of Plastic Surgery, Postgraduate Institute of Medical Education and Research, Chandigarh, India

Abstract

Soft tissue healing around implants may turn out to be the most decisive factor in the success or failure of the prosthesis. Dimension, configuration, and material of the healing abutments play a pivotal role in achieving optimal soft tissue architecture around implants. Digital imaging with computer-aided designing and computer-aided machining (CAD-CAM) technology, has made it easier to illustrate, design, replicate maxillofacial structures, and generate its supporting elements in a reliable, faster, and more convenient manner. This case report highlights the issue relevant to the implant-supported prosthetic replacement, on a site previously attempted for surgical reconstruction of the missing ear. Presurgical DICOM data were used to obtain custom CAD-CAM polyetheretherketone (PEEK) healing abutments on implants in a patient with an excessive amount of tissue in the missing right ear region. It is probably the first extraoral use of PEEK as a healing abutment in the workflow of implant retained maxillofacial prosthetics. No issue warranting the removal of the PEEK component was observed during the duration of its use.

Keywords: Auricular prosthesis, computer-aided designing and computer-aided machining, custom healing abutments, polyetheretherketone extraoral use, polyetheretherketone

Address for correspondence: Dr. Sudhir Bhandari, Unit of Prosthodontics, Oral Health Sciences Centre, Postgraduate Institute of Medical Education and Research, Sector 12, Chandigarh - 160 012, India.
 E-mail: drsudhirbhandari@yahoo.co.in

Submitted: 11-Feb-2020, **Revised:** 07-Sep-2020, **Accepted:** 14-Sep-2020, **Published:** 08-Oct-2020

INTRODUCTION

Complete or partial loss of any facial structure induces a negative impact on the patient's psychological and social well-being.^[1] The etiology can range from congenital malformations as seen in syndromes such as otofacial/craniofacial dysostosis, or nonsyndromic, or acquired causes which include burns, road traffic accidents,

animal bite, cancer, frostbite.^[2] Replacing a missing ear can be attained either by surgical reconstruction, adhesive/mechanically retained prosthesis, or a combination thereof. The procedure of surgical reconstruction of external ear presents many limitations owing to unavailability or inadequate flexibility of chondral cartilage, compromised blood supply to the region, existence of rudimentary

This is an open access journal, and articles are distributed under the terms of the Creative Commons Attribution-NonCommercial-ShareAlike 4.0 License, which allows others to remix, tweak, and build upon the work non-commercially, as long as appropriate credit is given and the new creations are licensed under the identical terms.

For reprints contact: reprints@medknow.com

How to cite this article: Dhiman M, Bhandari S, Gaba S. Utilizing DICOM data to generate custom computer-aided designing and computer-aided machining polyetheretherketone healing abutments for an ear prosthesis. J Indian Prosthodont Soc 2020;20:431-5.

Access this article online	
Quick Response Code:	Website: www.j-ips.org
	DOI: 10.4103/jips.jips_62_20

tissue, and variability in results with the manipulation of auto/allografts.^[3] Prosthodontic replacement offers more desirable results in terms of form, symmetry, orientation, and esthetic color matching. Traditionally, such prosthesis could be retained either by a spectacle, an adhesive or by engaging anatomical undercuts.^[2,4] Presently, craniofacial implants have been the most advocated approach for retention of an auricular prosthesis, with a high success rate of 92% in the mastoid region.^[5-7]

Healing abutments are utilized to maintain the patency of passage to the implant chamber through the overlying soft tissues and create suitable contours and emergence of the tissue bed for impression making. The use of a stock or custom, titanium alloy healing collars after the implant exposure surgery has been a norm. Polyetheretherketone (PEEK) has now been playing a pivotal role as a suitable substitute for titanium in orthopedics, traumatology, and dental implantology since the early 1990s. It is a contemporary biomaterial with a wide range of applications in the medical and engineering field since the year 1978. It has gained popularity because of its excellent biocompatibility and favorable mechanical and chemical properties, like low water absorption, flexibility, thermal stability, and chemical inertness.^[8]

This article presents a case report of a patient with missing right ear treated with two dental implants in the mastoid region with customized computer-aided designing and computer-aided machining (CAD-CAM) generated PEEK healing abutments to overcome the challenge posed by excessive soft tissue thickness.

CASE REPORT

A 31-year-old male patient was referred from the department of plastic surgery for the fabrication of an auricular prosthesis for his missing right side ear. The ear was lost as a consequence of a road traffic accident a few years ago. The patient was initially attempted for surgical reconstructing of the artificial ear using cartilage and alloplastic graft materials. As the reconstruction did not provide pleasing esthetics, it was later removed, and the patient was referred for prosthetic replacement of the missing ear. After due examination and obtaining patient's informed consent, two implants' supported custom silicone auricular prosthesis was agreed upon as the best treatment modality for the patient. Presurgical cone-beam computed tomography (CBCT) scans were made with a radiographic stent with radio-opaque markers in different probable implant positions. The scans were used to assess the proximity of dura, sigmoid sinuses, and any other

limiting anatomical structure from the planned implant positions. The same radiographic stent was modified and converted into a surgical stent to conform to the planned implant sites. Two dental implants were placed at sites 11:30 and 9:30 o'clock positions at approximately 20 mm distance from the center of the external auditory meatus.^[6] Thinning out of the basal tissue bed was also carried out in the same surgical appointment taking into consideration the presence of residual graft material from the previous reconstruction procedure lying in the tissue bed. The implants were left to heal for 3 months. Despite the attempted thinning of the tissue bed, fresh CBCT scans revealed the tissue thickness from the top of the implant surface to the external skin surface to be in the range of 7–11 mm over both the implants at various sites [Figure 1]. Only custom made healing abutment of a height higher than 11 mm could prove useful in maintaining the patency of the passage from the external skin surface to the implant chamber and prevent tissues from sagging in as they heal postsurgical exposure. In this scenario, where uncertainty prevailed with regards to obtaining precise custom healing abutments to suit the clinical requirements, CBCT DICOM (.dcm) files were converted into standard tessellation language using a software (Mimics Innovation Suite 17, Materialise, Technologielaan, Leuven, Belgium). 12 mm long healing abutments were designed using CAD [Figures 2 and 3] and were then milled (CAM) in PEEK material. The healing abutments were sterilized, and readied for connection to the fixture well before the patient was scheduled for the second stage implant exposure [Figures 4 and 5]. No adverse reaction like purulent discharge, severe pain, swelling, or any other sign of periimplantitis was encountered during the entire follow-up period of 4 weeks with PEEK abutments [Figure 6]. The patient was taken up in the

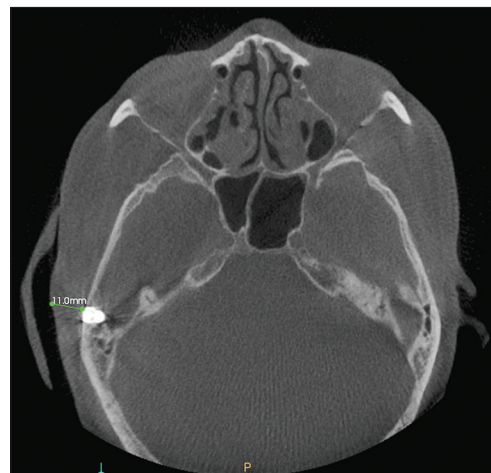


Figure 1: Cone-beam computed tomography image showing the thickness of overlying skin at implant level on the transverse plane

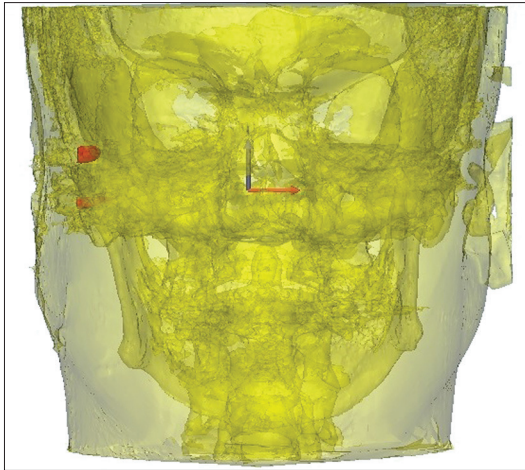


Figure 2: Digital model of the patient's face constructed from cone-beam computed tomography DICOM data (implants marked in red)

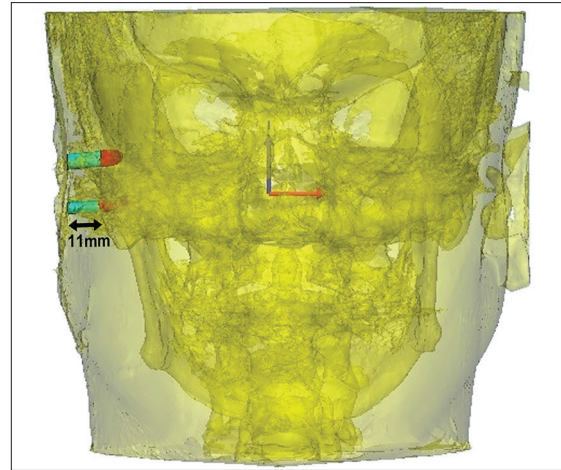


Figure 3: Computer-aided design of the custom healing abutments on reconstructed facial model (healing abutments marked in cyan)

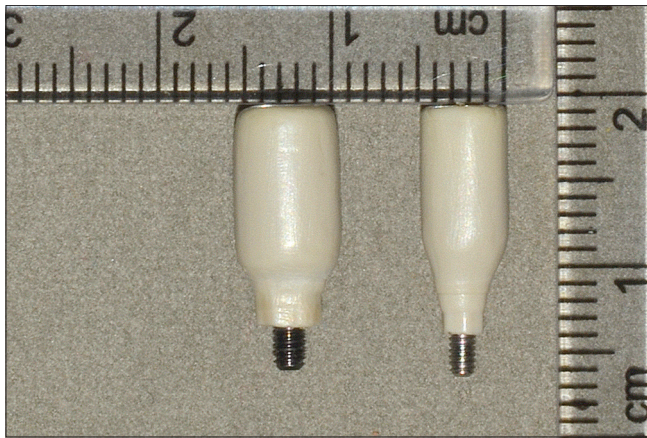


Figure 4: Custom polyetheretherketone healing abutments indicating their length and diameter

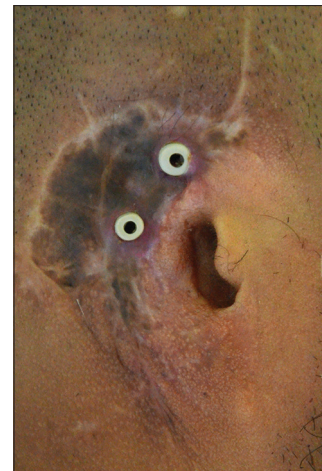

Figure 5: Polyetheretherketone healing abutments *in situ* emerging through the skin

conventional manner of impressions and technique to fabricate a titanium bar framework to support a silicone auricular prosthesis over the implants [Figures 7-9].

DISCUSSION

The merits of using skeletal anchorage utilizing osseointegrated implants include better retention, comfort, esthetics (because of possibly achieving thin merging edges), and an increase in the overall serviceability of prosthesis by eliminating the use of tissue adhesives and the associated wear and tear with their daily application and removal.^[2,4] In the conventional workflow, second stage surgery is performed to connect the osseointegrated implants and healing abutments. The surrounding tissues are left to heal so that they adapt around the lateral walls of healing abutments and provide the desired contours as they heal. Healing abutments also maintain the passage to implant chamber from external tissue surface as they prevent tissue sag inwards, leading

to re-closure. In routine practice, stock healing abutments made of materials like titanium, zirconia, and more recently PEEK are readily available and widely used in dentistry. Healing abutments can also be custom made into any desired shape or dimensions as per the clinical needs.

Fabrication of customized PEEK components using the CAD-CAM technique has a myriad of possibilities regarding their usability in the maxillofacial region. The abutments could be fabricated in the lab over scan bodies using digital DICOM files from CBCT, without any need for impression making.^[9] The utilized digital workflow was faster and convenient. This also allows the operator to be better prepared as the custom abutments can be sterilized and readied even before the implant exposure is performed. PEEK is already serving as an alternative to titanium alloys in the field of orthopedics and traumatology due to its biocompatibility, resistance to chemical and

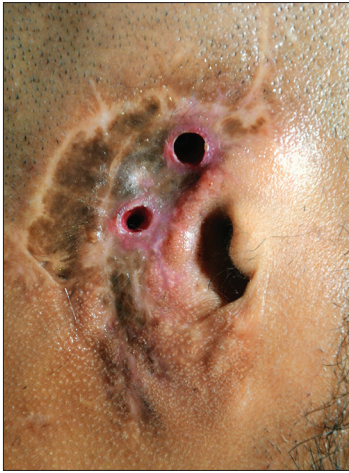

Figure 6: Passage to the implants created upon removal of the polyetheretherketone healing abutments

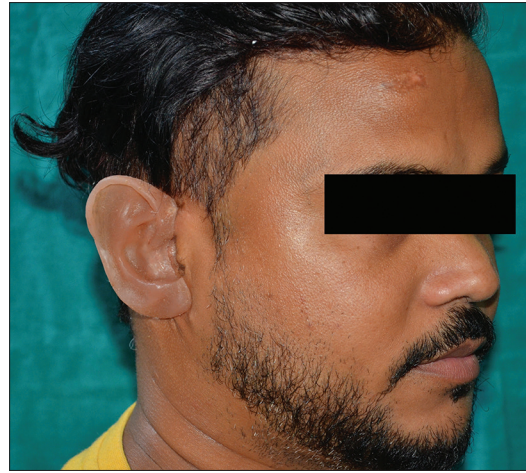

Figure 7: A bar and clip retained room temperature vulcanizing silicone prosthesis

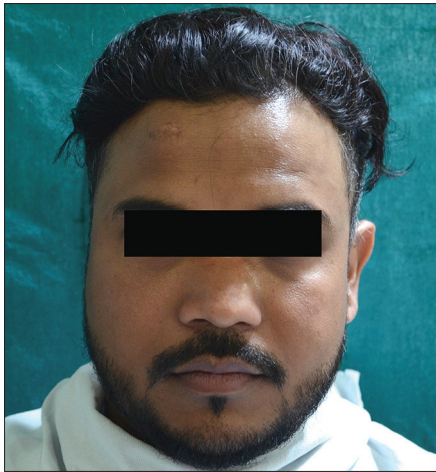

Figure 8: Preprosthetic frontal view of the patient

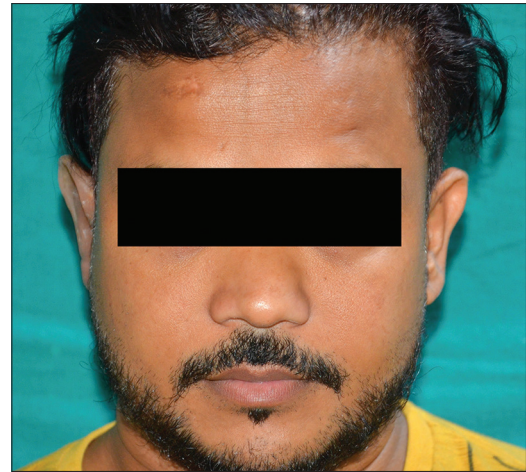

Figure 9: An acceptable three-dimensional orientation of the prosthetic ear leading to an evident change in the appearance of the patient

thermal changes, low water absorption, nontoxicity, and a modulus of elasticity comparable to bone.^[8,10] In the field of dentistry, its use as partial denture frameworks, short interim span fixed dental prostheses, and as stock/custom fabricated temporary abutments (up to 180 days) is well established.^[5] As per studies, the fracture resistance of some CAD-CAM milled PEEK frameworks is even superior to other materials used for framework fabrication, like lithium disilicate, or zirconia.^[11] Some of the advantages that newer PEEK materials have to offer over materials like zirconia or titanium includes low inflammatory response generation at the site over time, minimal scattering of rays in irradiated region, and low affinity to biofilm adhesion.^[12,13] A longer service life due to wear resistance and easy processing and manufacturing of PEEK by methods such as injection molding, computer-assisted milling, and most recently through three-dimensional (3D) additive manufacturing has broadened prospects of its use in the field of prosthodontics.

A higher cost involved in the entire workflow described is a limitation with respect to utilizing the process in routine clinical work. The ease and availability of additive manufacturing technology and compatible materials should bring the cost of fabrication down with time. The scope of further improving colour match at the margins of the prosthesis by external staining was limited due to the imposed lockdown in the ongoing Covid 19 pandemic. Another limitation regarding the use of DICOM data in generating 3D printed frameworks is the presence of noise in the obtained scans, which may affect the clinical image, and ultimately the accuracy of the printed product. The noise is dependent upon the quality of scans and can be reduced during the acquisition of the data and utilizing the available postprocessing techniques.

The thickness of each slice of the CBCT scans we utilized was 0.3 mm, and 600 slices were obtained for the region of interest. Such data are satisfactory to obtain a good 3D

model. The data obtained had less noise by default, which was further reduced by manually adjusting the threshold values without affecting the pixel values of the soft tissues.

Constant research is underway to increase the biocompatibility, osseointegration, and antimicrobial capabilities of this polymer with the help of nanosurface coatings such as TiO₂, hydroxyapatite, Ag-HA, and fluorohydroxyapatite.^[14-16]

As per the authors' best knowledge, the use of PEEK material as a component in extraoral maxillofacial prosthesis has not been presented in the literature to date.

Declaration of patient consent

The authors certify that they have obtained all appropriate patient consent forms. In the form the patient(s) has/have given his/her/their consent for his/her/their images and other clinical information to be reported in the journal. The patients understand that their names and initials will not be published and due efforts will be made to conceal their identity, but anonymity cannot be guaranteed.

Acknowledgement

We are thankful to Dr Viveyk Mittal for the laboratory support.

Financial support and sponsorship

Nil.

Conflicts of interest

There are no conflicts of interest.

REFERENCES

1. Henry PJ. Maxillofacial prosthetic considerations. In: Worthington P,

Branemark PI, editors. *Advanced Osseointegration Surgery: Applications in the Maxillofacial Region*. Chicago: The Quintessence Publishing Co Inc.; 1992. p. 313-26.

2. Arora V, Sahoo NK, Gopi A, Saini DK. Implant-retained auricular prostheses: A clinical challenge. *Int J Oral Maxillofac Surg* 2016;45:631-5.

3. Furnas DW. Complications of surgery of the external ear. *Clin Plast Surg* 1990;17:305-18.

4. Lemon JC, Chambers MS. Locking retentive attachments for an implant retained auricular prosthesis. *J Prosthet Dent* 2002;87:336-8.

5. Subaşı MG, Alıaçık G, Kalaycı A, Akman S, Durmuş E. Prosthetic rehabilitation of partial ear defect: 2 case reports. *J Indian Prosthodont Soc* 2014;14:196-201.

6. Granström G. Craniofacial osseointegration. *Oral Dis* 2007;13:261-9.

7. Kethireddy S, Kethireddy K. Refabrication of an implant-retained auricular prosthesis using clip attachment pickup technique. *J Indian Prosthodont Soc* 2017;17:310-5.

8. Siewert B, Plaza-Castro M, Sereno N, Jarman-Smith M. Applications of PEEK in the dental field. In: *PEEK Biomaterials Handbook*. 2nd ed. Netherlands: Elsevier; 2019. p. 333-42.

9. Bhamhani R, Bhattacharya J, Sen SK. Digitization and its futuristic approach in prosthodontics. *J Indian Prosthodont Soc* 2013;13:165-74.

10. Corvelli AA, Biermann PJ, Roberts JC. Design, analysis and fabrication of a composite segmental bone replacement implant. *J Adv Mater* 1997;28:2-8.

11. Beuer F, Steff B, Naumann M, Sorensen JA. Load-bearing capacity of all-ceramic three-unit fixed partial dentures with different computer-aided design (CAD)/computer-aided manufacturing (CAM) fabricated framework materials. *Eur J Oral Sci* 2008;116:381-6.

12. Goutam M, Giriapura C, Mishra SK, Gupta S. Titanium allergy: A literature review. *Indian J Dermatol* 2014;59:630.

13. Hahnel S, Wieser A, Lang R, Rosentritt M. Biofilm formation on the surface of modern implant abutment materials. *Clin Oral Implants Res* 2015;26:1297-301.

14. Sanpo N, Tan ML, Cheang P, Khor KA. Antibacterial property of cold-sprayed HA-Ag/PEEK coating. *J Therm Spray Technol* 2009;18:10-5.

15. Wang L, Zhang H, Deng Y, Luo Z, Liu X, Wei S. Study of oral microbial adhesion and biofilm formation on the surface of nanofluorohydroxyapatite/polyetheretherketone composite. *Chinese J Stomatol* 2015;50:378-82.

16. Rahmitasari F, Ishida Y, Kurahashi K, Matsuda T, Watanabe M, Ichikawa T. PEEK with reinforced materials and modifications for dental implant applications. *Dent J (Basel)* 2017;5:35.