

## Nonunion of capitate due to late diagnosis in a teenager

Authors' Contribution:  
Study Design A  
Data Collection B  
Statistical Analysis C  
Data Interpretation D  
Manuscript Preparation E  
Literature Search F  
Funds Collection G

ABCDEF **Seyit Ali Gümüştaş**  
ACDF **Hacı Bayram Tosun**  
ABDE **İsmail Ağır**  
ADEF **Abuzer Uludağ**

Department of Orthopaedics and Traumatology, Adiyaman Education and Research Hospital, Adiyaman, Turkey





Corresponding Author: İsmail Ağır, e-mail: [iagir@hotmail.com](mailto:iagir@hotmail.com)

**Patient:** Male, 13  
**Final Diagnosis:** Isolated capitate bone fracture  
**Symptoms:** —  
**Medication:** —  
**Clinical Procedure:** —  
**Specialty:** —

**Objective:** Unusual clinical course  
**Background:** Carpal fractures often appear in men under the age of 40 years. Isolated fracture of the capitate without dislocation is very rare and comprises 1% of all carpal fractures. Nonunion of capitate mostly resulted from delay in diagnosis and lack of initial treatment.  
**Case Report:** We reported the case of a 13-year-old boy who had a late-diagnosed capitate fracture. We put the wrist in a short-arm cast for 3 months. After the immobilization with the cast has been finalized, range of motion and strengthening exercises were started. One year after the trauma, we saw total union of the fracture.  
**Conclusions:** Diagnosis of carpal bone fracture may be missed, especially in skeletally immature patients. To prevent late diagnosis in skeletally immature patients, early control radiography should be taken. If further examination is needed, computed tomography should be performed. We can achieve good results with cast immobilization in this age group of patients. As a result, although the author has been advised surgical treatment for nonunion of capitate fracture, conservative treatment should be considered.

**MeSH Keywords:** Capitate Bone • Nonunion • Carpal Bones – injuries

Full-text PDF: <http://www.amjcaserep.com/download/index/idArt/890127>

 915  —  3  22

## Background

Carpal fractures often appear in men under the age of 40 years [1] and most commonly occurs after falling on an open hand. While scaphoid fractures are mostly seen, capitate fracture occurs very rarely [2].

The capitate is the largest of 8 carpal bones and is at the center of them [3]. The center of rotation of the wrist passes through the head of the capitate bone [4]. Isolated fracture of the capitate without dislocation is very rare and comprises 1% of all carpal fractures [5–7].

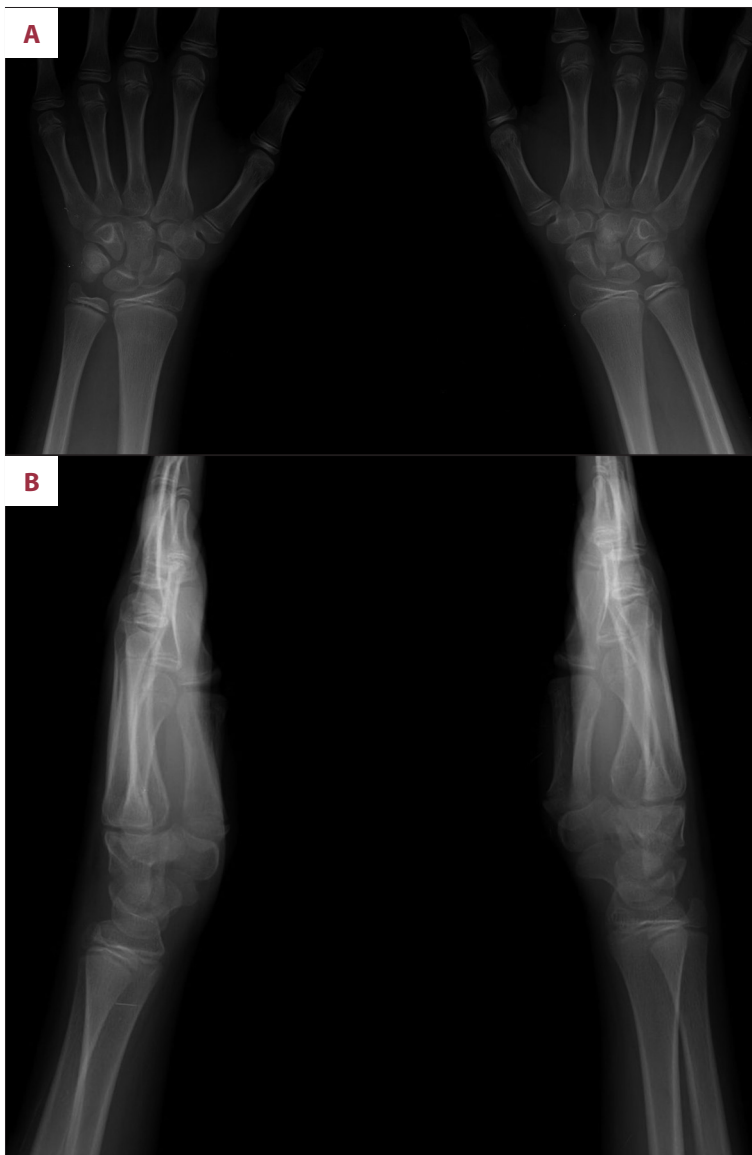
Nonunion has been reported as the most common complication; 19.6% to 56% in isolated capitate fractures [8,9]. Nonunion mostly results from delay in diagnosis and treatment [7,8,10].

Isolated and nondisplaced capitate fractures are successfully treated with cast immobilization [11]. Displaced fractures should be reduced anatomically and fixed with K-wires or Herbert screws [12–14]. In the literature, surgery is advised for the treatment of nonunion capitate fractures [8,15,16].

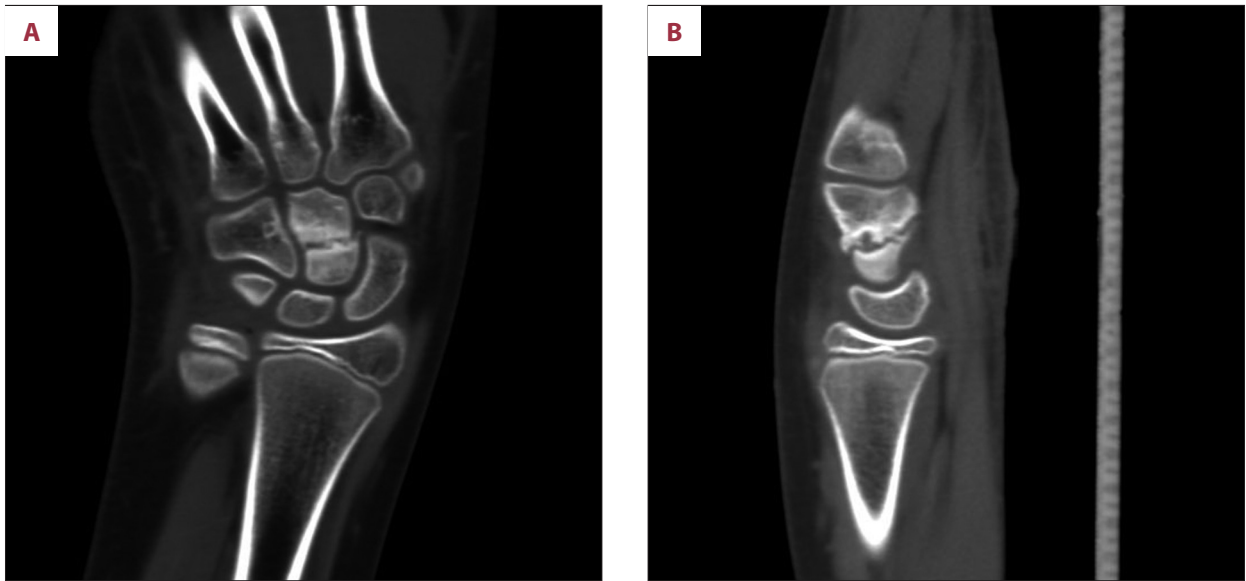
We present a case with nonunion of a capitate fracture, which was successfully treated conservatively.

## Case Report

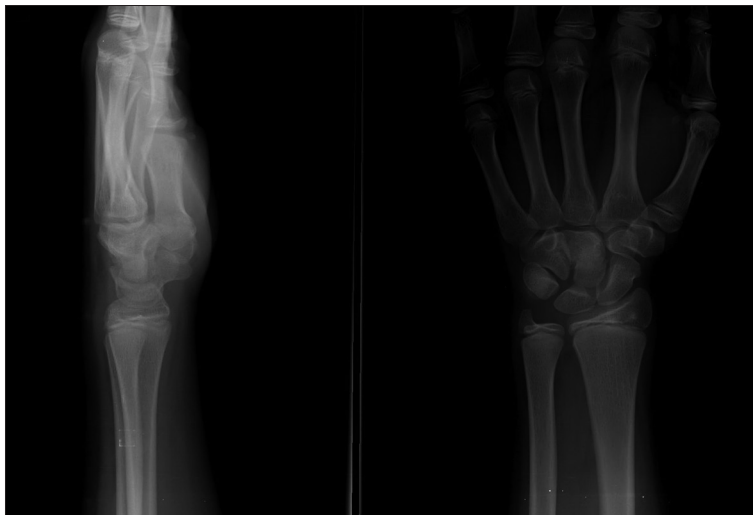We report the case of a 13-year-old boy who fell on his left hand and went to the emergency clinic, where radiographs were taken but no fracture was seen. Elastic bandage was applied, a non-steroidal anti-inflammatory drug was prescribed, and



**Figure 1A,B.** A transverse fracture line and sclerosis in the middle of the capitate at X-ray (AP and Lateral view).



**Figure 2A,B.** Computed tomography clearly showing the nonunion (coronal and sagittal view).



**Figure 3.** Total union of fracture at X-ray (AP and lateral view).

cold application was advised. The patient was called to come for a control examination 1 week later, but he did not appear. After 6 months, the patient came to the orthopedic clinic because his symptoms were unimproved.

At physical examination, we determined edema and pain with palpation of the capitate bone. Wrist range of motion was nearly full but the final stage was tender. There was no tenderness on scaphoid with palpation, Watson test, LT test, and Lichtman test results were negative. There was no evidence of compression of the median nerve.

Upon X-ray examination, we saw a transverse fracture line and sclerosis in the middle of the capitate (Figure 1). Computed tomography (CT) clearly showed the nonunion (Figure 2). X-ray and CT failed to show any other pathology.

We advised the surgical treatment for nonunion. However, the patient rejected the surgery, so we put the wrist in a short-arm cast for 3 months. After the immobilization had been finalized, range of motion and strengthening exercises were started. One year after the trauma, we saw total union of the fracture (Figure 3), edema had completely regressed, wrist range of motion was full and painless [80° flexion, 70° extension, 20° radial deviation, and 30° ulnar deviation] and grip strength was equal in both hands. The patient was followed for post-traumatic arthritis.

## Discussion

Fractures of the capitate are a rare injury, especially in children, are usually missed entirely, and account for only 0.3%

of all carpal fractures. Most of these fractures occur in association with additional carpal injury, particularly scaphoid fractures. This is usually the result of a high energy trauma [6,17–19]. Isolated capitate fractures usually occur after falling on an open hand [6].

Capitate fractures are often missed entirely because the initial radiographies of nondisplaced fractures are usually nondiagnostic. CT is very helpful for diagnosis of isolated fractures. MRI is helpful in showing avascular necrosis and for deciding whether there is union or nonunion [4,6].

The complication rate for capitate fractures is relatively high and consequences are important [4]. Functional limitation is common secondary to nonunion, avascular necrosis of the proximal pole, capitate collapse, symptomatic midcarpal arthritis, or associated injuries [7].

The outcome and the treatment modalities of isolated capitate fractures are not well determined. The orthopedists concurred with conservative treatment with initial cast immobilization (generally 6 to 12 weeks of immobilization), followed by mobilization within pain limits, because the displacement was minimal and the fracture fragment was small and not rotated [4,20].

Displaced fracture of the capitate requires anatomic repositioning and internal fixation with headless cannulated compression screws or K-wires [21]. The headless compression screw has advantage over the K-wire because it provides compression across the fracture site and allows early wrist exercise [22].

Nonunion has been reported as the most common complication; 19.6% to 56% in isolated capitate fractures [8,9]. Nonunion mostly results from delay in diagnosis and treatment. Nonunion can be treated with intercalary bone grafting and/or open reduction and internal fixation [7,8,10]. Our case was a misdiagnosed capitate fracture initially diagnosed as a soft-tissue injury. The patient did not come for control examination, so diagnosis of the fracture was delayed. Gehrman et al. [15] reported a case with nonunion of a capitate fracture treated with an iliac cancellous bone graft and screw osteosynthesis. Bone healing was verified 3 months after surgery and they recommended operative treatment for delayed union. Morisawa et al. [16] reported another case, in which the bone with a nutrient vessel was grafted; bone union and excellent results were obtained. In our case, after immobilization with a cast, we achieved union and excellent results. We treated our late-diagnosed capitate fracture case conservatively due to refusal of surgical treatment by the patient. Union was achieved with cast immobilization after 3 months. At last examination, there was full range of wrist motion without pain.

## Conclusions

Carpal bone fractures may be under-diagnosed, especially in skeletally immature patients. If complaints persist, control radiographies should be taken as soon as possible. If further examination is needed, CT should be performed. Surgery is the recommended treatment for nonunion of a capitate fracture. However, patient age should be taken into account because cast immobilization may be a good treatment choice for preadolescents

## References:

1. Freeland AE, Pesut TA: Oblique capitate fracture of the wrist. *Orthopedics*, 2004; 27(3): 287–90
2. Hey HW, Chong AK, Murphy D: Prevalence of carpal fracture in Singapore. *J Hand Surg Am*, 2011; 36(2): 278–83
3. Conolly JF (ed.): *The Management of Fractures and Dislocations: An Atlas*. 3<sup>rd</sup> ed. Philadelphia, PA: W.B. Saunders Co., 1981
4. De Schrijver F, De Smet L: Isolated fracture of the capitate: the value of MRI in diagnosis and follow up. *Acta Orthop Belg*, 2002; 68(3): 310–15
5. Adler JB, Shaftan GW: Fractures of the capitate. *J Bone Joint Surg Am*, 1962; 44: 1537–47
6. Albertsen J, Mencke S, Christensen L et al: Isolated capitate fracture diagnosed by computed tomography. Case report. *Handchir Mikrochir Plast Chir*, 1999; 31(2): 79–81
7. Rand JA, Linscheid RL, Dobyns JH: Capitate fractures: a long-term follow-up. *Clin Orthop Relat Res*, 1982; 165: 209–16
8. Yoshihara M, Sakai A, Toba N et al: Nonunion of the isolated capitate waist fracture. *J Orthop Sci*, 2002; 7(5): 578–80
9. Vigler M, Aviles A, Lee SK: Carpal fractures excluding the scaphoid. *Hand Clin*, 2006; 22(4): 501–16
10. Freeman BH, Hay EL: Nonunion of the capitate: a case report. *J Hand Surg Am*, 1985; 10(2): 187–90
11. Failla JM, Amadio PC: Recognition and treatment of uncommon carpal fractures. *Hand Clin*, 1988; 4(3): 469–76
12. Guiral J, Gracia A, Diaz-Oter JM: Isolated fracture of the capitate with a volar dislocated fragment. *Acta Orthop Belg*, 1993; 59(4): 406–8
13. Volk AG, Schnall SB, Merkle P, Stevanovic M: Unusual capitate fracture: a case report. *J Hand Surg Am*, 1995; 20(4): 581–82
14. Garcia-Elias M, Bishop AT, Dobyns JH et al: Transcarpal carpometacarpal dislocations, excluding the thumb. *J Hand Surg Am*, 1990; 15(4): 531–40
15. Gehrman SV, Wild M, Windolf J, Hakimi MY: Isolated fractures of the capitate: treatment of delayed union. *Handchir Mikrochir Plast Chir*, 2009; 41(3): 175–78
16. Morisawa Y, Ikegami H, Takayama S, Toyama Y: A case of pseudarthrosis of the capitate. *Hand Surg*, 2003; 8(1): 137–40
17. Wulff RN, Schmidt TL: Carpal fractures in children. *J Pediatr Orthop*, 1998; 18(4): 462–65
18. Goddard N: Carpal fractures in children. *Clin Orthop Relat Res*, 2005; 432: 73–76
19. Light TR: Carpal injuries in children. *Hand Clin*, 2000; 16(4): 513–22
20. Palumbo DM: An uncommon isolated fracture of the capitate bone. *JAAPA*, 2007; 20(12): 33–35
21. Amadio PC, Moran SL: Fractures of the carpal bones. In: Green DP (ed.), *Green's operative hand surgery*. 5<sup>th</sup> ed. New York: Elsevier Churchill Livingstone, 2005
22. Sabat D, Arora S, Dhal A: Isolated capitate fracture with dorsal dislocation of proximal pole: a case report. *Hand (NY)*, 2011; 6(3): 333–36