

Half-dose thrombolytic therapy in patients with right heart thrombi

Journal of International Medical Research

2019, Vol. 47(7) 3400–3407

© The Author(s) 2019

Article reuse guidelines:

sagepub.com/journals-permissions

DOI: 10.1177/0300060519850399

journals.sagepub.com/home/imr



Jamal Moosavi¹, Omid Shafe¹,
Azin Alizadehasl², Mozghan Parsaee²,
Anita Sadeghpour², Fahimeh Khesali²,
Hamid Reza Pouraliakbar³,
Kiara Rezaei Kalantari³, Melody Farrashi²,
Mehrdad Jafari Fesharaki² and
Parham Sadeghipour¹ 

Abstract

The management of floating right heart thrombi (FRHT) in patients with acute pulmonary emboli is controversial. Several recent case series have revealed similar efficacy and better survival rates with systemic thrombolytic therapy than with surgery. In this case series, we present our experience with the efficacy of “half-dose” or “safe-dose” thrombolytic therapy in the resolution of FRHT. Five patients who were admitted with confirmed acute pulmonary emboli and FRHT were included in the present report. Half-dose thrombolytic therapy (50 mg of alteplase) was administered to the patients. Follow-up echocardiography revealed complete resolution of the FRHT and considerable improvement in the right heart function. No bleeding events were recorded. Our small case series shows the efficacy and safety of half-dose thrombolytic therapy in FRHT resolution in a group of patients with high bleeding risk. Our findings should be tested in larger populations.

Keywords

Right heart thrombi, acute pulmonary emboli, thrombolytic therapy, surgical pulmonary embolectomy, half dose thrombolytic, echocardiography

Date received: 11 January 2019; accepted: 23 April 2019

¹Cardiovascular Intervention Research Center, Rajaie Cardiovascular Medical and Research Center, Iran University of Medical Sciences, Tehran, Iran

²Echocardiography Research Center, Rajaie Cardiovascular Medical and Research Center, Iran University of Medical Sciences, Tehran, Iran

³Rajaie Cardiovascular Medical and Research Center, Iran University of Medical Sciences, Tehran, Iran

Corresponding author:

Parham Sadeghipour, Cardiovascular Intervention Research Center, Rajaie Cardiovascular Medical and Research Center, Iran University of Medical Sciences, Vali-Asr Ave., Hashemi Rafsanjani Exp, Tehran 1995614331, Iran.

Email: psadeghipour@hotmail.com



Introduction

The treatment of right heart thrombi (RHT) is controversial, and the low prevalence (7%–18%) of this condition promotes ambiguity in clinical management.¹ RHT are categorized into two types: *in situ* thrombi, which have a benign clinical course, and floating RHT (FRHT), which carry a considerable risk of embolization and thus a high risk of mortality.² The classic treatment of FRHT is surgery; nonetheless, several case series have reported higher mortality rates with surgery than with systemic thrombolysis.¹ The main disadvantage of systematic thrombolytic therapy is bleeding, and various approaches have been proposed to overcome this adverse effect. The administration of half-dose thrombolytics has been shown to be promising in the treatment of submassive pulmonary emboli (PE),³ although it has been scarcely studied in the field of FRHT.⁴

In the current case series, we present our recent experience in the management of FRHT in patients with PE. In the first group, the patients received half-dose thrombolytic therapy because of their high bleeding risk. The thrombolytic regimen used in this group of patients consisted of a half-dose regimen: a 1-hour infusion of 50 mg of tissue plasminogen activator (Actilyse; Boehringer Ingelheim, Ingelheim am Rhein, Germany). Parenteral anticoagulation was stopped during the thrombolytic infusion, and heparin was started immediately after termination of the fibrinolytics at the rate of 18 U/kg/h. Because all patients weighed >50 kg, no thrombolytic dose reduction was needed. In the second group, the patients were scheduled for surgery because of clots in transit.

Patients

The study was approved by the ethics committee of Rajaie Cardiovascular Medical

and Research Center (Reference number: 9541). Written informed consent was obtained from every patient recruited for this case series.

Non-transitory RHT

Case 1. A 57-year-old man was admitted to our hospital with acute dyspnea. Physical examination showed blood pressure (BP) of 115/65 mmHg, heart rate (HR) of 108 bpm, temperature of 37.1°C, and respiratory rate of 28 breaths/min. The patient was conscious, and his oxygen saturation was 89% on room air. He had a history of ischemic stroke 6 months before the present event. Bilateral segmental and subsegmental pulmonary arterial branch thrombi were found on pulmonary computed tomography (CT) angiography. Echocardiography revealed a highly mobile elongated mass from the inferior vena cava to the right atrial junction, suggestive of a thrombus attached to the Eustachian valve (Figure 1(a)), with moderate right ventricular (RV) enlargement and moderate RV dysfunction. The levels of N-terminal pro B-type natriuretic peptide (NT-proBNP) and cardiac troponin I (cTnI) were 860 pg/mL and 0.18 ng/mL, respectively. Therefore, the patient was categorized as having an intermediate-high risk of PE with a relative contraindication for thrombolytics given the ischemic stroke 6 months before the present admission.⁵ A half-dose thrombolytic infusion was chosen for the patient. Follow-up echocardiography after 72 hours demonstrated improvements in RV size and function and complete disappearance of the RHT. Notably, the patient's symptoms improved and he was discharged 4 days later.

Case 2. A 73-year-old man with morbid obesity and multiple comorbidities, including diabetes mellitus and chronic kidney disease, was referred to our emergency department because of acute-onset dyspnea.

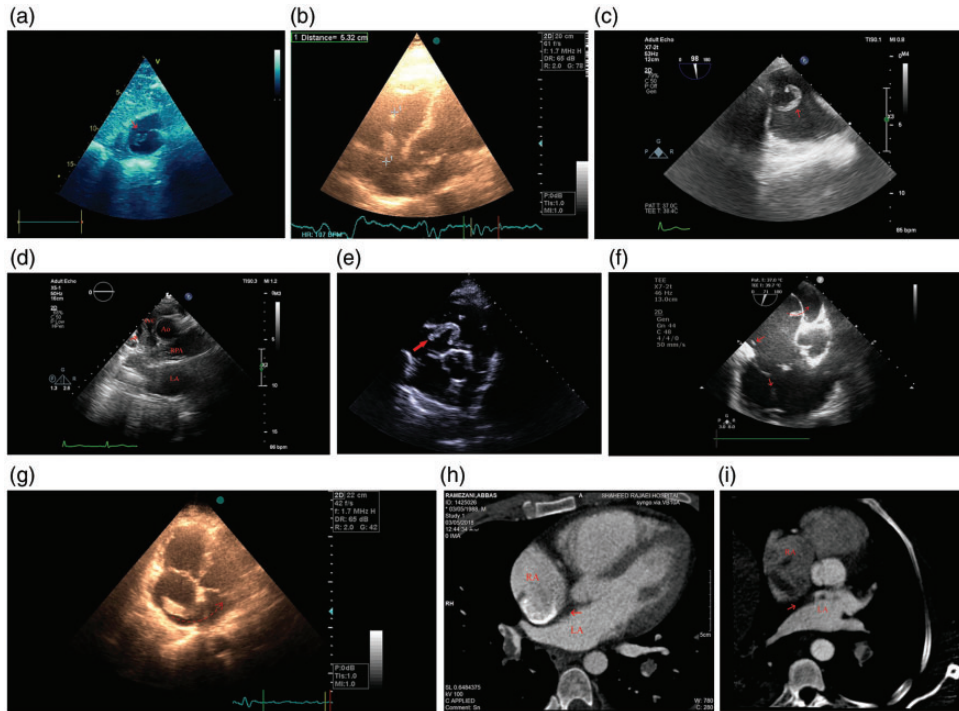


Figure 1. (a) An elongated hypermobile mass attached to the Eustachian valve (arrow) in the right atrium in the subcostal view of transthoracic echocardiography. (b) A large (5.3×1.0 cm) mobile wormlike mass in the right atrium, attached to the pacemaker lead and protruding into the right ventricle in the four-chamber view of transthoracic echocardiography. (c) An elongated hypermobile mass (arrow) attached to the Eustachian valve in the bicaaval view of transesophageal echocardiography. (d) A long wormlike mobile echodensity (arrow) in the superior vena cava in the suprasternal view of transthoracic echocardiography, Ao, aorta; LA, left atrium; RPA, right pulmonary artery. (e) Protrusion of an elongated mobile echodensity through the tricuspid valve (arrow) in the short-axis view of transthoracic echocardiography. (f) A hypermobile strand-like mass (4.8×0.6 cm) in the right atrium with protrusion into the right ventricle (small arrows) and left atrium through a patent foramen ovale tunnel (curved arrow) in the mid-esophageal 70° view of transesophageal echocardiography. (g) A long worm-shaped echogenic mass (6.4×1.1 cm) in the right atrium protruding into the right ventricle and left atrium through a patent foramen ovale (curved arrow) in the four-chamber view of transthoracic echocardiography. (h, i) Computed tomography angiography axial views of the heart, showing a right atrial serpiginous filling defect coursing through a patent foramen ovale (arrow) to the left atrium.

He had undergone cardiac pacemaker implantation 5 years earlier. He had also sustained a left humeral fracture due to upper extremity trauma 1 week prior to the current admission. Physical examination revealed BP of 100/60 mmHg and HR of 123 bpm. Pulmonary CT angiography showed acute thrombosis in the superior lobe of the right pulmonary artery and

the lingula of the left pulmonary artery. Laboratory tests showed NT-proBNP and cTnI levels of 974 pg/mL and 0.44 ng/mL, respectively. Echocardiography revealed a mobile large, wormlike thrombosis in the right atrium, attached to the pacemaker lead (Figure 1(b)), as well as severe RV dysfunction and severe RV enlargement. A half-dose thrombolytic regimen was

selected for the patient because of the various comorbidities and the recent trauma. The 72-hour follow-up echocardiography showed disappearance of the thrombosis, improvement of the RV dysfunction from severe to moderate, and a decrease in the systolic pulmonary artery pressure from 45 to 31 mmHg. The patient was later discharged with minimal residual symptoms.

Case 3. A 73-year-old man with a recent history of colostomy (3 weeks earlier) for colon cancer was admitted to our emergency department because of aggravating dyspnea. His BP was 105/80 mmHg and HR was 110 bpm. CT angiography revealed PE in the lobar, segmental, and subsegmental pulmonary artery branches. The levels of cTnI and NT-proBNP were elevated at 0.23 ng/mL and 670 pg/mL, respectively. Echocardiography revealed a 3.50- × 0.85-cm wormlike echodensity attached to the Chiari network in the right atrium with intermittent protrusion into the right ventricle, highly suggestive of thrombosis (Figure 1(c)), as well as mild to moderate RV enlargement and moderate RV dysfunction. Half-dose thrombolytic therapy was administered because of the patient's increased bleeding risk. Follow-up echocardiography showed complete resolution of the RHT. The patient was later discharged with alleviated symptoms.

Case 4. A 38-year-old woman who had undergone a complete workup for chronic thromboembolic pulmonary hypertension (CTEPH) and was a candidate for balloon pulmonary angioplasty was admitted with aggravating dyspnea that had begun 1 week before hospitalization. Her international normalized ratio was 2.1. Echocardiography showed severe RV enlargement and dysfunction with an estimated systolic pulmonary artery pressure of 65 mmHg. A long wormlike mobile echodensity was seen in the superior vena cava

in the suprasternal view, suggestive of thrombosis. Frequent protrusions of the tip of the mass into the superior vena cava–right atrial junction were seen in the subcostal view (Figure 1(d)). She underwent half-dose thrombolytic therapy. Complete thrombus resolution was detected on follow-up echocardiography 72 hours later, and she stated that her symptoms had been alleviated. She was subsequently discharged in good condition, and her balloon pulmonary angioplasty was postponed for 6 weeks.

Case 5. A 56-year-old man with a history of heart failure (left ventricular ejection fraction of 10%–15% on his previous echocardiographic examination) was admitted with respiratory distress. His initial hemodynamic evaluation showed a HR of 126 bpm and BP of 114/86 mmHg. No rales were detected on his physical examination. Because of atrial fibrillation, the patient was on warfarin therapy with an international normalized ratio of 1.9. Echocardiography revealed an elongated mobile echodensity in the right atrium frequently protruding into the right ventricle, suggestive of thrombosis (Figure 1(e)). Pulmonary CT angiography showed lobar PE in the inferior and middle lobes of the right lung. Because the patient was considered to have high surgical risk, a safe-dose regimen was chosen to decrease his bleeding risk. Fortunately, he recovered from the acute event and his respiratory distress resolved. No sign of a right atrial mass was seen on the echocardiographic examination the following day.

Transitory RHT

Case 6. A 30-year-old man was referred to our hospital with acute-onset dyspnea. At presentation, the patient had BP of 110/80 mmHg and HR of 125 bpm. Echocardiography demonstrated a large hypermobile strand-like mass (4.8 cm) in

the right atrium with protrusion into the right ventricle and left atrium through a patent foramen ovale (PFO) tunnel, suggestive of thrombosis in transit, with moderate to severe RV dysfunction and moderate RV enlargement (Figure 1(f), Movie 1(a)). Pulmonary CT angiography was immediately performed and showed thrombosis in the distal portions of the right and left pulmonary arteries with bilateral involvement of the segmental and subsegmental pulmonary arterial branches. A clot in transit from the PFO was also depicted (Figure 1(h)). Clots in transit preclude thrombolytic therapy because they carry a high risk of left-sided embolization. The patient underwent emergent surgical pulmonary embolectomy and thrombosis removal, and he was discharged 1 week later with no dyspnea and good echocardiographic prognostic factors.

Case 7. A 39-year-old man was referred to our hospital because of a right heart mass. At admission, he had dyspnea of New York Heart Association functional class IV. He had a history of a 23-hour nonstop car drive 3 days before the current hospitalization and left leg swelling beginning the night before. His BP was 113/65 mmHg and HR was 132 bpm. Transthoracic echocardiography revealed severe RV enlargement and RV dysfunction with mid and basal RV free wall hypokinesia and apical hypercontractility (McConnell sign) (Movie 1(b)). A long worm-shaped echogenic mass (6.4×1.1 cm) was detected in the right atrium, protruding into the right ventricle and left atrium through a PFO (Figure 1(g), Movie 1(b)). Pulmonary CT angiography showed saddle emboli in the main pulmonary artery bifurcation with extension into the lobar and segmental branches of the right and left pulmonary arteries and a clot in transit (Figure 1(i)). Similar to Case 6, given the presence of the right atrial clot in transit, surgical embolectomy with thrombus removal was performed. The RV size and function

were significantly recovered after surgery, and no sign of RHT was detected. The patient was discharged in good condition.

Discussion

Although surgical embolectomy has been recommended as the standard treatment strategy for RHT,² several observational studies have questioned its value as the first-line therapy. Kinney and Wright⁶ reported similar therapeutic efficacy for both therapeutic strategies in their meta-analysis. Chartier et al.,⁷ in one of the largest case series evaluating the different treatment strategies for FRHT, reported a 47.1% mortality rate in patients managed surgically versus 22.2% in those receiving fibrinolytics. In that study, the patients on sole anticoagulation therapy had a 62.5% mortality rate, underlining the need for more aggressive treatment. Similar results were reported by Rose et al.⁸ In their systematic review of 177 patients with RHT, the mortality rates of surgical embolectomy, thrombolytic therapy, and heparin alone were 23.8%, 11.3%, and 28.8%, respectively,⁸ which were also in favor of using thrombolytic therapy as the first-line management of RHT. In addition, untreated RHT might be lethal especially during the early period of hospitalization.¹ A meta-analysis by Kinney and Wright⁶ showed a short-term survival rate of only 19% in these patients, underlining the utmost importance of timing and rapid clinical decision-making.⁶ This might be considered an advantage for thrombolytic therapy, which can be started instantly and without the need for any special infrastructures. No comparative studies have focused on the cost and length of stay between the different treatment modalities for RHT. With respect to PE-related experiences, a recent update of a Cochrane database systematic review showed no significant difference in the length of

hospitalization between patients undergoing thrombolytic therapy and those receiving heparin alone (mean difference: -0.89 , 95% confidence interval: -3.13 to 1.34).⁹ Similarly, thrombolytic therapy is assumed to have a slightly higher total lifetime health care cost than anticoagulation alone.¹⁰ In contrast, major reports on pulmonary embolectomy have shown significantly longer intensive care unit lengths of stay, longer hospitalization periods, and consequently higher costs of surgery than with medical management.^{11,12}

Barrios et al.¹³ recently reported no differences between anticoagulation alone and reperfusion therapy with respect to all-cause death (6.2% vs. 14%, respectively) or PE-related mortality (4.7% vs. 7.8%, respectively) through a propensity score matched-pairs analysis. Nevertheless, the authors failed to provide any information concerning the type of RHT in that study. We believe that knowing the type of RHT is crucial and that it might have easily influenced the result of their analysis because the recommended treatment of in situ thrombosis is anticoagulation alone, as mentioned earlier.

The major disadvantage of thrombolytic therapy is bleeding. As Chatterjee et al.¹⁴ clearly demonstrated in their meta-analysis, fibrinolytics significantly decreased all-cause mortality in patients with PE at the expense of a considerable increase in major and intracranial bleeding. The bleeding complications were also the main reason for neutralization of the survival effect of thrombolytic therapy in patients with submassive PE in the famous PEITHO trial.¹⁵ Consequently, investigators have proposed various strategies for decreasing the hemorrhagic adverse events, and one of these strategies is half-dose or safe-dose thrombolytic therapy. In an early reports, Sharifi et al.³ compared the value of half-dose fibrinolytics with that of anticoagulation alone in patients with submassive PE. The primary end point of the study was a reduction in

the pulmonary artery pressure, which developed in 16% of the anticoagulation-only group and 57% of the thrombolytic group ($P < 0.001$). Sharifi et al.³ also reported that the length of hospital stay and a combination of death and recurrent PE were significantly decreased in the patients receiving fibrinolytics. Furthermore, they reported no bleeding complications in either of the groups. Kiser et al.¹⁶ recently published a retrospective cohort study comparing half-dose and full-dose thrombolytic therapies in patients with PE. Although the need for treatment escalation was more frequent in the half-dose group (53.8% vs. 41.4%, $P < 0.01$), hospital mortality was reported similar in both groups (13% vs. 15%). The superiority of the half-dose regimen in terms of bleeding adverse events was also demonstrated by Wang et al.¹⁷ in their small trial comparing half-dose and full-dose regimens (3% vs. 10%, respectively) in patients with submassive PE.

In our small case series, we evaluated the safety and efficacy of half-dose thrombolytic therapy in patients presenting with PE and FRHT. Our first group of patients had a considerable risk of hemorrhagic events; therefore, we concluded that full-dose thrombolytic therapy had an increased risk of adverse events and consequently opted for the half-dose strategy. Notably, we categorized all patients as having submassive PE, for which the clinical value of full-dose fibrinolytics is still debated. Apart from the full resolution of intracardiac thrombosis, the imaging follow-up during hospitalization showed that the right heart echocardiographic indices were also significantly improved, which can be of prognostic importance considering the concomitant PE. The half-dose regimen was also successful in resolving the thrombi accompanying the device (case 3), which at first glance might have required a larger dose of thrombolytic therapy. Importantly, no minor or major bleeding complications occurred in this small, albeit high-risk, population. As

described in Cases 6 and 7, we still do not recommend the application of this method for a clot in transit from a PFO because of potential left heart embolization during thrombolytic therapy. Data on the present group of patients were collected from our PE registry, in which all patients routinely undergo a strict follow-up program. During the 1-year follow-up, the first three patients and the sixth and seventh patients had significant RV function recovery with no CTEPH development or venous thromboembolic event recurrence. The patient with CTEPH (Case 4) was referred for balloon pulmonary angioplasty and developed two more episodes of segmental PE. Further tests revealed positive antiphospholipid antibodies. Finally, our fifth patient, who had severe heart failure, exhibited no significant improvement in the RV function compared with his discharge evaluation; however, no further venous thromboembolic events occurred.

In conclusion, half-dose thrombolytic therapy was a successful strategy in the treatment of FRHT, with satisfactory efficacy in resolving both intracardiac and pulmonary vasculature thromboses as well as potentially lowering the risk of bleeding. The suggested regimen must be tested in larger series before its use becomes more widespread, which is rather difficult because of the low prevalence of this condition.

Acknowledgements

The authors would like to thank Sara Tayebi and Nahid Rafiee for their valuable assistance in the preparation of the images.

Declaration of conflicting interest

The author(s) declared no potential conflicts of interest with respect to the research, authorship, and/or publication of this article.

Funding

This research received no specific grant from any funding agency in the public, commercial, or not-for-profit sectors.

ORCID iD

Parham Sadeghipour  <https://orcid.org/0000-0001-9602-0513>

Supplementary Material

Supplemental Material is available for this article online.

References

1. Chapoutot L, Nazeyrollas P, Metz D, et al. Floating right heart thrombi and pulmonary embolism: diagnosis, outcome and therapeutic management. *Cardiology* 1996; 87: 169–174.
2. The European Cooperative Study on the clinical significance of right heart thrombi. European Working Group on Echocardiography. *Eur Heart J* 1989; 10: 1046–1059.
3. Sharifi M, Bay C, Skrocki L, et al. Moderate pulmonary embolism treated with thrombolysis (from the “MOPETT” Trial). *Am J Cardiol* 2013; 111: 273–277.
4. Patel AK, Kafi A, Bonet A, et al. Resolution of a mobile right atrial thrombus complicating acute pulmonary embolism with low-dose tissue plasminogen activator in a patient with recent craniotomy. *J Intensive Care Med* 2016; 31: 618–621.
5. Konstantinides SV, Torbicki A, Agnelli G, et al. 2014 ESC guidelines on the diagnosis and management of acute pulmonary embolism. *Eur Heart J* 2014; 35: 3033–3069, 69a–69k.
6. Kinney EL and Wright RJ. Efficacy of treatment of patients with echocardiographically detected right-sided heart thrombi: a meta-analysis. *Am Heart J* 1989; 118: 569–573.
7. Chartier L, Bera J, Delome M, et al. Free-floating thrombi in the right heart: diagnosis, management, and prognostic indexes in 38 consecutive patients. *Circulation* 1999; 99: 2779–2783.

8. Rose PS, Punjabi NM and Pearse DB. Treatment of right heart thromboemboli. *Chest* 2002; 121: 806–814.
9. Hao Q, Dong BR, Yue J, et al. Thrombolytic therapy for pulmonary embolism. *Cochrane Database Syst Rev* 2018; 12: Cd004437.
10. Perloth DJ, Sanders GD and Gould MK. Effectiveness and cost-effectiveness of thrombolysis in submassive pulmonary embolism. *Arch Intern Med* 2007; 167: 74–80.
11. Shiomi D, Kiyama H, Shimizu M, et al. Surgical embolectomy for high-risk acute pulmonary embolism is standard therapy. *Interact Cardiovasc Thorac Surg* 2017; 25: 297–301.
12. Neely RC, Byrne JG, Gosev I, et al. Surgical embolectomy for acute massive and submassive pulmonary embolism in a series of 115 patients. *Ann Thorac Surg* 2015; 100: 1245–1251; discussion 51-2.
13. Barrios D, Chavant J, Jimenez D, et al. Treatment of right heart thrombi associated with acute pulmonary embolism. *Am J Med* 2017; 130: 588–595.
14. Chatterjee S, Chakraborty A, Weinberg I, et al. Thrombolysis for pulmonary embolism and risk of all-cause mortality, major bleeding, and intracranial hemorrhage: a meta-analysis. *JAMA* 2014; 311: 2414–2421.
15. Meyer G, Vicaut E, Danays T, et al. Fibrinolysis for patients with intermediate-risk pulmonary embolism. *N Engl J Med* 2014; 370: 1402–1411.
16. Kiser TH, Burnham EL, Clark B, et al. Half-dose versus full-dose alteplase for treatment of pulmonary embolism. *Crit Care Med* 2018; 46: 1617–1625.
17. Wang C, Zhai Z, Yang Y, et al. Efficacy and safety of low dose recombinant tissue-type plasminogen activator for the treatment of acute pulmonary thromboembolism: a randomized, multicenter, controlled trial. *Chest* 2010; 137: 254–262.