

# Large Multilocular Cystic Lesions in the Uterine Cervix: Differential Diagnosis and Significance

Ahmed Samy El-Agwany\*

Department of Obstetrics and Gynecology, Faculty of Medicine, Alexandria University, Alexandria, Egypt

## Abstract

**Introduction:** Cervical nabothian cysts are common in women of reproductive age. Although cysts are generally small and asymptomatic, large ones are extremely rare and may be misdiagnosed as malignancy. **Case Study:** We report a case of large multiple complex nabothian cyst, which was suspected as malignant one on imaging and examination. Pelvic examination and ultrasonography revealed ballooned cervix with multiple large complex nabothian follicles. There was an associated large adnexal mass with ascites. The patient was treated with total hysterectomy and omentectomy after aspiration of the fluid from the cervical cysts for debulking and limiting complications. Pathology revealed granulosa cell ovarian tumor, omental panniculitis, and cervical nabothian follicles. **Conclusion:** Large nabothian cysts should be kept in mind for differential diagnosis of cervical tumors. Ultrasonography is of value for the diagnosis of giant nabothian cysts and can aid in exclusion of malignancy. Differentiation between a malignant cystic lesion, such as an adenoma malignum, and a benign cystic lesion is crucial but difficult. Cervical nabothian follicles can be multiple and attain a large size up to 4 cm each. It is commonly benign but we should keep in mind the rare adenoma malignum on imaging and histopathology.

**Keywords:** Adenoma malignum, nabothian follicle, ultrasound

## INTRODUCTION

Nabothian cysts are common in reproductive women. They are multiple, translucent or opaque, and whitish to yellow on examination. Nabothian cysts usually occur at the transformation zone of the uterine cervix and are a few millimeters to 4 cm in diameter.<sup>[1]</sup> Although they are usually small and asymptomatic, large ones are rare and may be suspected as benign or malignant tumors. Multilocular cystic lesions in the uterine cervix can vary widely from benign to malignant because any cervical glandular proliferation can show multicystic spaces.<sup>[1-4]</sup> Differentiation between a malignant cystic lesion, such as an adenoma malignum, and a benign cystic lesion is crucial but difficult.<sup>[1-4]</sup>

## CASE REPORT

A 47-year-old woman, G4P3+1, normal vaginal delivery (NVD), last delivery since 18 years with irregular menses was referred to our hospital complaining of lower abdominal

pain and distension. Examination revealed bulky large edematous soft cervix larger than the uterine size with no parametrial affection with no friable tissue passing or necrosis. Ultrasound revealed endometrial thickness about 9 mm and well-defined endometrial–myometrial junction. Cervix was enlarged about 10 cm × 7 cm with Doppler study showing intracervical moderate vascularity with resistive index 0.48. The cervix showed a mass with a multilobulated pattern of multiple complex cystic lesions with largest one about 3 cm with echogenic contents with no vascularity. Furthermore, right heterogenous adnexal mass about 18 cm × 15 cm mainly solid with cystic areas and low vascularity with high resistance was detected. Furthermore, low moderate ascites was detected. Both kidneys were free. Tumor markers as carcinoembryonic antigen cancer antigen and alpha-fetoprotein were normal.

**Address for correspondence:** Dr. Ahmed Samy El-Agwany, Shatby Gyne-Oncology Specialized Center, Faculty of Medicine, Alexandria University, Egypt.  
E-mail: ahmedsamyagwany@gmail.com, ahmed.elagwany@alexmed.edu.eg

Received: 08-12-2017 Accepted: 12-02-2018 Available Online: 07-05-2018

### Access this article online

Quick Response Code:



Website:  
www.jmuonline.org

DOI:  
10.4103/JMU.JMU\_38\_18

This is an open access journal, and articles are distributed under the terms of the Creative Commons Attribution-NonCommercial-ShareAlike 4.0 License, which allows others to remix, tweak, and build upon the work non-commercially, as long as appropriate credit is given and the new creations are licensed under the identical terms.

**For reprints contact:** reprints@medknow.com

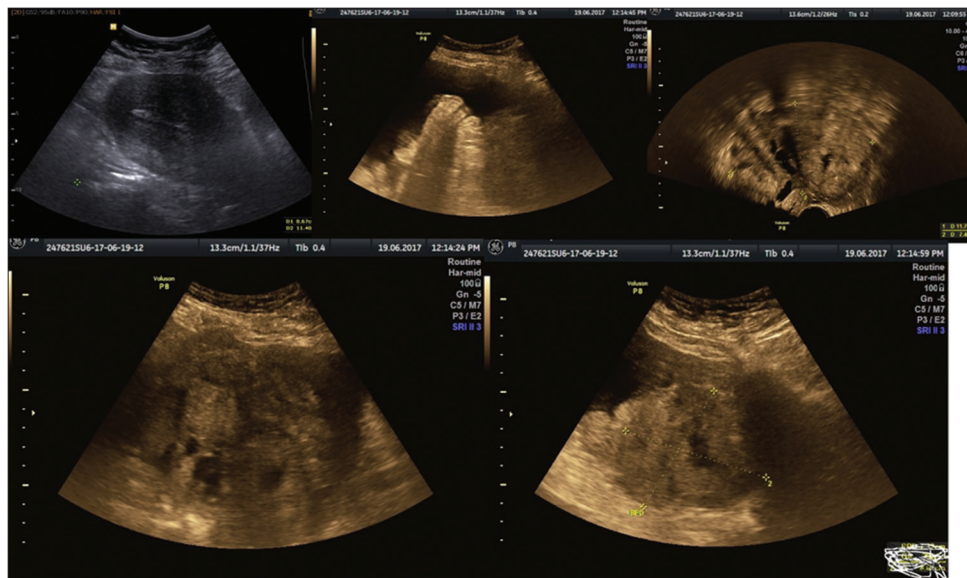
**How to cite this article:** El-Agwany AS. Large multilocular cystic lesions in the uterine cervix: Differential diagnosis and significance. J Med Ultrasound 2018;26:153-6.

A Papanicolaou smear and colposcopy were not performed. Computed tomography scan revealed a large adnexal complex mass about  $11.5 \times 18 \times 14$  with dilated left tortuous gonadal vessel, and cystic lesion ballooning the cervix measuring 8 cm with omental nodule about 1 cm and omental thickening with no lymph nodes detected. According to the findings by pelvic examination and ultrasound imaging, a diagnosis of ovarian neoplasm with suspicion of endophytic cervical cancer was made. No PAP smear or endocervical sampling were done as refused by the patient. Midline line staging laparotomy was done revealing right solid adnexal mass with ballooned cervix, so total hysterectomy after aspirating the fluid content from the cervix for debulking with bilateral salpingo-oophorectomy and infracolic omentectomy was done. The omentum was nodular, firm and torn easily on handling (unhealthy omentum) that could be an early sign of microscopic abdominal spread (metastasis). Pathological

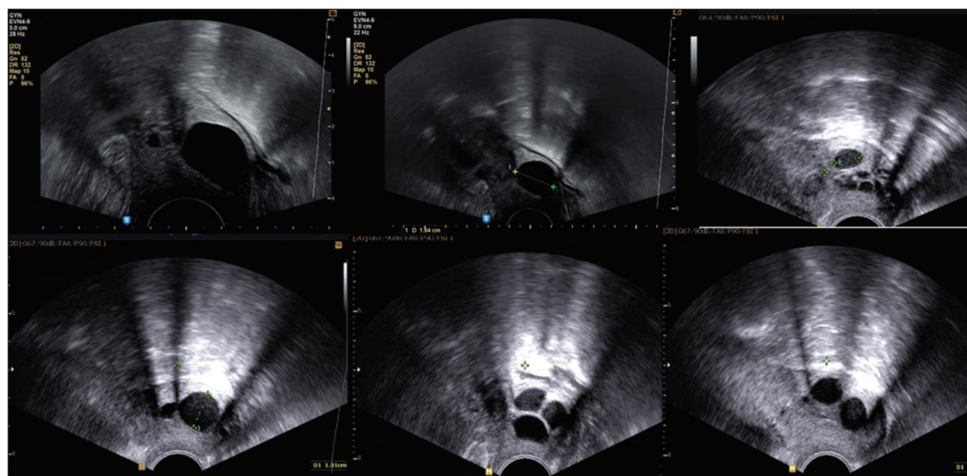
examination reported multiple cervical cystic spaces lined by endocervical type epithelium, which was compatible with a nabothian cyst and ovarian granulosa cell tumor. No evidence of dysplasia or malignancy was seen with granulosa cell tumor with omental panniculitis [Figures 1-4].

## DISCUSSION

Cervical multicystic lesion that invades the deep cervical stroma and contains solid components may suggest a malignancy. This varies from hyperplasia to high-grade malignancy based on the percentage of solid components within a lesion and that was not the case in our patient. In contrast, benign lesions do not deeply invade the cervical stroma, are small size, have well-defined margins, and do not contain solid components.<sup>[1,2]</sup> However, pseudoneoplastic glandular lesions, such as uterine cervicitis, tunnel cluster, deep endocervical glands, deep nabothian cysts,

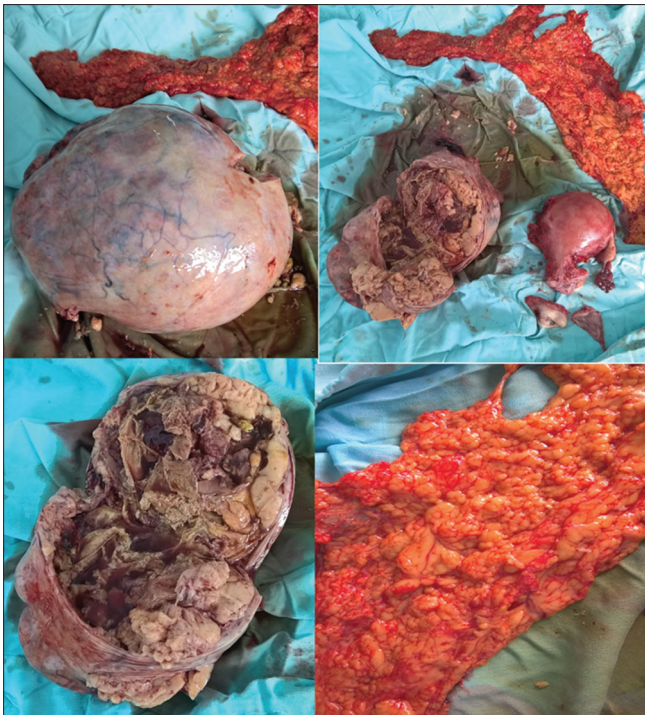

**Figure 1:** Ultrasound revealing normal size uterus, hyperechoic suspicious omentum, solid adnexal mass with cystic areas and ascites



**Figure 2:** Ultrasound showing large multiple complex cysts in the cervix with echogenic contents and debris with posterior acoustic enhancement with low vascularity on Doppler ultrasound

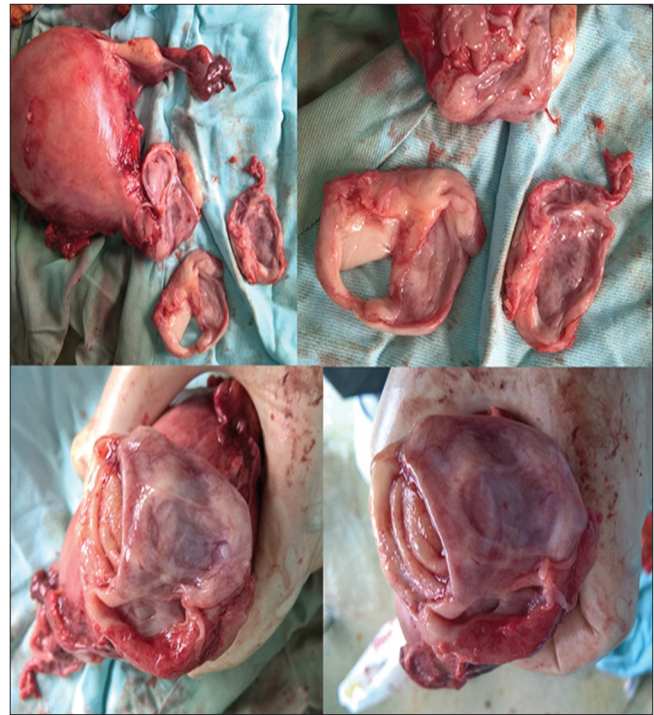




**Figure 3:** hysterectomy specimen showing solid ovarian mass with yellow contents and with omental specimen with nodular appearance of panniculitis

endocervical hyperplasia, metaplasias, endometriosis, and infectious are benign lesions but are often histologically and radiographically confused with adenoma malignum, a malignant multilocular cystic lesions. Differentiating between adenoma malignum and pseudoneoplastic glandular lesions might be impossible and pathologic differentiation is difficult because the histopathological features of these entities are similar. A large amount of watery discharge is known to be a chief clinical symptom observed in adenoma malignum but might also be the chief complaint of patients with tunnel cluster and nabothian cysts with inflammation as our patient was not complaining of that.<sup>[5-7]</sup>

Adenocarcinoma is a subtype of cervical carcinoma, characterized by barrel-shaped cervical mass, with preservation of the endocervical epithelium because of its submucosal location. They tend to affect younger women (<35 years), resulting in a worse prognosis than squamous cell carcinoma, which can be necrotic but usually does not have defined cystic spaces. Adenoma malignum, also known as minimal-deviation adenocarcinoma, is a special subtype of mucinous adenocarcinoma of the cervix.<sup>[1-3]</sup> Its prevalence is about 3% of all cervical adenocarcinomas. The most common symptom is a watery discharge that is often associated with Peutz-Jeghers syndrome (characterized by multiple hamartomatous polyps, most commonly involving the small intestine, but also colon and stomach; mouth and esophagus are spared, mucocutaneous melanin pigmentation involving the mouth, fingers, and toes) and mucinous tumors of the ovary.<sup>[4-7]</sup> An unfavorable prognosis has been reported because it disseminates into the



**Figure 4:** Hysterectomy specimen showing cervix in multiple sections with large multilocular spaces of large cervical cysts

peritoneal cavity even early and responds poorly to radiation or chemotherapy. A multicystic lesion with solid components in the deep cervical stroma on ultrasound can be detected although some benign cystic lesions will have the same picture.<sup>[5,7,8]</sup> The pathologic analysis shows conjugation of small cystic spaces lined predominantly by mucin-containing columnar epithelial cells with cystic spaces filled with mucin. Most of the glands have cellular atypia and structural dysplasia.<sup>[8]</sup>

Benign lesions as uterine cervicitis is associated with tenacious jellylike, yellow, or turbid discharge and a sensation of pelvic pressure or discomfort.<sup>[3]</sup> Uterine cervicitis appears as a round lesion located centrally in the cervix. Endocervical hyperplasia is located in the endocervix and superficial (inner) layer of the cervical wall. It is frequently seen in women who use oral progestational and in women who are pregnant or postpartum.<sup>[9]</sup> Appearing as a thickening of the endocervical mucosa with or without cystic change, endocervical hyperplasia may have a homogeneous solid component and a central and well-delineated geographic map-like aspect.<sup>[8-10]</sup> A nabothian cyst is a common finding that is usually located where one would find endocervical glands; however, it occasionally extends deep into the cervical stroma. They are retention cysts of the cervical glands that are caused by chronic inflammation with scarring.<sup>[10]</sup> Cystic accumulation of mucus within the dilated glands accounts for its imaging features.<sup>[9]</sup> Nabothian cyst appears as a single cystic lesion or as multiple cystic lesions in the fibrous cervical stroma, contiguous and round, with regular boundaries. Multiple nabothian cysts show posterior acoustic enhancement on ultrasound. The small size and well-defined margins may be used to differentiate nabothian

cysts from malignancy.<sup>[8-10]</sup> A tunnel cluster is a type of nabothian cyst characterized by complex multicystic dilatation of the endocervical glands.<sup>[3]</sup> It is a benign pseudoneoplastic glandular lesion of the cervix. It is found in approximately 8% of adult women, 40% of whom are pregnant, almost exclusively multigravida women, and older than 30 years. Tunnel cluster is more likely the result of a stimulatory phenomenon occurring during pregnancy that can persist for a variable period of time and is usually comprised of a rounded aggregate of 20–50 closely packed tubules of varying sizes.<sup>[10]</sup>

## CONCLUSION

Cervical nabothian follicles can be multiple and attain a large size up to 4 cm each. It is commonly benign but we should keep in mind the rare adenoma malignum on imaging and histopathology. Multilocular cystic lesions in the uterine cervix can vary widely from common benign lesions to malignant lesions rare. Thus, unnecessary hysterectomy can be avoided before histopathologic proof of malignancy and can facilitate prompt. Benign nabothian follicles can be differentiated from others by well defined margins, no solid components, no associated adenaxal masses or intestinal polyps and no excess watery discharge associated.

## Declaration of patient consent

The authors certify that they have obtained all appropriate patient consent forms. In the form, the patient has given her consent for her images and other clinical information to be reported in the journal. The patients understand that their names and initials will not be published and due efforts will be made to conceal their identity, but anonymity cannot be guaranteed.

## Financial support and sponsorship

Nil.

## Conflicts of interest

There are no conflicts of interest.

## REFERENCES

- Okamoto Y, Tanaka YO, Nishida M, Tsunoda H, Yoshikawa H, Itai Y, *et al.* MR imaging of the uterine cervix: Imaging-pathologic correlation. *Radiographics* 2003;23:425-45.
- Okamoto Y, Tanaka YO, Nishida M, Tsunoda H, Yoshikawa H. Pelvic imaging: Multicystic uterine cervical lesions. Can magnetic resonance imaging differentiate benignancy from malignancy? *Acta Radiol* 2004;45:102-8.
- Sugiyama K, Takehara Y. MR findings of pseudoneoplastic lesions in the uterine cervix mimicking adenoma malignum. *Br J Radiol* 2007;80:878-83.
- Oguri H, Maeda N, Izumiya C, Kusume T, Yamamoto Y, Fukaya T, *et al.* MRI of endocervical glandular disorders: Three cases of a deep nabothian cyst and three cases of a minimal-deviation adenocarcinoma. *Magn Reson Imaging* 2004;22:1333-7.
- Yoden E, Mikami Y, Fujiwara K, Kohno I, Imajo Y. Florid endocervical glandular hyperplasia with pyloric gland metaplasia: A radiologic pitfall. *J Comput Assist Tomogr* 2001;25:94-7.
- Mikami Y, Hata S, Melamed J, Fujiwara K, Manabe T. Lobular endocervical glandular hyperplasia is a metaplastic process with a pyloric gland phenotype. *Histopathology* 2001;39:364-72.
- De Graef M, Karam R, Juhan V, Daclin PY, Maubon AJ, Rouanet JP, *et al.* High signals in the uterine cervix on T2-weighted MRI sequences. *Eur Radiol* 2003;13:118-26.
- Temur I, Ulker K, Sulu B, Karaca M, Aydin A, Gurcu B, *et al.* A giant cervical nabothian cyst compressing the rectum, differential diagnosis and literature review. *Clin Exp Obstet Gynecol* 2011;38:276-9.
- Takatsu A, Shiozawa T, Miyamoto T, Kurosawa K, Kashima H, Yamada T, *et al.* Preoperative differential diagnosis of minimal deviation adenocarcinoma and lobular endocervical glandular hyperplasia of the uterine cervix: A multicenter study of clinicopathology and magnetic resonance imaging findings. *Int J Gynecol Cancer* 2011;21:1287-96.
- Bin Park S, Lee JH, Lee YH, Song MJ, Choi HJ. Multilocular cystic lesions in the uterine cervix: Broad spectrum of imaging features and pathologic correlation. *AJR Am J Roentgenol* 2010;195:517-23.