

Endovascular treatment of middle cerebral artery aneurysm with a (LVIS) device: Comparison of LVIS stent and non-LVIS stent

FEIYU CHEN¹ and XIAOYU FANG²

¹Department of Neurosurgery, Ningbo Second Hospital, Ningbo, Zhejiang 315312;

²Department of Ophthalmology and Otorhinolaryngology, Ningbo Yinzhou Second Hospital, Ningbo, Zhejiang 315040, P.R. China

Received November 7, 2017; Accepted June 6, 2018

DOI: 10.3892/etm.2018.7139

Abstract. Middle cerebral artery (MCA) aneurysm is a serious medical condition mainly occurring in the proximal and bifurcation tracts. Evidence has indicated that endovascular treatment is an effective surgical method for patients with MCA aneurysm. In the present study, the efficacy of endovascular treatment with low-profile visualized intraluminal support (LVIS) stent for MCA aneurysms was evaluated in comparison with that using a non-LVIS stent device. A total of 92 patients who underwent endovascular treatment of MCA aneurysms with LVIS stent or non-LVIS stent were included in the present study. The clinical presentation, aneurysmal characteristics, technical feasibility, procedural complications, as well as angiographic and clinical follow-up results were analyzed. The computed tomography scan demonstrated that endovascular treatment with LVIS stent markedly reduced pre-operative and intra-operative ruptures. It was indicated that endovascular treatment with LVIS stent resulted in less post-operative symptoms and cases of disability according to the modified Rankin scale score. In conclusion, the present outcomes provide evidence that endovascular treatment with an LVIS stent is an efficient method for the treatment of MCA aneurysm.

Introduction

Middle cerebral artery (MCA) aneurysms are among the most common intracranial angioma in the anterior cerebral circulation (1). The MCA bifurcation is a preferred site for aneurysm formation, and is involved in 18-20% in all

aneurysms encountered (2). A clinical study has indicated that MCA aneurysms are typically complex, multi-lobed and incorporate eloquent vascular branches (3). Critical surgical management at strategic points has been applied for the treatment of MCA aneurysms (4). Surgical treatments of poor-grade MCA aneurysms are associated with large sylvian hematomas following prophylactic hinged craniectomy (5). Of note, clinical and radiologic outcomes have suggested that endovascular treatment for MCA aneurysms has an acceptable safety profile with low rates of technical failure and re-treatment (6).

Endovascular treatment has been widely used for the treatment of MCA aneurysms (7). A previous study demonstrated that the low-profile visualized intraluminal support (LVIS) device is a novel tool for the treatment of wide-necked intracranial aneurysms (8). Endovascular and surgical options for ruptured MCA aneurysms indicate the superiority of endovascular vs. open microneurosurgical clipping for the treatment of ruptured MCA bifurcation aneurysms (9). A study also reported that the feasibility of the endovascular treatment of MCA aneurysms may be assessed by using a procedural 3D imaging and remodeling technique (10). Endovascular treatment of MCA aneurysms with coils may be successfully performed without inducing any neurologic deficits in most patients (11). In addition, endovascular treatment may be safely and effectively performed in selected cases of MCA aneurysm (12). Initial subtotal aneurysm occlusion may progress to total occlusion (13). Furthermore, endovascular treatment for MCA aneurysms decreased the morbidity and mortality rates compared with those achieved by conventional clipping, which suggested that combined treatment by endovascular and bypass surgery is capable of efficiently treating giant complex fusiform MCA aneurysms (14). Of note, a previous study has indicated that stent assistance contributed to the beneficial effect of endovascular treatment of MCA aneurysms, and identified that stent assistance achieves total or subtotal occlusion of large and giant aneurysms in 90% of cases (15).

In the present study, the efficacy of endovascular treatment with stent was evaluated in a total of 92 patients with MCA aneurysm. The clinical presentation, aneurysmal

Correspondence to: Professor Feiyu Chen, Department of Neurosurgery, Ningbo Second Hospital, 41 Xibei Street, Ningbo, Zhejiang 315312, P.R. China
E-mail: chenfeiyuprof@outlook.com

Key words: middle cerebral artery, low-profile visualized intraluminal support stent, endovascular treatment

characteristics, technical feasibility and procedural complications, as well as the angiographic and clinical follow-up results were compared between patients who were treated with LVIS stent or non-LVIS stent.

Materials and methods

Patient population. The present study included 92 patients with MCA aneurysm who presented at Ningbo Second Hospital (Ningbo, China) between June 2014 and May 2016. Patients who underwent surgical with LVIS device or non-LVIS stent were recruited. Patients were offered the choice between LVIS device or a non-LVIS stent. A total of 50 patients were male (54.3%) and 42 patients were female (45.7%). Their age ranged from 42.3 to 65.4 years (mean age, 53.85±11.55 years). A total of 53 patients (57.6%) received endovascular treatment with LVIS stent and 39 (42.4%) received endovascular treatment with non-LVIS stent (Table I). The major exclusion criteria were as follows: A World Federation of Neurosurgical Societies grade 5 (16), massive cerebral infarction (>50% of the MCA aneurysms) demonstrable on computed tomography (CT) examination, and patients with a history of tumor, migraine, cerebral hemorrhage or brain surgery injury. The major inclusion criteria were as follows: Digital subtraction angiography imaging studies demonstrating occlusion of a unilateral internal carotid artery or MCA and a modified Rankin Scale (mRS) score of 0-2 (17). NRS scores of patients were determined as described previously (18).

Surgical procedure and LVIS stenting. All surgical procedures were performed under general anesthesia using biplane angiographic equipment. The 6F guiding catheter was placed in the distal V2 segment of the vertebral artery. Reconstructive treatment included the LVIS stent-assisted or non-LVIS stent treatment. Stent sizes were selected according to the largest diameter of the parent artery and the length of the aneurysm. Other details of the surgical procedure were identical to those described previously (19).

Angiographic and clinical assessment and follow-up. Clinical outcomes were evaluated at the 6-month follow up. The efficacy of endovascular treatment with LVIS stent or non-LVIS stent was analyzed according to the Raymond classification (20). The pre- and post-operative angiographic analysis was generally performed at 0 and 6 months by using magnetic resonance angiography followed by digital subtraction angiography (21).

CT scans. The MCA aneurysm patients were subjected to pre- and post-operative CT scanning, and the volume of aneurysms (V) was calculated using the following formula: $V = a \times b \times c / 2$, with a, height; b, length; and c, width. CT was performed to identify the lesions as described previously (22). The clinical outcome at 6 months was evaluated using the Glasgow outcome scale (23).

Headache score. The improvement of headache was determined by assessing the headache at the 6-month follow-up compared with the pre-operative one. In the present study,

Table I. Clinical data of middle cerebral artery aneurysm patients.

Characteristic	Males	Females	P-value
Patients	50 (54.3%)	42 (45.7%)	0.68
Age (years)	42.3-62.6	45.2-65.4	0.24
Headache and dizziness (pre-treatment)	12 (13.0%)	10 (10.9%)	0.86
Ischemic infarction	7 (7.6%)	4 (4.3%)	0.034
Neck pain	18 (19.6%)	15 (16.3%)	0.62
Mass effect	23 (25.0%)	10 (10.9%)	0.028
Asymptomatic	12 (13.0%)	7 (7.6%)	0.025
Initial Raymond grade			
1	19 (20.7%)	17 (18.5%)	0.83
2	17 (18.5%)	14 (15.2%)	0.62
3	14 (15.2%)	11 (12.0%)	0.78
Procedural complications	10 (10.9%)	8 (8.7%)	0.86
Aneurysm length (mm)	4.5-13.8	5.2-14.6	0.75
Stent treatment			
LVIS	28 (30.4%)	25 (27.2%)	0.75
Non-LVIS	22 (23.9%)	17 (18.5%)	0.36

Values are expressed as n (%) or range. LVIS, low-profile visualized intraluminal support.

‘markedly improved headaches’ were defined as an increase in pain scores by 3-5 points determined by a numeric rating scale (NRS) (24).

Statistical analysis. Statistical analyses were performed using SPSS 19.0 (IBM Corp., Armonk, NY, USA). Headache improvement of patients after endovascular treatment with LVIS stent or non-LVIS stent was compared using the unpaired 2-tailed t-test, Mann-Whitney U-test or Pearson's χ^2 test. $P < 0.05$ was considered to indicate a statistically significant difference.

Results

Characteristics of MCA aneurysm patients. A total of 92 patients with MCA aneurysm were recruited in the present study. The mean age of the MCA aneurysm patients was 53.85±11.55 years. The cohort included 50 male and 42 female patients. The clinical, demographic and angiographic characteristics of the MCA aneurysm patients are summarized in Table I. No significant difference between the two groups was observed for ischemic infarction and mass effect. A flow chart indicating the stages of the present study is provided in Fig. 1.

Procedural complications and clinical outcome. All patients with MCA aneurysm received successful endovascular treatment with LVIS stent or non-LVIS stent. The outcomes indicated that endovascular treatment with LVIS stent removed a larger amount of hematoma compared with the non-LVIS stent. Head angiography demonstrated that the aneurysms in the MCA were removed in all patients after endovascular

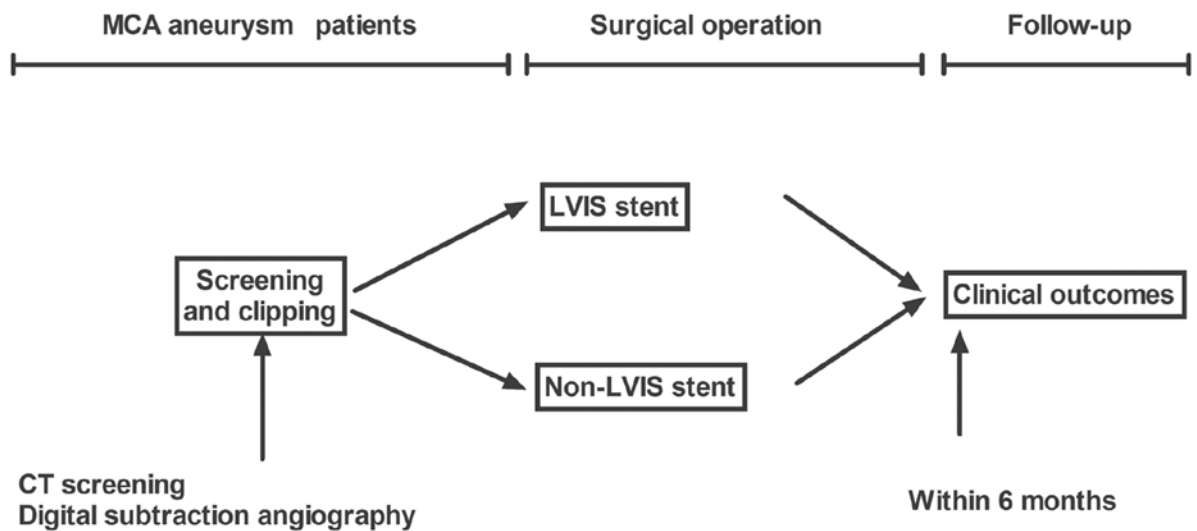


Figure 1. Study design and stages of this study. CT, computed tomography; MCA, middle cerebral artery; LVIS, low-profile visualized intraluminal support.

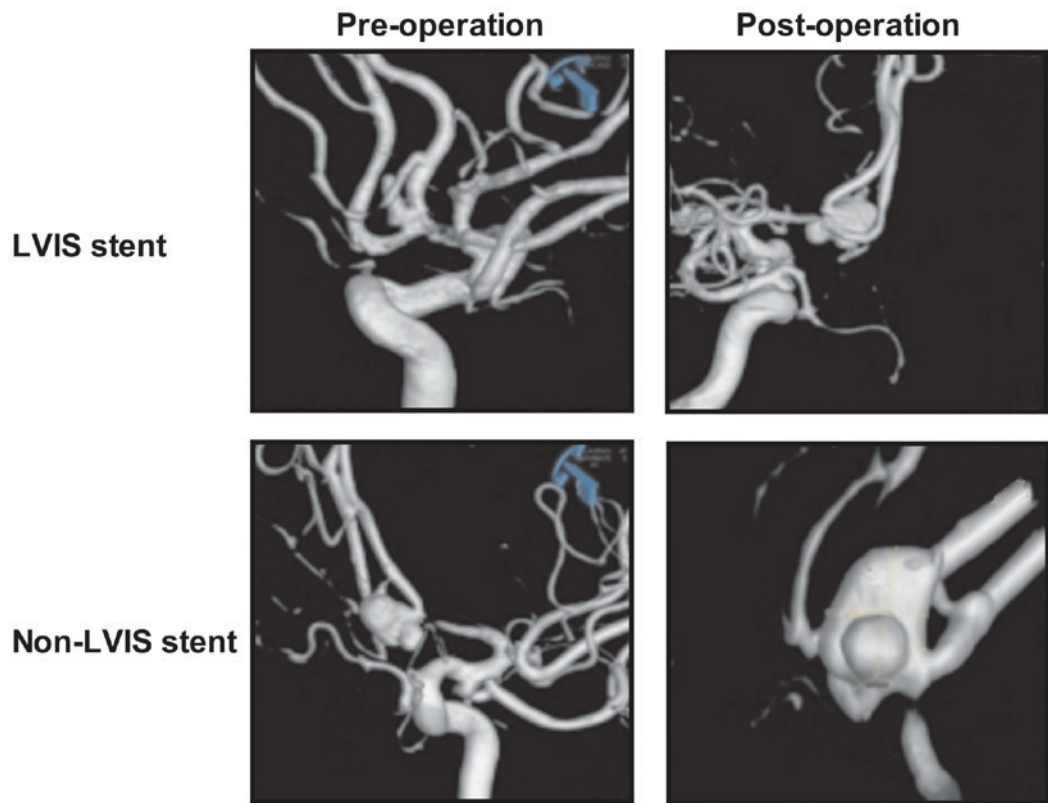


Figure 2. Angiography of the head compared between patients with middle cerebral artery aneurysms treated with LVIS stent and non-LVIS stent.

treatment with LVIS stent or non-LVIS stent (Fig. 2). It was observed that those patients who received endovascular treatment with LVIS stent exhibited a better recovery according to the GOS score compared with those subjected to endovascular treatment with non-LVIS stent (Table II).

Clinical outcome at follow-up. At follow-up, the mean headache NRS score in the majority of patients who had received endovascular treatment with LVIS stent was lower compared with that in the patients subjected to endovascular treatment with non-LVIS stent. The post-operative headaches of the

92 MCA aneurysm patients, including duration, frequency, quality and intensity, based on the NRS score, are listed in Table III. Outcomes demonstrated that 4 (7.5%) patients experienced headache daily, 3 (5.7%) had a headache on 5-15 days per month and 46 (86.8%) patients had a headache less frequently than that after endovascular treatment with LVIS stent. However, 8 (20.5%) patients suffered from headache daily, 10 (25.6%) patients had a headache on 5-15 days per month and 21 (53.8%) patients had a headache less frequently than that after endovascular treatment with non-LVIS stent within the 6-months follow-up. Representative angiography

Table II. Clinical outcomes and mean ratio of hematoma removal.

Parameter	LVIS stent (n=53)	Non-LVIS stent (n=39)	P-value
Removal ratio of hematoma in the first operation	0.26±0.046	0.35±0.050	0.024
GOS			
1	5 (9.4%)	8 (20.5%)	0.042
2	4 (7.5%)	10 (25.6%)	0.015
3	8 (19.0%)	4 (10.3%)	0.030
4	8 (19.0%)	5 (12.8%)	0.042
5	28 (52.8%)	12 (30.8%)	0.0048

Values are expressed as the mean ± standard deviation or n (%). GOS levels: 1, death; 2, persistent vegetative state; 3, severely disabled; 4, moderately disabled; 5, good outcome. GOS, Glasgow outcome scale; LVIS, low-profile visualized intraluminal support.

Table III. Characteristics of post-operative headache.

Characteristic	LVIS stent (n=53) (%)	Non-LVIS stent (n=39) (%)	P-value
Frequency			
Daily	4 (7.5)	8 (20.5)	0.036
5-15 days/month	3 (5.7)	10 (25.6)	0.022
15-30 days/year	46 (86.7)	21 (53.8)	0.0048
Duration			
<1 h	14 (26.4)	6 (15.4)	0.0065
1-12 h	2 (3.8)	6 (15.4)	0.036
1-2 days	3 (5.7)	8 (20.5)	0.022
2-7 days	1 (1.9)	5 (12.8)	0.0088
Features			
Swelling	1 (1.9)	3 (7.7)	0.0092
Pressure-like	1 (1.9)	2 (5.1)	0.088
Throbbing	2 (3.8)	3 (7.7)	0.078
Stabbing	1 (1.9)	4 (10.3)	0.0083
Other	2 (3.8)	1 (2.6)	0.688
Intensity			
<1	46 (86.8)	30 (76.9)	0.0046
1-3	5 (9.4)	3 (7.7)	0.56
4-7	1 (1.9)	4 (7.5)	0.0083
8-10	1 (1.9)	2 (5.1)	0.688

Values are expressed as n (%). Intensity was determined by the headache score. LVIS, low-profile visualized intraluminal support.

images of LVIS stent and non-LVIS stent cases were shown in Fig. 3. The results of the LVIS stent use exhibited an improved vascular morphology within the aneurysm compared with the non-LVIS stent treatment.

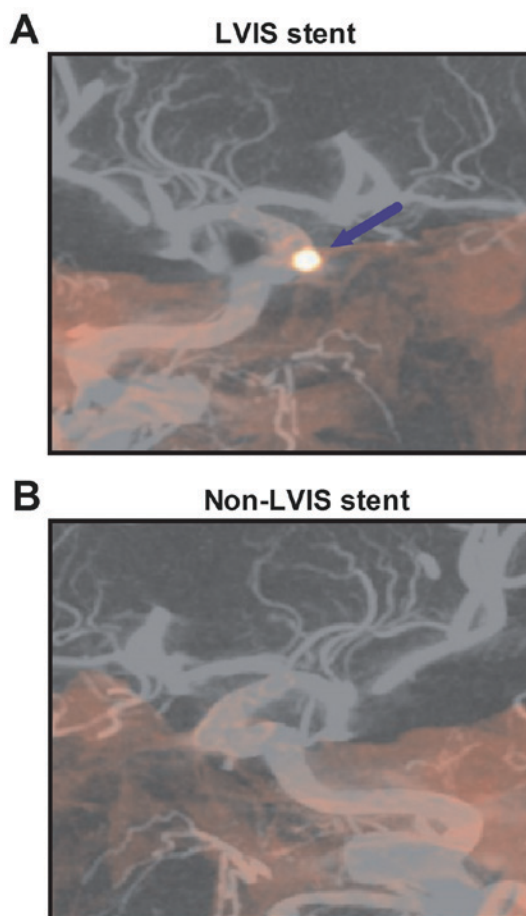


Figure 3. Representative angiography images of cases that received endovascular treatment with (A) LVIS stent and (B) non-LVIS stent. The arrow indicates the left internal carotid artery. LVIS, low-profile visualized intraluminal support.

Clinical efficacy and safety of endovascular treatment with LVIS stent. The CT scan demonstrated that endovascular treatment with LVIS stent significantly improved pre-operative and intra-operative ruptures (data not shown). Outcomes revealed that endovascular treatment with LVIS stent had less post-operative symptoms and less disability than endovascular treatment with non-LVIS stent (Table IV). Exploratory outcomes were assessed to identify potential predictors for headache improvement, intra-operative ruptures and disability following endovascular treatment with LVIS stent and endovascular treatment with non-LVIS stent, which may be used for evaluating improvements of certain symptoms. Outcomes demonstrated that patients in the LVIS stent group exhibited lower levels of chronic migraine, tension-type tension and headache severity compared with the non-LVIS stent group (Table V).

Discussion

MCA aneurysms are the most common types of lesion in the intracranial artery wall, and frequently lead to headache, dizziness, ischemic infarction, neck pain and mass effect, while certain cases may also be asymptomatic (25). Evidence has indicated that LVIS stent assists in the mechanical removal of thromboembolisms after embolization of MCA

Table IV. Clinical complications of endovascular treatment with LVIS stent.

Feature	LVIS stent (n=53) (%)	Non-LVIS stent (n=39) (%)	P-value
Pre-operative ruptures	0 (0)	2 (5.1)	<0.01
Intra-operative ruptures	2 (3.8)	4 (10.3)	0.038
Post-operative symptoms	1 (1.9)	3 (7.7)	0.042
Disability	2 (3.8)	7 (17.9)	<0.01

Values are expressed as n (%). LVIS, low-profile visualized intraluminal support.

Table V. Factors associated with headache outcomes.

Characteristic	LVIS stent (n=53) (%)	Non-LVIS stent (n=39) (%)	P-value
Chronic migraine	2 (3.8)	4 (10.3)	0.84
Tension-type intension	3 (5.7)	6 (15.4)	0.50
Headache severity	2 (3.8)	4 (7.7)	0.84
Posterior circulation	3 (5.7)	5 (12.8)	0.64
Headache improved	43 (81.1)	20 (51.3)	<0.01
Headache not improved	10 (18.9)	19 (48.7)	<0.01

Values are expressed as n (%). LVIS, low-profile visualized intraluminal support.

aneurysms (26,27). In the present study, it was reported that endovascular treatment with LVIS stent efficiently removed MCA aneurysms, significantly improved the clinical symptoms and resulted in favorable outcomes. LVIS stent is a novel device designed as an auxiliary for the endovascular treatment of MCA aneurysms (28). The present study indicated that endovascular treatment with LVIS stent significantly improved headaches compared with endovascular treatment with non-LVIS stent.

Endovascular treatment of MCA aneurysms with the LVIS junior stent provided excellent trackability and deliverability, and is safe and effective in the treatment of wide-necked MCA aneurysms with tortuous and smaller parent vessels (29). The present study reported that endovascular treatment with LVIS stent is a safe method for the treatment of MCA aneurysms in a total of 92 patients, which also significantly improved the symptoms of MCA aneurysms, including the duration, frequency, quality, location and intensity of headaches. Wang *et al* (28) suggested that the LVIS stent has certain hemodynamic effects on cerebral aneurysms. Ge *et al* (30) have indicated that endovascular treatment with LVIS stent may achieve a greater complete or near-complete occlusion rate compared with the non-LVIS stent treatment; however, there was no significant difference in procedure-associated complications and clinical outcomes between cases treated with LVIS and enterprise stents. The present study indicated that endovascular treatment with LVIS stent resulted in less post-operative symptoms and less cases with disability than endovascular treatment with non-LVIS stent. However, the present study only investigated endovascular treatment with the LVIS device in a small population of patients with MCA aneurysms. Further investigation of

cerebral hemodynamics using positron emission tomography after endovascular treatment with the LVIS stent or non-LVIS stent should be performed in the future using a larger number of MCA aneurysm patients.

A previous study has indicated that the LVIS stent is a safe and effective device for endovascular treatment (31). The present study reported that endovascular treatment using the LVIS stent significantly reduced pre-operative and intra-operative ruptures, and resulted in less post-operative symptoms and cases of disability than endovascular treatment with non-LVIS stent according to the mRS.

Zhu *et al* (32) have indicated that the LVIS stent decreased the risk of blood blister-like aneurysm recurrence compared with the non-LVIS stent and did not increase the risk of procedure-associated complications in 37 patients with intracranial carotid artery. Although the present study did not evaluate risk of blood blister-like aneurysm recurrence, it indicated that MCA aneurysm patients who received endovascular treatment with LVIS stent had a better outcome compared with non-LVIS stent group. Of note, exploratory outcomes suggested that endovascular treatment with LVIS stent significantly improved factors associated with headache outcomes, including chronic migraine, tension-type intension, headache severity, posterior circulation.

In conclusion, the present study analyzed the efficacy of endovascular treatment with LVIS stent in patients with MCA aneurysm. It has been previously reported that endovascular treatment with LVIS stent has certain hemodynamic effects on MCA aneurysms. Given the complex technique and the efficacy of endovascular treatment with LVIS stent, this method may be used to decrease headache and post-operative syndrome,

which should be taken into consideration for patients with MCA aneurysm. However, long-term and cohort studies are required to validate these results in larger populations.

Acknowledgements

Not applicable.

Funding

No was funding received.

Availability of data and materials

The analyzed data sets generated during the study are available from the corresponding author on reasonable request.

Authors' contributions

XF performed the experiments, prepared and analyzed experimental data. FC designed the experiments. The final version of the manuscript has been read and approved by all authors.

Ethical approval and consent to participate

This retrospective study was approved by the Ethics Committee of Ningbo Second Hospital (Ningbo, China).

Patient consent for publication

Not applicable.

Competing interests

The authors declare that they have no competing interests.

References

- Diaz OM, Rangel-Castilla L, Barber S, Mayo RC, Klucznik R and Zhang YJ: Middle cerebral artery aneurysms: A single-center series comparing endovascular and surgical treatment. *World Neurosurg* 81: 322-329, 2014.
- Baharoglu MI, Lauric A, Safain MG, Hippelheuser J, Wu C and Malek AM: Widening and high inclination of the middle cerebral artery bifurcation are associated with presence of aneurysms. *Stroke* 45: 2649-2655, 2014.
- Esposito G and Regli L: Reply to the comment on the article 'selective-targeted extra-intracranial bypass surgery in complex middle cerebral artery aneurysms: Correctly identifying the recipient artery using indocyanine green videoangiography': Recipient artery identification. *Neurosurgery* 74: E457-E458, 2014.
- Mrak G, Paladino J, Stambolija V, Nemir J and Sekhar LN: Treatment of giant and large fusiform middle cerebral artery aneurysms with excision and interposition radial artery graft in a 4-year-old child: Case report. *Neurosurgery* 10 (Suppl 1): E172-E177, 2014.
- Wang HJ, Ye YF, Shen Y, Zhu R, Yao DX and Zhao HY: Surgical treatment of poor grade middle cerebral artery aneurysms associated with large sylvian hematomas following prophylactic hinged craniectomy. *J Huazhong Univ Sci Technolog Med Sci* 34: 716-721, 2014.
- Mortimer AM, Bradley MD, Mews P, Molyneux AJ and Renowden SA: Endovascular treatment of 300 consecutive middle cerebral artery aneurysms: Clinical and radiologic outcomes. *AJNR Am J Neuroradiol* 35: 706-714, 2014.
- Eboli P, Ryan RW, Alexander JE and Alexander MJ: Evolving role of endovascular treatment for MCA bifurcation aneurysms: Case series of 184 aneurysms and review of the literature. *Neurol Res* 36: 332-338, 2014.
- Behme D, Weber A, Kowoll A, Berlis A, Burke TH and Weber W: Low-profile visualized intraluminal support device (LVIS Jr) as a novel tool in the treatment of wide-necked intracranial aneurysms: Initial experience in 32 cases. *J Neurointerv Surg* 7: 281-285, 2015.
- Santiago-Dieppa DR, Pannell JS and Khalessi AA: Endovascular and surgical options for ruptured middle cerebral artery aneurysms: Review of the literature. *Stroke Res Treat* 2014: 315906, 2014.
- Vanzin JR, Mounayer C, Piotin M, Spelle L, Boissonnet H and Moret J: Endovascular treatment of unruptured middle cerebral artery aneurysms. *J Neuroradiol* 32: 97-108, 2005.
- Iijima A, Piotin M, Mounayer C, Spelle L, Weill A and Moret J: Endovascular treatment with coils of 149 middle cerebral artery berry aneurysms. *Radiology* 237: 611-619, 2005.
- Lee CY, Kim CH, Sohn SI and Hong JH: Urgent bypass surgery following failed endovascular treatment in acute symptomatic stroke patient with MCA occlusion. *Neurologist* 22: 14-17, 2017.
- Doerfler A, Wanke I, Goericke SL, Wiedemayer H, Engelhorn T, Gizewski ER, Stolke D and Forsting M: Endovascular treatment of middle cerebral artery aneurysms with electrolytically detachable coils. *AJNR Am J Neuroradiol* 27: 513-520, 2006.
- Suzuki S, Tateshima S, Jahan R, Duckwiler GR, Murayama Y, Gonzalez NR and Viñuela F: Endovascular treatment of middle cerebral artery aneurysms with detachable coils: Angiographic and clinical outcomes in 115 consecutive patients. *Neurosurgery* 64: 876-889, 2009.
- Arustamyan SR, Yakovlev SB, Bocharov AV, Bukharin EY, Dorokhov PS, Mikeladze KG and Belousova OB: Endovascular treatment of large and giant intracranial aneurysms using stent assistance. *Zh Vopr Neurokhir Im N N Burdenko* 79: 28-37, 2015 (In English; Russian).
- Inamasu J, Nakae S, Ohmi T, Kogame H, Kawazoe Y, Kumai T, Tanaka R, Wakako A, Kuwahara K, Ganaha T and Hirose Y: The outcomes of early aneurysm repair in World federation of neurosurgical societies grade V subarachnoid haemorrhage patients with emphasis on those presenting with a Glasgow Coma Scale score of 3. *J Clin Neurosci* 33: 142-147, 2016.
- Patel N, Rao VA, Heilman-Espinoza ER, Lai R, Quesada RA and Flint AC: Simple and reliable determination of the modified rankin scale score in neurosurgical and neurological patients: The mRS-9Q. *Neurosurgery* 71: 971-975, 2012.
- Can A, Castro VM, Ozdemir YH, Dagen S, Yu S, Dligach D, Finan S, Gainer V, Shadick NA, Murphy S, *et al*: Association of intracranial aneurysm rupture with smoking duration, intensity, and cessation. *Neurology* 89: 1408-1415, 2017.
- Wang CC, Fang YB, Zhang P, Zhu X, Hong B, Xu Y, Liu JM and Huang QH: Reconstructive endovascular treatment of vertebral artery dissecting aneurysms with the Low-profile visualized intraluminal support (LVIS) device. *PLoS One* 12: e0180079, 2017.
- Stapleton CJ, Torok CM, Rabinov JD, Walcott BP, Mascitelli JR, Leslie-Mazwi TM, Hirsch JA, Yoo AJ, Ogilvy CS and Patel AB: Validation of the modified raymond-roy classification for intracranial aneurysms treated with coil embolization. *J Neurointerv Surg* 8: 927-933, 2016.
- Davis BJ, Oberstar E, Royalty K, Schafer S and Mistretta C: Volumetric limiting spatial resolution analysis of four-dimensional digital subtraction angiography. *J Med Imaging (Bellingham)* 3: 013503, 2016.
- Matsumoto M, Kodama N, Sakuma J, Sato S, Oinuma M, Konno Y, Suzuki K, Sasaki T, Suzuki K, Katakura T and Shishido F: 3D-CT arteriography and 3D-CT venography: The separate demonstration of arterial-phase and venous-phase on 3D-CT angiography in a single procedure. *AJNR Am J Neuroradiol* 26: 635-641, 2005.
- Hong I, Li CY and Velozo CA: Item-Level Psychometrics of the Glasgow Outcome Scale: Extended Structured Interviews. *OTJR (Thorofare N J)* 36: 65-73, 2016.
- Alghadir AH, Anwer S and Iqbal ZA: The psychometric properties of an Arabic numeric pain rating scale for measuring osteoarthritis knee pain. *Disabil Rehabil* 38: 2392-2397, 2016.
- Aoki T, Yoshitomi M, Yamamoto M, Hirohata M and Morioka M: Ruptured de novo aneurysm arising at a site remote from the anastomosis 14 years after superficial temporal Artery-middle cerebral artery bypass: A case report. *Neurosurgery* 71: E905-E909, 2012.

26. Alghamdi F, Mine B, Morais R, Scillia P and Lubicz B: Stent-assisted coiling of intracranial aneurysms located on small vessels: Midterm results with the LVIS Junior stent in 40 patients with 43 aneurysms. *Neuroradiology* 58: 665-671, 2016.
27. Darflinger RJ and Chao K: Using the barrel technique with the LVIS Jr (Low-profile Visualized Intraluminal Support) stent to treat a wide neck MCA bifurcation aneurysm. *J Vasc Interv Neurol* 8: 25-27, 2015.
28. Wang C, Tian Z, Liu J, Jing L, Paliwal N, Wang S, Zhang Y, Xiang J, Siddiqui AH, Meng H and Yang X: Flow diverter effect of LVIS stent on cerebral aneurysm hemodynamics: A comparison with Enterprise stents and the Pipeline device. *J Transl Med* 14: 199, 2016.
29. Feng Z, Li Q, Zhao R, Zhang P, Chen L, Xu Y, Hong B, Zhao W, Liu J and Huang Q: Endovascular treatment of middle cerebral artery aneurysm with the LVIS junior stent. *J Stroke Cerebrovasc Dis* 24: 1357-1362, 2015.
30. Ge H, Lv X, Yang X, He H, Jin H and Li Y: LVIS stent versus enterprise stent for the treatment of unruptured intracranial aneurysms. *World Neurosurg* 91: 365-370, 2016.
31. Luo JJ, Zhang ZH, Liu QX, Zhang W, Wang JH and Yan ZP: Endovascular brachytherapy combined with stent placement and TACE for treatment of HCC with main portal vein tumor thrombus. *Hepato Int* 10: 185-195, 2016.
32. Zhu D, Fang Y, Yang P, Zhang P, Chen L, Xu Y, Hong B, Huang Q and Liu JM: Overlapped stenting combined with coiling for blood Blister-like aneurysms: Comparison of low-profile visualized intraluminal support (LVIS) stent and Non-LVIS stent. *World Neurosurg* 104: 729-735, 2017.



This work is licensed under a Creative Commons Attribution-NonCommercial-NoDerivatives 4.0 International (CC BY-NC-ND 4.0) License.