



Received: 2016.04.15
Accepted: 2016.05.27
Published: 2017.02.25

Authors' Contribution:

- A** Study Design
- B** Data Collection
- C** Statistical Analysis
- D** Data Interpretation
- E** Manuscript Preparation
- F** Literature Search
- G** Funds Collection

Focal Biliary System Obstruction and Atypical Liver Mass: Intrahepatic Ruptured Cyst Hydatid Case Report

Esra Ummuhan Mermi^{ABEF}, Nurdan Fidan^{AEE}, Muammer Murat^{EE}

Department of Radiology, Hitit University, Training and Research Hospital, Corum, Turkey

Author's address: Esra Ummuhan Mermi, Department of Radiology, Hitit University, Training and Research Hospital, Corum, Turkey, e-mail: esraummuhanmermi@gmail.com

| | |
|-----------------------|---|
| Background: | Hydatid disease can involve any part of the body, but the liver is the most frequently affected organ. Intrahepatic rupture is one of the most serious complications of a hepatic hydatid cyst. Radiological findings, especially magnetic resonance imaging and magnetic resonance cholangiopancreatography (MRI/MRCP), are helpful in the diagnosis of hydatid disease. |
| Case Report: | We present a 48-year-old female patient with complaints of abdominal pain and jaundice. Radiological examination showed a heterogeneous lesion that contained cystic-solid components and millimetric calcifications in the liver. Adjacent intrahepatic bile ducts were dilated. |
| Conclusions: | In geographical areas endemic for hydatid disease, cyst rupture into the bile ducts should be included in the differential diagnosis even in seronegative cases, although it is not typical for hydatid cyst to be found as a mass lesion in the liver on US in patients with right upper quadrant pain and jaundice. Detailed imaging by MRI/MRCP should be done. |
| MeSH Keywords: | Bile Ducts, Intrahepatic • Cholangiopancreatography, Magnetic Resonance • Echinococcosis, Hepatic • Jaundice |
| PDF file: | http://www.polradiol.com/abstract/index/idArt/899073 |

Background

Hydatid disease is a parasitic disease caused by *Echinococcus granulosus* which is frequently found in our country. Although it can involve any part of the body, the disease most frequently affects the liver [1]. Hydatid cysts can remain asymptomatic for many years. Symptoms are usually associated with the involved organs, location, impact on adjacent organs, and complications of rupture [1,2]. Cysts may rupture into the bile ducts, thorax, peritoneal or pleural cavity, pericardium or gastrointestinal system. Although rupture into the bile ducts is rare, early diagnosis and treatment are important because of the potential serious complications such as jaundice, cholecystitis, acute cholangitis, liver abscess, pancreatitis, and even septicemia [3,4].

Case Report

A 48-year-old female patient was admitted to the emergency department of our hospital with complaints of abdominal

pain and jaundice. Physical examination showed tenderness in the right upper quadrant and jaundice in association with no abnormal laboratory findings, except for a slight increase in the bilirubin level. The patient was referred to our department for abdominal ultrasonography (US), which revealed a 4×3 cm heterogeneous, hypoechoic lesion in the liver, adjacent to the portal hilus; cystic and solid components and millimetric calcifications were also observed (Figure 1A, 1B). Intrahepatic bile ducts in the area from the portal hilus to segment V were slightly dilated with an increased periportal thickness and decreased echogenicity in the adjacent parenchyma (Figure 1C, 1D). In contrast to previous studies of ruptured hydatid cysts, an atypical heterogeneous liver mass was found, but the patient had no previous history of a hydatid cyst. A ruptured hydatid cyst was nevertheless considered because of the focal dilation of intrahepatic bile ducts and the decreased echogenicity in the periportal parenchyma. Magnetic resonance imaging/magnetic resonance cholangiopancreatography (MRI/MRCP) was recommended, with an initial diagnosis of primary bile duct tumor or intrahepatic ruptured hydatid cyst. Tumor markers

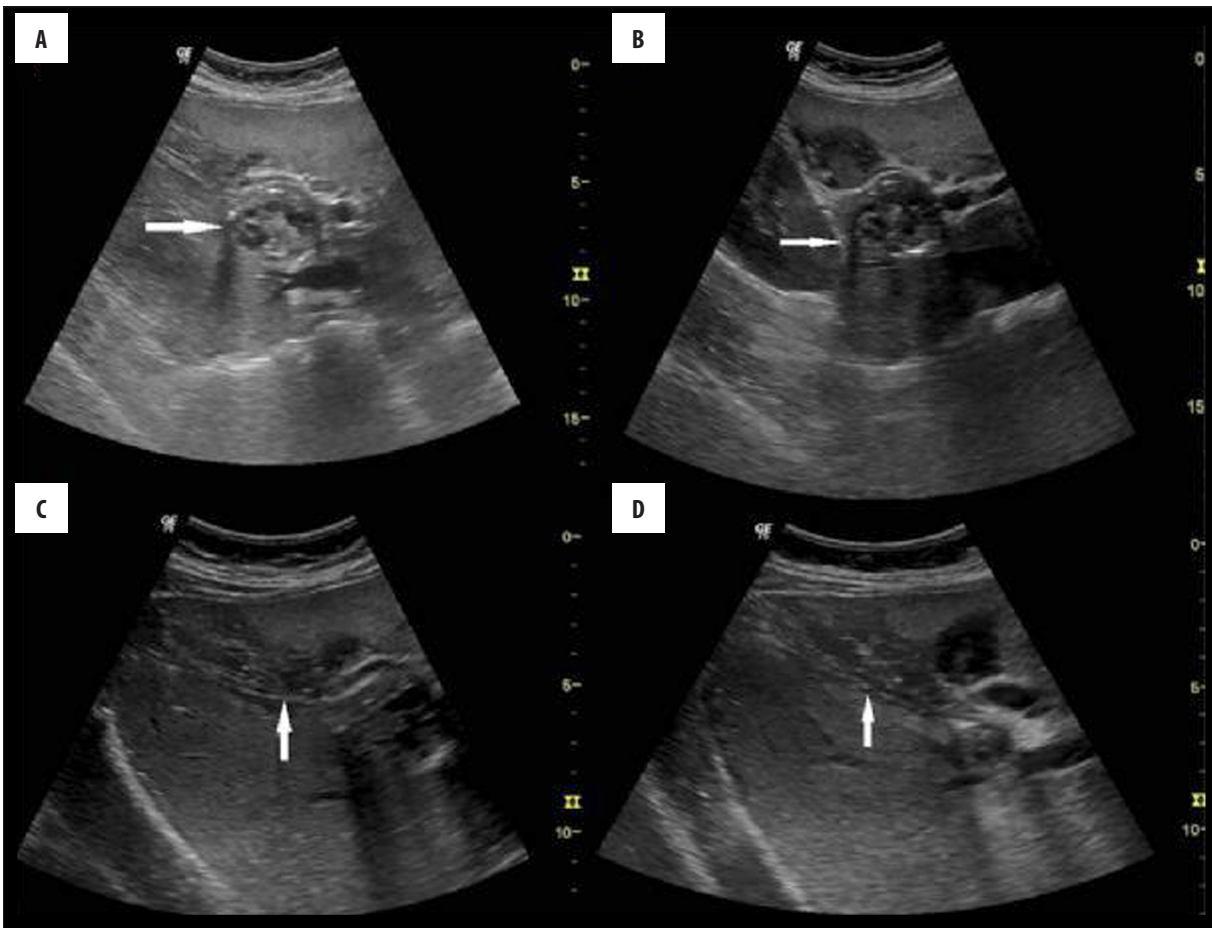


Figure 1. US examination shows a hypoechoic lesion with solid and cystic components having millimetric calcifications (arrow) at the level of the portal hilus in the liver (A, B). It also shows a mild dilation of the intrahepatic bile ducts at segment V of the liver, increased periportal thickness, and decreased echogenicity in the adjacent parenchyma (arrow) (C, D).

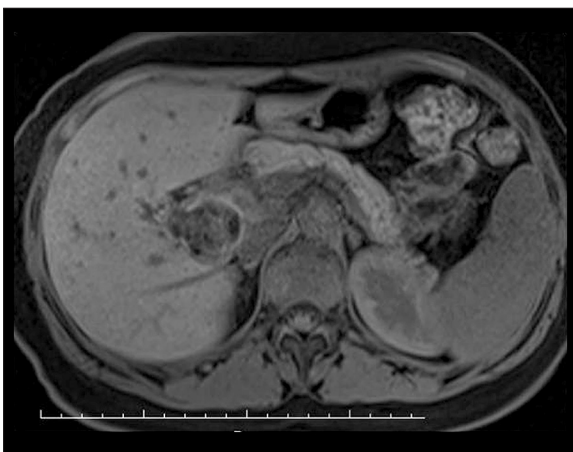


Figure 2. MR imaging shows a heterogeneous hypointense lesion at the level of the portal hilus in the liver on axial T1 fat-suppressed sequences.

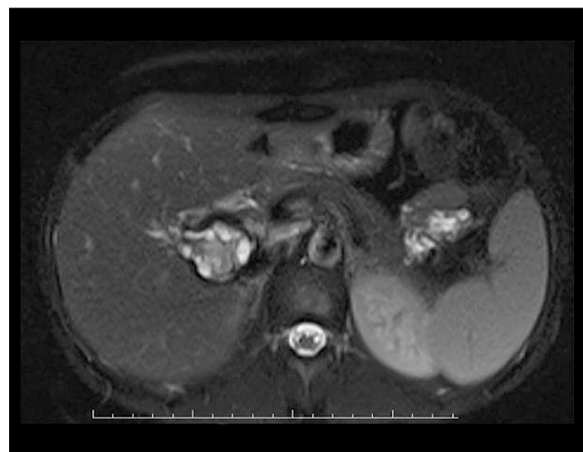


Figure 3. MR imaging shows a heterogeneous hyperintense lesion at the level of the portal hilus in the liver on axial T2 fat-suppressed sequences.

and serology showed no abnormalities. MRI/MRCP revealed a lesion at the level of the portal hilus, which was heterogeneous and hypointense on T1A sequences as well as heterogeneous and hyperintense with low-signal areas on T2A sequences with no contrast-enhancement (Figures 2–5). A slight dilation was observed in the intrahepatic bile ducts at

the level of segment V, as well as a signal change in adjacent parenchyma on T2A and contrast sequences (Figures 5–7). A fine fistula between the mass lesion and the adjacent intrahepatic bile duct was hardly distinguishable on thinner sections (Figure 7). In addition to these findings, US and MRI revealed a diffusely thickened gallbladder wall with

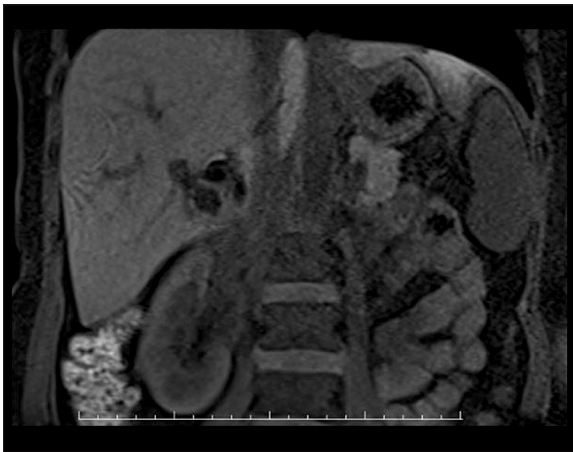


Figure 4. MR imaging shows a heterogeneous hypointense lesion hilum in the liver on coronal T1 fat-suppressed sequences.

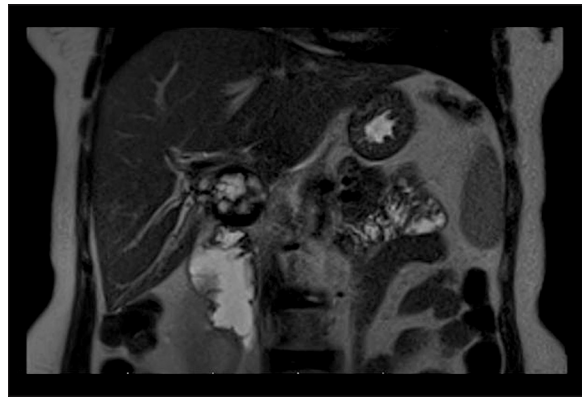


Figure 6. MR imaging shows a heterogeneous hyperintense lesion with a low signal in its periphery and mildly dilated adjacent intrahepatic bile ducts at the level of segment V on coronal T2 fat-suppressed sequences.

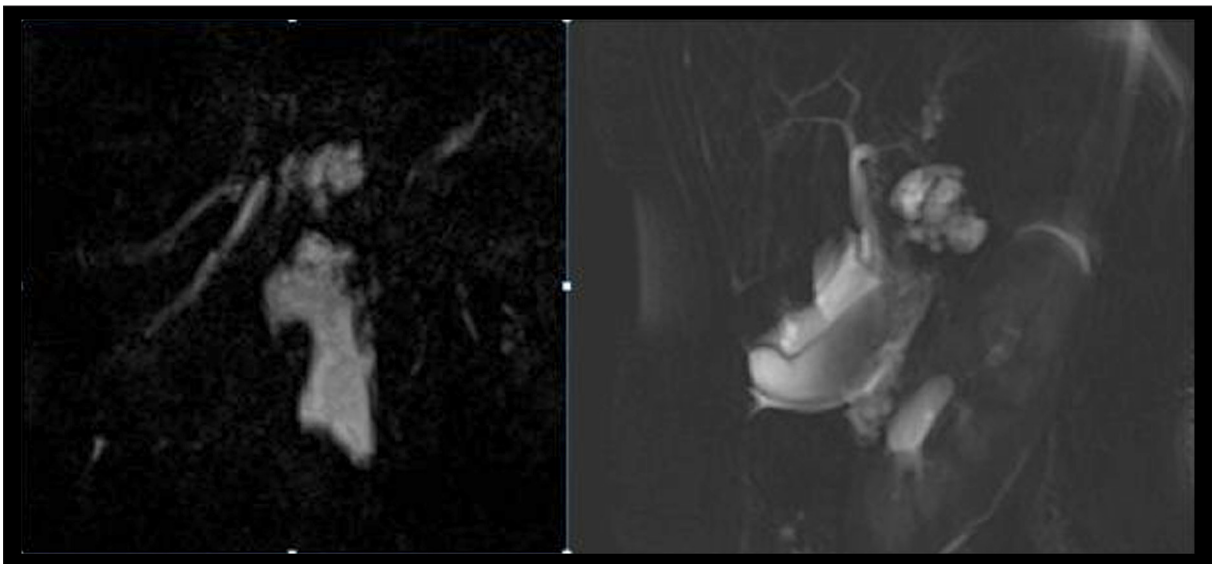


Figure 5. MRCP images show a high-signal lesion, focal dilatation in the intrahepatic bile ducts, and fluid (in the right) around the gallbladder.

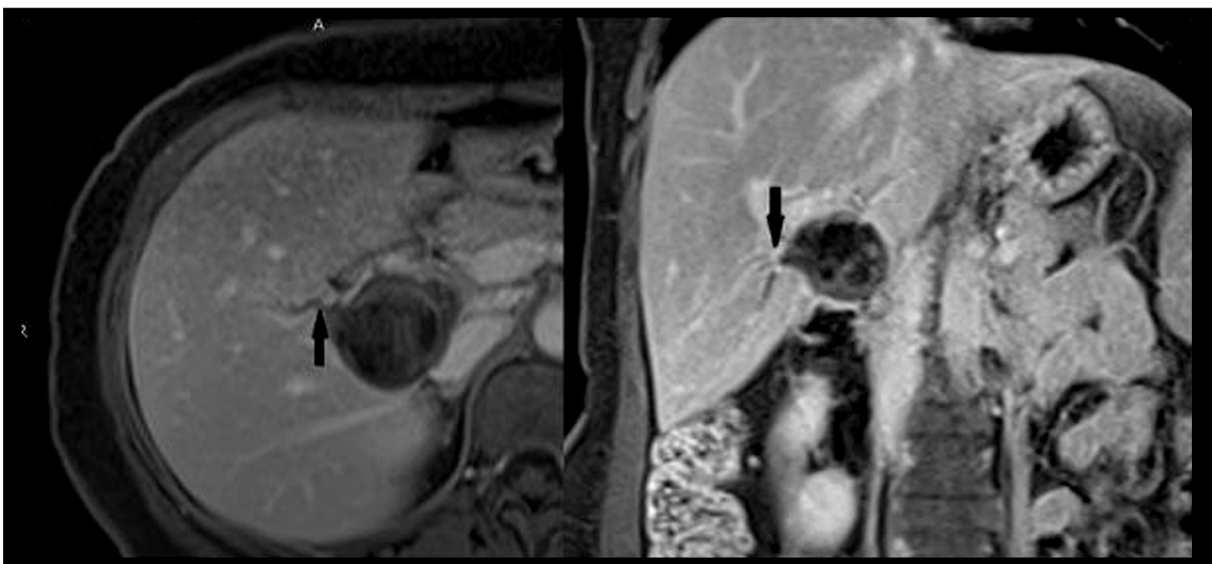


Figure 7. Axial and coronal contrast-enhanced fat-suppressed T1 MRI sequences show no contrast enhancement in the lesion, a fine fistula (black arrow) between the lesion and the intrahepatic bile ducts at the level of segment V, and mild dilatation in the intrahepatic bile ducts.

pericholestatic fluid. The initial diagnosis of intrabiliary rupture of hydatid cyst was confirmed by the surgery and pathology results.

Discussion

Intrabiliary rupture is the most common and serious complication of hepatic hydatid cysts [5]. Internal rupture secondary to increased intracystic pressure, external rupture because of trauma or spontaneous rupture may occur. Hydatid cyst rupture has three types [6]. In the first type of the contained rupture, hydatid fluid leaks between the endocyst and pericyst with no drainage out of the cyst. Communicating rupture is characterized by drainage to the adjacent bile ducts and is subdivided into simple and obvious ruptures, according to the size of the connection between the cyst and the bile ducts. No hydatid material passage to the bile ducts occurs in simple rupture, and it is usually asymptomatic; however, an obvious rupture may occur in time. On the other hand, plenty of hydatid material passes into the bile ducts in an obvious rupture, and this condition results in obstructive symptoms. In the third type of direct rupture, the cyst contents may be released into the peritoneal, and/or pleural cavities [7]. Our patient had a communicating rupture of hydatid cyst into the bile ducts, which opened to the intrahepatic bile ducts at the level of segment V through a fine fistula.

Rupture of the hydatid cyst into the bile ducts may result in jaundice as well as in cholecystitis, cholangitis, liver abscess, pancreatitis, and even septicemia [3]. The most common symptom is right upper quadrant pain followed by jaundice, fever, appetite loss, nausea and vomiting, back pain, itching, abdominal swelling, tachycardia, chills, and other symptoms [3].

Laboratory findings are often non-specific, and diagnosis is usually made with radiological imaging methods in clinically suspected patients. Leukocytosis and increased levels

of alkaline phosphatase, direct bilirubin, and liver enzymes may be present in patients with rupture into the bile ducts. Serology was negative, and a non-specific slight increase was found in the bilirubin levels in our patient.

Ultrasonography may reveal irregular cystic lesions, loss of wall integrity, and internal distention in the liver as well as echogenic material in the enlarged main biliary canal with no posterior acoustic shadowing. Abdominal CT can be used to determine the location and morphological characteristics of the cyst and to show low-density intraluminal material in the enlarged ductal canal [8]. Magnetic resonance imaging/magnetic resonance cholangiopancreatography is used to evaluate the nature, content, and association of the cyst with the bile ducts and the intra- and extrahepatic bile ducts [8]. Endoscopic retrograde cholangiopancreatography (ERCP) is the method used for both diagnosis and treatment. Preoperative ERCP can show biliary obstruction and female vesicles in the duodenum and ampulla of Vater [9]. Because of its non-invasiveness and reduced morbidity, MRI/MRCP has been rapidly replacing ERCP in recent years.

Surgical treatment may be needed if the hydatid cyst and the biliary system are related.

Conclusions

Intrabiliary rupture is one of the most serious complications of liver hydatid cysts. Biliary colic, cholangitis, and jaundice usually occur in liver hydatid cyst patients. In endemic areas, intrabiliary rupture should be considered in the differential diagnosis if patients have upper quadrant pain and jaundice. When an atypical mass lesion is found on US, detailed imaging should be done with MRI/MRCP.

Conflicts of interest

All of the authors declare no conflicts of interest.

References:

- Moro P, Schantz PM: Echinococcosis: A review. *Int J Infect Dis*, 2009; 13: 125–33
- Yilmaz M, Akbulut S, Kahraman A, Yilmaz S: Liver hydatid cyst rupture into the peritoneal cavity after abdominal trauma: Case report and literature review. *Int Surg*, 2012; 97(3): 239–44
- Bektaş M, Dökmeci A, Cinar K et al: Endoscopic management of biliary parasitic diseases. *Dig Dis Sci*, 2010; 55: 1472–78
- Dolay K, Akbulut S: Role of endoscopic retrograde cholangiopancreatography in the management of hepatic hydatid disease. *World J Gastroenterol*, 2014; 20(41): 15253–61
- Erzurumlu K, Dervisoğlu A, Polat C et al: Intrabiliary rupture: An algorithm in the treatment of controversial complication of hepatic hydatidosis. *World J Gastroenterol*, 2005; 11(16): 2472–76
- Polat P, Atamanalp SS: Hepatic hydatid disease: radiographic findings. *Eurasian J Med*, 2009; 41(1): 49–55
- Sparchez Z, Osian G, Onica A et al: Ruptured hydatid cyst of the liver with biliary obstruction: presentation of a case. *Rom J Gastroenterol*, 2004; 13(3): 245–50
- Ozaslan E, Bayraktar Y: Endoscopic therapy in the management of hepatobiliary hydatid disease. *J Clin Gastroenterol*, 2002; 35: 160–74
- Simşek H, Ozaslan E, Sayek I et al: Diagnostic and therapeutic ERCP in hepatic hydatid disease. *Gastrointest Endosc*, 2003; 58: 384–89