



Case report

An unexpected finding in a man with multiple pulmonary nodules, a pleural effusion and respiratory failure

Yik Lam Pang^{*},¹, Quentin Jones

Great Western Hospital, Marlborough Road, Swindon, SN3 6BB, United Kingdom

ARTICLE INFO

Article history:

Received 8 January 2017

Received in revised form

28 February 2017

Accepted 3 March 2017

Keywords:

Bovine tuberculosis

Mycobacterium Bovis

Tuberculosis

ABSTRACT

We report the case of a 47-year old Caucasian man with a history of depression and high alcohol intake who presented with a one-month history of weight loss, dry cough and abdominal pain. He had no smoking history of note. The patient was treated for a suspected chest infection, however developed respiratory failure and was intubated. A CT showed multiple pulmonary nodules, left pleural thickening extending to the mediastinum and bilateral pleural effusions-larger on the left, suggestive of disseminated malignancy. A broncho-alveolar lavage surprisingly contained numerous acid-fast bacilli and no malignant cells. Treatment for tuberculosis was initiated and the patient recovered gradually. After several weeks, a pyrazinamide-resistant organism was cultured and subsequently identified to be *Mycobacterium Bovis*.

We discuss this unexpected finding and review the literature on Bovine Tuberculosis in humans.

© 2017 The Authors. Published by Elsevier Ltd. This is an open access article under the CC BY-NC-ND license (<http://creativecommons.org/licenses/by-nc-nd/4.0/>).

1. Case report

Weight loss and cough are common symptoms presented at the primary and secondary practice. Based on the clinical history, and paired with a suggestive CT scan, clinicians may be suspicious of infection or underlying malignancy. However, certain atypical infective causes can mimic widespread malignancy on radiology and a high level of suspicion is needed to aid diagnosis. Currently, there are no reported cases of misdiagnosis of malignancy due to *Mycobacterium Bovis* and we discuss this rare finding in the following case.

A 47-year old man with a past medical history of depression, chronic fatigue syndrome and gastro-oesophageal reflux disease presented to the Emergency Department with a four-week history of dry cough, abdominal pain and weight loss. Regular medications included omeprazole and mirtazapine, and he had no known drug allergies. The patient was a non-smoker and had a history of high alcohol consumption. He previously worked in an office but was unemployed at the time. There was no history of foreign travel. On

examination he was cachectic and febrile (37.9 °C), with a heart rate of 119bpm and blood pressure of 110/85 mmHg. His saturations were 98% on room air, and chest examination revealed reduced breath sounds on the left consistent with a pleural effusion. The rest of the examination was unremarkable.

Blood tests showed raised inflammatory markers and deranged liver function tests (Fig. 1). A HIV test was negative. Chest radiograph revealed bilateral effusions, larger on the left with patchy shadowing in both lung fields (Fig. 2). Pleural ultrasound demonstrated a large free flowing anechoic pleural effusion.

A chest drain was inserted. Analysis of the heavily blood stained fluid showed a pH of 7.44, LDH 4557U/L, protein level of 41g/L and no malignant cells on cytology. Initial gram stain was negative and no Acid Fast Bacilli were seen. Three sputum samples were also negative for Acid Fast Bacilli.

CT scan of the chest, abdomen and pelvis (Fig. 3) showed multiple nodules throughout the lungs, small mediastinal lymph nodes and pleural thickening within the left hemi-thorax extending onto the mediastinal surface. There were no abnormalities in the abdomen or pelvis. The radiological appearances were reported as favouring a diagnosis of malignancy rather than infection.

The most likely diagnosis was thought to be disseminated malignancy with unknown primary with super imposed pulmonary infection.

The patient became increasingly hypoxic despite treatment with broad-spectrum antibiotics. In the absence of a definitive diagnosis

^{*} Corresponding author. Respiratory Department, Royal United Hospital, Combe Park, Avon, BA1 3NG, United Kingdom.

E-mail addresses: y.pang1@nhs.net (Y.L. Pang), Quentin.jones@gwh.nhs.uk (Q. Jones).

¹ Dr Y Pang is currently a core medical trainee at Royal United Hospital, Combe Park, Avon. BA1 3NG, United Kingdom.

Hb	112g/L	Na	128 mmol/L
MCV	107 fl	K	4.08mmol/L
WCC	14.7 x 10 ⁹ /L	Creatinine	42umol/L
Neutrophils	13.47x10 ⁹ /L		
Platelets	505 x 10 ⁹ /L	Albumin	24g/L
		Alkaline Phosphatase	481U/L
C reactive Protein	138mg/L	Aspartate Transaminase	54U/L
Clotting	Normal	Serum Bilirubin	19 uMol/L
Amylase	45 U/L	Gamma Glutamyl Transferase	790U/L

Fig. 1. Blood tests on admission.

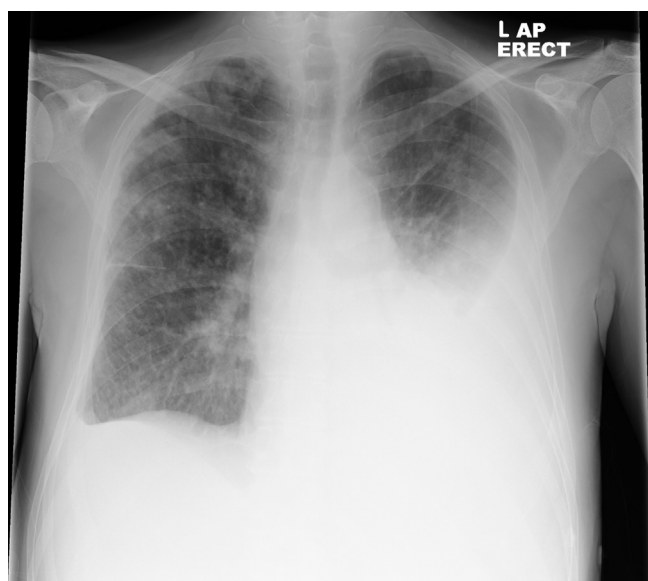


Fig. 2. Chest X-ray showing a large left pleural effusion, a small right pleural effusion and some nodules and consolidation in both lungs.

of malignancy, he was intubated for ventilatory support. A broncho-alveolar lavage obtained from bronchoscopy showed no malignant cells, but microbiological analysis yield numerous Acid Fast Bacilli. A diagnosis of miliary tuberculosis was made and standard Tuberculosis treatment (pyrazinamide, rifampicin, isoniazid, and ethambutol) was initiated. The patient made good clinical improvement and was eventually discharged.

Ten weeks after his bronchoscopy, an organism resistant to pyrazinamide was cultured and identified as *Mycobacterium Bovis* (*M. Bovis*). This unexpected finding led to a review of the history. The patient had not travelled abroad or consumed any unpasteurised milk. He owned a healthy cat and had lived next to a dairy farm for many years. His wife recalled that there might have been cases of Bovine Tuberculosis among the cattle on the farm. The Department of Public Health was informed and the patient's cat was tested for *M. Bovis* which subsequently was negative. Pyrazinamide was stopped and the patient completed a nine-month treatment (rifampicin, isoniazid and ethambutol) for pulmonary *M. Bovis* and made a gradual recovery.

2. Discussion

M. Bovis belongs to a group of tubercle bacilli known as the Mycobacterium Tuberculosis Complex (MTBC). MTBC comprises of 4 subspecies including *Mycobacterium Tuberculosis* (*M. Tuberculosis*), *M. Bovis*, *Mycobacterium Africanum* (*M. Africanum*) and *Mycobacterium Microti* (*M. Microti*), which were thought to be variants of a single species due to similarities in their DNA and phenotypical features [1].

Bovine Tuberculosis is found primarily in cattle but also in deer and other animals such as cats [2]. Transmission is most commonly via ingestion of infected dairy products [2,3], but can also be via inhalation or direct contact to mucosal membranes/open wounds with infected particles [2,4]. Human-to-human transmissions are rare but have been reported in isolated case-studies [5,6].

M. Bovis is rare in developed countries due to pasteurisation of milk [2,7]. In the United States, the Centre for disease control (CDC) [2] estimated that *M. Bovis* contributes to 2% of all tuberculosis cases per annum. In the United Kingdom, approximately 0.5–1.5% of MTBC cases per year were reported as *M. Bovis* between 1990 and 2003 [6]. Occupations such as farmers are at higher risk due to increased exposure [2]. In 2014, there was a cluster of *M. Tuberculosis* cases in cats in Berkshire. Two pet owners contracted the disease [8].

M. Bovis can present as primary infection or reactivation after a period of latency when the patient becomes immunocompromised [9]. The clinical and radiological features are similar to *M. Tuberculosis* [7]. However, *M. Bovis* is more likely to present as extra-pulmonary disease, such as in lymph nodes, the pleural space and the central nervous system [10].

Diagnosis of *M. Bovis* by culturing MTBC can take six weeks or more. Unfortunately, blood tests with elevated inflammatory markers could suggest both infection and malignancy. Deranged liver function tests are also nonspecific. Additional serological tests such as the Tuberculin skin test (TST), and interferon-gamma release assays (IGRAs) can be helpful, although they would not be able to distinguish between latent and active Mycobacterium infection [11].

Our patient had both lung and pleural involvement with *M. Bovis* hence we were able to confirm his diagnosis with a broncho-alveolar lavage. However, it can be difficult to achieve positive microbiology from pleural fluid in patients with only pleural involvement, as tuberculous effusions are usually results from hypersensitive reactions and contain few mycobacteria bacilli [11]. Positive yield is quoted to be approximately 30% in literature [11]. In addition, larger volume of pleural fluid may not necessary have a higher yield [12]. Laboratory analysis of tuberculous pleural fluid often show a low glucose exudate, high LDH levels with lymphocytosis [11,13]. In patients with moderate to high levels of suspicion for Tuberculosis, a pleural fluid adenosine deaminase (ADA) level between 40 and 60 U/L can be supportive [14]. The positive predictive value of ADA is stronger in areas of high Tuberculosis prevalence [15]. However, not all centres have ADA testing readily available and high ADA levels can also be caused by malignancies (mesothelioma, haematological, lung), inflammatory conditions (rheumatoid) and infections (empyema) [11].

Pleural biopsies have a higher yield for diagnosing tuberculosis pleurisy, reported between 60 and 95% [11], and will be able to provide information on causative organism and its sensitivities. They can be obtained via closed pleural biopsy at the bedside with thoracic ultrasound guidance, or via local anaesthetic thoracoscopy. Skilled professionals are required for the procedure and carry risks including pain, pneumothorax and neurovascular and visceral damage [16].

Patients who are culture positive for MTBC are normally treated

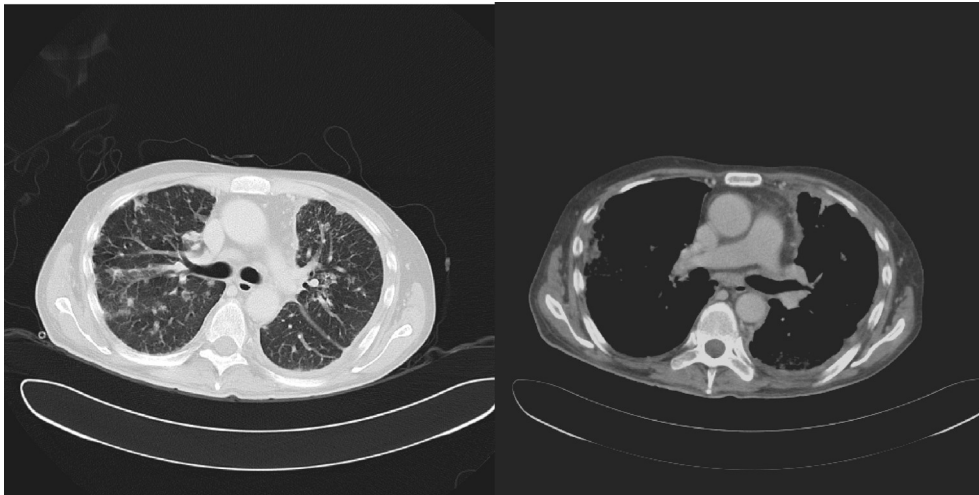


Fig. 3. CT scan after drainage of the left pleural effusion showing multiple pulmonary nodules and diffuse pleural thickening in the left lung extending to the mediastinum pleura.

with standard quadruple therapy. The drug regime can be changed (as in our patient) once the organism is identified and antibiotic sensitivities are known. *M. Bovis* is the only strain of MTBC resistant to pyrazinamide [1] and is treated for a total of nine months rather than six [17]. The CDC recommends a combination of isoniazid, rifampicin and ethambutol for the initial two months and isoniazid and rifampicin only for the subsequent seven months [18].

It is likely that our patient contracted *M. Bovis* from infected cattle – perhaps as the result of reactivation of latent infection. There were some clues, he was immune-compromised due to his alcohol intake, had persistent fevers and lived next to a farm. The radiology findings were consistent with tuberculosis.

The case we present is a reminder of how tuberculosis can mimic malignancies including primary lung cancer, disseminated malignancy with multiple pulmonary metastases and malignant pleural disease. It highlights the importance of confirming a malignancy diagnosis histologically and sending material for tuberculosis cultures if there is any suspicion of tuberculosis.

Conflict of interest

None declared.

Funding

This research did not receive any specific grant from funding agencies in the public, commercial, or not-for-profit sectors.

References

- [1] J.M. Grange, M.D. Yates, I.N. de Kantour, Guidelines for Speciation within the *Mycobacterium Tuberculosis* Complex, World Health Organisation (WHO), Geneva, 1996 (Publication number: WHO/EMC/ZOO/96.4).
- [2] Center for Disease Control and Prevention (CDC), *Mycobacterium bovis* (Bovine Tuberculosis) in Humans, 2011. New York City, <http://www.cdc.gov/tb/publications/factsheets/general/mbovis.pdf>.
- [3] P. Torres-Gonzalez, O. Soberanis-Ramos, A. Martinez-Gamboa, et al., Prevalence of latent and active tuberculosis among dairy farm workers exposed to cattle infected by *Mycobacterium Bovis*, *PLOS Neglected Trop. Dis.* 7 (4) (2013) e2177, <http://dx.doi.org/10.1371/journal.pntd.0002177>, 2013 Apr 25.
- [4] De la Rúa-Deomenech R, Human *Mycobacterium bovis* infection in the United Kingdom: incidence, risks, control measures and review of the zoonotic aspects of bovine tuberculosis, *Tuberc. Edinb.* 86 (2) (2005) 77, 10, <http://www.ncbi.nlm.nih.gov/pubmed/16257579>.
- [5] J.T. Evans, E.G. Smith, A. Banerjee, R.M. Smith, J. Dale, J.A. Innes, D. Hunt, A. Tweddell, A. Wood, C. Anderson, R.G. Hewinson, N.H. Smith, P.M. Hawkey, P. Sonnenberg, Cluster of human tuberculosis caused by *Mycobacterium bovis*: evidence for person-to-person transmission in the UK, *Lancet* 369 (2007) 1270–1276.
- [6] P.A. LoBue, W. Betancourt, L. Cowan, et al., Identification of a familial cluster of pulmonary *Mycobacterium bovis* disease, *Int. J. Tuberc. Lung Dis.* 8 (9) (2004) 1142–1146. <http://www.ncbi.nlm.nih.gov/pubmed/15455603?dopt=Abstract>.
- [7] E. Talbot, *Mycobacterium bovis*, in: C. Reyn (Ed.), *Uptodate*, 2014. Retrieved from: <http://www.uptodate.com/contents/mycobacterium-bovis>.
- [8] Pet Cats infected two people with TB, British Broadcasting Corporation News, 2014. Accessed: <http://www.bbc.co.uk/news/health-26766006> [6/4/2015].
- [9] G. Nedeltchev, T. Raghunand, M. Jassal, et al., Extrapulmonary dissemination of *Mycobacterium bovis* but not *Mycobacterium tuberculosis* in a bronchoscopic rabbit model of cavitary tuberculosis, *Infect. Immun.* 77 (2) (2009) 598–603.
- [10] C. Majoor, C. Magis-Escurra, J. Van Ingen, et al., Epidemiology of *Mycobacterium bovis* disease in humans, The Netherlands, 1993–2007, *Emerg. Infect. Dis.* 17 (3) (2011), <http://dx.doi.org/10.3201/eid1703.101111>.
- [11] M. Frye, J. Huggins, et al., Tuberculous Pleural Effusions in HIV-uninfected Patients, 2016. Uptodate. Retrieved from: <http://www.uptodate.com/contents/tuberculous-pleural-effusions-in-hiv-uninfected-patients>.
- [12] F. Von Groote-Bidlingmaier, C.F. Koegelenberg, C.T. Bolliger, P.K. Chung, C. Rautenbach, E. Wasserman, M. Bernasconi, S.O. Friedrich, A.H. Diacon, The Yield of different pleural fluid volumes for *Mycobacterium tuberculosis* culture, *Thorax* 68 (3) (2013) 290–291. <https://www.ncbi.nlm.nih.gov/pubmed/22863812>.
- [13] M. Vorster, B. Allwood, A. Diacon, C. Koegelenberg, Tuberculous pleural effusions: advances and controversies, *J. Thorac. Dis.* 7 (6) (2015) 981–991. June, <https://www.ncbi.nlm.nih.gov/pubmed/26150911>.
- [14] R. Krenke, P. Korczyński, Use of pleural fluid levels of adenosine deaminase and interferon gamma in the diagnosis of tuberculous pleuritis, *Curr. Opin. Pulm. Med.* 16 (2010) 367–375. July, <https://www.ncbi.nlm.nih.gov/pubmed/20473171>.
- [15] J.M. Porcel, Tuberculous pleural effusion, *Lung* 187 (5) (2009) 263–270. Sept-Oct, <https://www.ncbi.nlm.nih.gov/pubmed/19672657>.
- [16] J. Cocoran, I. Psallidas, J. Wrightson, R. Hallifax, N. Rahman, Pleural procedural complications: prevention and management, *J. Thorac. Dis.* 7 (6) (2015) 105867. June, <https://www.ncbi.nlm.nih.gov/pubmed/26150919>.
- [17] P.A. Lobue, K.S. Moser, Treatment of *Mycobacterium bovis* infected tuberculosis patients; San Diego County, California, United States, 1994–2003, *Int. J. Tuberc. Lung Dis.* 9 (3) (2005) 333–338.
- [18] American Thoracic Society, CDC, Infectious Disease Society of America. Treatment of Tuberculosis. *MMWR Recomm Rep.* vol. 52, 2003, p. 1. Accessed: <http://www.cdc.gov/mmwr/preview/mmwrhtml/rr5211a1.htm>.