



Letter to the Editor

A simple formula for measuring the aortic valve area in pre-procedural echocardiography for transcatheter aortic valve implantation: An innovation



Aortic Stenosis (AS) is one of the most common valvular diseases in developed countries, affecting nearly 7% of people over 65 years.¹ Severe AS has been associated with a poor prognosis and high mortality rate if left untreated.² Considering the fact that medical therapy is not beneficial in these patients, aortic valve replacement seems to be the only effective treatment in recent practice.³ It is noteworthy to contemplate that patients with aortic stenosis usually have significant comorbidities including left ventricular (LV) dysfunction, respiratory and kidney problems, in addition to advanced age. Therefore, surgical aortic valve replacement (AVR) is prohibited in many of them because of high peri-procedural mortality.⁴ In these conditions, transcatheter aortic valve replacement/implantation (TAVR/TAVI) has been utilized as a low-risk effective substitute.¹

Transesophageal echocardiography (TEE) and also multi-detector computed tomography (MDCT) have been approved as the preferred imaging methods for measuring aortic annular size, aortic valve morphology and area (AVA) in pre-TAVI evaluation. In this regard, real-time three-dimensional TEE (3D-TEE) has been detected to be superior to transthoracic echocardiography (TTE).^{5,6} Even though, there have been several studies revealing accuracy of 3D-TEE in measuring aortic annulus, this modality is considered a semi-invasive procedure with known complications especially in elderly patients.⁷ In pre-TAVI assessment, MDCT has been considered as the standard imaging for aortic annular measurement; however, there are some limitations in the use of MDCT in elderly patients as many of them have associated renal disease and subsequent contraindication for the use of contrast agents. Besides, as two-dimensional (2D) echocardiography may underestimate the aortic annulus due to its oval-shaped morphology, 3D-TEE accompanied with MDCT have been used for valve sizing in selected cases to minimize the post-procedural paravalvular leakage.^{8,9}

In our tertiary heart center, we used a simple formula with 2D-TTE data to estimate the size of the aortic annulus. In our measurements, we found out that if we assume aortic valve as a simple ellipse,¹⁰ the aortic annulus diameter that we measure by TTE is the minor axis (r_1) of the mentioned oval; and the major axis (r_2) of it is equal to the size of minor axis (r_1) + 1.2 mm. The value “1.2 mm” was an estimation derived from observation of 22 patients in our center who underwent TAVI (Table 1). As shown in Fig. 1, the area of an ellipse can be calculated by “ $A = \pi \times r_1/2 \times r_2/2$ ”.^{11–13} We calculated the area of aortic annulus with the aforementioned formulas, and all the selected prosthetic valves based on these measurements were acceptable. By using the Kolmogorov–Smirnov test, we confirmed the normality of distribution in our data. So that, we utilized independent *t*-test to compare the calculated area by 2D-TTE and the measured annular area by 3D-TEE and MDCT. There was no statistically significant difference between calculated area by 2D-TTE and measured annular area by 3D-TEE (*p*-value = 0.60) and also between calculated area by 2D and reported annular area by MDCT (*p*-value = 0.15). Using Pearson’s correlation coefficient, the calculated aortic annulus area was positively correlated with measured annulus by 3D-TEE ($r = 0.98$, $p < 0.01$) and reported annulus area by MDCT ($r = 0.98$, $p < 0.01$).

As we know, significant proportion of patients who are considered for TAVI procedure, have advanced age, renal disease, pulmonary disease, frailty, and GI disorders; therefore, providing effective modalities to minimize their exposure to contrast agents or any invasive procedures that may need sedation would be of significant value. Regarding our findings, it is possible to measure the area of aortic annulus and to estimate the suitable valve for TAVI according to TTE data. This formula would be helpful by eliminating the need for 3D-TEE or MDCT in patients selected for TAVI and would substantially decrease the time and cost consumed in each situation.

Table 1

Data derived from 22 patients in our heart center who were selected for TAVI procedure. *Estimated major axis was calculated by adding 1.2 mm to minor axis. The value “1.2 mm” was an estimation derived from observation of 22 patients. **There was no statistically significant difference between calculated area by 2D-TTE and measured annular area by 3D TEE (p-value = 0.60) and also between calculated area by 2D and reported annular area by MDCT (p-value = 0.15).

2D-TTE			3D-TTE			MDCT		
Minor axis	Estimated major axis*	Calculated area**	Minor axis	Major axis	Annulus area**	Minor axis	Major axis	Annulus area**
20.0	21.2	332.8	20.0	21.0	340.0	19.8	21.0	343.0
21.0	22.2	366.0	21.3	22.0	370.0	21.2	22.0	376.0
19.0	20.2	301.3	19.2	20.0	310.0	19.2	20.7	315.0
21.0	22.2	366.0	20.8	22.0	389.0	20.8	22.0	395.0
22.0	23.2	400.7	22.0	23.0	405.0	21.6	23.0	417.0
18.0	19.2	271.3	18.0	19.5	288.0	18.3	19.9	298.0
21.0	22.2	366.0	21.5	22.0	380.0	21.2	22.7	389.0
20.0	21.2	332.8	20.0	21.0	320.0	19.8	21.2	326.0
19.0	20.2	301.3	19.3	20.5	320.0	19.2	20.2	335.0
22.0	23.2	400.7	22.8	22.8	386.0	21.7	23.0	415.0
20.0	21.2	332.8	20.0	21.0	317.0	20.3	21.6	355.0
22.0	23.2	400.7	22.6	22.8	415.0	22.2	23.0	427.0
18.0	19.2	271.3	18.2	19.2	280.0	18.3	19.6	294.0
17.0	18.2	242.9	17.0	18.2	255.0	17.2	18.5	278.0
19.0	20.2	301.3	19.0	20.0	312.0	19.3	20.7	332.0
20.0	21.2	332.8	20.4	21.2	340.0	19.7	21.0	352.0
21.0	22.2	366.0	21.4	22.0	377.0	20.8	22.3	393.0
20.0	21.2	332.8	20.0	21.5	340.0	19.8	21.3	355.0
18.0	19.2	271.3	18.2	19.0	280.0	18.5	19.5	294.0
18.0	19.2	271.3	17.8	19.3	292.0	17.8	19.0	304.0
21.0	22.2	366.0	21.0	22.2	372.0	20.8	22.0	394.0
17.0	18.2	242.9	17.6	18.5	252.0	17.2	18.5	261.0

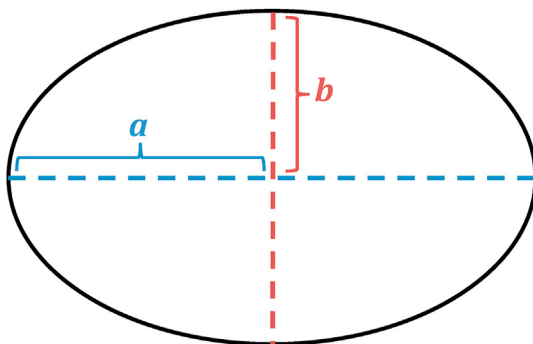


Fig. 1. The area of an ellipse can be calculated by “ $A = \pi \times (r_1)/2 \times (r_2)/2$ ”. In this figure, the blue dashed lined represents the major axis (r_2) and the red dashed line shows the minor axis(r_1).

Ethical statement

The manuscript does not contain clinical studies or patient data.

Declaration of competing interest

The authors declare no conflict of interest.

References

1. Arora S, Misenheimer JA, Ramaraj R. Transcatheter aortic valve replacement: comprehensive review and present status. *Tex Heart Inst J.* 2017 Feb;44(1): 29–38.
2. Varadarajan P, Kapoor N, Bansal RC, Pai RG. Survival in elderly patients with severe aortic stenosis is dramatically improved by aortic valve replacement: results from a cohort of 277 patients aged ≥ 80 years. *Eur J Cardio Thorac Surg.* 2006 Nov 1;30(5):722–727.
3. Nishimura RA, Otto CM, Bonow RO, et al. AHA/ACC guideline for the management of patients with valvular heart disease: executive summary: a report of the American College of Cardiology/American Heart Association Task Force on Practice Guidelines. *J Am Coll Cardiol.* 2014;63(22):2438–2488, 2014 Jun 10.
4. Sharony R, Grossi EA, Saunders PC, et al. Aortic valve replacement in patients with impaired ventricular function. *Ann Thorac Surg.* 2003 Jun 1;75(6): 1808–1814.
5. Jánosi RA, Kahlert P, Plicht B, et al. Measurement of the aortic annulus size by real-time three-dimensional transesophageal echocardiography. *Minim Invasive Ther Allied Technol.* 2011 Apr 1;20(2):85–94.
6. Leipsic J, Gurvitch R, LaBounty TM, et al. Multidetector computed tomography in transcatheter aortic valve implantation. *JACC (J Am Coll Cardiol): Cardiovasc Imag.* 2011 Apr 1;4(4):416–429.
7. Hahn RT, Khalique O, Williams MR, et al. Predicting paravalvular regurgitation following transcatheter valve replacement: utility of a novel method for three-dimensional echocardiographic measurements of the aortic annulus. *J Am Soc Echocardiogr.* 2013 Sep 1;26(9):1043–1052.
8. Mediratta A, Addetia K, Medvedofsky D, et al. 3D echocardiographic analysis of aortic annulus for transcatheter aortic valve replacement using novel aortic valve quantification software: comparison with computed tomography. *Echocardiography.* 2017 May;34(5):690–699.
9. Altiok E, Koos R, Schröder J, et al. Comparison of two-dimensional and three-dimensional imaging techniques for measurement of aortic annulus diameters before transcatheter aortic valve implantation. *Heart.* 2011 Oct 1;97(19): 1578–1584.
10. Salaun E, Zenses AS, Evin M, et al. Effect of oversizing and elliptical shape of aortic annulus on transcatheter valve hemodynamics: an in vitro study. *Int J Cardiol.* 2016;208:28–35. <https://doi.org/10.1016/j.ijcard.2016.01.048>.

11. <https://www.wikihow.com/Calculate-the-Area-of-an-Ellipse>.
12. Immè S, Todaro D, La Manna A. *Transcatheter Aortic Valve Implantation: Medtronic CoreValveEvolut R. In Percutaneous Treatment of Left Side Cardiac Valves*. Cham: Springer; 2018:385–404.
13. Rao RS, Maniar H, Zajarías AL. Sapien valve: past, present, and future. *Cardiac Interv Today*. 2015;9:35–41.

Azin Alizadehasl

Cardio-Oncology Research Center, Rajaie Cardiovascular Medical & Research Center, Tehran, Iran

Sayfollah Abdi

Rajaie Cardiovascular Medical and Research Center, Tehran, Iran

Ata Firoozi

Rajaie Cardiovascular Medical and Research Center, Tehran, Iran

Asghar Mohamadi

Cardiovascular Research Center, Shahid Rahimi Hospital, Lorestan University of Medical Sciences, Khorramabad, Iran

Rasoul Azarfarin

Cardio-Oncology Research Center, Rajaie Cardiovascular Medical & Research Center, Tehran, Iran

Shirin Habibi Khorasani*

Echocardiography Research Center, Rajaie Cardiovascular Medical & Research Center, Tehran, Iran

* Corresponding author.

E-mail address: shirin9565.khorasani@gmail.com (S.H. Khorasani).

3 July 2020

Available online 6 January 2021