

# Volumetric analysis of normal condyles and those with disc displacement with reduction in the Indonesian population: A CBCT study

Azkya Patria Nawawi<sup>1</sup>, Rasmi Rikmasari<sup>2</sup>, Erna Kurnikasari<sup>2</sup>, Fahmi Oscandar<sup>3,\*</sup>,  
Yurika Ambar Lita<sup>3</sup>

<sup>1</sup>Department of Prosthodontics, Faculty of Dentistry, Universitas Jendral Ahmad Yani, Indonesia

<sup>2</sup>Department of Prosthodontics, Faculty of Dentistry, Universitas Padjadjaran, Indonesia

<sup>3</sup>Department of Oral and Maxillofacial Radiology, Faculty of Dentistry, Universitas Padjadjaran, Indonesia

## ABSTRACT

**Purpose:** Disc displacement can cause resorption of the head of the condyle and affect its volume. This study analysed the volume of normal condyles and those with disc displacement with reduction (DDR) in cone-beam computed tomography (CBCT) scans from the Indonesian population.

**Materials and Methods:** This study analysed 56 condyles (26 normal and 30 with DDR) from patients who visited the Oral and Maxillofacial Radiology Unit after being referred from the Prosthodontics Unit at Dental Hospital Universitas Padjadjaran from December 2020 to February 2021. Samples were divided into 2 groups (normal and DDR left and right-side condyles) based on the DC/TMD Axis 1 form through the clinical examination results. Both sample groups were exposed to CBCT radiation. The CBCT imaging results in the Digital Imaging and Communications in Medicine format were exported to the open-source ITK-SNAP format to determine condyle volume. Volumetric data from the cortical and trabecular areas of the right or left side condyles were arranged by sex. The independent t-test was used to determine the significance of differences with IBM SPSS version 21.0. Intra- and inter-observer reliability and validity were tested before determining the volume of the condyles.

**Results:** Normal condyles and DDR condyles showed significant differences in volume ( $P < 0.05$ ). Significant differences were also seen in cortical ( $P = 0.0007$ ) and trabecular ( $P = 0.0045$ ) volumes. There was a significant difference in condylar volume based on sex.

**Conclusion:** The normal condyle volume was significantly different from the DDR condyle volume in both sexes. (*Imaging Sci Dent 2022; 52: 103-8*)

**KEY WORDS:** Cone-Beam Computed Tomography; Mandibular Condyle; Temporomandibular Disorder

## Introduction

Disc displacement with reduction (DDR) is the most common intra-articular disorder of the temporomandibular joint (TMJ) and is defined as an abnormal positional relationship of the articular disc with the mandibular condyle, fossa, and articular eminence. Previous studies<sup>1-4</sup> described the progression of DDR from reduction to non-reduction,

resulting in symptoms such as clicking, crepitus, pain, and limitation of jaw movement.

Garagiola et al.<sup>5</sup> stated that the condylar morphology of DDR patients showed changes in the height and inclination to the distal direction. Poluha et al.<sup>4</sup> mentioned that DDR caused morphological changes in the disc, with a potential impact on changes in the condylar shape. Thus, DDR is a common intra-articular disorder that can cause clinical symptoms and morphological changes of the condyle.

According to a previous study by Chang et al.,<sup>3</sup> condylar resorption could affect the volume of the condyle and its position in the glenoid fossa. Pohula et al.<sup>4</sup> stated that condylar volume was significantly associated with the presence

Received September 26, 2021; Revised October 30, 2021; Accepted November 3, 2021

Published online January 13, 2022

\*Correspondence to : Prof. Fahmi Oscandar

Department of Oral and Maxillofacial Radiology, Faculty of Dentistry, Universitas Padjadjaran, Jalan Sekeloa I, Bandung, Jawa Barat, 40132, Indonesia  
Tel) 62-22-2533044, E-mail) fahmi.oscandar@fkg.unpad.ac.id

Copyright © 2022 by Korean Academy of Oral and Maxillofacial Radiology

This is an Open Access article distributed under the terms of the Creative Commons Attribution Non-Commercial License (<http://creativecommons.org/licenses/by-nc/3.0>) which permits unrestricted non-commercial use, distribution, and reproduction in any medium, provided the original work is properly cited.

Imaging Science in Dentistry · pISSN 2233-7822 eISSN 2233-7830

of DDR and that the volume decreased when DDR changed to disc displacement without reduction in both sexes. Condylar volume change can be seen on radiographic examinations that aim to evaluate the cortical and trabecular architecture. According to the studies by Bayram et al.<sup>6</sup> and Farronato et al.,<sup>7</sup> cone-beam computed tomography (CBCT) enabled early identification of signs in the condyle from minor erosions of the articular cortex to actual deformations of the condylar head without distortion, thereby facilitating analyses of bone morphology, joint space, and dynamic function across all 3 dimensions. CBCT provides images with superior diagnostic quality. This is possibly due to the isotropic (equal in all 3 dimensions) voxel resolution, which produces sub-millimetre spatial resolution ranging from 0.4 mm to as low as 0.125 mm. A rapid scan time of 10-70 seconds is another major advantage of CBCT, as it acquires all basic images in a single rotation.<sup>8,9</sup> According to a comparative study between magnetic resonance imaging (MRI) and CBCT by Alkhader et al.,<sup>10</sup> CBCT was better than MRI in detecting changes in condylar shape such as flattening, osteophyte formation or erosion, rather than changes in size. They concluded that this was probably because MRI had limited spatial resolution and larger slice thickness (> 3 mm) in clinical use. Therefore, CBCT can be used to measure volume accurately.

Currently, studies on temporomandibular joint (TMJ) volume in DDR patients are still limited. Based on the study of Chang et al.,<sup>3</sup> a quantitative assessment of condylar volume could help evaluate the relationship between DDR and condylar structure. However, researchers have yet to evaluate the relationship between DDR and condyle structure in terms of its volume, particularly in the population of Indonesia. The study aimed to analyse the volume of normal condyles compared with condyles showing DDR using CBCT in the Indonesian population.

## Materials and Methods

This study was approved by the Ethics Committee of the Faculty of Medicine, Universitas Padjadjaran, Bandung, West Java, Indonesia with registration number 6366/UN6.F1/DL/2020 on November 11, 2020.

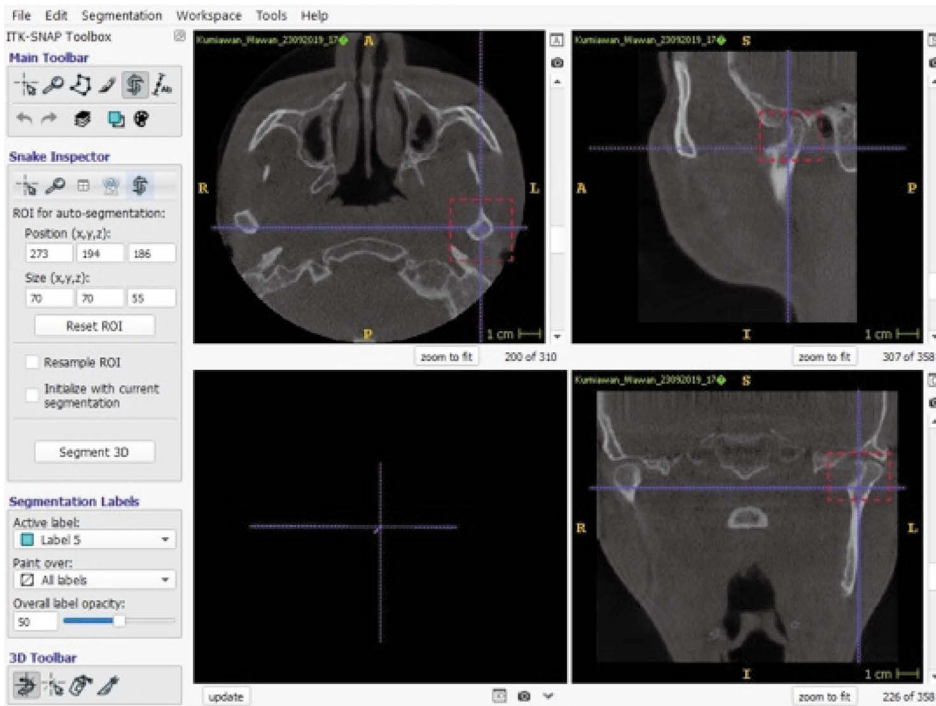
The analytical study design included 56 condyles (26 normal and 30 with DDR) obtained from the patients who visited the Oral and Maxillofacial Radiology Unit after being referred from the Prosthodontics Unit at Dental Hospital Universitas Padjadjaran from December 2020 to February 2021. The inclusion criteria of this population were high-quality CBCT images and an age of 20 years and over (for

males) or 18 years and over (for females), regardless of the presence of TMJ complaints. Patients with developmental disorders in the lower jaw affecting the condyle, trauma to the jaw, arthritis, neoplasms, and a history of orthodontic treatment were excluded. Prior to CBCT imaging, the samples were divided into 2 groups according to whether there was a normal relation (NR) or DDR based on the DC/TMD Axis 1 form in the clinical examination results. All samples were exposed to CBCT radiation using an Orthopantomograph OP300 Maxio (Imaging Instrumentarium, Tuusula, Finland) with an 8 cm × 15 cm and 13 cm × 15 cm field of view, a scan time of 40 s, and isotropic voxels with an axial slice thickness of 0.4 mm.

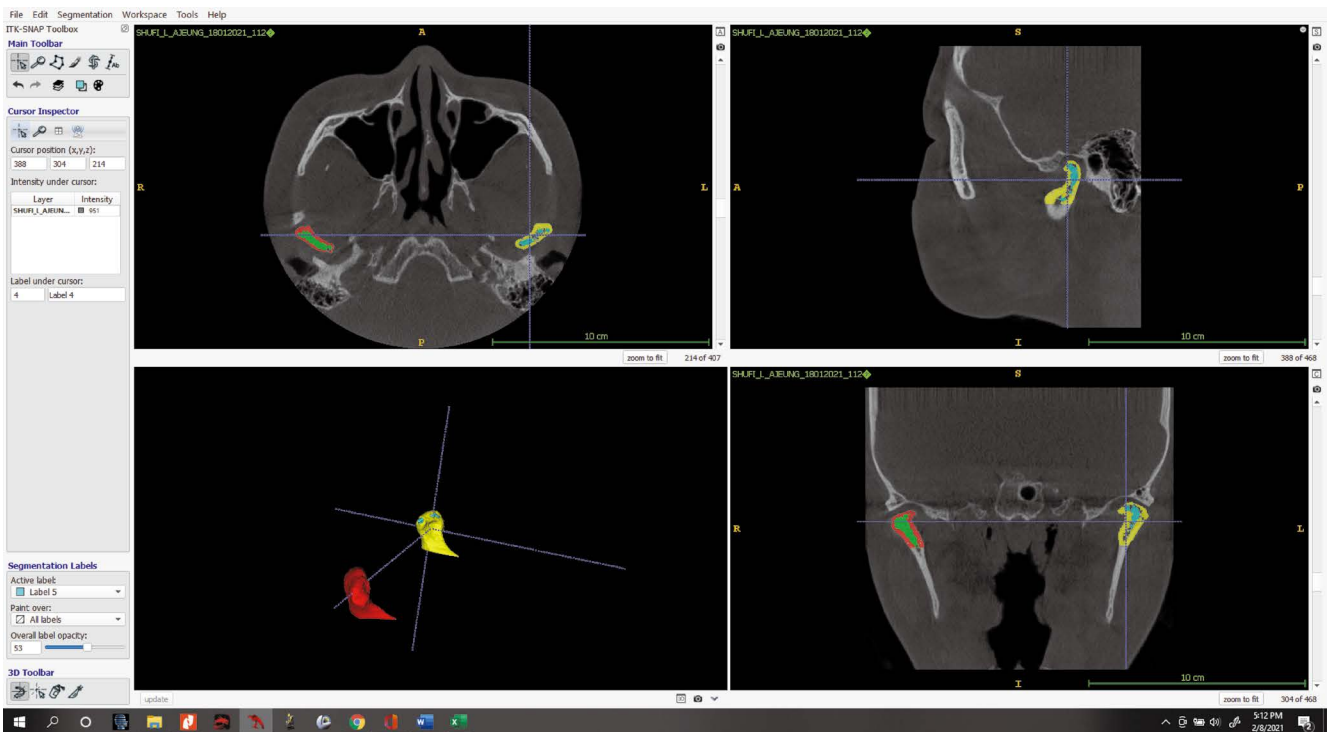
The CBCT data were exported in the Digital Imaging and Communications in Medicine format and imported to the open-source ITK-SNAP software (ITK-SNAP version 3.8.0, <https://www.itksnap.org/>) to analyse condylar volume, while the condylar boundaries were determined on the axial sections. The superior contour of the condyle was determined as the first radiopaque point found in the upper articular area. The inferior border was selected as the first point where the sigmoid notch was visible at the bottom of the condyle (Fig. 1).<sup>3,11</sup>

The condylar bone consists of 2 parts, namely cortical and trabecular bone, which differ in terms of density (Fig. 2). In the ITK-SNAP application, the classification menu was selected to enter pre-segmentation mode. Next, the paint brush mode was selected, and the disc was marked on cortical bone and trabecula areas with different colours using brush style 3. The initialisation was clicked by positioning the cursor on and selecting the added bubble at the cursor button. In the last step, “evolution” was opened, the “execute” button was selected, and then the process was carried out on the cortical bone and trabeculae until finished. The “update” button was selected in the 3D window to display the segmentation results. The “volume” and “statistics” buttons were selected on the segmentation menu to display the condyle volume results in voxel count and millimetres cubed. The cortical volume, trabecular volume, and total volume were calculated in units of millimetres cubed. The calculation results were then compiled into Microsoft Excel 2019 (Microsoft Corp, Redmond, WA, USA). Cortical, trabecular, and total condyle volume were analysed according to sex and the cortical and trabecular area of the condyle, while ignoring the side.

The measurements were performed by 2 oral and maxillofacial radiologists. The first observer measured 28 samples, with 1 repetition at a 3-week interval for an intra-observer analysis of measurements. Meanwhile, the first and



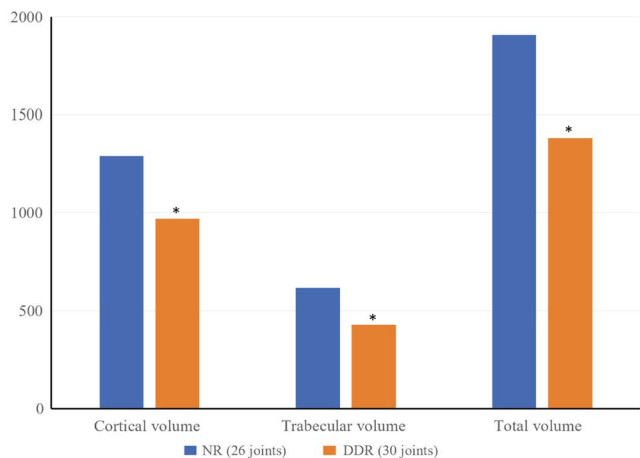
**Fig. 1.** Stages of determining the region of interest (ROI) in the condyle. In the axial view, the inferior border is selected when the first point of the sigmoid notch is visible at the bottom of the condyle. The condyle is positioned in the centre and the user should make sure that no part is cut off. At the lower sagittal boundary slice, the ROI is tangent to the blue orientation line that represents the slice tangent to the sigmoid notch.



**Fig. 2.** Three-dimensional view of right and left condyle segmentation. The yellow and red areas are cortical bone, and the green areas are trabecular bone.

second observer measured the same 28 samples at the same time for an inter-observer analysis. The Cronbach alpha coefficient was used to analyse intra- and inter-observer reliability. The independent t-test was used to evaluate differ-

ences between NR and DDR condyles in cortical, trabecular, and total volume and to investigate differences by sex using SPSS version 21.0 (IBM Corp., Armonk, NY, USA).



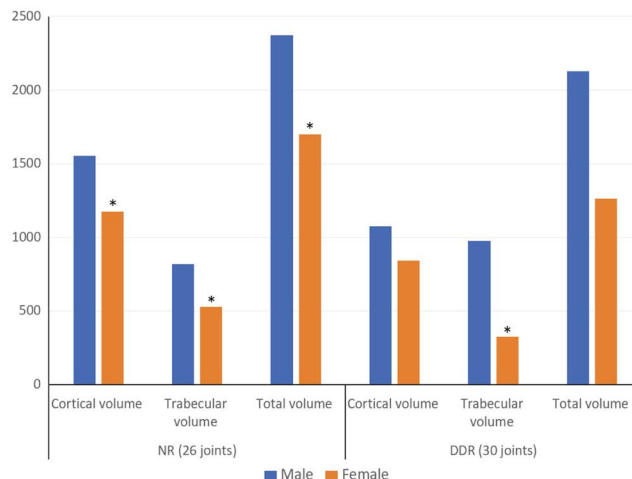
**Fig. 3.** Condylar volume of normal relation (NR) and disc displacement with reduction (DDR) (\*:  $P < 0.05$ ).

### Results

Excellent reliability was found for intra- ( $R = 0.995$ ) and inter-observer ( $R = 0.973$ ) measurements, making it possible to conclude that both observers had the same measurement validity.

The sample consisted of 12 condylar joints obtained from 6 men and 44 from 22 women. The male subjects were younger (NR:  $23.75 \pm 4.50$  years, DDR:  $25.00 \pm 5.00$  years) on average than the female subjects (NR:  $35.33 \pm 10.06$  years, DDR:  $32.00 \pm 12.8$  years). The independent t-test showed significant differences between NR and DDR in cortical volume ( $P < 0.05$ ), trabecular volume ( $P < 0.005$ ), and total volume ( $P < 0.05$ ) (Fig. 3).

There was a significant difference in condylar volume according to sex. In the male subjects with NR condyles, the total condylar volume was  $2373.37 \pm 715.32 \text{ mm}^3$ , the cortical volume was  $1555.53 \pm 518.80 \text{ mm}^3$ , and the trabecular volume was  $817.84 \pm 310.59 \text{ mm}^3$ . In the male subjects with DDR condyles, the total volume was  $2128.11 \pm 716.41 \text{ mm}^3$ , the trabecular volume was  $974.66 \pm 495.91 \text{ mm}^3$ , and the cortical volume was  $1075.60 \pm 260.07 \text{ mm}^3$ . In the female subjects with NR condyles, the total volume was  $1700.41 \pm 280.46 \text{ mm}^3$ , the cortical volume was  $1172.77 \pm 255.31 \text{ mm}^3$ , and the trabecular volume was  $527.64 \pm 236.18 \text{ mm}^3$ . Finally, in the female subjects with DDR condyles, the total volume was  $1264.37 \pm 421.40 \text{ mm}^3$ , the cortical volume was  $842.82 \pm 300.37 \text{ mm}^3$ , and the trabecular volume was  $324.01 \pm 222.06 \text{ mm}^3$ . The cortical, trabecular, and total volumes of the condyles in male subjects were significantly higher than those in female subjects in both the NR and DDR groups (Fig. 4).



**Fig. 4.** Condylar volume between normal relation (NR) and disc displacement with reduction (DDR) groups according to sex (\*:  $P < 0.05$ ).

### Discussion

Our results were uniform as there was no significant difference in the results of the measurements made by both oral and maxillofacial radiologists. Most patients with DDR were women. This result was similar to that reported by Ferreira et al.<sup>12</sup> in a study in Brazil, where 73.8% of TMJ disorders were found in female patients. Similar results were found by Oltramari-Navarro et al.<sup>13</sup> in Brazil, who reported that women had symptoms more often than men. The female predominance of TMJ disorders may be associated with the sex hormone oestrogen, as its receptors could change metabolic function, increasing ligament weakness and pain stimulation by modulating the limbic system.<sup>14-16</sup> A statistical analysis of symptoms showed that women reported more frequent complaints of pain in the temporomandibular joint, facial muscles, neck and shoulder area, headaches, fatigue in masticatory muscles, and sensitive teeth.

TMJ disorders show a female predominance, with a female-to-male ratio of 3-4:1. Sex has been established as a significant risk factor for TMJ disorders apart from para-functional habits.

The study showed that there was a significant difference in volume between the NR and DDR condyles in cortical volume, trabecular volume, and overall volume. The volume might decrease due to resorption in the condyle. This study accords with the findings of Cevidanes et al.,<sup>17</sup> who explained that mandibular resorption had a high prevalence in DDR patients, particularly ongoing DDR, because DDR is usually followed by osteoarthritis. When osteoarthritis

occurs, progressive bone erosion and remodelling occur repeatedly. The repeated process of remodelling and bone degeneration could decrease the condylar size.

The results of the present study also align with those reported by Chang et al.,<sup>3</sup> who showed a significant difference between the NR and DDR condyle. This study is also consistent with a previous study by Byun et al.,<sup>18</sup> which reported that mandibular condylar bone changes were significantly affected by DDR and that condyle morphological changes became more severe as DDR progressed. Nonetheless, results showing differences in similar studies remain very limited.

The bone damage due to disc displacement can theoretically occur according to the direct mechanical trauma model, hypoxic reperfusion model, and neurogenic inflammation model. Each model predicts that highly reactive molecular species are generated in response to mechanical stimuli. During disc displacement, mechanical stimulation increases because the displaced disc cannot exert its proper protective function during functional jaw movement. Increased mechanical stimulation produces highly reactive molecular species and can trigger molecular cascades associated with articular tissue catabolism in the affected condyle. This point aligns with that made in Milam's study.<sup>19</sup>

This study concluded that there were differences in condylar volume based on sex, with a larger condylar volume in men than in women. This finding is similar to the results of Tecco et al.<sup>11</sup> in a Caucasian population and accord with those of a study by Al-Koshab et al.,<sup>20</sup> which showed a significantly higher condylar volume in men than in women. The finding of significant differences in condylar volume according to sex are also supported by a study by Mostafavi et al.<sup>21</sup> in Iran, which showed that there were differences in condylar volume between male and female patients. To the authors' knowledge, no study has yet observed smaller condylar volume in males than in females.

Condylar volume was significantly different between males and females in TMJs with DDR. The condyles in male subjects showed smaller reductions in total condylar volume and trabecular volume than those in female subjects in both NR and DDR condyles. This finding disagrees with the results reported by Chang et al.,<sup>3</sup> who showed that there was a greater reduction in male subjects than in female subjects.

The reasons for sex differences in condylar volume changes are not clearly understood. Sex differences can be attributed to hormonal influences on the TMJs that experience disc displacement. A study in animals and humans showed that sex hormones are associated with cartilage

breakdown in temporomandibular disorders. Women are more often affected by TMJ disorders than men, and the female sex hormone (oestrogen) plays an important role in the occurrence of TMJ disorders.

The advent of CBCT has revolutionised the practice of dentistry, and CBCT is now considered the gold standard for imaging the oral and maxillofacial area due to its numerous advantages, including reductions in exposure time, radiation dose, and cost in comparison to other imaging modalities.<sup>22</sup> CBCT has proven to provide reliable, precise, and clinically relevant TMJ data. Ikeda and Kawamura<sup>23</sup> determined the physiologic position of the condyle in centric relation in the sagittal, coronal, and axial planes in healthy patients, to obtain a standard measure of clinical assessment of condyle position obtained from CBCT.<sup>24</sup> This study used a different CBCT device when compared to the study conducted by Pupo et al.<sup>25</sup> in Brazil. Pupo compared diagnoses using clinical examinations and MRI. The results showed that clinical examinations had lower validity in diagnosing DDR than MRI. MRI can improve diagnostic accuracy, particularly when the information can influence clinical decisions. These findings contrast with those of the study conducted by Vogl et al.,<sup>26</sup> which explained that the clinical examination of the TMJ should not be overlooked, as the findings are an early indication for further diagnosis. Imaging of the TMJ aims to assess the integrity of hard and soft tissue components within the joint, ascertain the stage of the disease, and evaluate the effect of treatment.

This study used ITK-SNAP to determine volume, as was done in the study conducted by Yushjeviich. The results showed that ITK-SNAP is a reliable software application that can be used to segment the structures in 3-dimensional medical images. Yushjeviich et al.<sup>27</sup> used ITK-SNAP to measure brain tumour volume. The results of their study showed that ITK-SNAP is a reliable semi-automatic tool to accelerate segmentation in complicated problems that automatic segmentation tools cannot solve.

A limitation of this study is the unequal number of male and female samples. The absence of patients with disc displacement without reduction means that this study could not conduct a detailed comparison of the relevant changes. The volume of NR condyles was found to be significantly smaller than that of DDR condyles.

**Conflicts of Interest:** None

## References

1. Matsumoto K, Kameoka S, Amemiya T, Yamada H, Araki M, Iwai K, et al. Discrepancy of coronal morphology between

- mandibular condyle and fossa is related to pathogenesis of anterior disk displacement of the temporomandibular joint. *Oral Surg Oral Med Oral Pathol Radiol* 2013; 116: 626-32.
2. de Melo DP, Sousa Melo SL, de Andrade Freitas Oliveira LS, Ramos-Perez FM, Campos PS. Evaluation of temporomandibular joint disk displacement and its correlation with pain and osseous abnormalities in symptomatic young patients with magnetic resonance imaging. *Oral Surg Oral Med Oral Pathol Radiol* 2015; 119: 107-12.
  3. Chang MS, Choi JH, Yang IH, An JS, Heo MS, Ahn SJ. Relationships between temporomandibular joint disk displacements and condylar volume. *Oral Surg Oral Med Oral Pathol Radiol* 2018; 11: 192-8.
  4. Poluha RL, Canales GT, Costa YM, Grossmann E, Bonjardim LR, Conti PC. Temporomandibular joint disc displacement with reduction: a review of mechanisms and clinical presentation. *J Appl Oral Sci* 2019; 27: e20180433.
  5. Garagiola U, Mercatali L, Bellintani C, Fodor A, Farronato G, Lőrincz A. Change in condylar and mandibular morphology in juvenile idiopathic arthritis: cone beam volumetric imaging. *Fogorv Sz* 2013; 106: 27-31.
  6. Bayram M, Kayipmaz S, Sezgin OS, Küçük M. Volumetric analysis of the mandibular condyle using cone beam computed tomography. *Eur J Radiol* 2012; 81: 1812-6.
  7. Farronato M, Cavagnetto D, Abate A, Cressoni P, Fama A, Maspero C. Assessment of condylar volume and ramus height in JIA patients with unilateral and bilateral TMJ involvement: retrospective case-control study. *Clin Oral Investig* 2020; 24: 2635-43.
  8. Scarfe W, Farman A, Sukovic P. Clinical applications of cone-beam computed tomography in dental practice. *J Can Dent Assoc* 2006; 72: 75-80.
  9. Krishnamoorthy B, Mamatha N, Kumar VA. TMJ imaging by CBCT: current scenario. *Ann Maxillofac Surg* 2013; 3: 80-3.
  10. Alkhader M, Ohbayashi N, Tetsumura A, Nakamura S, Okochi K, Momin MA. Diagnostic performance of magnetic resonance imaging for detecting osseous abnormalities of the temporomandibular joint and its correlation with cone beam computed tomography. *Dentomaxillofac Radiol* 2010; 39: 270-6.
  11. Tecco S, Saccucci M, Nucera R, Polimeni A, Pagnoni M, Cordasco G, et al. Condylar volume and surface in Caucasian young adult subjects. *BMC Med Imaging* 2010; 10: 28.
  12. Ferreira CL, Silva MA, Felício CM. Signs and symptoms of temporomandibular disorders in women and men. *Codas* 2016; 28: 17-21.
  13. Oltramari-Navarro PV, Yoshie MT, Silva RA, Conti AC, Navarro RL, Marchiori LL, et al. Influence of the presence of temporomandibular disorders on postural balance in the elderly. *Codas* 2017; 29: e20160070.
  14. Chisnoiu AM, Picos AM, Popa S, Chisnoiu PD, Lascu L, Picos A, et al. Factors involved in the etiology of temporomandibular disorders - a literature review. *Clujul Med* 2015; 88: 473-8.
  15. Rikmasari R, Kusumadewi AN, Damayanti L, Dziab H, Kurnikasari E. The analysis of temporomandibular disorder based on RDC/TMD Axis I revision 2010 in dentistry students. *Padjadjaran J Dent* 2016; 28: 111-20.
  16. Bueno CH, Pereira DD, Pattussi MP, Grossi PK, Grossi ML. Gender differences in temporomandibular disorders in adult populational studies: a systematic review and meta-analysis. *J Oral Rehabil* 2018; 45: 720-9.
  17. Cevidanes LH, Walker D, Schilling J, Sugai J, Giannobile W, Paniagua B, et al. 3D osteoarthritic changes in TMJ condylar morphology correlates with specific systemic and local biomarkers of disease. *Osteoarthritis Cartilage* 2014; 22: 1657-67.
  18. Byun ES, Ahn SJ, Kim TW. Relationship between internal derangement of the temporomandibular joint and dentofacial morphology in women with anterior open bite. *Am J Orthod Dentofac Orthop* 2005; 128: 87-95.
  19. Milam S. Pathogenesis of degenerative temporomandibular joint arthritides. *Odontology* 2005; 93: 7-15.
  20. Al-Koshab M, Nambiar P, John J. Assessment of condyle and glenoid fossa morphology using CBCT in south-east Asians. *PLoS One* 2015; 10: e0121682.
  21. Mostafavi M, Vahdat AS, Javadian L, Ghaznavi A. Analysis of condylar volume in relation to craniofacial morphology using cone beam computed tomography. *J Contemp Med Sci* 2018; 4: 202-6.
  22. Jain S, Choudhary K, Nagi R, Shukla S, Kaur N, Grover D. New evolution of cone-beam computed tomography in dentistry: combining digital echnologies. *Imaging Sci Dent* 2019; 49: 179-90.
  23. Ikeda K, Kawamura A, Ikeda R. Assessment of optimal condylar position in the coronal and axial planes with limited cone-beam computed tomography. *J Prosthodont* 2011; 20: 432-8.
  24. Schnabl D, Rottler AK, Schupp W, Boisserée W, Grunert I. CBCT and MRT imaging in patients clinically diagnosed with temporomandibular joint arthralgia. *Heliyon* 2018; 4: e00641.
  25. Pupo YM, Pantoja LL, Veiga FF, Stechman-Neto J, Zwir LF, Farago PV, et al. Diagnostic validity of clinical protocols to assess temporomandibular disk displacement disorders: a meta-analysis. *Oral Surg Oral Med Oral Pathol Radiol* 2016; 122: 572-86.
  26. Vogl TJ, Lauer HC, Lehnert T, Naguib NN, Ottl P, Filmann N, et al. The value of MRI in patients with temporomandibular joint dysfunction: correlation of MRI and clinical findings. *Eur J Radiol* 2016; 85: 714-9.
  27. Yushkevich PA, Gao Y, Gerig G. ITK-SNAP: an interactive tool for semi-automatic segmentation of multi-modality biomedical images. *Annu Int Conf IEEE Eng Med Biol Soc* 2016; 2016: 3342-5.