

## CASE REPORT

## Endovascular Repair of Ruptured Popliteal Artery Aneurysms: A Case Report and Review of the Literature

S.L. Brown <sup>a,\*</sup>, M. Lewis <sup>b</sup>, D.R. Morrow <sup>a</sup>

<sup>a</sup>Department of Vascular Surgery, Norfolk and Norwich University Hospital, Colney Lane, Norwich, Norfolk, NR4 7UY, UK

<sup>b</sup>Department of Interventional Radiology, Norfolk and Norwich University Hospital, Colney Lane, Norwich, Norfolk, NR4 7UY, UK

**Objective/Background:** The objectives were to report the management and outcomes of a 96-year-old man who presented with an acutely swollen right leg due to a ruptured popliteal aneurysm, and to review the relevant literature.

**Methods:** A ruptured popliteal artery aneurysm is a rare diagnosis and is one that is often missed at time of presentation. Previous case reports have documented successful outcomes following surgical repair, and a smaller number following endovascular repair. This is a case report of a 96-year-old man who eventually underwent endovascular repair of a ruptured popliteal artery aneurysm after a delay in diagnosis. A literature review was performed to analyse published data in this field.

**Results:** The patient underwent an uncomplicated endovascular repair with a GORE<sup>®</sup> VIABAHN<sup>®</sup> stent. A 15-week follow-up ultrasound demonstrated biphasic flow in a patent stent-graft with an unchanged aneurysm sac size and no evidence of an endoleak. A review of the literature demonstrated nine cases of ruptured non-mycotic popliteal artery aneurysms treated endovascularly. Seven cases survived the postoperative period, three had no follow-up recorded, and four cases had patent stent-grafts at time of follow-up.

**Conclusion:** Safe and effective endovascular repair of a ruptured popliteal artery aneurysm with endograft patency seen at the 15-week follow-up is reported. Review of the literature suggests that open repair remains the first-line management choice; however, endovascular repair is a valuable alternative. There is a further need for longer-term monitoring of endograft patency following endovascular repair.

© 2016 Published by Elsevier Ltd on behalf of European Society for Vascular Surgery. This is an open access article under the CC BY-NC-ND license (<http://creativecommons.org/licenses/by-nc-nd/4.0/>).

Article history: Received 10 March 2016, Revised 15 June 2016, Accepted 3 July 2016,

**Keywords:** Endovascular procedure, Gore Viabahn, Ruptured popliteal aneurysm

### BACKGROUND

The popliteal artery is the most common site for peripheral aneurysm formation.<sup>1</sup> However, rupture of a popliteal artery aneurysm is rare. A recent study has reported the incidence of rupture at the time of presentation at 2.2%.<sup>2</sup> Early diagnosis is key to prevent injury to life or limb. To date, no guidelines are available to advise on management of a ruptured popliteal artery aneurysm. Currently, surgical intervention is performed more frequently,<sup>3</sup> but endovascular repair is increasingly being used, particularly in those with multiple comorbidities.

This case report aims to add to the limited amount of evidence available,<sup>4</sup> demonstrating successful endovascular repair of a ruptured popliteal artery aneurysm.

### CASE PRESENTATION

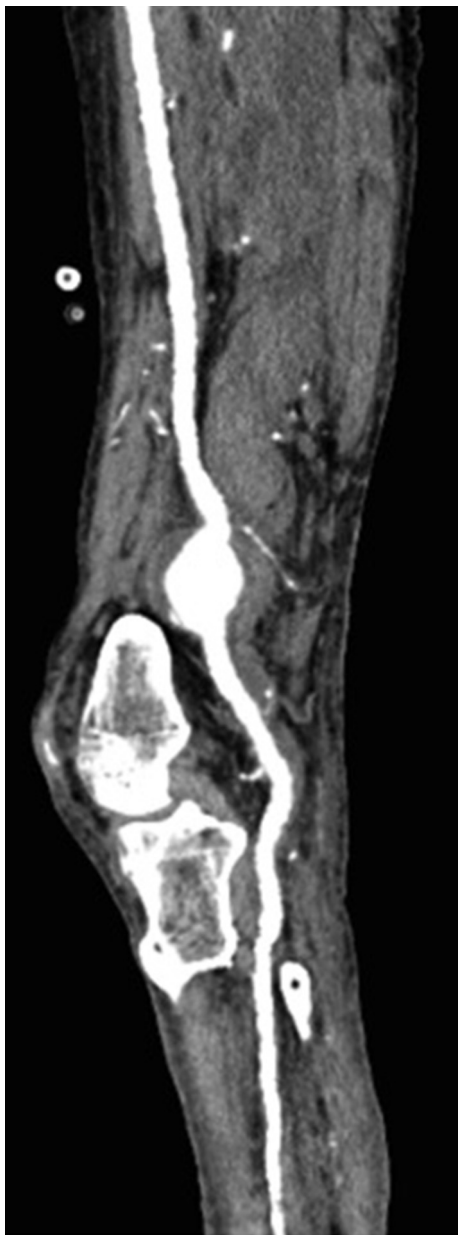A 96-year-old male ex-smoker with a background of benign prostatic disease and dementia was admitted to another hospital following a collapse at home. Blood tests performed on admission revealed a normocytic anaemia with a haemoglobin of 119 g/L, a raised D-dimer of 1095 ng/mL, normal troponin, normal C-reactive protein, and a neutrophilia of  $10.44 \times 10^9/L$ . A cause for the collapse and raised D-dimer were investigated; however, no cause was found. A diagnosis of venous thromboembolism was considered but excluded on the basis of Well's score; therefore, the patient was not anticoagulated and was discharged home with a course of antibiotics for a urinary tract infection.

The next day the patient was referred back to the medical team by his general practitioner with a swollen right knee and thigh with extensive bruising, suspicious for deep vein thrombosis. The patient attended the deep vein thrombosis clinic and underwent a lower limb ultrasound, which revealed a patent venous system and detected a popliteal artery aneurysm (anteroposterior diameter

\* Corresponding author. Department of Vascular Surgery, Norfolk and Norwich University Hospital, Colney Lane, Norwich, Norfolk, NR4 7UY, UK.  
E-mail address: [stephaniebrown@doctors.org.uk](mailto:stephaniebrown@doctors.org.uk) (S.L. Brown).

2405-6553/© 2016 Published by Elsevier Ltd on behalf of European Society for Vascular Surgery. This is an open access article under the CC BY-NC-ND license (<http://creativecommons.org/licenses/by-nc-nd/4.0/>).

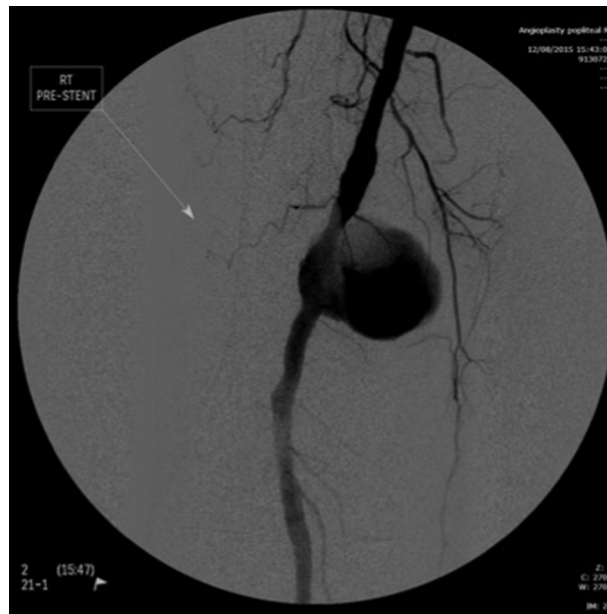
<http://dx.doi.org/10.1016/j.ejvssr.2016.07.001>



**Figure 1.** Computed tomography angiogram demonstrating the right 4 × 5 cm right saccular popliteal artery aneurysm (lateral view).

45 mm) with a haematoma in the medial aspect of the leg just above his knee that measured 11.4 × 5.2 cm. The patient was discharged home the same day and referred to the authors' vascular service for an urgent outpatient appointment that took place 7 days later. At this point, the patient was found to be having difficulty walking owing to pain in his right leg and he was admitted from the clinic as an emergency.

Clinically, extensive bruising was evident behind the patient's right knee and posterior-medial thigh. A pulsatile mass was felt posterior to the medial aspect of his right knee, and the pulsatile area was felt to be extending into his posterior mid-thigh. The patient's right foot was pulseless but not acutely ischaemic.



**Figure 2.** On-table angiogram showing right 4 × 5 cm saccular popliteal artery aneurysm pre-stent.

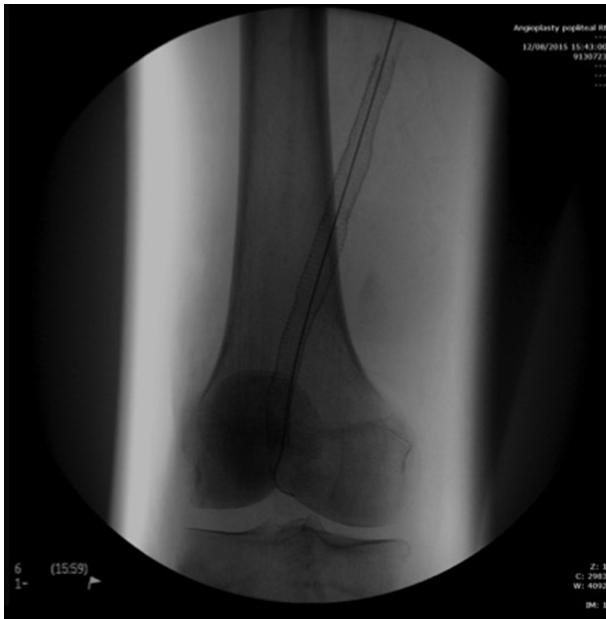Admission blood tests showed an acute normocytic anaemia with a haemoglobin level of 77 g/L. A computed tomography angiogram demonstrated a right 4 × 5 cm right saccular popliteal artery aneurysm with a large posterior thigh collection extending superiorly measuring approximately 23 × 3 cm (Fig. 1). Run-off was severely diseased but patent. No other aneurysmal disease in the aorta or more distally was identified. As part of the patient's management, he was transfused with blood and discussed in the vascular multidisciplinary team meeting.

Primarily because of the patient's age and longstanding cognitive impairment, the safest definitive management option was felt to be endovascular repair with insertion of an above-knee popliteal stent-graft. A GORE® VIABAHN® stent (W.L. Gore & Associates, Flagstaff, AZ, USA) was deployed through a right femoral cut-down under general anaesthetic (as decided by the anaesthetist at the time, although local anaesthetic may be preferable in some patients). Completion angiogram showed successful exclusion of the aneurysm (Figs. 2–4) with an unchanged run off. The patient was then started on dual antiplatelets post-operatively (aspirin and clopidogrel) for 3 months, followed by lifelong aspirin.

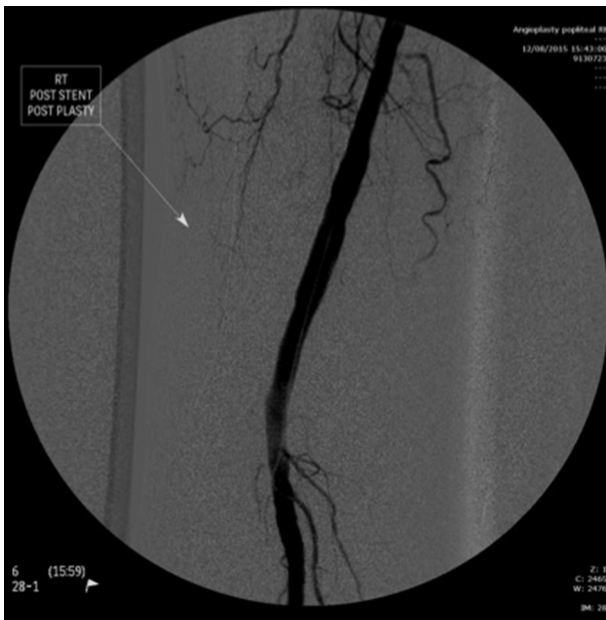### **Outcome and follow-up**

The patient was seen in clinic 6 weeks after his discharge from hospital. He was recovering well with the bruising and swelling having all settled down. A below-knee palpable pulse was present, indicating that the stent at this time was patent and the mass was no longer pulsatile.

A follow-up graft patency check was performed 15 weeks postoperatively. Doppler ultrasound showed biphasic flow in a patent stent. The aneurysm sac size was unchanged and



**Figure 3.** On-table imaging showing deployed stent.



**Figure 4.** On-table imaging showing completion angiogram.

no endoleak was seen. Owing to the patient's advancing dementia, no further outpatient follow-up has been arranged.

## DISCUSSION

This case report provides further evidence around the difficulty in diagnosing and managing cases of suspected ruptured popliteal artery aneurysms. It is hard to determine the point of rupture of this patient's popliteal artery aneurysm, whether it was triggered by his fall,

whether it caused his fall, or whether it happened after he was discharged. The authors' suspicions are that his collapse was triggered by rupture of the popliteal artery aneurysm, but it took several days for the diagnosis to become apparent. Clearly, the patient should have been admitted for treatment following the ultrasound scan, but the significance of the haematoma was not appreciated by the referring venous thromboembolism specialist nurse.

A PubMed database search was performed on 5 June 2016 to review the current literature surrounding ruptured popliteal artery aneurysms. To summarize, a total of 58 cases were found, 11 of which had been repaired with an endovascular technique (summarized in Table 1).

Out of the 58 cases, eight were mycotic of which two were repaired using endovascular techniques.<sup>5,6</sup> Both endografts were patent at the 6-month and 2-year follow-up.<sup>2,5</sup> The remaining six cases were surgically managed.

Out of the 50 non-mycotic aneurysms, 41 were treated with a surgical approach, including bypass or ligation, and nine were repaired using the endovascular approach.<sup>7–11</sup> Four of the endovascular cases demonstrated patent endografts at follow-up (two at 3 months,<sup>7</sup> one at 6 months,<sup>8</sup> and one at 1 year<sup>9</sup>). Two patients died within 3 days of the postoperative period of unrelated causes.<sup>7,10</sup> For three cases, specific follow-up was not recorded.<sup>11</sup> One endograft thrombosed immediately during the operation; after a successful thrombectomy, this endograft remained patent 3 months later.<sup>7</sup> Although the numbers are small, endovascular repair is showing promising results in terms of endograft patency and safety in the emergency setting.

Interestingly, a recent large Swedish study looking at patency results in 592 elective patients undergoing popliteal artery aneurysm repair either with the open or endovascular technique demonstrated lower endograft patency rates at both at 30 days and 1 year in the endovascular repair group compared with the open surgical method.<sup>2</sup>

Previous case studies have demonstrated missed or delayed diagnosis of a ruptured popliteal artery aneurysm. While reviewing the literature, nine cases were initially misdiagnosed. Five cases were diagnosed as a deep vein thrombosis,<sup>12–14</sup> one case was thought to be a knee haemarthrosis,<sup>12</sup> one a popliteal artery aneurysm thrombosis,<sup>12</sup> one a peroneal nerve neuritis,<sup>12</sup> and one an abscess.<sup>15</sup> On reflection, it is possible that nonvascular clinicians are misdiagnosing ruptured popliteal artery aneurysms in those with leg pain and swelling. This is an important differential particularly in those who are older, male, and who may have a history of hypertension and smoking.

To summarize, this case report reflects safe and effective endovascular repair of a ruptured popliteal aneurysm; however, although a valuable alternative, open repair remains the first-line choice at present.

**Table 1.** Summary of all 11 endovascular repairs of ruptured popliteal artery aneurysms.

Reference	Cases (n)	Age (y)	Mycotic	Symptoms	Diagnostic imaging	Size (cm)	Type of endovascular repair	Complications	Follow-up
Bani-Hani et al. <sup>5</sup>	1	85	Yes (group G <i>Streptococcus</i> )	Collapse, pyrexia, swollen limb	Duplex US, CT and MRI	2 × 12	2 × VIABAHN® endografts	Postoperative infected haematoma with multiple thigh collections	Patent at 24 mo
Schimmer and Somjen <sup>6</sup>	1	80	Yes ( <i>Staphylococcus aureus</i> )	Leg swelling and pyrexia	CT	NS	1 × VIABAHN® endograft	None	Patent at 6 mo
Gerasimidis et al. <sup>7,a</sup>	3	NS	NS	NS	NS	NS	HEMOBAHN® endograft	Intraoperative graft thrombosis, thrombectomy performed successfully	Died after 3 mo—graft patent
							HEMOBAHN® endograft	Died day 3 postoperatively from cardiac shock	NA
							WALLGRAFT® endograft	None	Patent at 31 mo
Smith et al. <sup>8</sup>	1	75	No	Knee pain	Duplex US and CT	4	Endovascular occlusion with 16 mm AMPLATZER™ vascular plug	None	Well at 6 mo, no follow-up imaging discussed
Yevgeniy et al. <sup>9</sup>	1	86	No	Acute swelling and pain of knee and thigh	CT	7	2 × VIABAHN® endografts	None	Patent at 12 mo
Lamoca et al. <sup>10</sup>	1	88	No	Swollen leg, hypovolaemic shock	Duplex US and CT	9.1	2 × VIABAHN® endografts	Died day 2 postoperatively—respiratory failure	NA
Möllenhoff et al. <sup>11,a</sup>	3	NS	NS	NS	NS	NS	NS	NS	NS

Note. US = ultrasound; CT = computed tomography; MRI = magnetic resonance imaging; NS = not specified; NA = not available.

<sup>a</sup> Individual cases not discussed as part of a study.

**CONFLICTS OF INTEREST**

None.

**FUNDING**

None.

**REFERENCES**

- 1 Galland RB. Popliteal aneurysms: from John Hunter to the 21st century. *Ann R Coll Surg Engl* 2007;**89**:466–71.
- 2 Cervin A, Tjarnstrom J, Ravn H, Acosta S, Hultgren R, Welander M, et al. Treatment of popliteal aneurysm by open and endovascular surgery: a contemporary study of 592 procedures in Sweden. *Eur J Vasc Endovasc Surg* 2015;**50**:342–50.
- 3 Coskun I, Demirturk OS, Tunel HA, Andic C, Gulcan O. Positive clinical outcomes of the saphenous vein interposition technique for ruptured popliteal artery aneurysm. *Surg Today* 2014;**44**:1674–7.
- 4 National Institute for Health and Clinical Excellence. *Interventional procedure overview of endovascular stent-grafting of popliteal aneurysms*. NICE Interventional procedures programme IP 817. 2010.
- 5 Bani-Hani MG, Elnahas L, Plant GR, Ward A, Moawad M. Endovascular management of ruptured infected popliteal artery aneurysm. *J Vasc Surg* 2012;**55**:532–4.
- 6 Schimmer W, Somjen GM. Endovascular repair of a ruptured, mycotic popliteal aneurysm. *ANZ J Surg* 2009;**79**:560–1.
- 7 Gerasimidis T, Sfyroeras G, Papazoglou K, Trellopoulos G, Ntinis A, Karamanos D. Endovascular treatment of popliteal artery aneurysms. *Eur J Vasc Endovasc Surg* 2003;**26**:506–11.
- 8 Smith RJ, Gajendragadkar PR, Winterbottom AP, Cooper DG, Hayes PD, Boyle JR. Endovascular occlusion of a ruptured popliteal artery aneurysm. *Vasc Endovasc Surg* 2010;**44**:298–301.
- 9 Yevgeniy R, Young E, Joseph R. Endovascular repair of a ruptured giant popliteal artery aneurysm. *Perspect Vasc Surg Endovasc Ther* 2009;**21**:190–4.
- 10 Lamoca LM, Alerany MB, Hernando LL. Endovascular therapy for a ruptured popliteal aneurysm. *Catheter Cardiovasc Interv* 2010;**75**:427–9.
- 11 Möllenhoff C, Katsargyris A, Steinbauer M, Tielliu I, Verhoeven EL. Current status of Hemobahn/Viabahn endografts for treatment of popliteal aneurysms. *J Cardiovasc Surg (Torino)* 2013;**54**:785–91.
- 12 Sie RB, Dawson I, van Baalen JM, Schultze Kool LJ, van Bockel JH. Ruptured popliteal artery aneurysm. An insidious complication. *Eur J Vasc Endovasc Surg* 1997;**13**:432–8.
- 13 Illig KA, Eagleton MJ, Shortell CK, Ouriel K, DeWeese JA, Green RM. Ruptured popliteal artery aneurysm. *J Vasc Surg* 1998;**27**:783–7.
- 14 Mathisen SR, Arvesen A, Kroese A. A construction worker with acute knee pain. *Tidsskr Nor Laegeforen* 2006;**126**:1488–9.
- 15 Dzieciuchowicz L, Winckiewicz M. Difficulties in diagnosis of ruptured popliteal artery aneurysm. *Wiad Lek* 2005;**58**:451–4.