

Sleeve fracture of the adult patella

Case report and review of the literature

Linjun Xie, MS, Hong Xu, MS, Lizhi Zhang, MD, Rong Xu, MS, Yingkun Guo, MD*

Abstract

Rationale: The patellar fractures are common in adults, but rare in children. As a particular type of patellar fracture, however, sleeve fractures are almost always limited to children in the under 16's group.

Patient concerns: Herein, we report a rare case of a 19-year-old healthy adult female who presented sleeve fracture at the superior pole of the left patella. The clinical and radiological features are found including joint effusion, anterior tilt of the patella and a shell of bone lying proximally to the patella.

Diagnoses: Computed tomography and magnetic resonance imaging examination have been performed to further confirm the diagnosis of sleeve fracture, rupture of the quadriceps tendon and the cartilaginous injury.

Interventions: Under general anaesthesia, she underwent open surgical procedures for reconstituting anatomically the fracture and repairing the rupture of the quadriceps tendon.

Outcomes: Six months after the operation, she could fully use her left knee without any pain and disability.

Lessons: Sleeve fractures of the patellar in adults are extremely rare, and our case is of interest for the first time occurring in healthy female adults. Our case report and literature review was aim to describe the clinic and imaging characteristics of superior pole sleeve fractures in adults, and highlight that physicians must be aware of this entity in adults so as to reduce misdiagnosis due to unfamiliarity.

Abbreviations: CPM = continuous passive activity, CT = computed tomography, MRI = magnetic resonance imaging.

Keywords: computed tomography, magnetic resonance imaging, patella, sleeve fracture, x-ray

1. Introduction

Sleeve fractures are rare and a common type of patellar fracture affecting in children under 16 years.^[1] The reasons can be explained that the immature osteochondral junction in child is more vulnerable to injury than the enthesis of the fully ossified adult patella, which leads to a sleeve of avulsion pulled off the main bony patella, usually from the lower pole. However, sleeve fractures of the superior patella pole are uncommon, and a few reported cases are mostly involved the early adolescents.^[2] In adults, sleeve fractures are extremely rare form of patellar fracture. Up to now, to the best of our knowledge, only 3 cases

involving the male adults were reported in the English literatures, including 2 healthy men and 1 patient with osteogenesis imperfect.^[3–5] For the first time, we present an extremely rare case of a sleeve fracture of the superior patellar pole in a healthy woman. As an untreated case may lead to permanent disabilities, the literature review of sleeve fracture is vital for unfamiliar physician to make prompt diagnosis and clinical managements.

2. Case report

A 19-year-old woman was transferred to our hospital because of traumatic injury at the superior pole of the patella with history of a fall by jumping. The initial clinical complaint is a sudden severe pain with the incapacity of walking afterwards. Physical examination showed reduced active movements of her left knee, swelling, and joint effusion. Plain x-rays showed patella baja and an avulsed fragment of the superior pole of the patella (Fig. 1). Computed tomography (CT) scan revealed a shell of bone lying proximally to the patella on multiplanar reconstruction (Fig. 2A) and shaded surface display images (Fig. 2B). Clinically, disruption of the extensor mechanism was suspected. Magnetic resonance imaging (MRI) has been performed to determine the diagnosis of rupture of the quadriceps tendon and the cartilaginous injury (Fig. 3). Under general anesthesia, she underwent open surgical procedures for reconstituting anatomically the fracture and repairing the rupture of the quadriceps tendon. All the above-mentioned imaging findings were confirmed during surgical procedures. Intraoperatively, a bony fragment with a piece of articular cartilage was found above the patella, proximal quadriceps tendon was seen attached the bone pieces, and a same size bone cortical defects were seen on patella. Based on the postulation that the bony fragment pulled off the upper pole of the patella, the diagnosis of sleeve fracture of the upper pole of the

Editor: Giovanni Tarantino.

LX and HX contributed equally to this work and should be considered cofirst authors.

The authors declare no conflicts of interest.

Department of Radiology; Key Laboratory of Obstetric and Gynecologic and Pediatric Diseases and Birth Defects of Ministry of Education; West China Second University Hospital, Sichuan University, Chengdu, China.

* Correspondence: Yingkun Guo, Department of Radiology, Key Laboratory of Obstetric and Gynecologic and Pediatric Diseases and Birth Defects of Ministry of Education, West China Second University Hospital, Sichuan University, 20# Section 3 South Renmin Road, Chengdu, Sichuan 610041, China (e-mail: gykpanda@163.com).

Copyright © 2017 the Author(s). Published by Wolters Kluwer Health, Inc. This is an open access article distributed under the terms of the Creative Commons Attribution-Noncommercial License 4.0 (CCBY-NC), where it is permissible to download, share, remix, transform, and build-up the work provided it is properly cited. The work cannot be used commercially without permission from the journal.

Medicine (2017) 96:32(e7096)

Received: 3 November 2016 / Received in final form: 11 May 2017 / Accepted: 12 May 2017

<http://dx.doi.org/10.1097/MD.0000000000007096>

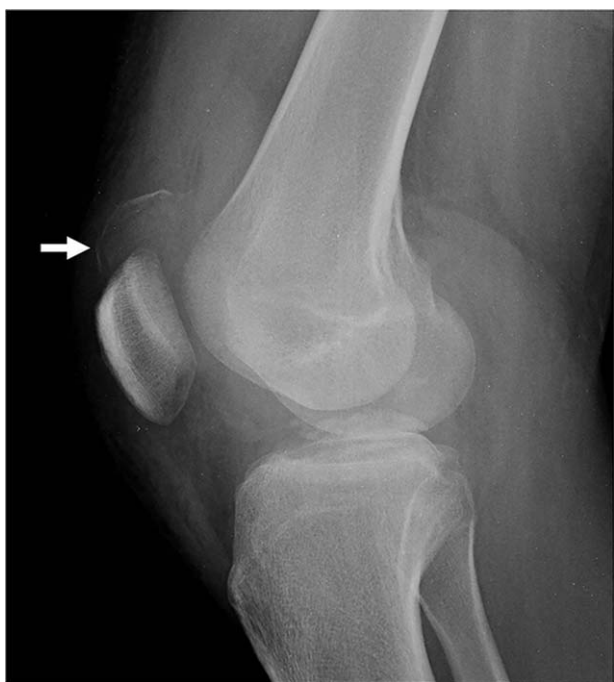

Figure 1. A 19-year-old female with sleeve fracture at the superior pole of the left patella. Patella and avulsed fragment are showed in plain radiograph (arrows).

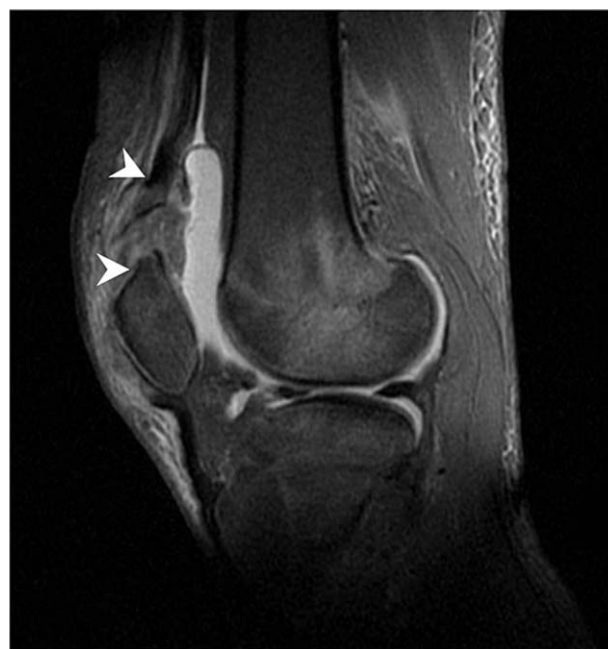

Figure 3. Quadriceps tendon rupture, cartilaginous injury (arrowheads), and joint effusion are visualized at 1.5 T magnetic resonance image (sagittal view, FSE sequence, TR 3,700ms, TE 46ms).

patella was finally reached. Then, complete removal of the blood clot and tissue debris in the joint cavity and around the broken ends of the quadriceps tendon was performed. Joint capsule and quadriceps tendon were sutured, patella fracture piece was reset and pulled down to the front, and wire fixation was applied. After surgery a gypsum fixed knee joint in the extension position was chosen for therapy. Postoperative x-ray report showed patellar position and shape of normal, fixed well. After surgery with gypsum, fixed knee joint in the extension position and weight-bearing was permitted with a crutch. Rehabilitation plan include instructing the patient postoperative quadriceps training, cast fixed knee joint after 4 weeks of continuous passive activity (CPM), and CPM functional exercise for 2 weeks. At the 6-month follow-up, the patient reported a knee free of swelling, normal appearance,

and the recovered capacity of straight, normal, flexion 120 degrees, and free walking.

Because this report just reviewed previous data and did not involve any human trials, there is no need to conduct special ethic review, and the ethical approval is not necessary. Written informed consent was obtained from the patient for the publication of this case report and its accompanying images.

3. Discussion

Sleeve fractures of the patella in children as a term was first described by Houghton et al.^[6] In 1979, which was determined as a sleeve of cartilage pulled off the main bony patella. Because of rapid quadriceps contraction against resistance in trauma, a small avulsion was often taken from the distal pole of the patella.

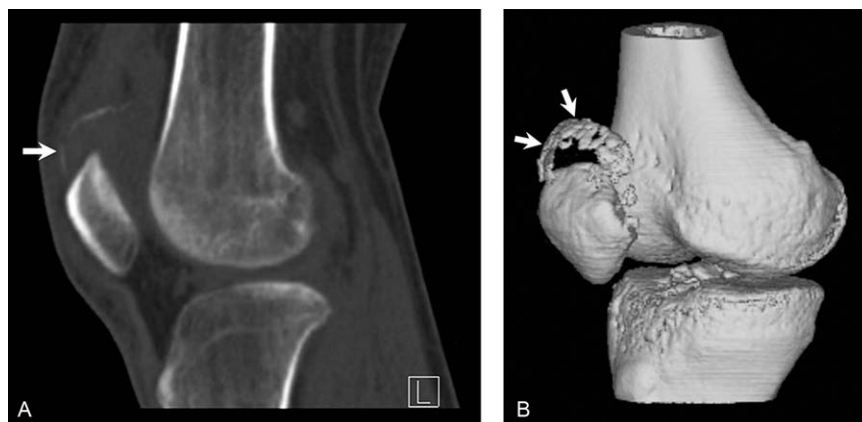


Figure 2. On computed tomography (CT) images, a shell of bone lying proximally to the patella is showed on multiplanar reconstruction (A) and shaded surface display images (B).

Table 1**Reported cases of the patellar sleeve fractures in adults.**

Case	Year	Sex	Age, y	History	Location	Treatment	Follow-up
Current	2014	F	19	Healthy	Upper pole	Surgery	Fully recovery after 6 months
No. 2	2014	M	24	Healthy	Upper pole	Surgery	Fully recovery after 26 months
No. 3	2013	M	22	Healthy	Upper pole	Conservative	Function regain after 3 weeks
No. 4	2003	M	30	Osteogenesis imperfecta	Upper pole	Surgery	Fracture union after 6 months

Similar to adults, patella fractures make up 1% of all fractures in children. However, sleeve fractures are almost unique to children, and make up 57% of all patella fractures under 16 years group. Age-range predominance of this injury is probably explained that the more flexible ligaments, hyaline cartilage, and joint capsule in children result in greater joint laxity for protecting the patella from traumatic events. Thus, avulse cartilage or bone is frequently found rather than rupture the tendon.^[1,2]

Sleeve fractures of the patella in children usually occur in the inferior pole of the patella, very rarely in the superior pole. However, sleeve fractures of the patella mainly affect the superior pole in adults, with a predilection for men (3 males, 1 female), aged 19 to 30 years (Table 1).^[3-5] Compared with the immature and vulnerable osteochondral junction in children, the enthesis of a fully ossified patella in adults is more resistant to tensile force injury, so the patellar sleeve fractures in adults are extremely rare.^[7] Ten years ago, Kakazu et al^[5] showed that the superior pole patellar sleeve avulsions occurred in a 30-year-old man with osteogenesis imperfecta. Except for such weakened skeleton, only 2 cases of sleeve fractures in healthy adult men have been reported in the English literatures.^[3,4] The current case is of interest because of such a rare form of injury occurred in healthy adult woman that has not yet been reported in the literature.

Clinically, treatment options including conservative and surgical treatment depends on the severity of bone displacement and the extensor mechanism of the knee.^[3-5] Sleeve fractures predominantly involve the cartilaginous portion of the patella in children. Conventional radiography occasionally underestimated the severity of the avulsion fracture. Diagnosis may be missed or delayed due to clinical unfamiliarity and on the x-ray findings that may look normal if there is no a high index of suspicion. MR

imaging is helpful for assessing the need for surgery because of comprehensively demonstrating the extent of cartilaginous injury, joint involvement, and rupture of the quadriceps tendon. Because the osteogenic tissue in the sleeve are potentially enlarging the patella, an untreated case may lead to complications including patella magna, extensor lag, and quadriceps muscle atrophy, even permanent disabilities.^[1,2,7] For full function recovery, the sleeve fracture should be promptly and properly treated with internal fixation or immobilization. When the sleeve fracture and disruption of the extensor mechanism were suspected, combined with ultrasound, CT, or MRI examination may be helpful for offering the potential to improve diagnostic confidence, make better decisions and reduce the frequency of clinical hazards.

References

- [1] Hunt DM, Somashekar NA. review of sleeve fractures of the patella in children. *Knee* 2005;12:3-7.
- [2] Ray JM, Hendrix J. Incidence, mechanism of injury, and treatment of fractures of the patella in children. *J Trauma* 1992;32:464-7.
- [3] Ro KH, Park JH, Kim MJ, et al. Rare sleeve fracture of the superior patella pole in an adult due to forceful passive physiotherapy following cast immobilization. *Knee* 2014;21:600-4.
- [4] Teixeira PA, Lecocq S, Moisei A, et al. Sleeve-like avulsion fracture of the superior pole of the patella in a healthy adult. *Diagn Interv Imaging* 2013;94:108-11.
- [5] Kakazu T, Tatemoto H, Kawamura M, et al. Sleeve fracture of the upper pole of the patella in an adult with osteogenesis imperfecta. *Injury* 2003;34:793-4.
- [6] Houghton GR, Ackroyd CE. Sleeve fractures of the patella in children: a report of three cases. *J Bone Joint Surg Br* 1979;61-B:165-8.
- [7] Gettys FK, Morgan RJ, Fleischli JE. Superior pole sleeve fracture of the patella. *Am J Sports Med* 2010;38:2331-6.