

## CASE REPORT

# Successful stenting of four spontaneous oesophageal perforations in a single patient during a 3-year period

Magnus Sundbom<sup>\*†</sup> and Jakob Hedberg<sup>†</sup>

Department of Surgical Sciences, Upper Gastrointestinal Surgery, Uppsala University, Uppsala, Sweden

<sup>\*</sup>Correspondence address. Department of Surgical Sciences, Upper Gastrointestinal Surgery, Uppsala University, Ingång 70, SE-751 85 Uppsala, Sweden.  
Tel: +46-18-6114616; Fax: +46-18-556808; E-mail: magnus.sundbom@surgsci.uu.se

## Abstract

Spontaneous oesophageal perforation, a rare condition associated with high mortality due to mediastinitis and multi-organ failure, can be treated surgically or with endoscopic stents. We present a case of four right-sided oesophageal perforations during a 3-year period in a single patient, all successfully stented. The 51-year-old Caucasian male had his first oesophageal perforation in 2012, which was successfully treated with a fully covered endoscopic stent. No residual pathology was seen at stent removal. Two years later, the patient was successfully treated with stents twice for recurrent perforations. The fourth spontaneous perforation at the same site occurred this fall, and again endoscopic treatment was successful. The patient does not report any squeals. In spite of the successful outcome, we would like to emphasize the need for close surveillance and readiness for definitive surgical treatment.

## INTRODUCTION

Spontaneous oesophageal perforations typically occur after vomiting due to high intraluminal oesophageal pressure. Most commonly, the perforation occurs on the left, a couple of centimetres proximal to the gastro-oesophageal junction [1]. An untreated oesophageal perforation will most often lead to mediastinitis and multi-organ failure. With a mortality of 17–25% [2, 3], this is the most lethal gastrointestinal perforation. Historically, prompt aggressive surgery was used to close the perforation or to redirect the oesophageal flow from the mediastinum [4]. During the last decades, endoscopic treatment, for example, stenting, in combination with broad-spectrum antibiotics, adequate drainage and intensive care, has been used with good results [5].

To date, only eight cases of recurrent oesophageal perforations, occurring up to 30 years after the first perforation, have been published [6]. The majority of these patients were treated by surgical repair through a thoracotomy at the initial episode, as well as at the recurrent perforation, although, supportive

care was used in a few. No case of subsequent recurrence, that is, three perforations or more, has been reported, neither the repeated use of endoscopic stents.

## CASE REPORT

The present case concerns a 51-year-old man with a history of alcohol abuse and two myocardial infarctions. In September–October 2012, he was successfully treated for a peptic stricture in the distal oesophagus with two endoscopic dilatations and proton pump inhibitors. Biopsies were normal.

### Episode 1

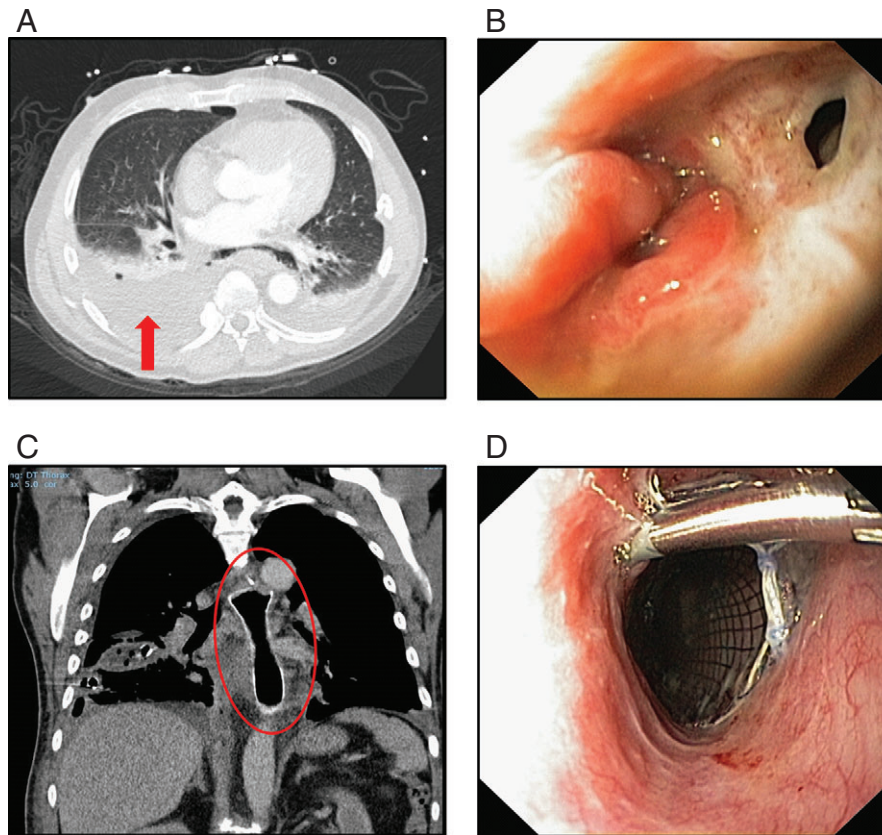
In late December 2012, the patient was admitted to the emergency department with a 2-day history of haematemesis and upper abdominal pain. A computed tomography (CT) scan demonstrated gas in the mediastinum and a massive pleural effusion on the right side (Fig. 1A). Endoscopy revealed an

<sup>†</sup>Author contributions: Sundbom M. and Hedberg J. contributed equally to both the care of the patient and preparation of this manuscript.

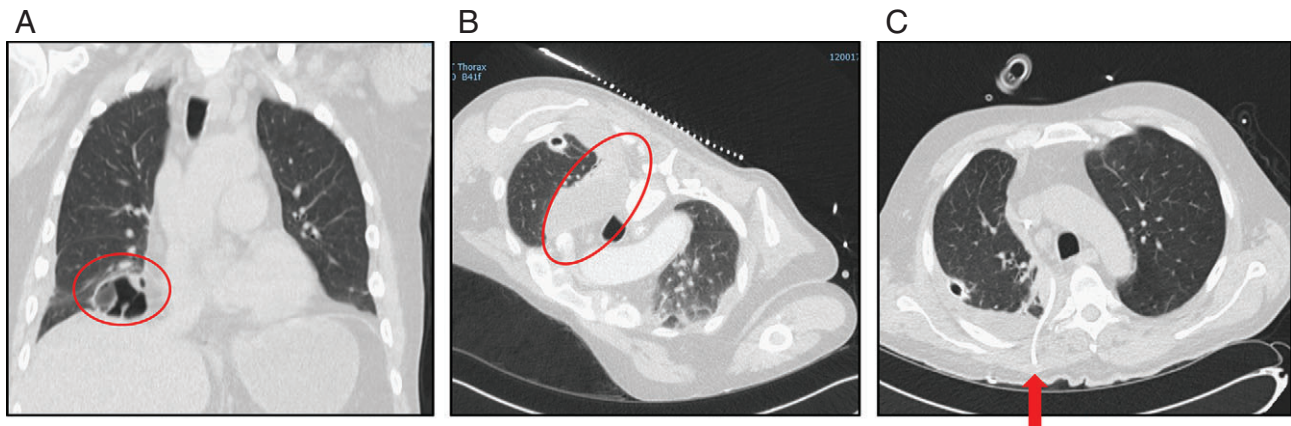
Received: January 26, 2016. Accepted: March 6, 2016

Published by Oxford University Press and JSCR Publishing Ltd. All rights reserved. © The Author 2016.

This is an Open Access article distributed under the terms of the Creative Commons Attribution Non-Commercial License (<http://creativecommons.org/licenses/by-nc/4.0/>), which permits non-commercial re-use, distribution, and reproduction in any medium, provided the original work is properly cited. For commercial re-use, please contact [journals.permissions@oup.com](mailto:journals.permissions@oup.com)



**Figure 1:** Episode 1. (A) Gas in the mediastinum and massive pleural effusion in the right hemithorax (red arrow). (B) Distal oesophageal perforation with surrounding granulation at endoscopy. (C) and (D) Stent in place. Note the clip marking the upper border of the stent, simplifying radiological slippage assessment.



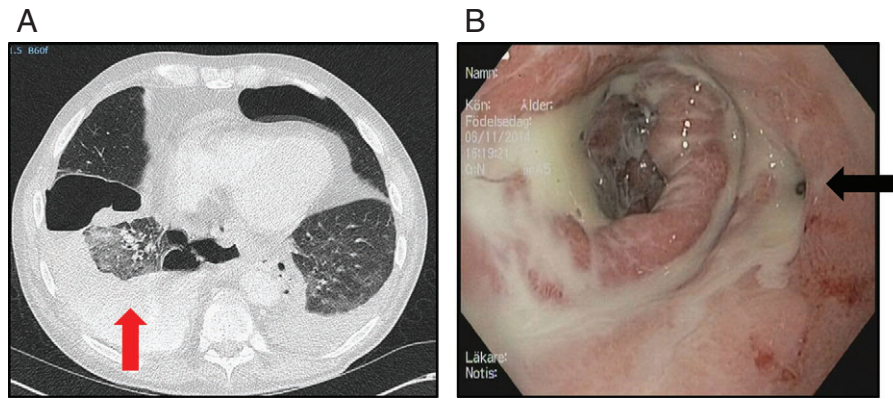
**Figure 2:** Episode 2. (A) Small basal right-sided pneumothorax with a gas-liquid level (red circle) on admission. (B) and (C) Successful CT-guided drainage of an apical right-sided mediastinal abscess (red circle) with a dorsal pig-tail drain left in place (red arrow).

oesophageal perforation, 2 cm above the gastro-oesophageal junction on the right side, as well as widespread esophagitis (Fig. 1B). After careful irrigation with warm saline, a 28-mm fully covered 120-mm long stent (Micro-Tech Europe GmbH, Düsseldorf, Germany) was inserted under fluoroscopic guidance. A haemostatic clip (Olympus Europe, Hamburg, Germany) was placed to mark the upper limit of the stent, allowing easy identification of stent slippage on subsequent chest X-rays, according to our routine (Fig. 1C and D). The postoperative course was uneventful, except one stent repositioning, and the patient could return home after 23 days. When stent was removed 2 weeks

later, that is, 40 days after admittance, the perforation had healed fully and no residual pathology was found.

### Episode 2

In April 2014, the patient had a recurrent oesophageal perforation with a gas-liquid level in a right-sided pneumothorax, however, no free air was seen in the mediastinum (Fig. 2A). Endoscopy demonstrated a new perforation in the same area, which was sealed with an identical stent. The pleural effusion was drained. In intensive care, the patient required a tracheotomy as well as



**Figure 3:** Episode 3. (A) Massive leakage of per oral water-soluble contrast into the right pleural cavity (red arrow) on admission. (B) Remaining opening, 32 days after stent insertion (black arrow), successfully healed a month later.

haemodialysis due to respiratory and renal failure. Several abscesses were treated with ultrasound or CT-guided drains (Fig. 2B and C). Definitive surgical treatment with an end-cervical oesophagostomy was discussed; however, the patient's condition improved. No remaining oesophageal pathology was seen at stent removal (Day 13), and after 39 days in total, he left the hospital.

### Episode 3

The third oesophageal perforation occurred 6 months later (Fig. 3A). After resuscitation, endoscopy revealed a recurrent perforation, successfully treated by a fully covered stent. At the time of stent removal (Day 32), the perforation had not healed completely, why a new stent was placed (Fig. 3B). A month later, only a superficial erosion remained.

### Episode 4

In August 2015, the patient experienced severe chest pain after having had haematemesis and a CT scan revealed free air around the distal oesophagus and a right-sided pneumothorax. At endoscopy, a recurrent perforation could be sealed with a large bore stent. Except for drainage of an abscess in the right pleura, the course was uneventful and the patient discharged in 10 days. A small remaining defect, seen at 5 weeks, had totally healed a month later.

## DISCUSSION

This is the first report on four spontaneous oesophageal perforations in a single patient, all successfully treated by endoscopic stenting. In addition, right-sided oesophageal perforations are rare [7]; however, in the present case, the prior endoscopic dilatations could have created a local weakening in the oesophageal wall.

Spontaneous oesophageal perforation is a rare condition associated with high mortality due to mediastinitis and multi-organ failure. Treatment recommendations vary from urgent surgical treatment [8] to endoscopic stenting [1, 9]. After a literature review in 2008, de Schipper et al. [1] suggest endoscopic treatment if the perforation is diagnosed within 48 hours in a patient without sepsis, otherwise thoracotomy. In 2013, Spapen et al. reduced the time span to 24 hours [9]. As demonstrated here, slippage of the stent is rather common, but by placing a clip in the oesophageal mucosa, migration can be monitored by

chest X-rays. Please note that intubated patients are in extra need of surveillance, relying only on indirect signs, for example, saliva/air in the chest tube or instillation of methylene blue via a nasogastric tube, to ensure that the perforation is totally sealed.

In the presented case, definitive surgical treatment with an end-oesophagostomy was discussed during the second episode. In retrospect, this might have been beneficial, but at that time, the patient's condition was considered to be too poor. In addition, if an end-oesophagostomy is created, a second procedure to restore the oesophago-gastric continuity is mandatory. It is, however, important to remember that in patients who have severe mediastinal contamination, a surgical procedure allowing thorough cleaning of the area around the perforation can be compulsory and life-saving.

In summary, endoscopic treatment is often sufficient in treating oesophageal perforations, even in a compromised patient experiencing recurrent episodes, as shown here. In spite of the successful outcome, we would, however, like to emphasize the need for close surveillance and consideration of definitive surgical treatment in this rare and life-threatening condition.

## DECLARATIONS

According to Swedish law, no ethical approval is needed for case report studies. The patient has given written consent to the anonymized presentation of this case report. Authors M.S. and J.H. have both contributed with conception of this report, data gathering and manuscript preparation.

## CONFLICT OF INTEREST STATEMENT

None declared.

## REFERENCES

- de Schipper JP, Pull ter Gunne AF, Oostvogel HJ, van Laarhoven CJ. Spontaneous rupture of the oesophagus: Boerhaave's syndrome in 2008. Literature review and treatment algorithm. *Dig Surg* 2009;26:1–6. Epub 2009/01/16. doi:10.1159/000191283. PubMed PMID: 19145081.
- Vidarsdottir H, Blondal S, Alfredsson H, Geirsson A, Gudbjartsson T. Oesophageal perforations in Iceland: A whole population study on incidence, aetiology and surgical

- outcome. *Thorac Cardiovasc Surg* 2010;**58**:476–80. Epub 2010/11/27. doi:10.1055/s-0030-1250347. PubMed PMID: 21110271.
3. Markar SR, Mackenzie H, Wiggins T, Askari A, Faiz O, Zaninotto G, et al. Management and outcomes of esophageal perforation: A national study of 2,564 patients in England. *Am J Gastroenterol* 2015;**110**:1559–66. doi:10.1038/ajg.2015.304. PubMed PMID: 26437667.
  4. Barrett NR. Report of a case of spontaneous perforation of the oesophagus successfully treated by operation. *Br J Surg* 1947;**35**:216–8. Epub 1947/10/01. PubMed PMID: 20271775.
  5. Dasari BV, Neely D, Kennedy A, Spence G, Rice P, Mackle E, et al. The role of esophageal stents in the management of esophageal anastomotic leaks and benign esophageal perforations. *Ann Surg* 2014;**259**:852–60. Epub 2014/02/11. doi:10.1097/SLA.0000000000000564. PubMed PMID: 24509201.
  6. Ieta K, Oki A, Teshigahara K, Osone K, Sasaki S, Nakamura J, et al. Recurrent spontaneous esophageal rupture. *Clin J Gastroenterol* 2013;**6**:33–7. doi:10.1007/s12328-012-0356-8. PubMed PMID: 26181402.
  7. Reardon ES, Martin LW. Boerhaave's syndrome presenting as a mid-esophageal perforation associated with a right-sided pleural effusion. *J Surg Case Rep* 2015;**2015**. Epub 2015/11/27. doi:10.1093/jscr/rjv142. PubMed PMID: 26608019; PubMed Central PMCID: PMC4658504.
  8. Abu-Daff S, Shamji F, Ivanovic J, Villeneuve PJ, Gilbert S, Maziak DE, et al. Esophagectomy in esophageal perforations: An analysis. *Dis Esophagus* 2014. Epub 2014/10/21. doi:10.1111/dote.12294. PubMed PMID: 25327568.
  9. Spapen J, De Regt J, Nieboer K, Verfaillie G, Honore PM, Spapen H. Boerhaave's syndrome: Still a diagnostic and therapeutic challenge in the 21st century. *Case Rep Crit Care* 2013;**2013**:161286. Epub 2013/01/01. doi:10.1155/2013/161286. PubMed PMID: 24829816; PubMed Central PMCID: PMC4010036.