

CASE REPORT

General Medicine

Myocarditis and pericarditis after vaccination for COVID-19

 Blake Hudson MD¹ | Ryan Mantooth MD² | Matthew DeLaney MD¹
¹ University of Alabama at Birmingham, Mantooth is Washington Regional Medical Center, Birmingham, Alabama, USA

² Washington Regional Medical Center, Fayetteville, Arkansas, USA

Correspondence

 Matthew DeLaney, MD, University of Alabama,
 Birmingham, AL 35209, USA.

 Email: matthewcdelaney@gmail.com

Funding and support: By *JACEP Open* policy, all authors are required to disclose any and all commercial, financial, and other relationships in any way related to the subject of this article as per ICMJE conflict of interest guidelines (see www.icmje.org). The authors have stated that no such relationships exist.

Abstract

Two previously healthy males presented to the emergency symptoms with signs of pericarditis/myocarditis after being vaccinated with an mRNA vaccine for COVID-19.

KEYWORDS

COVID-19, cardiology, ECG, myocarditis, pericarditis, vaccine

1 | INTRODUCTION

With the rapid development and rollout of vaccinations for COVID-19 patients are reporting a variety of possible vaccine-related adverse events. Acute myocarditis (AM) and pericarditis are 2 potential complications that have been associated with previous vaccinations.¹ Although the exact incidence of AM after vaccination is somewhat unclear, recent studies have reported cases of clinically significant AM in ~1:5500 patients after smallpox vaccination.² Less commonly similar cases have been reported after vaccinations for influenza and human papillomavirus.³ More recently there have been various reports in the lay press of AM after vaccination for COVID-19. This case series presents 2 patients with concerns of myocarditis shortly after receiving their second vaccine.

2 | NARRATIVE

2.1 | Case #1

A previously healthy 24-year-old male presented to the emergency department with worsening myalgias and fevers, chills, nausea, vomiting, and 24 hours of worsening midline, substernal burning that was worse when lying flat. These symptoms began 3 days after receiving his second Pfizer COVID-19 vaccination.

His physical examination was normal other than an initial blood pressure of 174/84 mmHg.

The patient's initial ECG (Figure 1) showed J-point elevation in the lateral leads with slightly widened QRS complexes.

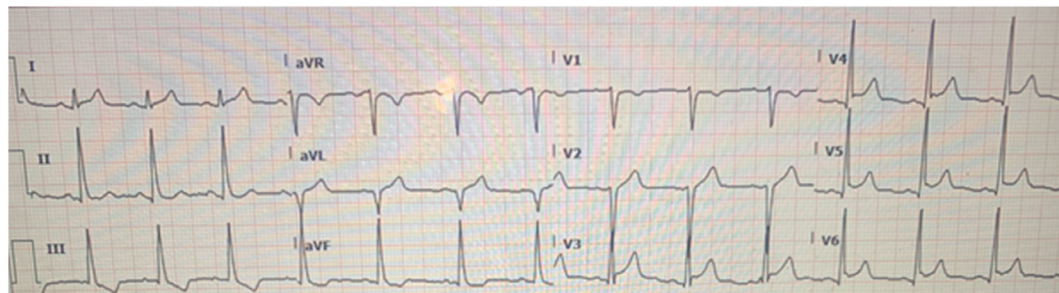


FIGURE 1 Initial electrocardiogram

Supervising Editor: Kenneth Katz, MD

This is an open access article under the terms of the [Creative Commons Attribution-NonCommercial-NoDerivs](https://creativecommons.org/licenses/by-nc-nd/4.0/) License, which permits use and distribution in any medium, provided the original work is properly cited, the use is non-commercial and no modifications or adaptations are made.

© 2021 The Authors. *JACEP Open* published by Wiley Periodicals LLC on behalf of American College of Emergency Physicians

Laboratory tests were as follows:

Troponin	Gen 5 Troponin	Brain natriuretic peptide	D-dimer (FEU)	WBC count	Erythrocyte sedimentation rate	C-reactive protein
1.5 ng/mL (<0.09)	261 ng/L (<15)	420 (<450)	843 ng/mL (<499)	11.3 K/mcL	6 mm/hr (0-15 mm/hr)	3.6 mg/dL (<0.9 mg/dL)

Rapid influenza and COVID-19 testing nasal polymerase chain reaction (PCR) testing were negative.

Chest x-ray and computed tomography (CT) angiography of the chest were unremarkable.

Because of the patient's ECG findings and symptoms, a diagnosis of myopericarditis was made. Cardiology was consulted and the patient was admitted to the hospitalist service. Inpatient echocardiography revealed a normal ejection fraction (EF) without any obvious abnormality. The patient was started on aspirin 650 mg thrice daily and colchicine 0.6 mg twice daily. His troponin peaked at 685 ng/L and was discharged 2 days later with 3 months of daily aspirin and colchicine with a presumed diagnosis of myopericarditis.

2.2 | Case #2

A previously healthy 22-year-old male presented to the ED with 3 days of worsening chills, low-grade fevers, and chest pain. He states that the morning of presentation, his pain intensified and was described as pressure in the center-left chest without any radiation. He noticed his symptoms started \approx 12 hours after his second Pfizer vaccination. He denied any other associated symptoms.

Rapid influenza and COVID-19 testing nasal PCR testing were negative.

The patient was noted to have significant diaphoresis but had an otherwise normal examination. Patient's initial ECG was normal; however, repeat ECG (Figure 2) several hours later revealed the following.

Notable laboratory tests:

Troponin	Gen 5 Troponin	D-dimer (FEU)	WBC count	Erythrocyte sedimentation rate	C-reactive protein
1.05 ng/mL (<0.09)	268 ng/L (<15)	491 ng/mL (<499)	9.97 K/mcL	4 mm/hr (0-15 mm/hr)	3.6 mg/dL (<0.9 mg/dL)

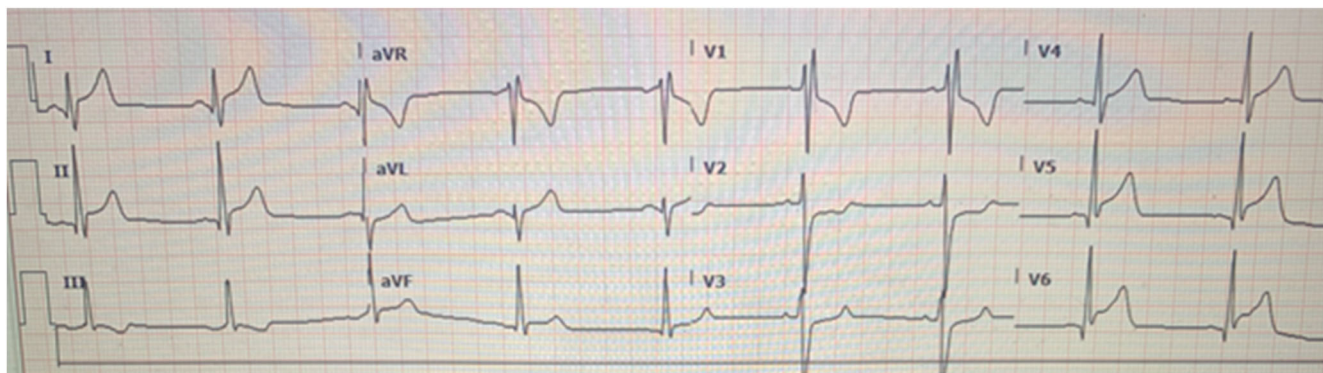


FIGURE 2 Initial electrocardiogram

The patient was admitted to the hospital and was started on aspirin and colchicine, and then transitioned to ibuprofen 400 mg three times a day with colchicine 0.6 mg daily at discharge. His initial echocardiogram showed a normal EF but did have trace mitral and tricuspid regurgitation. A subsequent echo 2 days later was normal. The patient was discharged after an uneventful hospital stay with a presumed diagnosis of myopericarditis.

3 | DISCUSSION

Historically, cases of AM have been reported after a variety of vaccinations. With the development of novel mRNA based vaccinations for COVID-19, it is unclear if this new technology could pose a similar risk of myocarditis and pericarditis. These 2 cases appear to be some of the earliest cases of myocarditis and pericarditis after vaccination for COVID-19. Although the medical literature gives little insight into the incidence of these potential complications, there are an increasing number of reports from the lay press. The first reported case appears to have occurred in early February when a 19-year-old male in Israel was hospitalized with myocarditis after receiving his second vaccination.⁴

In late April 2021 various news outlets worldwide reported on a leaked and redacted report allegedly from the Israeli Health Ministry on potential cases of myocarditis after vaccination.⁵ Following these early reports, a commission was established to investigate these cases.

Also in late April, a review by the website Military.com of the Food and Drug Administration's Vaccine Adverse Event Report

System (VAERS) database found that as of April 26, 2021 there were 45 reported cases of myocarditis after vaccination. The majority of patients were men between 22 and 40 years old. Of these cases, 19 were reported after the Pfizer vaccine and 26 after the Moderna vaccine.⁶ In late April the US Department of Defense acknowledged that it had been tracking cases of myocarditis since March 2021 and was aware of 14 cases. All but 1 of these patients developed symptoms after their second vaccine dose. In terms of particular agents, 11 of these reported cases involved the Moderna vaccine with 3 involving the Pfizer version.

In early June 2021 the Israeli Health Ministry released a report noting that 275 cases of myocarditis had been reported between December 2020 and May 2021 out of a cohort of approximately 5 million vaccinated patients. Although ~95% of the cases were categorized as mild, the health ministry reported 2 cases of fatal myocarditis in a previously healthy 22-year-old woman and a 35-year-old man. In terms of specific risk factors, most of the reported cases appear to have happened after the second dose of the mRNA vaccine. As seen in the review of the VAERS database, patient age and gender seemed to be an additional risk factors with the authors concluding that “there is a probable link between receiving the second dose of the vaccine and the appearance of myocarditis among men aged 16 to 30 years old.”⁷ The authors noted the association between vaccination and myocarditis was most notable in 16–19 year-old men but did not provide a precise estimate of the magnitude of any potential association in these patients.⁸

Currently the response to these potential vaccine related cases has been variable. Following this report from Israel, a press release from Pfizer stated that although they were aware of these reported cases they had “not observed a higher rate of myocarditis than what would be expected in the general population... a causal link to the vaccine has not been established.” In late May 2021, the Centers for Disease Control and Prevention (CDC) reported that they were aware of “increased cases of myocarditis and pericarditis” after vaccination with both the Pfizer and Moderna mRNA vaccines. Echoing the Israeli report, the CDC reported that these cases appeared more frequently in adolescent males after the second vaccination. Despite these reports, the CDC concluded that any potential risk from vaccination was likely outweighed by the potential benefits and continued to recommend the use of these agents in all patients 12 years of age and older.⁹

There is considerable debate regarding a potential causal relationship between vaccinations and cases of myocarditis. Various potential mechanisms including hypersensitivity to vaccine components, inflammatory reaction, or inappropriate activation of the immune system have been proposed, yet given the relative rarity of these cases it is difficult to establish a true causal relationship.¹⁰

Clinically the key to identifying these cases is to have a high index of suspicion in any patient who presents with acute symptoms after a COVID-19 vaccination. Patients with concerns for AM typically present to the ED for chest pain, fatigue, dyspnea, syncope, or palpitations. Reportedly chest pain is the most frequent symptom at 85–95%, dyspnea at 19% to 49%, and syncope at 6%. Fever can accompany these symptoms in 65% of patients. The data are mixed regarding a viral

prodrome with some reports as low as 18% and as high as 80%. Notably in our cases the patients had no symptoms prior to receiving their vaccinations.

ECG is abnormal in ~85% of cases. ST elevation is most common, with increased involvement of inferior leads. There can be QRS widening indicating conduction system dysfunction, atrioventricular blocks, unexplained sinus tachycardia, ventricular dysrhythmias, or symptomatic bradycardia.¹¹

Formal guidelines use criteria, such as cardiac magnetic resonance imaging findings and biopsy results to confirm the diagnosis of myocarditis. Although these tests are not available in most EDs, labs including troponin, brain natriuretic peptide, erythrocyte sedimentation rate, C-reactive protein, and cardiac antibodies are often abnormal and, when coupled with a concerning clinical presentation, can be used to make a presumptive diagnosis.

In cases of possible vaccine related myocarditis the mainstay of management is supportive care including dysrhythmia management and treatment of heart failure when present. Steroids and intravenous immunoglobulin are often used to modulate a potential immune response, yet there is little evidence to support their routine use. Salicylates and nonsteroidal anti-inflammatory drugs are the mainstay of treatment in acute pericarditis, but there has been some question of its use in myocarditis as there is concern for a potential increase in adverse events.¹²

As the distribution of COVID-19 vaccines increases, there are a growing number of cases after patients received a novel mRNA vaccine. Although the current body of evidence is sparse, the majority of cases seem to occur in otherwise healthy young men most often after their second vaccination. Although the majority of reported cases are coming from the lay press as the number of reports increases there is growing concern for at least an association between COVID-19 vaccination and subsequent myocarditis. While we wait for more data clinicians should have a high suspicion for these potential complications in any patient who presents with cardiopulmonary symptoms after COVID-19 vaccination.

CONFLICT OF INTEREST

The authors report no conflict of interest.

REFERENCES

1. Kuntz J, Crane B, Weinmann S, Naleway AL, Vaccine safety datalink investigator team. Myocarditis and pericarditis are rare following live viral vaccinations in adults. *Vaccine*. 2018;36(12):1524-1527.
2. Engler RJ, Nelson MR, Collins LC, et al. A prospective study of the incidence of myocarditis/pericarditis and new onset cardiac symptoms following smallpox and influenza vaccination. *PLoS One*. 2015; 10(3): e0118283.
3. Mei R, Raschi E, Forcesi E, Diemberger I, De Ponti F, Poluzzi E. Myocarditis and pericarditis after immunization: gaining insights through the vaccine adverse event reporting system. *Int J Cardiol*. 2018; 273: 183-186.
4. Jaffe-Hoffman M. 19-year-old hospitalized in ICU days after receiving second Pfizer vaccine. *Jerusalem Post*. 2021. <https://www.jpost.com/health-science/19-year-old-hospitalized-with-heart-inflammation-after-pfizer-vaccination-657428>

5. Odenheimer A. Israel examines heart inflammation cases after Pfizer shot. Bloomberg. 2021. <https://www.bloombergquint.com/onweb/israel-examines-heart-inflammation-cases-after-pfizer-covid-shot>
6. Kime P. Pentagon tracking 14 cases of heart inflammation in troops after COVID-19 shots. Military News. 2021. <https://www.military.com/daily-news/2021/04/26/pentagon-tracking-14-cases-of-heart-inflammation-troops-after-covid-19-shots.html>
7. Israel sees probable link between Pfizer-BioNTech vaccine and myocarditis cases. CBC. 2021. <https://www.cbc.ca/news/health/israel-pfizer-myocarditis-1.6049766>
8. Israeli Ministry of Health. Surveillance of myocarditis (inflammation of the heart muscle) cases between December 2020 and May 2021. 2021. <https://www.gov.il/en/departments/news/01062021-03>
9. Centers for Disease Control and Prevention. Clinical Considerations: Myocarditis and Pericarditis after Receipt of mRNA COVID-19 Vaccines Among Adolescents and Young Adults. 2021. <https://www.cdc.gov/vaccines/covid-19/clinical-considerations/myocarditis.html>
10. Kim YJ, Bae JI, Ryoo SM, et al. Acute fulminant myocarditis following influenza vaccination requiring extracorporeal membrane oxygenation. *Acute Crit Care*. 2019;34(2):165-169. [10.4266/acc.2017.00045](https://doi.org/10.4266/acc.2017.00045).
11. Buttà C, Zappia L, Laterra G, Roberto M. Diagnostic and prognostic role of electrocardiogram in acute myocarditis: a comprehensive review. *Ann Noninvasive Electrocardiol*. 2020; 25: e12726.
12. Kociol RD, Cooper LT, Fang JC, et al. American Heart Association Heart Failure and Transplantation Committee of the Council on Clinical Cardiology. Recognition and Initial Management of Fulminant Myocarditis: a Scientific Statement From the American Heart Association. *Circulation*. 2020; 141(6): e69-e92.

How to cite this article: Hudson B, Mantooth R, DeLaney M. Myocarditis and pericarditis after vaccination for COVID-19. *JACEP Open*. 2021;2:e12498. <https://doi.org/10.1002/emp2.12498>