

# Continuous quadratus lumborum block as post-operative strategy for pain control in spinal fusion surgery

## Address for correspondence:

Dr. Jon Wilton,  
Department of Anaesthesia,  
Dignity Health Mercy  
Medical Center Mt. Shasta,  
914 Pine St., Mount Shasta,  
CA 96067, USA.  
E-mail: jon.wilton@  
dignityhealth.org

**Submitted:** 04-May-2020

**Revised:** 05-Jun-2020

**Accepted:** 12-Jul-2020

**Published:** 01-Oct-2020

**Jon Wilton, Helen Chiu<sup>1</sup>, Natalie Codianne<sup>2</sup>, Herschel Knapp<sup>3</sup>,  
Vicente Roques Escolar<sup>4</sup>, Shari Burns<sup>5</sup>**

Departments of Anaesthesia and <sup>2</sup>Pharmacy, Dignity Health Mercy Medical Center Mt. Shasta, Mount Shasta, <sup>1</sup>Department of Pharmacy, Dignity Health Mercy Medical Center Redding, Redding, <sup>3</sup>Department of Clinical Informatics, Dignity Health Southern California Regional Office, CA, <sup>5</sup>Department of Nurse Anaesthesia, College of Health Sciences, Midwestern University, Glendale, AZ, USA, <sup>4</sup>Department of Anaesthesia and Intensive Care Medicine, Arrixaca University Clinical Hospital, Murcia, Spain

## ABSTRACT

**Background and Aims:** Lumbar spinal fusions have post-operative pain levels that can be difficult to treat. The objective of this study was to determine if using bilateral quadratus lumborum (QL) nerve block catheters for lumbar fusions changes the patient's post-operative recovery experience by reducing opioid consumption, thereby limiting potential risks and side effects and reducing recovery time. **Methods:** There were a total of 52 surgical lumbar fusion patients in this single-center, retrospective cohort review. In control Group A, there were 26 patients who received opioid regimens. In control Group B, there were 26 patients who received bilateral QL block catheters with breakthrough opioid regimens. Forty-eight hour post-operative opioid use in oral morphine milligram equivalents (MME) and length of stay (LOS) from the post-anaesthesia care unit to hospital discharge were examined. **Results:** Group A had a mean MME of  $307.62 \pm 305.37$  mg. Group B had a statistically significant lower mean total MME of  $133.78 \pm 152.66$  mg ( $P = 0.012$ ,  $\alpha = 0.05$ ). On an average, Group A required 2.3 times the MMEs than Group B. Group A had a mean LOS of  $2.34 \pm 1.87$  days, whereas Group B had a lower mean LOS of  $1.98 \pm 0.51$  days. This difference of 0.36 days was not statistically significant ( $P = 0.522$ ,  $\alpha = 0.05$ ). **Conclusion:** Surgical lumbar fusion patients who received the QL block catheter had a lower opioid requirement compared to standard opioid regimens. The study was underpowered to detect a difference in LOS.

**Key words:** Anaesthetics, analgesics, morphine milligram equivalent, nerve block, opioid, acute pain, pain, post-operative, spinal fusion

## Access this article online

Website: [www.ijaweb.org](http://www.ijaweb.org)

DOI: [10.4103/ijja.JJA\\_476\\_20](https://doi.org/10.4103/ijja.JJA_476_20)

Quick response code



## INTRODUCTION

Conventionally, spinal surgeries, including lumbar fusions, have extensively relied on opioid therapies for pain treatment. This reliance contributes to a patient population that is increasingly dependent on opiates.<sup>[1,2]</sup> Anaesthesia providers must explore alternative methods of pain control to mitigate the adverse side effects and risks associated with current methods.<sup>[3,4]</sup> The intent of this study was to show that continuous quadratus lumborum (QL) blocks can reduce opioid consumption and control post-operative pain in spinal fusion surgery.

Recently, surgical services across the spectrum have been transitioning to 'Enhanced Recovery After Surgery' protocols to improve outcomes. These protocols emphasise opioid reduction and utilising

This is an open access journal, and articles are distributed under the terms of the Creative Commons Attribution-NonCommercial-ShareAlike 4.0 License, which allows others to remix, tweak, and build upon the work non-commercially, as long as appropriate credit is given and the new creations are licensed under the identical terms.

**For reprints contact:** [reprints@medknow.com](mailto:reprints@medknow.com)

**How to cite this article:** Wilton J, Chiu H, Codianne N, Knapp H, Escolar VR, Burns S. Continuous quadratus lumborum block as post-operative strategy for pain control in spinal fusion surgery. *Indian J Anaesth* 2020;64:869-73.

alternatives for treating pain.<sup>[5]</sup> Adjuncts such as lidocaine infusions, ketamine infusions, magnesium sulphate infusions, non-steroidal anti-inflammatory drugs (NSAIDs), acetaminophen and diazepam have all been utilised with various levels of success as non-opioid alternatives for post-lumbar fusion surgical pain.<sup>[6]</sup> Unfortunately, many infusions cannot routinely be maintained past the time spent in the post-anaesthesia care unit (PACU). Patient comorbidities may preclude the use of NSAIDs and acetaminophen's maximum dose threshold often requires additional pain control options. Alternatives such as diazepam have an extremely long half-life with their own set of deleterious side effects. These issues result in the majority of practitioners still relying on opiates as the primary treatment modality for post-operative spinal surgery pain.

Truncal and fascial plane blocks are a relatively new treatment modality.<sup>[7,8]</sup> During July of 2017, the authors placed QL catheters for a two-stage anterior and posterior lumbar fusion. The entire opioid load until discharge was 5 mg of oxycodone and 100 µg of fentanyl. Since then, QL catheters or single-shot blocks have been utilised by the authors' facility for every major lumbar spine surgery.

While there are documented case studies and the authors' experience, there are still limited data demonstrating the effectiveness of QL blocks. Based on the authors' personal experiences, the QL block for spine surgery is preferred for multiple reasons. QL catheters are kept further away from the surgical site, resulting in less local spread to the surgical field, which can be problematic with surgical site drains. This lack of spread is also beneficial secondary to potentially less risk of infection, less chance of liability with any post-operative neurological deficits and surgeon preference.

## METHODS

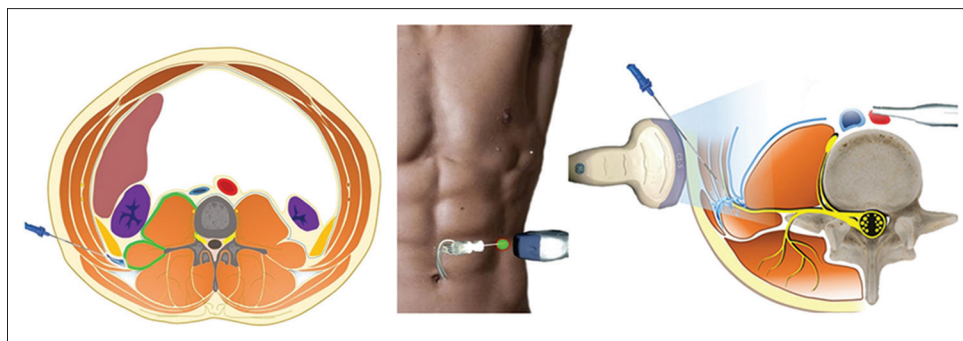
After an explanation was given, the patients demonstrated verbal and written agreement to receive this technique. For efficiency, depending on body habitus, positioning was achieved with supine or, at most, a slight lateral displacement. This position allows the patient to be prepped, draped and catheters placed bilaterally with minimal effort and time. Standard monitoring, including electrocardiography, pulse oximetry and blood pressure monitors were applied and recorded throughout the procedure. Each

patient received anxiolytics as requested, but the ability to verbalise was maintained throughout the procedure. The lateral abdominal wall was prepped with chlorhexidine antiseptic. Sterile technique and appropriate personal protective equipment were utilised. This included using a mask, sterile gloves, probe cover, gel and sterile drapes covering the area surrounding the target area.

For each case, the Quik-bloc (Avanos, Alpharetta, Georgia) over-the-needle catheter system was used almost exclusively. These catheters were all placed through ultrasound guidance using a 2–5 MHz 5C2 curvilinear probe (3300 Terason, Burlington, MA, USA).

For the QL approach, the sterile probe is placed in a transverse view at the triangle of Petit between the iliac crest and the costal margin where the transabdominal muscle is identified [Figures 1 and 2]. The transducer is then slid posterior until the transabdominal muscle posterior aponeurosis is identified adjacent to the QL muscle and the middle thoracolumbar fascia.<sup>[7,8]</sup> The projected needle path is injected with 1% lidocaine via a 25G 1.5-inch needle. The catheter over the needle system is then inserted anterior to probe and advanced in-plane until the needle tip is visualised between the middle thoracolumbar fascia and the QL muscle.<sup>[9]</sup> The local anaesthetic mixture is then injected in this plane with confirmation by visualising hydrodissection and local spread. Once this space is dilated, the catheter and needle are then advanced into the local anaesthetic pocket and needle is withdrawn. The process is repeated on the contralateral side to achieve a bilateral block.

In this study, the standard technique for the local anaesthetic mixture involved calculating the maximum dose of local anaesthetic and injecting half the dose into each of the two catheters.<sup>[10]</sup> For each block, the local anaesthetic was then diluted with normal saline to a volume of 40 ml for each side.<sup>[11]</sup> This was based on research and the authors' personal experience with previously utilised transabdominal plane blocks. During the patient's PACU stay, a patient rate controlled OnQ elastomeric pump (Avanos, Alpharetta, Georgia) was instituted, one for each catheter. An average basal rate for infusion into each catheter was initiated at 2–4 mL/h. The rate was then titrated based on response up to 14 mL/h, and the pumps continued infusing until empty. This was limited to 5 days or less.



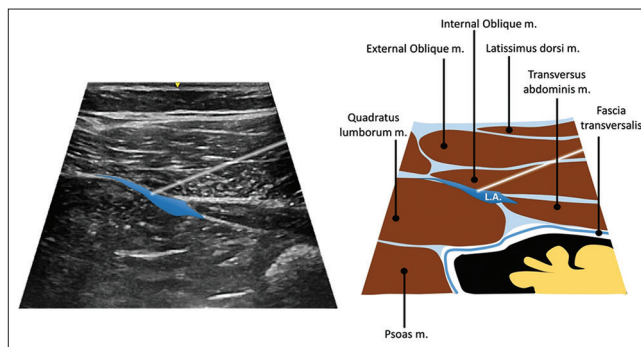
**Figure 1:** Diagram of transducer placement for quadratus lumborum nerve block

The study was conducted at a critical access hospital in northern California, United States and was approved by an Institutional Review Board. Patient consent was deemed unnecessary.

Two groups were included in the study. Group A included patients undergoing lumbar fusion without continuous catheter local anaesthetic infusion and traditional opioid treatment regimens. The number of Group A participants was matched retrospectively to match the sample size of Group B. Group A included cases before July of 2017. Group B consisted of patients undergoing lumbar fusions with QL Block catheters and local anaesthetic infusions. This group consisted of all spinal fusions that consented to QL catheters since July of 2017. A total of 52 patients were reviewed, 26 in each group [Table 1]. The patient's length of stay (LOS) and the morphine milligram equivalents (MMEs) in the first 48 h were examined. Exclusion criteria were patients <18 years of age and illicit drug use.

The data were collected from the patient's pre-anaesthesia record, anaesthesia record and medication administration electronic medical records (Cerner, Kansas City, MO, USA).

The study size was limited by the available number of lumbar fusion cases where catheters had been utilised; we examined 26 patient records for each of the two groups (Group A and Group B) for a total sample size of 52. The reviewed records were from patient procedures occurring between July 2015 and March 2019. Mean MMEs and length of hospital stay were calculated using the Mann-Whitney U-test using the traditional  $\alpha = 0.05$  cut-off value to determine (*P*) statistical significance. To achieve 80% power, it was calculated that a sample size of 45 was needed in each group to detect a difference in the primary endpoint of mean MMEs.



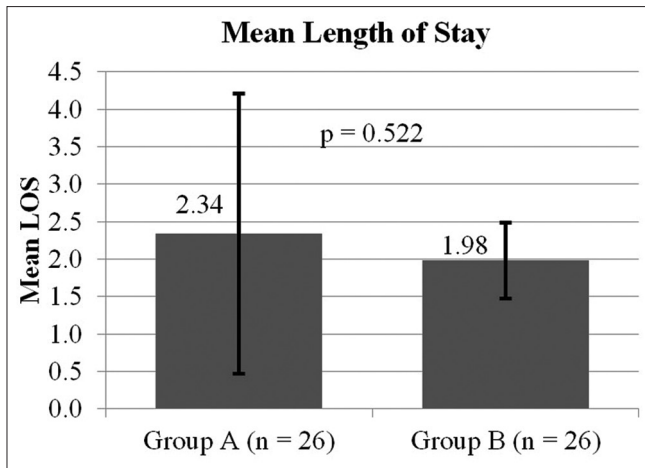
**Figure 2:** Sonographic anatomy

Table 1: Patient demographics (n=52)			
Characteristic	Group A	Group B	P
Mean age (years), range	66.4 (43-81)	66.8 (38-87)	0.88
Male, n (%)	16 (62)	12 (46)	0.21

**RESULTS**

LOS and oral MMEs were gathered for the 52 patients: 26 that were not catheterised and 26 that were catheterised. LOS produced a substantial positive skew among the patients who were not catheterised, whereas those who were catheterised had a normal distribution. As such, the Mann-Whitney U test– the non-parametric equivalent of the *t*-test was utilised. Non-catheterised patients had a mean LOS of 2.34 (standard deviation [SD] = 1.87) days, whereas catheterised patients had a mean LOS of 1.98 (SD = 0.51) days [Figure 3]. Although patients who were catheterised had a lower mean LOS than those who were not, this difference of 0.36 days was not statistically significant (*P* = 0.522,  $\alpha = 0.05$ ). However, the sample size was underpowered to detect a difference due to the limited number of cases available for review. Interestingly, the SD in Group B was much smaller (0.51) compared to the large SD of 1.87 in Group A.

Initial analysis of the MME variable revealed a substantial positive skew for each of the two groups.

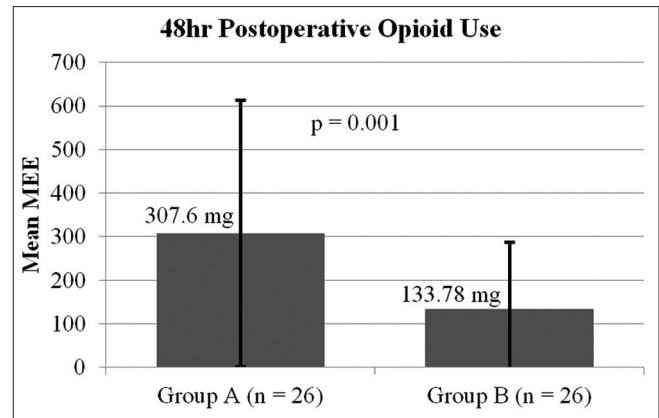


**Figure 3:** Mean length of stay after lumbar fusion in patients without quadratus lumborum catheters (Group A) compared to patients with quadratus lumborum catheters (Group B). LOS – Length of stay in days

Again, the Mann–Whitney U-test was selected. Non-catheterised patients had a mean MME of  $307.62 \pm 305.37$  mg, whereas catheterised patients had a mean MME of  $133.78 \pm 152.66$  mg [Figure 4]. Patients who were catheterised required a statistically significantly lower mean dosage compared to those who were not catheterised ( $P = 0.001$ ,  $\alpha = 0.05$ ). On an average, non-catheterised patients required >2.3 times more opioid pain medication than those who were catheterised.

## DISCUSSION

Internationally, there has been an increased interest in implementing the use of regional anaesthesia for spine surgery and acute pain. However, the associated research is limited to case studies. Examples of these include: QL block,<sup>[12,13]</sup> retrolaminar block,<sup>[14,15]</sup> erector spinae block,<sup>[16-24]</sup> and thoracolumbar interfascial plane block.<sup>[25-28]</sup> The use of regional anaesthesia for spine surgery is new; therefore, little research exists about the optimal block and/or volume. A case series of three patients receiving continuous erector spinae blocks for lumbar spine surgery reported that rescue analgesia with opioids was only needed within the 1<sup>st</sup> h post-operatively.<sup>[29]</sup> The patients in this case series also received 2 mcg/kg of fentanyl intraoperatively, and the local anaesthetic infusion was not titrated to patient response. The current retrospective study is unique in that no opioid analgesia was given intraoperatively and the patients with a QL block had a >50% reduction in post-operative opioid requirements. In addition, the ability to titrate the local anaesthetic infusion between 2 and 14 ml/h provided an option to increase the dose before



**Figure 4:** Mean opioid use 48 h after lumbar fusion in patients without quadratus lumborum catheters (Group A) compared to patients with quadratus lumborum catheters (Group B). MME – Morphine milligram equivalents

moving to opioid rescue therapy for breakthrough pain.

Despite this evidence, the adoption of these techniques is rare and further research is needed. Specifically, the optimal block performed for each specific procedure and the optimum local anaesthetic choice, volume and total dose will need to be researched and evaluated. To date, there have only been case reports published using the QL technique for lumbar fusion.<sup>[9,10]</sup> In the case reports 20 mL of local anaesthetic was used for each side of the block compared to the 40 mL used in this study.

The current study is the first statistical analysis comparing QL blocks with the standard of care. As a pilot study, this analysis will potentially help legitimise QL blocks as a regional anaesthesia treatment modality useful for the treatment of pain associated with lumbar fusions. This study was limited by its retrospective design and small sample size. Future studies at facilities with more resources may consider factoring in pain scores, baseline home opioid consumption, potential complications and number of levels fused.

Other considerations when using the QL catheter technique include barriers to adoption due to the time required in developing the skill and surgeon acceptance of these techniques. There is also an additional workload involved as use requires daily rounding and maintenance of the catheter. Potential concerns with the QL catheter technique are risk of infection, potential for local anaesthetic in the surgical drains, toxicity, tachyphylaxis and timing of dosing when utilising neuromonitoring. In this study, there was no incidence of catheter site infection or toxicity.

## CONCLUSION

This study demonstrates a significantly lower opiate consumption when lumbar fusions are performed using the QL block catheter compared to the standard opioid regimens. The study was underpowered to detect a difference in LOS, but results indicate a trend towards shorter LOSs with the QL block. On discovery of QL block effectiveness in the setting of lumbar fusions, this modality became and remains the standard of care at the study facility. Further studies in a prospective randomised control design with a larger sample size are warranted.

## Financial support and sponsorship

Nil.

## Conflicts of interest

There are no conflicts of interest.

## REFERENCES

1. Brummett CM, Waljee JF, Goesling J, Moser S, Lin P, Englesbe MJ, et al. New persistent opioid use after minor and major surgical procedures in US adults. *JAMA Surg* 2017;152:17. Available from: <https://www.ncbi.nlm.nih.gov/pmc/articles/PMC7050825/pdf/nihms-1063980.pdf>. [Last accessed on 2019 Jan 16].
2. Dunn LK, Durieux ME, Nemergut EC, Naik BI. Surgery-induced opioid dependence: Adding fuel to the fire? *Anesth Analg* 2017;125:1806-8.
3. Hurley R. US surgeon general: Doctors have central role in solving opioid epidemic. *BMJ* 2017;356:3. Available from: <https://www.bmj.com/content/bmj/356/bmj.j715.full.pdf>. [Last accessed on 2019 Jan 16].
4. Koepke EJ, Manning EL, Miller TE, Ganesh A, Williams DGA, Manning MW. The rising tide of opioid use and abuse: The role of the anesthesiologist. *Perioper Med (Lond)* 2018;7:16.
5. Gopinath R, Dhanalakshmi SK, Tejavath K, Venu P. Pain relief is not optional – Choose wisely. *Indian J Anaesth* 2020;64:453-5.
6. Singh K, Bohl DD, Ahn J, Massel DH, Mayo BC, Narain AS, et al. Multimodal analgesia versus intravenous patient-controlled analgesia for minimally invasive transforaminal lumbar interbody fusion procedures. *Spine (Phila Pa 1976)* 2017;42:1145-50.
7. Chakraborty A, Khemka R, Datta T. Ultrasound-guided truncal blocks: A new frontier in regional anaesthesia. *Indian J Anaesth* 2016;60:703-11.
8. Elsharkawy H, El-Boghdady K, Barrington M. Quadratus lumborum block: Anatomical concepts, mechanisms, and techniques. *Anesthesiology* 2019;130:322-35.
9. Serifsoy TE, Tulgar S, Selvi O, Senturk O, Ilter E, Peker BH, et al. Evaluation of ultrasound-guided transversalis fascia plane block for postoperative analgesia in cesarean section: A prospective, randomized, controlled clinical trial. *J Clin Anesth* 2020;59:56-60.
10. Williams DJ, Walker JD. A nomogram for calculating the maximum dose of local anaesthetic. *Anaesthesia* 2014;69:847-53.
11. Urigel S, Molter J. AANA Journal course: Update for nurse anesthetists: Transversus abdominis plane (TAP) Bblocks. *AANA J* 2014;82:73-9.
12. Iwamitsu R, Ueshima H, Otake H. Intermittent bilateral posterior quadratus lumborum block was effective for pain management in lumbar spinal fusion. *J Clin Anesth* 2017;42:16.
13. Ueshima H, Hiroshi O. Lumbar vertebra surgery performed with a bilateral posterior quadratus lumborum block. *J Clin Anesth* 2017;41:61.
14. Ueshima H, Hara E, Otake H. Lumbar vertebra surgery performed with a bilateral retrolaminar block. *J Clin Anesth* 2017;37:114.
15. Onishi E, Toda N, Kameyama Y, Yamauchi M. Comparison of clinical efficacy and anatomical investigation between retrolaminar block and erector spinae plane block. *Biomed Res Int* 2019;2019:8. Available from: <http://downloads.hindawi.com/journals/bmri/2019/2578396.pdf>. [Last accessed on 2019 May 20].
16. Almeida CR, Oliveira AR, Cunha P. Continuous bilateral erector of spine plane block at T8 for extensive lumbar spine fusion surgery: Case report. *Pain Pract* 2019;19:536-40.
17. Chin KJ, Lewis S. Opioid-free analgesia for posterior spinal fusion surgery using erector spinae plane (ESP) blocks in a multimodal anesthetic regimen. *Spine (Phila Pa 1976)* 2019;44:E379-83.
18. Melvin JP, Schrot RJ, Chu GM, Chin KJ. Low thoracic erector spinae plane block for perioperative analgesia in lumbosacral spine surgery: A case series. *Can J Anaesth* 2018;65:1057-65.
19. Kline J, Chin KJ. Modified dual-injection lumbar erector spine plane (ESP) block for opioid-free anesthesia in multilevel lumbar laminectomy. *Korean J Anesthesiol* 2019;72:188-90.
20. Cesur S, Yayik AM, Ozturk F, Ahiskalioglu A. Ultrasound-guided low thoracic erector spinae plane block for effective postoperative analgesia after lumbar surgery: Report of five cases. *Cureus* 2018;10:5. Available from: <https://www.ncbi.nlm.nih.gov/pmc/articles/PMC6338404/pdf/cureus-0010-00000003603.pdf>. [Last accessed on 2019 Jan 16].
21. Singh S, Chaudhary NK. Bilateral ultrasound guided erector spinae plane block for postoperative pain management in lumbar spine surgery: A case series. *J Neurosurg Anesthesiol* 2019;31:354.
22. Ueshima H, Inagaki M, Toyone T, Otake H. Efficacy of the erector spinae plane block for lumbar spinal surgery: A retrospective study. *Asian Spine J* 2019;13:254-7.
23. Yayik AM, Cesur S, Ozturk F, Ahiskalioglu A, Ay AN, Celik EC, et al. Postoperative analgesic efficacy of the ultrasound-guided erector spinae plane block in patients undergoing lumbar spinal decompression surgery: A randomized controlled study. *World Neurosurg* 2019;126:e779-85.
24. Ueshima H, Otake H. Clinical experiences of ultrasound-guided erector spinae plane block for thoracic vertebra surgery. *J Clin Anesth* 2017;38:137.
25. Christopher S, Gopal TV, Vardhan V. Thoracolumbar interfascial plane block, way forward for awake endoscopic laminectomies. *Indian J Anaesth* 2020;64:436-7.
26. Hand WR, Taylor JM, Harvey NR, Epperson TI, Gonselman RJ, Bolin ED, et al. Thoracolumbar interfascial plane (TLIP) block: A pilot study in volunteers. *Can J Anaesth* 2015;62:1196-200.
27. Kumar A, Sinha C, Kumar A, Bhadani UK. Ultrasound-guided thoracolumbar interfascial plane block for spine surgery. *Saudi J Anaesth* 2017;11:248-9.
28. Ueshima H, Otake H. Clinical efficacy of modified thoracolumbar interfascial plane block. *J Clin Anesth* 2016;30:74-5.
29. Chaudhary NK, Singh S. Continuous ultrasound-guided erector spinae plane block for post-operative pain management in lumbar spine surgery: A case series. *Indian J Anaesth* 2018;62:638-9.