

# Roles of osteopontin and matrix metalloproteinase-7 in occurrence, progression, and prognosis of nonsmall cell lung cancer

Ying Sun, Dan Li, Xiao-Hong Lv, Shu-Cheng Hua, Ji-Chang Han, Feng Xu, Xian-Dong Li

Department of Respiratory Medicine, The First Hospital of Jilin University, Changchun, China

**Background:** This study detected osteopontin (OPN) and matrix metalloproteinase-7 (MMP-7) expressions to explore the roles of OPN and MMP-7 in the occurrence, progression, and prognosis of nonsmall cell lung cancer (NSCLC). **Materials and Methods:** A retrospective study was conducted on NSCLC tissues ( $n = 152$ ; case group) and adjacent nonneoplastic lung parenchyma (adjacent to tumor  $>5$  cm;  $n = 152$ ; control group) collected from 152 NSCLC patients. The protein expressions of OPN and MMP-7 were detected by immunohistochemistry. OPN and MMP-7 messenger RNA (mRNA) expressions were detected by reverse transcription polymerase chain reaction (RT-PCR). **Results:** The protein and mRNA expressions of OPN and MMP-7 in NSCLC tissues were evidently higher than those in adjacent nonneoplastic lung parenchyma (all  $P < 0.05$ ). OPN protein and mRNA expression were associated with the degree of differentiation, tumor node metastasis (TNM) staging, and lymph node metastasis in NSCLC (all  $P < 0.05$ ). MMP-7 protein expression was associated with TNM staging and lymph node metastasis (both  $P < 0.05$ ) while MMP-7 mRNA expression was associated with the degree of differentiation, TNM staging, and lymph node metastasis (all  $P < 0.05$ ). A significantly positive relativity was revealed between OPN expression and MMP-7 expression (protein:  $r = 0.789$ ,  $P < 0.001$ ; mRNA:  $r = 0.377$ ,  $P < 0.001$ ). Lymph node metastasis, TNM staging, OPN, and MMP-7 protein expressions were independent risk factors for the prognosis of NSCLC (all  $P < 0.05$ ). **Conclusion:** High MMP-7 and OPN protein expressions are closely related to the occurrence, progression, and prognosis of NSCLC, and can be served as unfavorable prognostic factors for NSCLC.

**Key words:** Lymph node metastasis, matrix metalloproteinase-7 (MMP-7), nonsmall cell lung cancer (NSCLC), osteopontin (OPN), prognosis, tumor node metastasis (TNM) staging

**How to cite this article:** Sun Y, Li D, Lv XH, Hua SC, Han JC, Xu F, Li XD. Roles of osteopontin and matrix metalloproteinase-7 in occurrence, progression, and prognosis of nonsmall cell lung cancer. J Res Med Sci 2015;20:1138-46.

## INTRODUCTION

Lung cancer, the most common type of cancer, is a leading cause of cancer-related deaths for both males and females worldwide.<sup>[1]</sup> A total of 226,200 new cases (116,500 in men and 109,700 in women) of lung cancers are diagnosed in 2012, and 160,300 deaths (87,700 in men and 72,600 in women) are estimated to occur from the disease.<sup>[2]</sup> Nonsmall cell lung cancer (NSCLC), any type of epithelial lung cancer other than small-cell lung carcinoma (SCLC), is reported to account for nearly 85% of all lung cancer cases.<sup>[3]</sup> Common symptoms of NSCLC involve hemoptysis, chest pain, low fever, cough,

fatigue, weight loss, anorexia, dyspnea, and emptytysis.<sup>[4]</sup> Among NSCLC patients, complete surgical resection of primary tumors in the early stage is the unique possible clinical treatment.<sup>[5]</sup> Although the detection and surgical and medical treatments for NSCLC have improved, the clinical behavior of NSCLC remains bad, with an unsatisfactory overall 5-year survival rate of only 17%, and approximately 65-75% of NSCLC patients possess unresectable advanced or metastatic disease at diagnosis.<sup>[6]</sup> One new area of research in early-stage NSCLC is identifying molecular markers tumor node metastasis (TNM) staging to completely evaluate the prognosis of NSCLC patients and to define novel strategies.<sup>[7]</sup> Numerous novel prognostic factors,

This is an open access article distributed under the terms of the Creative Commons Attribution-NonCommercial-ShareAlike 3.0 License, which allows others to remix, tweak, and build upon the work non-commercially, as long as the author is credited and the new creations are licensed under the identical terms.

**For reprints contact:** reprints@medknow.com

Access this article online	
Quick Response Code: 	Website: www.jmsjournal.net
	DOI: 10.4103/1735-1995.172980

**Address for correspondence:** Dr. Shu-Cheng Hua, Department of Respiratory Medicine, The First Hospital of Jilin University, Xinmin Street No. 71, Chaoyang, Changchun - 130 021, China. E-mail: shuchenghua@eyou.com

**Received:** 11-04-2015; **Revised:** 17-06-2015; **Accepted:** 28-11-2015

such as osteopontin (OPN) and matrix metalloproteinase-7 (MMP-7), have been identified in NSCLC patients that may provide potential therapeutic targets for NSCLC, which are certainly warranted.<sup>[8]</sup>

OPN, as a phosphorylated acidic glycoprotein, is defined to be both a multifunctional cytokine and an adhesion protein secreted by a variety of cells.<sup>[9]</sup> Through interactions with its receptors, integrins ( $\alpha 4, \alpha 5, \alpha 8, \alpha 9$ ) $\beta 1, \alpha v$ ( $\beta 1, \beta 3, \beta 5$ ), and CD44 variants, OPN is recognized to participate in a wide range of physiologic and pathologic processes, consisting of cell-mediated immunity, tissue repair, cellular migration, and remodeling.<sup>[10,11]</sup> In addition, OPN has been reported to be correlated to development, progression, and metastasis in various malignancies such as NSCLC.<sup>[12]</sup> MMP-7, the smallest (28 kDa) member of the MMP family, is produced by tumor cells and has broad substrate specificity against extracellular matrix (ECM) components.<sup>[13]</sup> MMP-7 is found to be potentially involved in tumor metastasis and inflammatory processes, through cleaving cell surface proteins and promoting adhesion of cancer cells.<sup>[14]</sup> Previous clinical studies have shown an overexpression of MMP-7 to correlate with poor prognosis in many malignant tumors including NSCLC, indicating that MMP-7 could be useful as a tumor-associated biological marker.<sup>[15,16]</sup>

In conventional clinical studies, only one of these two indicators is detected in the body of patients with NSCLC.<sup>[15,17]</sup> In our present study, the combined determination of OPN and MMP-7 expression levels in paraffin-embedded tissues from NSCLC patients was conducted by using the immunohistochemical method and reverse transcription polymerase chain reaction (RT-PCR) to explore the roles of OPN and MMP-7 in the occurrence, progression, and prognosis of NSCLC.

## MATERIALS AND METHODS

### Study design and participants

Between January 2010 and January 2013, 152 patients (males: 108; females: 44; age range: 38~79 years; mean age:  $57.2 \pm 11.5$  years) diagnosed with NSCLC by pathologists were selected from the Department of Thoracic Surgery of the First Hospital of Jilin University. NSCLC tissues of all the patients were collected by resection as case group, and adjacent nonneoplastic lung parenchyma (adjacent to tumor > 5 cm) was also collected from the same patient population as the control group. Clinicopathological data of all the patients were complete.<sup>[18]</sup> The inclusion criteria for the NSCLC patients were:

1. Patients with primary NSCLC;
2. Patients without preoperative chemotherapy, immunotherapy, or radiotherapy;
3. Patients without administration of anti-inflammatory drugs;
4. Patients without chronic heart, liver, or kidney disease, or endocrine diseases.

Patients, who had coronary heart disease, hypertension, diabetes, cerebrovascular disease, rheumatic diseases, or NSCLC combined with other tumors were excluded.<sup>[8]</sup> There were 64 NSCLC patients with age  $\geq 60$  years and 88 patients with age <60 years. Among all patients, 81 patients were diagnosed with squamous cell carcinoma, 59 patients with adenocarcinoma, and 12 patients with other types.<sup>[12]</sup> According to the seventh edition of the TNM classification for lung cancer released by the Union for International Cancer Control (UNCC) in 2009, 48 patients were confirmed with stage I NSCLC, 27 patients with stage II NSCLC, 63 patients with stage III NSCLC, and 14 patients with stage IV NSCLC; 40 patients were confirmed with well-differentiated NSCLC, and 112 patients with moderate-to-poor differentiated NSCLC; 94 patients were confirmed with lymph node metastasis and 58 patients without lymph node metastasis.<sup>[19,20]</sup> All pathological tissues were fixed by 10% neutral-buffered formalin, embedded by paraffin, and cut into 4- $\mu$ m sections. The end of the follow-up was December 30, 2014, and the follow-up data of all the patients were complete and recorded. Prognosis of all patients was also recorded with overall survival (OS). This retrospective study was approved by the Ethics Committee of the First Hospital of Jilin University. All study participants provided written informed consent before the experiments. The experimental principles were in accordance with the Declaration of Helsinki.<sup>[21]</sup>

### Immunohistochemistry

The protein expression levels of OPN and MMP-7 were detected by using the *Streptomyces* antibiotic regulation protein-peroxidase (SP) method. The SP kit was purchased from Zhongshan Biotechnology Company (Beijing, China). The paraffin sections were baked in a 60°C oven (Fuzhou Maixin Biotechnology Co., Ltd., Fuzhou, Fujian, China) for 2 h, deparaffinized with xylene, rehydrated in descending alcohol, and then rinsed by sterile distilled water for 3-5 min. The antigen retrieval in tissue sections was performed by using a modified method of microwave antigen retrieval. The tissue sections were cooled to room temperature and washed by using phosphate buffer saline (PBS)  $3 \times 5$  min. Each tissue section was added with antihuman OPN mouse monoclonal antibody (Zhongshan Biotechnology Company, Beijing, China) and antihuman MMP-7 mouse monoclonal antibody (Fuzhou Maixin Biotechnology Co., Ltd., Fuzhou, Fujian, China). The tissue sections were incubated in a 37°C incubator (Fuzhou Maixin Biotechnology Co., Ltd., Fuzhou, Fujian, China) for 1 h, and washed by using PBS  $3 \times 5$  min. After that, biotin-labeled secondary antibody was added

to each tissue section, which was then incubated at room temperature for 30 min and washed by PBS for  $3 \times 5$  min. Then, tissue sections were stained with diaminobenzidine (DAB), counterstained with hematoxylin, dehydrated, cleared in xylene and finally mounted. PBS was used as negative control. The staining results were observed under an optical microscope and determined by a semi-quantitative method. The staining intensity was first scored as 0 for no intensity, 1 for low intensity (light yellow), 2 for moderate intensity (pale brown), and 3 for high intensity (sepia). The percentage of positive cells was then scored as: 0 for unspecific staining of positive cells, 1 for the percentage of stained positive cells  $\leq 10\%$ , 2 for the percentage of stained positive cells between 11% and 50%, 3 for the percentage of stained positive cells between 51% and 75%, and 4 for the percentage of stained positive cells  $>75\%$ .<sup>[22]</sup> The double-blind method was applied by two pathologists separately to determine the staining results.

### Reverse transcription polymerase chain reaction

Total RNA was isolated from NSCLC tissues and adjacent nonneoplastic lung parenchyma by utilizing TRIzol reagent (Invitrogen Life Technologies, Carlsbad, CA, USA) according to the manufacturer's protocol. The first-strand of cDNA was synthesized from 5  $\mu$ l total RNA by using the reverse transcription kit (RT kit, MBI Fermentas, Vilnius, Lithuania) according to the manufacturer's protocol. Polymerase reaction (PCR) reaction system (25  $\mu$ l) included: 1  $\mu$ l cDNA, 2.5 U Tap DNA polymerase (MBI Fermentas), buffer solution, 10 pmol upstream primers and 10 pmol downstream primers (10 pmol). The  $\beta$ -actin was used as the internal control. RT-PCR kit was purchased from Fermentas Company (Glen Brunie, MD, USA). PCR primers were synthesized by Shanghai Shenggong Biotechnology (Shanghai, China). The upstream primer of (OPN) was 5'-CATCTCAGAAGCAGAATCTCCTA-3', the downstream primer of OPN was 5'-GGAAGTTCCTGACTATCAATCA-3', and the size of amplified fragments of OPN was 617 bp. The upstream primer of MMP-7 was 5'-TTGGCCTACCTATAACTGG-3', the downstream primer of MMP-7 was 5'-CTGTAATATGCGGTAAGTCTC-3', and the size of amplified fragments of MMP-7 was 177 bp. The upstream primer of  $\beta$ -actin was 5'-CCTTCCTGGGCATGGAGTCCT-3', the downstream primer of  $\beta$ -actin was 5'-GGAGCAATGATCTTGATCTT-3', and the size of amplified fragments of  $\beta$ -actin was 204 bp. Reaction conditions were: Initial predenaturation at 94°C for 5 min followed by 30 cycles of denaturation at 94°C for 45 s, anneal at 55°C for 1 min, and extension at 72°C for 1 min, and a final extension at 72°C for 10 min. After 1% agarose gel electrophoresis, electrophoresis results were observed and photographed by utilizing an ultraviolet (UV) analyzer. Gray value was measured by applying a Software

Image Tool 3.0 (Freeware provided by the University of Texas Health Sciences Center, San Antonio, Tex., USA). With  $\beta$ -action as an internal control, band densities of the resulting products were quantified with Bandleader software (Magnitee, Krasnodar, Russia).

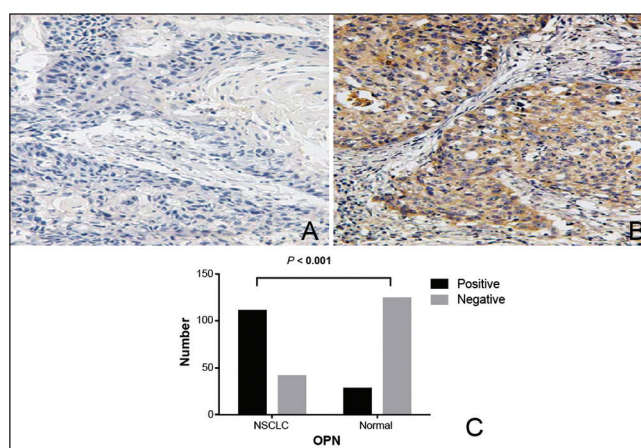
### Statistical analysis

The SPSS 17.0 software (SPSS Inc., Chicago, Illinois, USA) was applied for statistical analysis. All measurement data were presented as mean  $\pm$  standard deviation (SD) and compared by using the *t*-test. Enumeration data were presented as percentage or rate, and compared by the chi-square test. Spearman rank-correlation analysis was used to assess the correlations of OPN with MMP-7 expressions. The relationships between OPN and MMP-7 and postoperative survival period were analyzed by applying the Kaplan-Meier curve, and verified by the log-rank test. The Cox proportional hazard model was utilized for multivariate analysis of prognosis. A value of  $P < 0.05$  was considered to be statistically significant.

## RESULTS

### Protein and messenger RNA expressions of osteopontin and matrix metalloproteinase-7

OPN-positive staining was observed to be located in the cell nucleus and cytoplasm (pale brown or sepia particles). The positive expression rate of OPN protein in the NSCLC tissues was apparently higher than that in the adjacent nonneoplastic lung parenchyma (73.03% vs 18.42%,  $P < 0.001$ ) [Figure 1]. MMP-7 protein was mainly expressed in the cytoplasm in NSCLC tissues. The positive expression rate of MMP-7 protein in the NSCLC tissues was significantly higher than that in the adjacent nonneoplastic lung parenchyma (63.16% vs 23.68%,  $P < 0.001$ ) [Figure 2]. The relative messenger RNA (mRNA) expression of OPN in the



**Figure 1:** OPN protein positive expression in the NSCLC tissues by immunohistochemistry SP method ( $\times 400$ ). Note: (a) The negative expression of OPN in NSCLC tissues (b) The positive expression of OPN in NSCLC tissues (c) A histogram of OPN protein expression; SP, *Streptomyces* antibiotic regulatory protein-peroxidase; NSCLC, nonsmall cell lung cancer; OPN, osteopontin



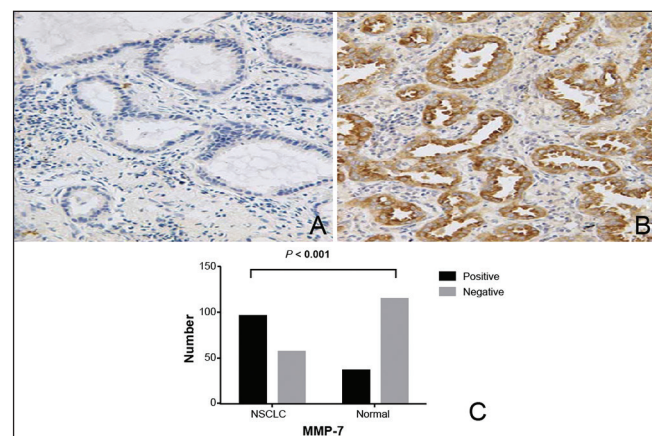
NSCLC tissues was much higher than that in the adjacent nonneoplastic lung parenchyma ( $0.69 \pm 0.22$  vs  $0.32 \pm 0.15$ ,  $P < 0.001$ ) [Figure 3a]. The relative mRNA expression of MMP-7 in the NSCLC tissues was much higher than that in the adjacent nonneoplastic lung parenchyma ( $0.61 \pm 0.27$  vs  $0.46 \pm 0.27$ ,  $P < 0.001$ ) [Figure 3b].

### Associations of osteopontin protein and messenger RNA expression with clinicopathological features in nonsmall cell lung cancer

There was no statistical significance in OPN protein expression among patients with different genders, ages, histological types, and smoking statuses (all  $P > 0.05$ ). An obvious association was detected to exist between OPN protein expression and differentiation degree, with higher positive expression rate of OPN in patients with lower degree of differentiation ( $P < 0.001$ ). The protein expression of OPN was also found to be evidently associated with the tumor TNM staging, with higher positive expression rate of OPN in late-stage NSCLC ( $P < 0.001$ ). In addition, the positive expression rate of OPN protein in patients with lymph node metastasis was higher than that in patients without lymph node metastasis ( $P < 0.01$ ). No significant association was detected between OPN mRNA expression and gender, age, smoking status, histological type, or differentiation degree (all  $P > 0.05$ ) while an apparent association between OPN mRNA expression and lymph node metastasis, differentiation degree, and TNM staging was observed (all  $P < 0.05$ ) [Table 1].

### Associations of matrix metalloproteinase-7 protein and messenger RNA expression with clinicopathologic features in nonsmall cell lung cancer

No statistical significance was detected in MMP-7 protein expression among patients with different genders, ages,

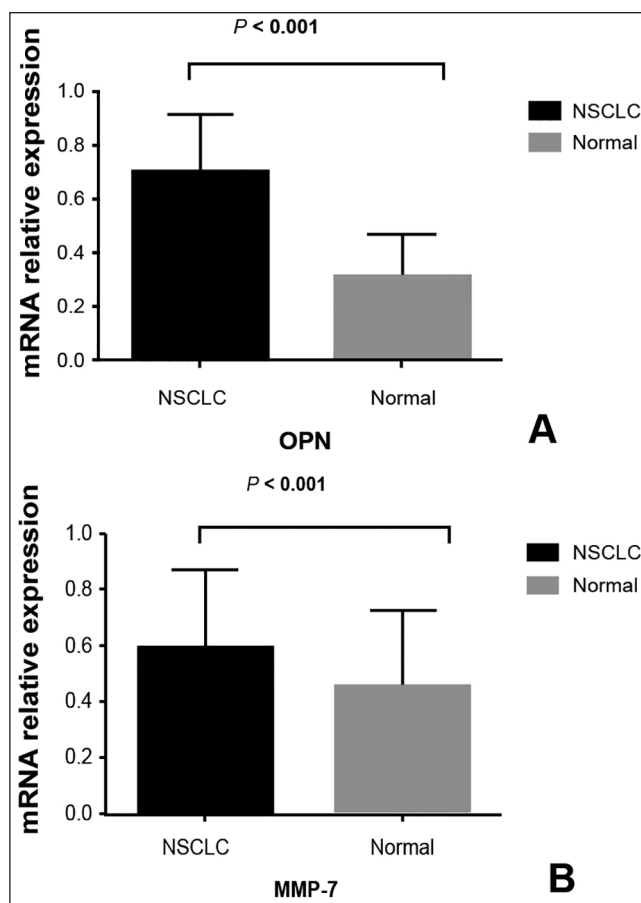


**Figure 2:** MMP-7 protein positive expression in the NSCLC tissues by immunohistochemistry SP method ( $\times 400$ ). Note: (a) The negative expression of MMP-7 in NSCLC tissues (b) The positive expression of MMP-7 in NSCLC tissues (c) A histogram of MMP-7 protein expression; SP, *Streptomyces* antibiotic regulatory protein-peroxidase; NSCLC, nonsmall cell lung cancer; MMP-7, matrix metalloproteinase-7

histological types, smoking statuses, and differentiation degrees (all  $P > 0.05$ ). It was detected that MMP-7 protein expression was apparently associated with TNM staging; to be more specific, the positive expression rate of MMP-7 protein was higher in late-stage NSCLC ( $P = 0.01$ ). Moreover, the positive expression rates of MMP-7 protein in patients with lymph node metastasis were higher than those in the patients without lymph node metastasis ( $P = 0.02$ ). No obvious association was observed between MMP-7 mRNA expression and age, gender, histological type, smoking status, or differentiation degree (all  $P > 0.05$ ) while mRNA expression of MMP-7 was apparently correlated to lymph node metastasis, differentiation degree, and TNM staging (all  $P < 0.05$ ) [Table 2].

### Correlation of osteopontin expression with matrix metalloproteinase-7 expression in NSCLC

The Spearman rank-correlation analysis was utilized to analyze the correlations of the percentage of stained OPN and MMP-7-positive cells in the 152 NSCLC tissue specimens and the mRNA expressions of OPN and MMP-7, which demonstrated a significantly positive relativity between OPN



**Figure 3:** Relative mRNA expression levels of OPN and MMP-7 in NSCLC tissues. Note: (a) Relative mRNA expression level of OPN (b) Relative mRNA expression level of MMP-7; OPN, osteopontin; MMP-7, matrix metalloproteinase-7; NSCLC, nonsmall cell lung cancer

**Table 1: Associations of OPN expression with clinicopathologic features in NSCLC**

Groups	N	OPN		P value	OPN mRNA	P value
		Positive (N)	Positive (%)			
Gender						
Male	108	82	75.93	0.21	0.70±0.21	0.80
Female	44	29	65.91		0.69±0.23	
Age						
≥60 years	64	47	73.44	0.92	0.72±0.24	0.27
<60 years	88	64	72.73		0.68±0.20	
Histological type						
Squamous cell carcinoma	81	63	77.78	0.34	0.70±0.19	0.90
Adenocarcinoma	59	40	67.80		0.69±0.25	
Other types	12	8	66.67		0.72±0.21	
Differentiation degree						
High	40	18	45.00	<0.001	0.59±0.22	<0.001
Moderate-poor	112	93	83.04		0.74±0.20	
TNM staging						
I+II	75	43	57.34	<0.001	0.62±0.21	<0.001
III+IV	77	68	88.31		0.78±0.19	
Lymph node metastasis						
Yes	94	77	81.91	0.01	0.76±0.21	<0.001
No	58	34	58.62		0.60±0.19	

TNM = Tumor node metastasis; OPN = Osteopontin; NSCLC = Non-small cell lung cancer

**Table 2: Associations of MMP-7 expression with clinicopathologic features in NSCLC**

Groups	N	MMP-7		P value	MMP-7 mRNA	P value
		Positive (N)	Positive (%)			
Gender						
Male	108	68	62.96	0.94	0.61±0.26	0.84
Female	44	28	63.64		0.60±0.32	
Age						
≥60 years	64	39	60.94	0.63	0.63±0.30	0.37
<60 years	88	57	64.77		0.59±0.25	
Histological type						
Squamous cell carcinoma	81	52	64.20	0.15	0.59±0.26	0.86
Adenocarcinoma	59	35	59.32		0.65±0.27	
Other types	12	9	75.00		0.56±0.34	
Differentiation degree						
High	40	22	55.00	0.21	0.56±0.23	0.02
Moderate-poor	112	74	66.07		0.63±0.28	
TNM staging						
I+II	75	40	53.33	0.01	0.50±0.27	<0.001
III+IV	77	56	72.73		0.71±0.24	
Lymph node metastasis						
Yes	94	66	70.21	0.02	0.70±0.26	<0.001
No	58	30	51.72		0.46±0.23	

TNM = Tumor node metastasis; MMP-7 = Matrix metalloproteinase-7; NSCLC = Non-small cell lung cancer

protein expression and MMP-7 protein expression as well as OPN mRNA expression and MMP-7 mRNA expression (protein:  $r = 0.789$ ,  $P < 0.001$ ; mRNA:  $r = 0.377$ ,  $P < 0.001$ ).

### Prognostic factors analysis

Based on a follow-up period of 5 years, the mean survival time of NSCLC patients was  $31.11 \pm 12.81$  months, and the 5-year survival rate of the patients was 24.34%. With a univariate survival analysis, the following eight

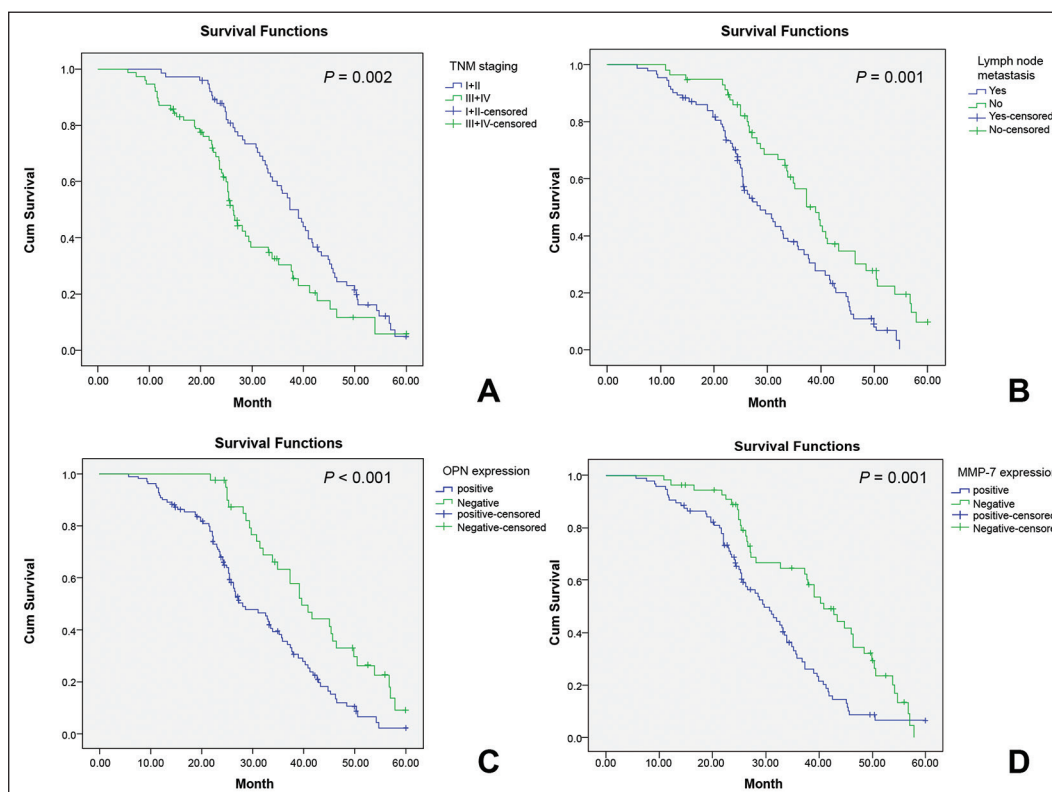
factors: Age, gender, histological type, differentiation degree, lymph node metastasis, TNM staging, OPN protein positive expression, and MMP-7 protein positive expression of the patients with NSCLC were analyzed. The results revealed that the median survival time of the patients with stage I + II NSCLC and stage III + IV NSCLC was 37.35 months and 26.25 months, respectively, and TNM staging was associated with the prognosis in patients with NSCLC ( $\chi^2 = 9.96$ ,  $P < 0.01$ ). In addition, the

median survival time of the patients with and without lymph node metastasis was 28.58 months and 39.02 months, respectively, and lymph node metastasis was associated with the prognosis in patients with NSCLC ( $\chi^2 = 11.36$ ,  $P < 0.01$ ). The median survival time of the patients with OPN protein positive and negative expression was 28.05 months and 39.65 months, respectively, and OPN protein expression was associated with the prognosis in patients with NSCLC ( $\chi^2 = 12.94$ ,  $P < 0.001$ ). The median survival time of the patients with MMP-7 protein positive expression and negative expression was 29.65 months and 40.89 months, respectively, and MMP-7 protein expression was associated with the prognosis in patients with NSCLC ( $\chi^2 = 10.39$ ,  $P < 0.01$ ) [Figure 4]. No evident association was detected among age, gender, histological type or differentiation degree, and prognosis in patients with NSCLC (all  $P > 0.05$ ) [Figure 5]. The factors, which were proven to be associated with the prognosis of NSCLC by the univariate analysis, were

further evaluated by multivariate analysis with the Cox proportional hazard model, demonstrating that lymph node metastasis, TNM staging, and OPN and MMP-7 protein expression were independent risk factors for the prognosis of NSCLC [TNM: Odds ratio (OR) = 1.536, 95% confidence interval (CI) = 1.013~2.299,  $P < 0.05$ ; lymph node metastasis: OR = 1.859, 95%CI = 1.225~2.822,  $P < 0.01$ ; OPN: OR = 1.917, 95% CI = 1.219~3.015,  $P < 0.01$ ; MMP-7: OR = 1.787, 95%CI = 1.179~2.708,  $P < 0.01$ ] [Table 3].

## DISCUSSION

In this current study, we focused on OPN and MMP-7 protein expressions assessed by immunohistochemistry and OPN and MMP-7 mRNA expressions by RT-PCR in 152 NSCLC patients. Our present results demonstrated that the protein and mRNA expressions of OPN and MMP-7 were apparently higher in NSCLC tissues as compared to the adjacent nonneoplastic lung parenchyma, suggesting

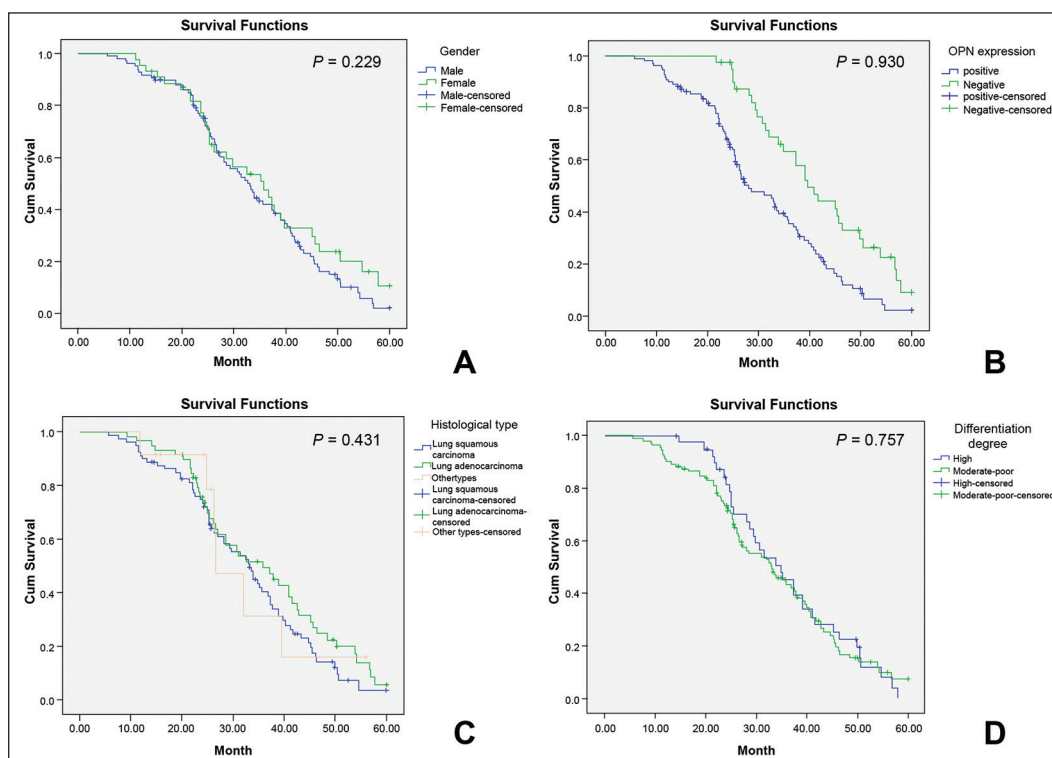


**Figure 4:** The Kaplan-Meier curves of TNM staging (a), Lymph node metastasis (b), OPN protein expression (c), And MMP-7 protein expression (d), Note: TNM = Tumor node metastasis; OPN = Osteopontin; MMP-7 = Matrix metalloproteinase-7

**Table 3: A multivariate analysis of prognostic factors**

Factors	B	SE	Wald	OR	95% CI	P value
TNM staging	0.423	0.209	4.090	1.536	1.013~2.299	<0.05
Lymph node metastasis	0.620	0.213	8.476	1.859	1.225~2.822	<0.01
OPN	0.651	0.231	7.938	1.917	1.219~3.015	<0.01
MMP-7	0.580	0.212	7.492	1.787	1.179~2.708	<0.01

TNM = Tumor node metastasis; OPN = Osteopontin; MMP-7 = Matrix metalloproteinase-7; B = Regression coefficient value; SE = Standard error; Wald = Chi-square value; OR = Odds ratio value; 95% CI = 95% confidence interval



**Figure 5:** The Kaplan-Meier curves of gender (a), Age (b), Histological type (c), And differentiation degree (d)

that OPN and MMP-7 expressions may be implicated in the carcinogenesis of NSCLC. OPN has a crucial role in tumorigenesis, progression, and metastatic dissemination in several types of human tumors including NSCLC, and our findings are consistent with previous researches on OPN expression in NSCLC.<sup>[17,23]</sup> MMP-7 protein factor, characterized by extensive substrate specificity and strong matrix degradation activity, is reported to be involved in tumor metastasis and inflammatory processes by the cleavage of cell surface proteins and promotion of cancer cells' adhesion.<sup>[24]</sup> Our results of the expression of MMP-7 are also in consistency with previous researches demonstrating a higher MMP-7 expression in NSCLC patients.<sup>[24]</sup>

In the present study, the associations of OPN and MMP-7 expressions with various clinicopathologic variables were analyzed to clarify their underlying prognostic roles. We also assessed the staining intensity, and considered a score that combines the staining intensity with their percentage of immunoreactive tumor cells as a subjective index. Regarding the association between OPN and MMP-7 expressions and clinical outcomes in the patients, we observed that the protein expression of OPN was obviously related to lymph node metastasis, the degree of differentiation, and TNM staging. To be more specific, in a patient with higher degree of differentiation, late-stage tumor, or lymph node metastasis, the lymph node metastasis was relative higher. The protein expression of MMP-7 was detected to be evidently associated with TNM staging and lymph node metastasis, with a higher

MMP-7 protein expression in patients with late-stage tumor or lymph node metastasis. As for the mRNA expressions of OPN and MMP-7, they were found to be obviously correlated to the degree of differentiation, TNM staging, and lymph node metastasis. These results implied that OPN and MMP-7 expressions may play vital roles in the progression and prognosis of NSCLC. The result that OPN expression was related to poor survival might have resulted from the multifunctionality of OPN.<sup>[25]</sup> The major functions of OPN are attributed to interacting between secreted OPN and its receptors on target cells.<sup>[26]</sup> The functions of MMP-7 include destruction of the basement membrane components, which is a crucial event in the invasion and metastasis of tumor cell.<sup>[27]</sup> Increased expression of MMP-7 in cancer cells is associated with tumor progression and metastasis in NSCLC, which has been evidenced in numerous reports.<sup>[24,28]</sup> Xiao *et al.* have reported that MMP-7 plays a role in the progression of NSCLC and has a synergistic effect on the pathogenesis, invasion, and metastasis of NSCLC, contributing to the prediction of the progression and prognosis of NSCLC.<sup>[29]</sup> Furthermore, using a Cox model, our multivariate analysis presented that lymph node metastasis, TNM staging, and the protein expression of OPN and MMP-7 were independent risk factors for the prognosis of NSCLC, which further confirmed our results showing that OPN and MMP-7 were prognostic biomarkers in NSCLC.

Moreover, it was observed that the protein and mRNA expressions of OPN were positively correlated to the protein



and mRNA expressions of MMP-7, which was closely associated with the development of NSCLC. A mechanism of action between the mentioned two biological substances was found by a comprehensive analysis of the biological functions of OPN and MMP-7: The high expression of MMP-7 protein and mRNA played an important role in promoting OPN protein and mRNA expression through the synergistic effect between them, resulting in an increase in its secretion upper limit, and promotion of the division and proliferation of lung cancer cell.<sup>[30]</sup> Meanwhile, it also stimulated tumor neovascularization, leading to invasion of NSCLC to the surrounding tissue and lymph node metastasis.<sup>[31]</sup>

## CONCLUSION

In conclusion, both high MMP-7 and OPN expressions are closely related to the occurrence, progression, and prognosis of NSCLC, serving as unfavorable prognostic factors for NSCLC. In addition, the occurrence, invasion, and metastasis of NSCLC can be predicted by detecting the protein expression levels of MMP-7 and OPN, lymph node metastasis, and TNM staging. These results have significant importance in biologically characterizing early-stage tumors and supplying new therapeutic opportunities in NSCLC.

## Acknowledgments

We would like to acknowledge the reviewers for their helpful comments on this paper.

## Financial support and sponsorship

Nil.

## Conflicts of interest

There are no conflicts of interest.

## AUTHOR'S CONTRIBUTION

YS and DL contributed in the conception of the work, XHL and SCH conducting the study, JCH revising the draft, FX approval of the final version of the manuscript, and XDL agreed for all aspects of the work.

## REFERENCES

- Zhang C, Li J, Han Y, Jiang J. A meta-analysis for CXCR4 as a prognostic marker and potential drug target in non-small cell lung cancer. *Drug Des Devel Ther* 2015;9:3267-78.
- Ettinger DS, Wood DE, Akerley W, Bazhenova LA, Borghaei H, Camidge DR, *et al.* Non-small cell lung cancer, version 1.2015. *J Natl Compr Canc Netw* 2014;12:1738-61.
- Yang YL, Luo XP, Xian L. The prognostic role of the class III  $\beta$ -tubulin in non-small cell lung cancer (NSCLC) patients receiving the taxane/vinorelbine-based chemotherapy: A meta-analysis. *PLoS One* 2014;9:e93997.
- Lu KH, Li W, Liu XH, Sun M, Zhang ML, Wu WQ, *et al.* Long non-coding RNA MEG3 inhibits NSCLC cells proliferation and induces apoptosis by affecting p53 expression. *BMC Cancer* 2013;13:461.
- Zou XL, Wang C, Liu KE, Nie W, Ding ZY. Prognostic significance of osteopontin expression in non-small-cell lung cancer: A meta-analysis. *Mol Clin Oncol* 2015;3:633-8.
- Wang Y, Gu J, Roth JA, Hildebrandt MA, Lippman SM, Ye Y, *et al.* Pathway-based serum microRNA profiling and survival in patients with advanced stage non-small cell lung cancer. *Cancer Res* 2013;73:4801-9.
- Yan CH, Lv M, Li H, Song X, Yan F, Cao S, *et al.* Osteopontin is a novel prognostic biomarker in early-stage non-small cell lung cancer after surgical resection. *J Cancer Res Clin Oncol* 2015;141:1371-8.
- Sun BS, Li Y, Zhang ZF, You J, Wang CL. Osteopontin combined with CD44v6, a novel prognostic biomarker in non-small cell lung cancer undergoing curative resection. *Ann Thorac Surg* 2013;96:1943-51.
- Takenaka M, Hanagiri T, Shinohara S, Yasuda M, Chikaishi Y, Oka S, *et al.* Serum level of osteopontin as a prognostic factor in patients who underwent surgical resection for non-small-cell lung cancer. *Clin Lung Cancer* 2013;14:288-94.
- Jiang Y, Yao M, Liu Q, Zhou C. OPN gene polymorphisms influence the risk of knee OA and OPN levels in synovial fluid in a Chinese population. *Arthritis Res Ther* 2013;15:R3.
- Ogbureke KU, Weinberger PM, Looney SW, Li L, Fisher LW. Expressions of matrix metalloproteinase-9 (MMP-9), dentin sialophosphoprotein (DSPP), and osteopontin (OPN) at histologically negative surgical margins may predict recurrence of oral squamous cell carcinoma. *Oncotarget* 2012;3:286-98.
- Jin Y, Tong DY, Tang LY, Chen JN, Zhou J, Feng ZY, *et al.* Expressions of osteopontin (OPN),  $\alpha v\beta 3$  and Pim-1 associated with poor prognosis in non-small cell lung cancer (NSCLC). *Chin J Cancer Res* 2012;24:103-8.
- Kim EJ, Lee SY, Woo MK, Choi SI, Kim TR, Kim MJ, *et al.* Fibulin-3 promoter methylation alters the invasive behavior of non-small cell lung cancer cell lines via MMP-7 and MMP-2 regulation. *Int J Oncol* 2012;40:402-8.
- Zhang J, Luo J, Ni J, Tang L, Zhang HP, Zhang L, *et al.* MMP-7 is upregulated by COX-2 and promotes proliferation and invasion of lung adenocarcinoma cells. *Eur J Histochem* 2014;58:2262.
- Stenvold H, Donnem T, Andersen S, Al-Saad S, Al-Shibli K, Busund LT, *et al.* Overexpression of matrix metalloproteinase-7 and -9 in NSCLC tumor and stromal cells: Correlation with a favorable clinical outcome. *Lung Cancer* 2012;75:235-41.
- Liang Y, Guo S, Zhou Q. Prognostic value of matrix metalloproteinase-7 expression in patients with non-small cell lung cancer. *Tumour Biol* 2014;35:3717-24.
- Shojaei F, Scott N, Kang X, Lappin PB, Fitzgerald AA, Karlicek S, *et al.* Osteopontin induces growth of metastatic tumors in a preclinical model of non-small lung cancer. *J Exp Clin Cancer Res* 2012;31:26.
- Zhang Y, Wang R, Song H, Huang G, Yi J, Zheng Y, *et al.* Methylation of multiple genes as a candidate biomarker in non-small cell lung cancer. *Cancer Lett* 2011;303:21-8.
- Mirsadraee S, Oswal D, Alizadeh Y, Caulo A, van Beek E Jr. The 7<sup>th</sup> lung cancer TNM classification and staging system: Review of the changes and implications. *World J Radiol* 2012;4:128-34.
- Shimizu K, Yoshida J, Nagai K, Nishimura M, Ishii G, Morishita Y, *et al.* Visceral pleural invasion is an invasive and aggressive indicator of non-small cell lung cancer. *J Thorac Cardiovasc Surg* 2005;130:160-5.
- Salako SE. The declaration of Helsinki 2000: Ethical principles and the dignity of difference. *Med Law* 2006;25:341-54.
- Beesley MF, McLaren KM. Cytokeratin 19 and galectin-3 immunohistochemistry in the differential diagnosis of solitary thyroid nodules. *Histopathology* 2002;41:236-43.



23. Li Y, Sun BS, Pei B, Li CG, Zhang ZF, Yin YS, *et al.* Osteopontin-expressing macrophages in non-small cell lung cancer predict survival. *Ann Thorac Surg* 2015;99:1140-8.
24. Yamamoto T, Oshima T, Yoshihara K, Nishi T, Arai H, Inui K, *et al.* Clinical significance of immunohistochemical expression of insulin-like growth factor-1 receptor and matrix metalloproteinase-7 in resected non-small cell lung cancer. *Exp Ther Med* 2012;3:797-802.
25. Yu TT, Han ZG, Shan L, Tao J, Zhang T, Yuan SF, *et al.* Expression of osteopontin in non-small cell lung cancer and correlative relation with microvascular density. *Asian Pac J Cancer Prev* 2014;15:29-32.
26. Jin Y, Tong DY, Chen JN, Feng ZY, Yang JY, Shao CK, *et al.* Overexpression of osteopontin,  $\alpha\beta 3$  and Pim-1 associated with prognostically important clinicopathologic variables in non-small cell lung cancer. *PLoS One* 2012;7:e48575.
27. Bourboulia D, Stetler-Stevenson WG. Matrix metalloproteinases (MMPs) and tissue inhibitors of metalloproteinases (TIMPs): Positive and negative regulators in tumor cell adhesion. *Semin Cancer Biol* 2010;20:161-8.
28. Liu H, Zhang T, Li X, Huang J, Wu B, Huang X, *et al.* Predictive value of MMP-7 expression for response to chemotherapy and survival in patients with non-small cell lung cancer. *Cancer Sci* 2008;99:2185-92.
29. Xiao XY, Lang XP. Correlation between MMP-7 and bFGF expressions in non-small cell lung cancer tissue and clinicopathologic features. *Cell Biochem Biophys* 2015;73:1-6.
30. de Castro Brás LE, DeLeon-Pennell KY, Bratton DR, Ma Y, Yabluchanskiy A, Halade GV, *et al.* Matrix metalloproteinase-9 stimulated osteopontin proteolysis enhances the extracellular matrix response post myocardial infarction. *Circulation* 2013;128:A15262.
31. Lindsey ML, Zouein FA, Tian Y, Padmanabhan Iyer R, de Castro Brás LE. Osteopontin is proteolytically processed by matrix metalloproteinase 9. *Can J Physiol Pharmacol* 2015;93: 879-86.