

Received: 2010.09.14  
Accepted: 2010.11.29  
Published: 2011.06.01

## T cell lymphoma presenting as esophageal obstruction and bronchoesophageal fistula

### Authors' Contribution:

- A** Study Design
- B** Data Collection
- C** Statistical Analysis
- D** Data Interpretation
- E** Manuscript Preparation
- F** Literature Search
- G** Funds Collection

Mala Sharma<sup>ABCDEF</sup>, Wilbert S. Aronow<sup>ABCDEF</sup>, Miechelle O'Brien<sup>ABCDEF</sup>,  
Kaushang Gandhi<sup>ABCDEF</sup>, Harshad Amin<sup>ABCDEF</sup>, Harit Desai<sup>ABCDEF</sup>

Department of Medicine, Divisions of Cardiology and Gastroenterology, New York Medical College, Valhalla, NY, U.S.A

Source of support: Departmental sources

### Summary

#### Background:

The mediastinum is an uncommon location for presentation of peripheral T cell lymphoma. Esophageal involvement by non-Hodgkin's lymphoma is extremely unusual. Although staging can be performed with routine imaging studies, surgical intervention is often required to ensure accurate histologic diagnosis of these lymphomas. Peripheral T cell lymphomas not otherwise specified are among the most aggressive non-Hodgkin lymphomas with often a poor response to conventional chemotherapy

#### Case Report:

We report a case of a 63 year-old-man with an aggressive mediastinal T cell lymphoma presenting as esophageal obstruction and bronchoesophageal fistula. The patient was treated with a cyclophosphamide, vincristine, and prednisone (COP) regimen. Repeat computer tomography scan of the chest after chemotherapy noted a significant decrease in the cavitory lesion in the right paroesophageal region and right mediastinum. Bronchoscopy revealed a large opening in the posterior wall of the bronchus intermedius leading into the esophagus. A fistulogram was done which clearly demonstrated a fistulous tract between the lower esophagus and the right intermediate bronchus secondary to perforation from the lymphoma. The patient eventually underwent cervical esophagostomy and jejunostomy tube placement to correct the bronchoesophageal fistula.

#### Conclusions:

The mediastinum is an uncommon location for presentation of peripheral T cell lymphomas, and surgical intervention is often required to ensure accurate histological diagnosis of these lymphomas. In our patient, aggressive mediastinal T cell lymphoma presented as esophageal obstruction and bronchoesophageal fistula

#### key words:

T cell lymphoma • mediastinum • esophageal obstruction • bronchoesophageal fistula

#### Full-text PDF:

<http://www.medscimonit.com/fulltxt.php?ICID=881797>

#### Word count:

1587

#### Tables:

–

#### Figures:

3

#### References:

10

#### Author's address:

Wilbert S. Aronow, Cardiology Division, New York Medical College, Macy Pavilion, Room 138, Valhalla, NY 10595, U.S.A., e-mail: waronow@aol.com

## BACKGROUND

The mediastinum is an uncommon location for presentation of peripheral T cell lymphoma (PTCL) [1,2]. Esophageal involvement by non-Hodgkin's lymphoma is extremely unusual. Although staging can be performed with routine imaging studies, surgical intervention is often required to ensure accurate histologic diagnosis of these lymphomas. PTCLs not otherwise specified are among the most aggressive non-Hodgkin lymphomas with often a poor response to conventional chemotherapy. Their response to conventional chemotherapy is indeed poor, with 5-year relapse-free and overall survival rates of 26% and 20%, respectively. [3]

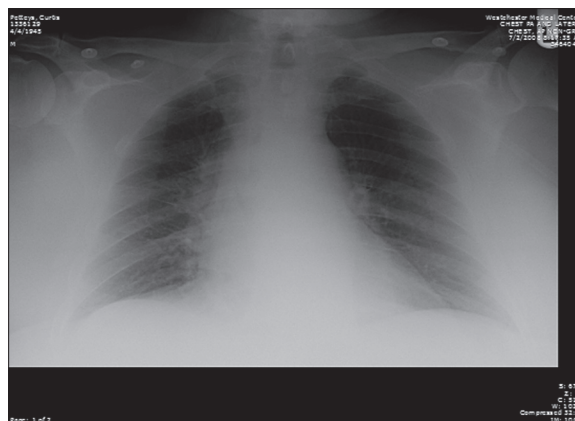
## CASE REPORT

A 63-year-old obese man with a history of hypertension, hypercholesterolemia, and paroxysmal atrial fibrillation was referred to Westchester Medical Center/New York Medical College with a 3-week history of productive cough, hemoptysis, dysphagia, and weight loss. About 3 weeks prior to admission, the patient started to experience cough initially productive of clear sputum. He also developed then new onset dysphagia initially with solids which gradually progressed to liquids and lost 40 pounds within 3 weeks. The patient also had three episodes of small amounts of hemoptysis prior to admission. The patient had been treated by his primary care physician with oral antibiotics and oral corticosteroids for 3 days prior to hospitalization without any relief. He denied any history of fever, nausea, vomiting, diarrhea, constipation, melena, or hematochezia.

His medications included metoprolol, digoxin, furosemide, lansoprazole, ezetimibe, simvastatin and aspirin. The patient did not have any known drug allergies. His family history was significant for his father's death from myocardial infarction at the age of 40 years and for his mother having diabetes mellitus. The patient had a history of consuming half a bottle of vodka every night for over 20 years. He had a history of smoking 1-2 cigarettes/day for 20 years but quit smoking 10 years ago.

On physical examination, the patient's temperature was 97.1 degrees Fahrenheit. His heart rate was 87 beats per minute and regular, his respiratory rate was 18 per minute, his blood pressure was 122/53 mm Hg, his weight was 292 pounds, and his oxygen saturation was 94% on 2 liters nasal canula. The rest of the physical examination was unremarkable with no palpable lymphadenopathy or organomegaly.

Initial laboratory results showed a white blood cell count of  $15,900/\text{mm}^3$  with a differential of 80.6% neutrophils, 5.2% lymphocytes, and 13.4% monocytes. His red blood cell count was  $5,040,000/\text{mm}^3$ , hemoglobin was 15.8 gm/dl, hematocrit was 46.2%, serum sodium was 130 mEq/l, serum potassium was 3.6 mEq/l, serum chloride was 88 mEq/l, serum bicarbonate was 28 mEq/l, serum creatinine was 1.5 mg/dl, blood urea nitrogen was 25 mg/dl, random blood glucose was 161 mg/dl, serum calcium was 9.7 mg/dl, serum aspartate aminotransferase was 26 U/l, serum alanine aminotransferase was 24 U/l, serum alkaline phosphatase was 77 U/l, serum lactate dehydrogenase was 306 U/l and serum total bilirubin was 0.7 mg/dl.



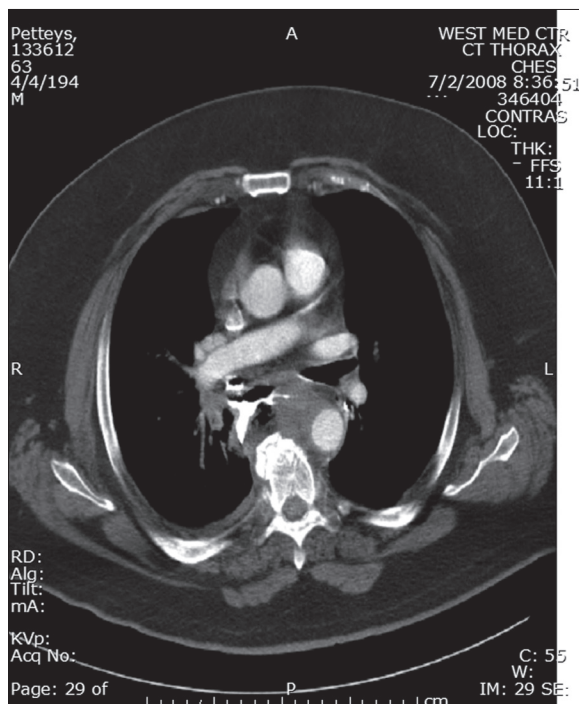
**Figure 1.** Chest roentgenogram shows confluent opacity in the mediastinum.

The chest roentgenogram (Figure 1) revealed a confluent opacity in the right retrohilar and retrocardiac region. The computerized tomography (CT) scan of the chest with contrast (Figures 2, 3) revealed a mid to distal esophageal mass suspicious for esophageal neoplasm. There was a fistulous connection to a right paraesophageal cavity containing oral contrast, debris, and air with suggestion of an additional fistulous connection between the esophagus and the right mainstem bronchus. Right-sided parahilar lymphadenopathy and pleural effusion were also noted.

Endoscopy revealed complete obstruction in the mid esophagus and a large necrotic cavity with inability to pass the scope beyond the obstruction. Biopsies of the necrotic mass taken during endoscopy were indeterminate and suggestive of necrotic tissue with acute pyogenic inflammation. A repeat CT scan of the chest, abdomen, and pelvis demonstrated again a mediastinal mass density involving the right paratracheal, subcarinal, and paraesophageal regions. There was significant thickening of the mid-distal esophagus, with a cavitory lesion in the right paraesophageal region, bilateral pleural effusions, and mild lymphadenopathy in the upper abdomen. Bone scan showed no evidence of skeletal metastasis.

The patient underwent CT-guided esophageal mass biopsy which revealed densely fibrotic tissue with infiltrating stromal cells, lymphocytic and eosinophilic inflammatory cells. Tissue staining was negative for cytokeratin (AE1/AE3), positive for muscle common actin, positive for lymphocyte common actin, negative for CD-20 B lymphocytes, and negative for CD 117(C-kit). The differential diagnosis for the mass at this time included smooth muscle tumor, myofibroblastic tumor, and inflammatory pseudotumor.

At this time, an open exploration with biopsy was considered. Right thoracotomy with exploration of the pleural space was performed, and intraoperative findings were significant for a large posterior mediastinal mass extending from the carina to the hiatus of the esophagus. The mass was noted to be adherent to the lung. Multiple biopsies were taken. The biopsies of the tissue sample obtained during the open thoracotomy revealed diffuse proliferation of atypical lymphoid cells involving the mediastinal fibroadipose tissue and were demonstrated to be CD-5 and CD-45 positive T cells. However no other T cell markers could be analyzed. Flow cytometry



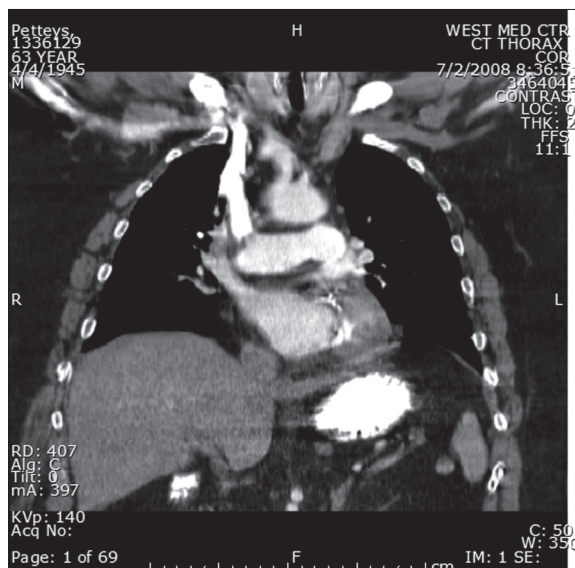
**Figure 2.** Computer tomography (CT) scan of the chest reveals a 4.6 times 3.1 cm cavity adjacent to the esophagus with a fistulous connection between the necrotic cavity and the right main bronchus.

also revealed that CD-20 positive B cells comprised <1% of the total sample analyzed, and no definite clonality for surface kappa or lambda light chains could be detected. The lesion was thus classified as peripheral T cell lymphoma (PTCL), not otherwise specified. Positivity for Epstein-Barr virus – associated small RNAs was not analyzed.

Postoperatively, the patient was noted to have atrial flutter with a rapid ventricular rate and was started on a diltiazem intravenous drip, and the patient's cardiac rhythm converted to sinus rhythm within 24 hours. Two days later, the patient was noted to be acutely hypoxic requiring urgent intubation and mechanical ventilation. The work-up was negative for pulmonary embolism. The patient became febrile and septic requiring intravenous antibiotics for treatment of postobstructive pneumonia and also required vasopressors for hypotension.

The biopsy report revealed diffuse proliferation of atypical lymphoid cells involving the mediastinal fibroadipose tissue demonstrated by immunochemical staining to be T cells. The lesion was classified as peripheral T cell lymphoma (PTCL), not otherwise specified. Doxorubicin was omitted from the regimen because of its potential cardiotoxicity. The patient was treated with a cyclophosphamide, vincristine, and prednisone (COP) regimen. Repeat CT scan of the chest after chemotherapy noted a significant decrease in the cavitary lesion in the right paraesophageal region and right mediastinum.

Bronchoscopy revealed a large opening in the posterior wall of the bronchus intermedius leading into the esophagus. A fistulogram was done which clearly demonstrated a



**Figure 3.** Fistulous connection between the necrotic cavity and the right main bronchus.

fistulous tract between the lower esophagus and the right intermediate bronchus secondary to perforation from the lymphoma. The patient eventually underwent cervical esophagostomy and jejunostomy tube placement to correct the bronchoesophageal fistula. The patient required revision of the J tube secondary to obstruction, following which the patient was started on tube feedings.

## DISCUSSION

Lymphoma is one of the most common mediastinal tumors and may be manifested as a primary mediastinal lesion, or more frequently, as generalized disease. WHO in 2008 classified lymphomas into 3 broad categories- B cell lymphomas, T and NK cell lymphomas, and Hodgkins lymphomas [4]. T cell lymphomas include PTCLs that make up a heterogeneous morphological group of aggressive neoplasms that share a mature T cell immunophenotype. [3–5]. PTCLs represent approximately 12% of lymphoid neoplasms. PTCLs can be roughly subdivided into: specified and not otherwise specified (NOS). While PTCL specified tumors correspond to distinct but rare entities often occurring at extranodal sites, 40–50% of the PTCLs show such morphological and molecular variability as to hamper any further classification, and to justify their inclusion in a waste-basket category termed “not otherwise specified (NOS)”. NOS represent the commonest type of PTCLs. PTCL NOS more often presents in stage III–IV, with nodal, skin, liver, spleen, bone marrow or peripheral blood involvement. The tumor is highly variable in terms of cell morphology and may contain prominent reactive components. Immunohistochemistry usually shows T cell associated molecule expression, although the phenotypic profile is aberrant in about 80% of cases. PTCL/NOS are among the most aggressive non-Hodgkin lymphomas. Their response to conventional chemotherapy is indeed poor, with 5-year relapse-free and overall survival rates of 26% and 20%, respectively [1].

The mediastinum is an uncommon location for presentation of PTCL [3–5]. Symptoms associated with a mediastinal

presentation of a lymphoma are often attributable to invasion of thoracic structures such as the pericardium or pleura or compression of mediastinal structures [6].

Diagnostic problems may arise when lymphoma manifests with primary mediastinal lymphadenopathy or a focal mass [7]. Esophageal involvement by non-Hodgkin's lymphoma is extremely unusual [8]. Esophageal involvement by lymphoma is, in most cases, secondary. Affected mediastinal lymph nodes may either cause narrowing of the lumen due to external compression or the esophageal wall may be invaded directly when tumors spread beyond their anatomical boundaries [9]. Although staging can be performed with routine imaging studies, surgical intervention is often required to ensure accurate histologic diagnosis of these lymphomas [9]. Treatment regimens are the same as those used for diffuse large B cell lymphomas (omitting rituximab). A combination of chemotherapy drugs is usually used, such as cyclophosphamide, doxorubicin, vincristine and prednisolone (CHOP) or prednisolone, **mitoxantrone**, cyclophosphamide, **etoposide**, **bleomycin** and vincristine (**PMitCEBO**). If the lymphoma is stage 1 or 2 (only affecting lymph nodes in one area of the body), a combination of chemotherapy and radiotherapy may be used [10].

## CONCLUSIONS

The mediastinum is an uncommon location for presentation of peripheral T cell lymphomas, and surgical intervention is often required to ensure accurate histological diagnosis of these lymphomas. In our patient, aggressive mediastinal T cell lymphoma presented as esophageal obstruction and bronchoesophageal fistula

## Conflicts of interest

None of the authors have any conflicts of interest pertaining to this article.

## REFERENCES:

1. Zucca E, Zinzani PL: Understanding the group of peripheral T-cell lymphomas, unspecified. *Curr Hematol Rep*, 2005; 4: 23–30
2. Harris NL, Jaffe ES, Stein H et al: A revised European – American classification of lymphoid neoplasms: a proposal from the International Lymphoma Study Group. *Blood*, 1994; 84: 1361–92
3. Campidelli P, Zinzani L, Falini B et al: Peripheral T cell lymphoma, not otherwise specified: the stuff of genes, dreams and therapies. *J Clin Pathol*, 2008; 61: 1160–67
4. Swerdlow S, Campo E, Harris N: World Health Organization Classification of Tumours of Haematopoietic and Lymphoid Tissues. Lyon, France: IARC Press, 2008
5. Lopez-Guillermo A, Cid J, Salar A et al: Peripheral T-cell lymphomas: initial features, natural history, and prognostic factors in a series of 174 patients diagnosed according to the REAL Classification. *Ann Oncol*, 1998; 9: 849–55
6. Petersdorf SH, Wood DE: Lymphoproliferative disorders presenting as mediastinal neoplasms. *Semin Thorac Cardiovasc Surg*, 2000; 12: 290–300
7. Strollo DC, Rosado-de-Christenson ML, Jett JR: Primary mediastinal tumors Part II. Tumors of the middle and posterior mediastinum. *Chest*, 1997; 112: 1344–57
8. Wagner PL, Tam W, Lau PY et al: Primary esophageal large T-cell lymphoma mimicking esophageal carcinoma: A case report and literature review. *J Thorac Cardiovasc Surg*, 2008; 135: 957–58
9. Taal BG, Van Heerde P, Somers R: Isolated primary oesophageal involvement by lymphoma: a rare cause of dysphagia: two case histories and a review of other published data. *Gut*, 1993; 34: 994–98
10. Evens AM, Gartenhaus RB: Treatment of T-cell non-Hodgkin's lymphoma. *Curr Treat Options Oncol*, 2004; 5: 289–303