

Contents lists available at [ScienceDirect](https://www.sciencedirect.com)

International Journal of Surgery Case Reports

journal homepage: www.casereports.com

Diagnostic challenges of benign breast phyllodes tumour: A rapid-growing tumour during pregnancy caused breast loss. A case report

Lina Pankratjevaite^{a,*}, Amuras Samulionis^b, Theodora Miliou^c

^a Department of Plastic and Breast Surgery, Aalborg University Hospital, Aalborg, Denmark

^b Department of Pathology, Aalborg University Hospital, Aalborg, Denmark

^c Department of Radiology, Aalborg University Hospital, Aalborg, Denmark

ARTICLE INFO

Article history:

Received 28 February 2021

Received in revised form 29 March 2021

Accepted 31 March 2021

Available online 8 April 2021

Keywords:

Breast phyllodes
Rare breast disease
Surgery
Pregnancy
Case report

ABSTRACT

INTRODUCTION: Phyllodes tumours are rare breast neoplasms. It is especially rare in pregnancy.

PRESENTATION OF CASE: We report a case of a 37-year-old woman with left breast benign phyllodes tumour, which started to grow very fast during pregnancy. The tumour was too big for breast-conserving surgery and it was necessary to remove the whole left breast. Patient underwent successful nipple-skin-sparing mastectomy with immediate silicone implant reconstruction.

CONCLUSION: Breast phyllodes are classified as benign, borderline, and malignant. Standard treatment of breast phyllodes is surgery. The choice of surgery type depends on the tumour factors and breast size.

We highlight that, inadequate treatment of phyllodes tumour can result to recurrence, growth, or even metastatic spread, when tumour has malignant potential.

© 2021 The Authors. Published by Elsevier Ltd on behalf of IJS Publishing Group Ltd. This is an open access article under the CC BY-NC-ND license (<http://creativecommons.org/licenses/by-nc-nd/4.0/>).

1. Introduction

Phyllodes tumour is an uncommon breast mass with incidence from 0.3% to 0.5% of all breast tumours [1,2]. They tend to strike women in their 40s (range 11–83) [3].

Breast phyllodes tumours can be benign, borderline, and malignant. Older patients more often have higher grade tumours [4,5].

Breast phyllodes tumours usually manifest as a rapid growing, painless mass [6]. They vary in size and can reach up to 60 cm [7].

Anamnesis, clinical assessment, imaging studies play an important role in the diagnosis of breast phyllodes tumour. The diagnosis can only be definitively established by histopathological examination.

Breast phyllodes tumours are managed surgically. The type of surgery depends on the tumour size, breast size, tumour potential of malignancy, risk of local recurrence and risk for distant metastases.

In line with the SCARE criteria, we report a case of a 37-year-old woman with left breast phyllodes tumour, which started to grow up very fast during pregnancy. Patient underwent successful skin-sparing mastectomy with immediate silicone implant reconstruction in Aalborg University Hospital, Denmark [8].

* Corresponding author at: Department of Plastic and Breast Surgery, Aalborg University Hospital, Sondre Skovvej 3, 9000, Aalborg, Denmark.

E-mail address: linapankratjevaite@gmail.com (L. Pankratjevaite).

2. Case report

A 37-year-old female from the Philippines presented with a deformed, hard left breast. She was known with a chronic hepatitis B infection. The patient had no allergies, no other diseases or relevant family history, she denied taking any special medications, and was not a habitual smoker or drinker.

Two years ago, the patient underwent extirpation of 30 mm tumour from the left breast in the Philippines.

According to the patient, benign tumour was removed radical and she didn't need any adjuvant treatment or follow-up. She did not have any documents from the Philippines.

Six months ago, the patient was pregnant for the first time in her life and experienced a miscarriage. According to the patient, the left breast was growing up very fast during pregnancy. She noticed, that it became much bigger and harder than the right breast. The patient thought it could be the result of the hormonal changes during pregnancy, and came to our patient clinic, because the lump in the left breast did not disappear after the miscarriage.

The left breast was found fully filled with hard, big mass during a physical examination. However, skin was not involved.

A breast ultrasound showed a 67 mm well-defined, cystic structure in the left breast (BIRADS 3, Fig. 1).

Mammogram demonstrated a well-circumscribed 74 mm mass in the left breast (Fig. 2).

Core needle biopsy was performed. Histopathological examination of the material was not conclusive, and core needle biopsy

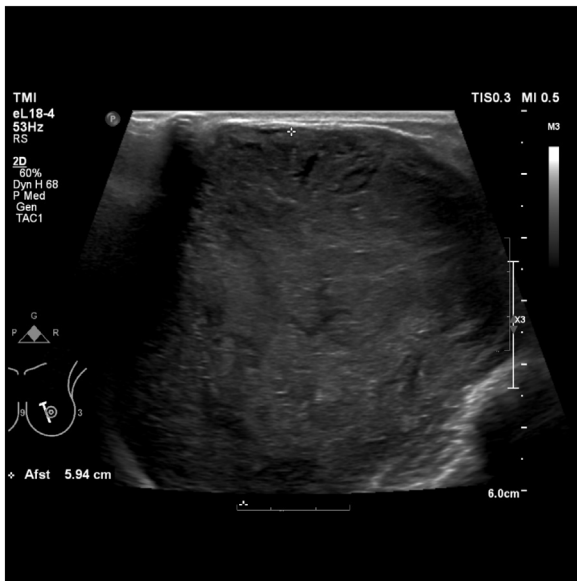

Fig. 1. Ultrasound revealed big cystic lesion on the left breast.

was repeated. This time it showed an acute and chronic inflammation, without malignancy. It was decided to perform an excisional biopsy, because there was no correlation between the histologic diagnosis and the imaging findings.

Tumour was reached through the small inframammary incision. The mass was well-circumscribed, but when the capsule was cut, haemorrhagic, necrotic masses have shown up. The inner part of the tumour was very fragile. Histopathological examination of surgical material showed a characteristic leaf-like epithelial pattern. There was no stromal atypia, but it was found to have low stromal cellularity and areas with necrosis. Preoperative benign phyllodes tumour diagnosis was made.

The patient was discussed at the Multidisciplinary team (MDT) conference. Because of the tumour size, it was decided to perform nipple-skin-sparing mastectomy with immediate silicone implant reconstruction (Fig. 3). The surgery was performed by experienced breast surgeons in a collaboration with a plastic surgeon. Final histopathological examination confirmed benign phyllodes tumour diagnosis (Figs. 4, 5). It was found to be a well-defined, encapsulated biphasic lesion with typical leaf-like pattern with low stromal cellularity. There was no atypia and no mitotic activity. Ki67

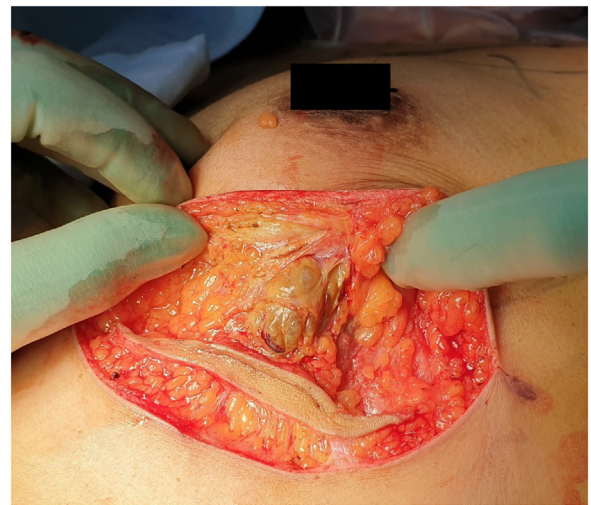

Fig. 3. Patient underwent successful nipple-skin-sparing mastectomy with immediate silicone implant reconstruction.

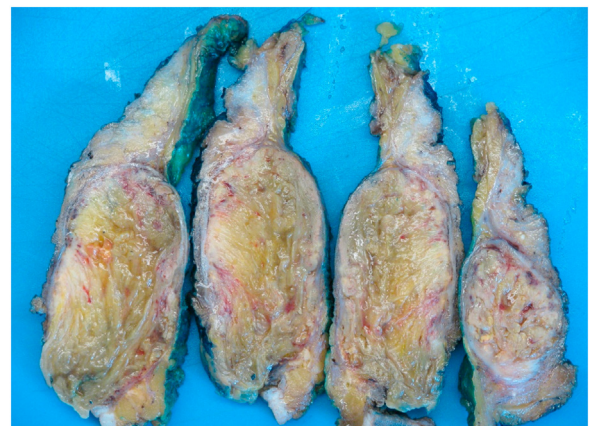

Fig. 4. Gross image of the tumour and the breast.

index showed low proliferation ratio. The biggest part of tumour was necrotized. There were no signs of malignancy. Tumour was removed radically.

The patient's postoperative course was uneventful. No adjuvant treatment was required, and she remained without recurrence at

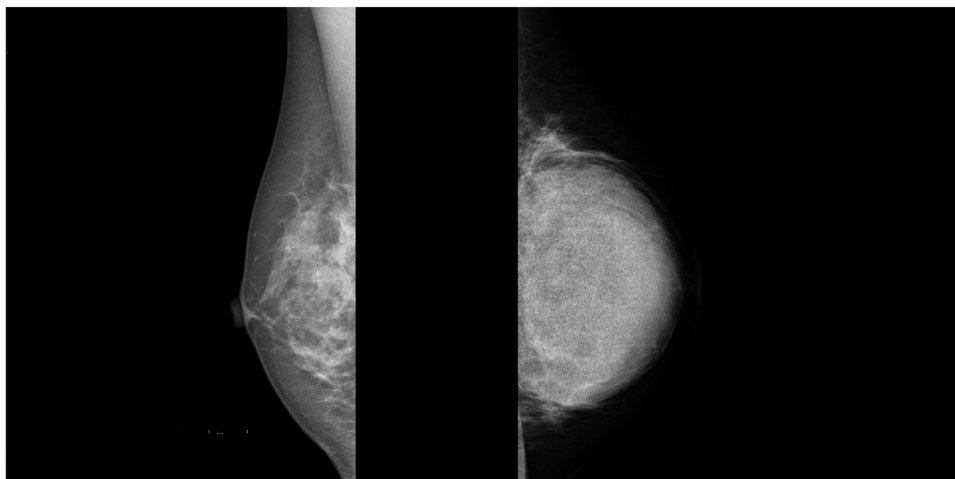


Fig. 2. Normal breast tissue on the right breast, and phyllodes tumour on the left breast.

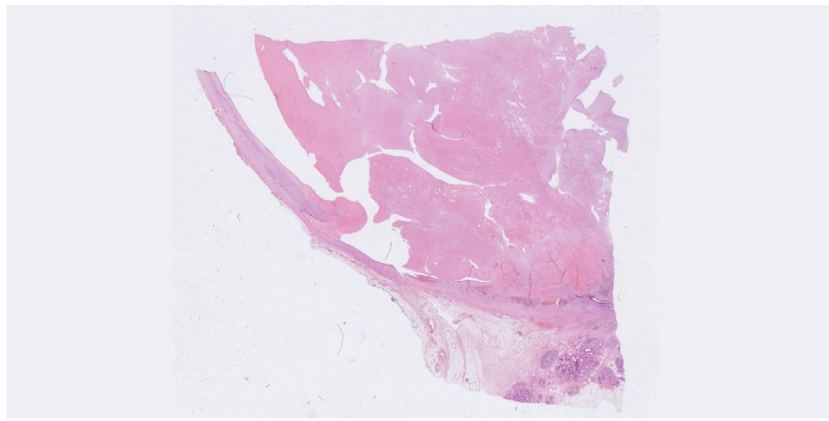


Fig. 5. Microscopic image of the tumour.

her one-year follow-up in our outpatient clinic. The patient was satisfied with surgical outcome and good cosmetic results.

3. Discussion

Accurate diagnosis of breast phyllodes tumours is essential to ensure the best treatment option for the patient. Inadequate treatment can result in tumour recurrence, growth, or even metastatic spread, when tumour has malignant potential.

Clinically phyllodes tumour usually appears as a round, firm, well-circumscribed, painless mass of the breast [9].

Though imaging studies play an important role in the diagnosis of tumour in breast, but phyllodes tumour does not have any specific radiologic features. Usually on imaging studies it appears as a lobulated shape (sometimes round), with well-defined margins, solid or solid-cystic mass of the breast [10]. Magnetic resonance imaging (MRI) may be also used for phyllodes tumour diagnosis.

It is very important to differentiate phyllodes tumour from other benign breast diseases (for example, fibroadenoma, juvenile fibroadenoma, adenoma, lipoma, hamartoma, etc.) or malignant tumours (for example, carcinoma, sarcoma, metastases, etc.).

The definitive diagnosis is made just after the histopathological examination. Sometimes preoperative core needle biopsy is not enough and other possibilities like re-biopsy, excisional biopsy or surgery without preoperative histopathological diagnosis should be considered. In our case, the first core needle biopsy was inconclusive, the second has shown just chronic and acute inflammation. Just the third excisional biopsy confirmed phyllodes tumour diagnosis. Our case show, that sometimes doctors can have diagnostic challenges by diagnosing phyllodes tumour. It can happen because, sometimes phyllodes tumours have big areas with haemorrhagic, necrotic tissues and radiologists are using just 16-gauge needles to take the sample from the lesions.

Macroscopically phyllodes tumour usually appears as lobulated tumour, with grey or red “meaty” consistency, with haemorrhagic, fibro gelatinous, necrotic areas on cut section [11].

Microscopically phyllodes tumours have characteristic features like “leaf-like” structure [12].

The World Health Organisation (WHO) classifies breast phyllodes tumours into benign, borderline, and malignant based on the degree of stromal cellularity, stromal atypia, stromal overgrowth, mitotic activity and tumour margin [10].

Benign phyllodes tumours have mild stromal atypia, mildly increased stromal cellularity, absent stromal overgrowth, and mitotic activity usually is lower than 5 per 10 high-power fields (HPF) [12]. Borderline phyllodes tumours are characterized by moderate stromal atypia, moderately increased stromal cellularity,

absent or very focal stromal overgrowth and mitotic activity usually is 5–9 per 10 HPF [12]. Marked stromal atypia, markedly/diffusely increased stromal cellularity, stromal overgrowth and more than 10 mitoses per 10 HPF are the characteristics of malignant phyllodes tumour [12].

National Comprehensive Cancer Network (NCCN) guidelines recommend wide excision with tumour-free margins of 1 cm or more for phyllodes tumour [13,14]. Sometimes breast-conserving surgery is not enough and mastectomy should be performed to obtain an adequate margin [15]. However, wide excision can lead to lack of breast volume, breast deformity, and be associated with psychological problems and poorer quality of life. To approach better cosmesis some authors recommend to consider staged excision [15].

Furthermore, some authors declare that 1 cm margin might be over treatment [14,16].

According to the literature, the local recurrence (LR) rate belongs from the grade of phyllodes tumour: the pooled LR rate is 8% for benign phyllodes compared with 13% for borderline and 18% for malignant [13]. However, according to some authors, there is no difference of the recurrence rates of benign phyllodes between a 1 mm and 10 mm margin (p 0.124) and 1 mm is an acceptable margin for benign tumour [16]. Nevertheless, the LR rate of benign phyllodes increases to 12.9% with positive margins [16]. In case of margin involvement re-excision or close surveillance should be offered for the patients with positive margins of benign phyllodes [14,16]. No adjuvant treatment is needed for the patient with microscopically radical removed benign phyllodes tumours, and they can be followed up with annual surveillance [14].

Doctors need to be aware, that phyllodes tumour can occur or start to grow-up very fast during pregnancy [17]. It is not known, how pregnancy affects the diagnosis, treatment, and prognosis, because only few cases of phyllodes tumour related to pregnancy have been reported [18].

4. Conclusion

Standard treatment of phyllodes tumours is surgery. Inadequate treatment can result to tumour recurrence, growth, or even metastatic spread, when tumour has malignant potential. The choice of surgery type depends on the tumour factors, breast size. In suitable cases, skin-sparing mastectomy with immediate silicone implant reconstruction might be a treatment option.

5. Learning points/take home messages

- Phyllodes tumours are extremely rare in pregnancy.

- It is not known, how pregnancy affects the diagnosis, treatment, and prognosis due to small number of cases.
- Inadequate treatment can result to tumour recurrence, growth, or even metastatic spread, when tumour has malignant potential.
- Further studies in this area are needed.

Declaration of Competing Interest

The authors report no declarations of interest.

Funding

None.

Ethical approval

Ethical approval was not required in the treatment of the patient in this report.

Consent

Written informed consent was obtained from the patient for publication of this case report and accompanying images. A copy of the written consent is available for review by the Editor-in-Chief of this journal on request.

Author contribution

Lina Pankratjevaite – contributes to the study concept and design, data collection and writing the paper.
Amuras Samulionis – writing the paper.
Theodora Miliou – writing the paper.

Registration of research studies

Not applicable.

Guarantor

Lina Pankratjevaite is the guarantor of this submitted article.

Provenance and peer review

Not commissioned, externally peer-reviewed.

Acknowledgements

We are grateful and appreciate the assistance of doctor Mette Holmqvist, Department of Plastic and Breast Surgery, Aalborg University Hospital, Sdr. Skovvej 3, 9000 Aalborg, Denmark.

References

- [1] M.D. Rowell, R.R. Perry, J.G. Hsiu, S.C. Barranco, Phyllodes tumors, *Am. J. Surg.* 165 (1993) 376–379, [http://dx.doi.org/10.1016/S0002-9610\(05\)80849-9](http://dx.doi.org/10.1016/S0002-9610(05)80849-9).
- [2] D.P. Geisler, M.J. Boyle, K.F. Malnar, et al., Phyllodes tumors of the breast: a review of 32 cases, *Am. Surg.* 66 (4) (2000) 360–366.
- [3] A.V. Barrio, B.D. Clark, J.I. Goldberg, L.W. Hoque, S.F. Bernik, L.W. Flynn, et al., Clinicopathologic features and long-term outcomes of 293 phyllodes tumors of the breast, *Ann. Surg. Oncol.* 14 (2007) 2961–2970, <http://dx.doi.org/10.1245/s10434-007-9439-z>.
- [4] R.Z. Karim, S.K. Gerega, Y.H. Yang, A. Spillane, H. Carmalt, R.A. Scolyer, et al., Phyllodes tumours of the breast: a clinicopathological analysis of 65 cases from a single institution, *Breast* 18 (2009) 165–170, <http://dx.doi.org/10.1016/j.breast.2009.03.001>.
- [5] J. Ben hassouna, T. Damak, A. Gamoudi, R. Chargui, F. Khoms, S. Mahjoub, et al., Phyllodes tumors of the breast: a case series of 106 patients, *Am. J. Surg.* 192 (2006) 141–147, <http://dx.doi.org/10.1016/j.amjsurg.2006.04.007>.
- [6] E.P. Weledji, G. Enow-Orock, M.N. Ngowe, L. Aminde, Breast-conserving surgery is contraindicated for recurrent giant multifocal phyllodes tumours of breast, *World J. Surg. Oncol.* 12 (2014) 2–5, <http://dx.doi.org/10.1186/1477-7819-12-213>.
- [7] J. Paryani, A huge benign phyllodes tumour of the breast: a rare entity, *Indian J. Surg. Oncol.* 10 (2019) 389–391, <http://dx.doi.org/10.1007/s13193-019-00911-y>.
- [8] R.A. Agha, T. Franchi, C. Sohrabi, G. Mathew, A. Kerwan, A. Thoma, et al., The SCARE 2020 guideline: updating consensus surgical CAse REport (SCARE) guidelines, *Int. J. Surg.* 84 (2020) 226–230, <http://dx.doi.org/10.1016/j.ijsu.2020.10.034>.
- [9] A.A. Mangi, B.L. Smith, M.A. Gadd, K.K. Tanabe, M.J. Ott, W.W. Souba, Surgical management of phyllodes tumors, *Arch. Surg.* 134 (5) (1999) 487–493, <http://dx.doi.org/10.1001/archsurg.134.5.487>, *ModGeriatr* 1973;3:406–409.
- [10] C. Ditsatham, W. Chongruksut, Phyllodes tumor of the breast: diagnosis, management and outcome during a 10-year experience, *Cancer Manag. Res.* 11 (2019) 7805–7811, <http://dx.doi.org/10.2147/CMAR.S215039>.
- [11] C.A. Ossa, F. Herazo, M. Gil, C. Echeverri, G. Ángel, M. Borrero, et al., Phyllodes tumor of the breast: a clinic-pathologic study of 77 cases in a Hispanic cohort, *Colomb. Med. (Cali, Colomb.)* 46 (2015) 104–108, <http://dx.doi.org/10.25100/cm.v46i3.1595>.
- [12] Y. Zhang, C.G. Kleer, Phyllodes tumor of the breast histopathologic features, differential diagnosis, and molecular/genetic updates, *Arch. Pathol. Lab. Med.* 140 (2016) 665–671, <http://dx.doi.org/10.5858/arpa.2016-0042-RA>.
- [13] Y. Lu, Y. Chen, L. Zhu, P. Cartwright, E. Song, L. Jacobs, et al., Local recurrence of benign, borderline, and malignant phyllodes tumors of the breast: a systematic review and meta-analysis, *Ann. Surg. Oncol.* 26 (2019) 1263–1275, <http://dx.doi.org/10.1245/s10434-018-07134-5>.
- [14] S. Ogunbiyi, A. Perry, K. Jakate, J. Simpson, R. George, Phyllodes tumour of the breast and margins: how much is enough? *Can. J. Surg.* 62 (2019) E19–21, <http://dx.doi.org/10.1503/cjs.005718>.
- [15] E.C. Ip, O. Ung, A novel breast-conserving surgical technique in the management of phyllodes tumours of the breast, *World J. Surg.* (2020) 2–5, <http://dx.doi.org/10.1007/s00268-020-05748-z>.
- [16] M. Shaaban, L. Barthelmes, Benign phyllodes tumours of the breast: (over) treatment of margins – a literature review, *Eur. J. Surg. Oncol.* 43 (2017) 1186–1190, <http://dx.doi.org/10.1016/j.ejso.2016.10.019>.
- [17] T. Likhitmaskul, W. Asanprakit, S. Charoenthammaraksa, V. Lohsiriwat, S. Supaporn, W. Vassanasiri, et al., Giant benign phyllodes tumor with lactating changes in pregnancy: a case report, *Gland Surg.* 4 (2015) 339–33943, <http://dx.doi.org/10.3978/j.issn.2227-684X.2015.01.09>.
- [18] W.-X. Zhang, X.-Y. Kong, J. Zhai, Y. Fang, Y. Song, J. Wang, Fatal outcome of malignant phyllodes tumor of the breast in pregnancy: a case and literature review, *Gland Surg.* 10 (2021) 371–377, <http://dx.doi.org/10.21037/gs-20-538>.

Open Access

This article is published Open Access at [sciencedirect.com](https://www.sciencedirect.com). It is distributed under the [IJSR Supplemental terms and conditions](https://creativecommons.org/licenses/by/4.0/), which permits unrestricted non commercial use, distribution, and reproduction in any medium, provided the original authors and source are credited.