

Clinical Report

## Late onset tacrolimus-induced life-threatening polyneuropathy in a kidney transplant recipient patient

Delphine Renard<sup>1</sup>, Thierry Gauthier<sup>4</sup>, Jean-Pierre Venetz<sup>2</sup>, Thierry Buclin<sup>1</sup> and Thierry Kuntzer<sup>3</sup>

<sup>1</sup>Division of Clinical Pharmacology, University Hospital of Lausanne, Lausanne, Switzerland, <sup>2</sup>Transplantation Center, University Hospital of Lausanne, Lausanne, Switzerland, <sup>3</sup>Division of Neurology, University Hospital of Lausanne, Lausanne, Switzerland and <sup>4</sup>Riviera Hospital, Vevey, Switzerland

Correspondence and offprint requests to: Delphine Renard; E-mail: delphine.renard@chuv.ch

### Abstract

A 59-year-old kidney recipient was diagnosed with a late onset of severe chronic inflammatory demyelinating polyradiculoneuropathy and almost fully recovered after stopping tacrolimus and one course of intravenous immunoglobulin treatment. Unique features of this patient are the unusually long time lapse between initiation of tacrolimus and the adverse effect (10 years), a strong causality link and several arguments pointing toward an inflammatory etiology. When facing new neurological signs and symptoms in graft recipients, it is important to bear in mind the possibility of a drug-induced adverse event. Discontinuation of the suspect drug and immunomodulation are useful treatment options.

**Keywords:** adverse event; chronic inflammatory demyelinating polyradiculoneuropathy; tacrolimus

### Introduction

Safety concerns about tacrolimus include neurological adverse events (NAEs) similar to other calcineurin inhibitors [1–4]. In a 1991 prospective study ( $n=44$ ), NAEs were reported in 32% of liver transplant recipients on tacrolimus [5]. In 2007, a large prospective study ( $n=1645$ ) reported NAEs to be present in 10–15% of patients treated with calcineurin inhibitors for 1 year [6]. We report here a kidney transplant recipient who developed a life-threatening demyelinating sensorimotor polyneuropathy while on tacrolimus.

### Case report

A 59-year-old African-born female patient underwent renal deceased donor heterotopic transplantation in August 2000. Cytomegalovirus serology was negative in the donor, positive in the recipient; Epstein-Barr virus serology was positive in both donor and recipient. Initial immunosuppression consisted of basiliximab 20 mg at days 0 and 4, then cyclosporine (targeted plasma level 150–200 µg/L), azathioprine (1–2 mg/kg/day) and steroids. At day 7, cyclosporine was switched to tacrolimus (targeted plasma level 8–10 µg/L) because of digestive intolerance. Two episodes of mild rejection at months (M) 4 and 106 were successfully treated.

Otherwise, creatinine and tacrolimus serum levels remained stable over many years (Fig. 1).

Ten years after the graft, at M118, the patient complained about painful paresthesias first in both hands, and 1 month later in her feet. At M120, neurological examination revealed distal loss of touch and vibratory sensations of four extremities. The sensory nerve action potentials (SNAPs) were absent in the ulnar, median and sural nerves (Tables 1 and 2). At M121, the patient was hospitalized for stance and gait disorders. General examination was normal, tendon reflexes were preserved, but all sensory modalities were reduced in her distal upper and lower limbs. On the fourth hospital day, tacrolimus serum level was found to be elevated at 22.2 µg/L. The patient was found to have been erroneously receiving a double dose since admission. This was corrected and 5 days later, the tacrolimus level had almost normalized at 13.2 µg/L, but the neurological manifestations worsened. A repeat nerve conduction study demonstrated findings consistent with motor neuronal demyelination and absent SNAPs (Table 1). The patient also developed hypertension, tachycardia, profuse sweating, alternating diarrhea–constipation, urinary incontinence, multiple electrolyte disorders consistent with dysautonomia and delirium related to severe hyponatremia (117 mmol/L, normal range 135–145 mmol/L) and opiate toxicity. Results of extensive laboratory and radiology studies were all negative. Two days later, intravenous infusions of immunoglobulins (IVIg) were started (2 g/kg over 4 days), and tacrolimus was switched to sirolimus. With further supportive treatment, all symptoms improved rapidly over the next 3 weeks, and the patient was discharged home after a 2-month hospital stay (M123).

Two months later (M125), she was independent in all activities of daily living; however, diffuse hyporeflexia, bilateral hypoesthesia in a stocking and glove distribution with distal reduction of vibration sense, with some gait and Romberg unsteadiness, were still present.

## Discussion

Ten years after the graft, this 59-year-old kidney transplant recipient experienced a life-threatening sensorimotor peripheral neuropathy strongly suggesting a diagnosis of chronic inflammatory demyelinating polyradiculoneuropathy (CIDP). A tacrolimus-induced adverse event

has been judged probable (score of 5/13 according to the Naranjo Adverse Drug Reaction Probability Scale) [7].

We identified 12 other published reports of tacrolimus-related polyneuropathy [8–15]. The onset was within the first 3 months after initiation of tacrolimus in most of the patients, but one presented with symptoms after 10 months of treatment. Tacrolimus blood levels were described as over the target range in five cases. Demyelinating type of neuropathy was predominant. In contrast, tacrolimus has been used as an immunosuppressant treatment in two cases of primary CIDP [16, 17].

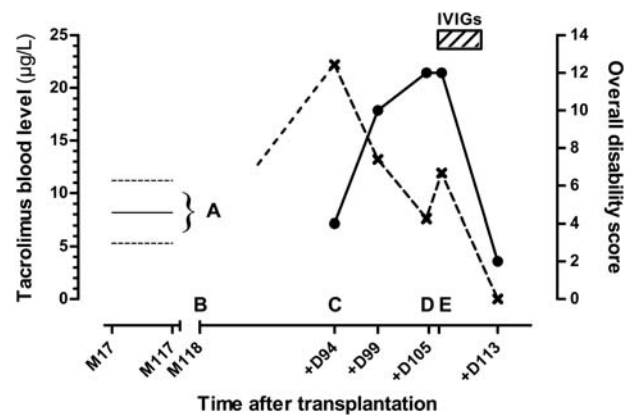
The underlying mechanism in our patient is probably inflammatory and non-toxic, given the fast and excellent response to the single course of IVIGs. The cause of inflammation is undetermined and some undiagnosed infection remains a possibility. Autoimmune damage is another possibility, a tacrolimus-triggered event in the context of dysimmunity in this graft recipient being possible.

In summary, our case contributes quite unique features of what is already known on tacrolimus-induced neuropathy:

1. The adverse effect occurred 10 years after initiation of tacrolimus.
2. A causal role of tacrolimus is suggested by a suggestive temporal relationship, long-term response after cessation of treatment, exclusion of other causes, some degree of dose–response relationship during transient overdosage and consistency with previously published cases.
3. Tacrolimus could be switched safely to sirolimus. Sirolimus-induced neurotoxicity has rarely been described [18, 19]. In our patient, it has been well tolerated so far after an ongoing treatment of 18 months.

In conclusion, this case illustrates that a drug-induced adverse reaction may occur a long time after starting tacrolimus. Early discontinuation of the offending drug and immunomodulation by IVIGs are the key components of management given the potential for a life-threatening course.

*Conflict of interest statement.* None declared.



**Fig. 1.** Tacrolimus whole blood levels (cross symbols) and clinical findings over time following transplantation. 0 = graft; M = month post-graft; D = days after 1st neurological manifestations; IVIGs = intravenous immunoglobulins. Overall disability sum score (filled circles) was retrospectively calculated according to Merckies ISJ et al., *J Neurol Neurosurg Psychiatry*, 2002. Tacrolimus whole blood levels were quantified by means of an immunoassay. (A) Variations of tacrolimus levels from M17 to M117 (full line = mean level, dotted lines = highest and lowest levels ever measured). (B) Onset of neurological manifestations at M118 = D0. (C) First neurological impairment at D94. (D) Switch from tacrolimus to sirolimus and beginning of IVIGs at D105. (E) First clinical improvement at D113.

**Table 1.** Results of nerve conduction studies (right side unless otherwise mentioned) at months 2.5 (A), 4 (B) and 7 (C) after the onset of neurological manifestations<sup>a</sup>

Nerve	Recording site	Parameters	A	B	C	Normal
<b>Motor studies</b>						
Median	Abductor pollicis brevis	Distal latency (ms)	4.5	17.4		<4.0
		Amplitude (mV)	6.8	0.2		>5
		Duration (ms)	10	37.8		<6
		CV (m/s)	52	0		>50
Tibial	Abductor hallucis	Distal latency (ms)	NR	0		<6.5
		Amplitude (mV)				>3
Peroneal	Extensor digitorum brevis (Tibialis anterior)	Distal latency (ms)	7.5	0(6)	12	<6.0 (<2.0)
		Amplitude (mV)	0.4	(0.1)	0.4	>3 (>4)
		Duration (ms)		(15)	15	<6 (<8)
		F-wave latency (ms)		0		<52
<b>Sensory studies</b>						
Median (digit 2)	Wrist	Amplitude (µV)	0	NR		>7
Sural	Ankle (right and left)	Amplitude (µV)	0	0	0	>5

<sup>a</sup>Data are all abnormal, characterized by prolonged distal motor latencies and desynchronization of the motor responses, and absence of sensory responses, suggestive of sensorimotor demyelinating neuropathy—ms, milliseconds; µV or mV, micro or millivolts; m/s, metre/second; CV, conduction velocity; NR, not recorded; 0, absent.

**Table 2.** Main characteristics of the 12 reported cases of tacrolimus-induced neuropathy (references in text)<sup>a</sup>

References	Sex, age in years	Type of graft	Tacrolimus treatment details	Symptoms onset (time after transplant)	Clinical signs	Type of conduction abnormalities	Treatment	Outcome
Ayres <i>et al.</i> [8]	Male, 31	Liver	tacrolimus 0.3 mg/kg daily from day 7 after transplant	D8	Flaccid quadriparesis; Renal failure	Motor axonal	Complete resolution within a few days	Complete recovery
Ayres <i>et al.</i> [8]	Male, 58	Liver	po from D7 on, 0.3 mg/kg/d	D8	Flaccid quadriparesis	Motor, axonal	Tacrolimus withdrawal	Complete recovery
Wilson <i>et al.</i> [15]	Male, 57 (diabetes mellitus)	Liver	None given	Shortly after	Paresthesias, and foot drops over 6 months	Multifocal, demyelinating	PLEX over 10 days	Improvement over months
Wilson <i>et al.</i> [15]	Male, 60	Liver	None given	D14	Distal paresthesias, walking difficulties over 2 months	Multifocal, demyelinating	PLEX over 10 days, and IVIGs	Improvement over months
Wilson <i>et al.</i> [15]	Male, 35 (alcoholic cirrhosis)	Liver	None given	D14	Distal paresthesias with weakness, bedridden	Sensori-motor, axonal	IVIGs over 3 days	Improvement over 3 weeks, then lost to follow-up
Bronster <i>et al.</i> [11]	Male, 45	Liver	Complex (see reference)	Over the 4 months following transplant	Disabling distal paresthesias	Generalized, demyelinating	Tacrolimus switched to cyclosporine	Improvement over weeks
Laham <i>et al.</i> [14]	Male, 40	Kidney	Complex (see reference)	D14	Distal muscle weakness	Multifocal, demyelinating	Withdrawal of tacrolimus; IVIGs over 5 days	Recovery within 19 weeks
Boukriche <i>et al.</i> [10]	Male, 52	Lung	Tacrolimus plasma level elevated	D3	Distal paresthesias, weakness and inability to walk	Sensori-motor, axonal	Transient cessation of tacrolimus	Improvement over months
Bhagavati <i>et al.</i> [9]	Female, 44	Kidney	3 mg bid	10 months	Facial twitching and numbness, gait dysbalance	Demyelinating, involving limbs and cranial nerves	IVIGs over 5 days	Improvement over months, recovery after 3 months
Bhagavati <i>et al.</i> [9]	Male, 53	Kidney	12 mg, then 7 mg bid	Immediately	None given	Diffuse, predominantly axonal neuropathy	Tacrolimus dose reduced to 2 mg bid	Resolution after 5–6 weeks
De Weerd <i>et al.</i> [12]	Female, 44	Liver and pancreas	Tacrolimus 0.04–0.08 mg/kg	D9	Distal muscle weakness	Asymmetric motor axonal	Tacrolimus dose reduced, IVIGs over 5 days	Improvement over months (walking aids after 2 years)
Labate <i>et al.</i> [13]	Female, 56	Heart	Tacrolimus 5 mg bid	2 months	Progressive paresthesias in the lower limbs	Symmetric, sensorimotor demyelinating	Tacrolimus switched to cyclosporine	Improvement over months

<sup>a</sup>D, days post-graft; iv, intravenous; IVIGs, intravenous immunoglobulins.

## References

1. Alessiani M, Cillo U, Fung JJ et al. Adverse effects of FK 506 overdosage after liver transplantation. *Transplant Proc* 1993; 25: 628–634
2. Bechstein WO. Neurotoxicity of calcineurin inhibitors: impact and clinical management. *Transplant Int* 2000; 13: 313–326
3. Eidelman BH, Abu-Elmagd K, Wilson J et al. Neurologic complications of FK 506. *Transplant Proc* 1991; 23: 3175–3178
4. Said G. Chronic inflammatory demyelinating polyneuropathy. *Neuromuscul Disord* 2006; 16: 293–303
5. Wijidicks EF, Wiesner RH, Dahlke LJ et al. FK506-induced neurotoxicity in liver transplantation. *Ann Neurol* 1994; 35: 498–501
6. Ekberg H, Tedesco-Silva H, Demirbas A et al. Reduced exposure to calcineurin inhibitors in renal transplantation. *N Engl J Med* 2007; 357: 2562–2575
7. Naranjo CA, Busto U, Sellers EM et al. A method for estimating the probability of adverse drug reactions. *Clin Pharmacol Ther* 1981; 30: 239–245
8. Ayres RC, Dousset B, Wixon S et al. Peripheral neurotoxicity with tacrolimus. *Lancet* 1994; 343: 862–863
9. Bhagavati S, Maccabee P, Muntean E et al. Chronic sensorimotor polyneuropathy associated with tacrolimus immunosuppression in renal transplant patients: case reports. *Transplant Proc* 2007; 39: 3465–3467
10. Boukriche Y, Brugiere O, Castier Y et al. Severe axonal polyneuropathy after a FK506 overdosage in a lung transplant recipient. *Transplantation* 2001; 72: 1849–1850
11. Bronster DJ, Yonover P, Stein J et al. Demyelinating sensorimotor polyneuropathy after administration of FK506. *Transplantation* 1995; 59: 1066–1068
12. De Weerd A, Claeys KG, De Jonghe P et al. Tacrolimus-related polyneuropathy: case report and review of the literature. *Clin Neurol Neurosurg* 2008; 110: 291–294
13. Labate A, Morelli M, Palamara G et al. Tacrolimus-induced polyneuropathy after heart transplantation. *Clin Neuropharmacol* 2010; 33: 161–162
14. Laham G, Vilches A, Jost L et al. Acute peripheral demyelinating polyneuropathy and acute renal failure after administration of FK506. *Medicina (B Aires)* 2001; 61: 445–446
15. Wilson JR, Conwit RA, Eidelman BH et al. Sensorimotor neuropathy resembling CIDP in patients receiving FK506. *Muscle Nerve* 1994; 17: 528–532
16. Ahlmen J, Andersen O, Hallgren G et al. Positive effects of tacrolimus in a case of CIDP. *Transplant Proc* 1998; 30: 4194.
17. Echaniz-Laguna A, Anheim M, Wolf P et al. Chronic inflammatory demyelinating polyradiculoneuropathy (CIDP) in patients with solid organ transplantation: a clinical, neurophysiological and neuropathological study of 4 cases. *Rev Neurol (Paris)* 2005; 161: 1213–1220
18. Bodkin CL, Eidelman BH. Sirolimus-induced posterior reversible encephalopathy. *Neurology* 2007; 68: 2039–2040
19. Molina MG, Diekmann F, Burgos D et al. Sympathetic dystrophy associated with sirolimus therapy. *Transplantation* 2008; 85: 290–292

Received for publication: 3.5.12; Accepted in revised form: 15.5.12