

This is an Open Access article licensed under the terms of the Creative Commons Attribution-NonCommercial-NoDerivs 3.0 License ([www.karger.com/OA-license](http://www.karger.com/OA-license)), applicable to the online version of the article only. Distribution for non-commercial purposes only.

# Recurrent Respiratory Papillomatosis: A Rare Chronic Disease, Difficult to Treat, with Potential to Lung Cancer Transformation: Apropos of Two Cases and a Brief Literature Review

Stamatis Katsenos · Heinrich D. Becker

Department of Interdisciplinary Endoscopy, Thoraxklinik at Heidelberg University, Heidelberg, Germany

## Key Words

Recurrent respiratory papillomatosis · Human papilloma virus · Interferon-alpha · Lung cancer

## Abstract

Recurrent respiratory papillomatosis (RRP), which is caused exclusively by human papilloma virus (HPV), is a rare condition characterized by recurrent growth of benign papillomata in the respiratory tract. The papillomata can occur anywhere in the aerodigestive tract but most frequently in the larynx, affecting both children and adults. The management of this entity remains still challenging since no specific definitive treatment exists. Nevertheless, novel surgical interventions as well as several adjuvant therapies have shown promising results in the long-term palliative management of this debilitating disease. Despite its mostly benign nature, RRP may cause significant morbidity and mortality because of its unpredictable clinical course and especially its tendency, albeit infrequent, for malignant transformation. In this article, we present two patients with RRP; one underwent bronchoscopic laser ablation in combination with inhaled interferon-alpha administration that led to a long-term regression of the disease while the other patient was diagnosed with transformation to squamous cell lung carcinoma with fatal outcome. We include a review of the current literature with special emphasis on RRP management and the potential role of HPV in the development of lung cancer.

## Introduction

Recurrent respiratory papillomatosis (RRP) is a rare disease in which multiple exophytic squamous wart-like lesions occur within the respiratory tract [1]. Although generally considered to be a pediatric disease, RRP frequently manifests itself in adulthood [2]. Human papilloma virus (HPV) is the causative agent of RRP. Out of more than 120 subtypes, viral subtypes 6 and 11 account for more than 90% of all RRP cases. HPV subtypes 16 and 18 have also been detected in papillomas, but are much less common [3].

The disease primarily involves the larynx, especially the vocal cords but also various extralaryngeal sites. The most frequent are, in decreasing order, oral cavity, trachea, bronchi, lung parenchyma and esophagus [4]. Despite its benign nature, RRP can bear considerable morbidity and mortality as lesions have a tendency to grow and extend throughout the entire respiratory tract causing severe airway obstruction, and they are also liable to recurrence after surgical resection. Additionally, in the rare case of malignant transformation, morbidity and mortality are increasing [5, 6]. The course of RRP varies; spontaneous remission is occasionally noted or the disease may maintain a stable state requiring only intermittent surgical procedures. In the majority of RRP cases, however, the disease takes a more aggressive course necessitating surgical treatment every few days to weeks and consideration of adjuvant medical therapy. The disease is a challenge for the treating physician, inflicts emotional encumbrance onto patients and families as well as causes great expenses to the healthcare systems [7, 8].

No specific treatment has hitherto been shown to be efficacious in eradicating RRP. However, progress has recently been made in the management, i.e. the development of new promising drugs. In this report, we describe two patients with RRP, one with successful long-term treatment, the other with lethal outcome, and review the recent knowledge about treatment and the potential link between HPV infection and lung cancer.

## Case Reports

### Case 1

The patient's history (a 41-year-old male, heavy smoker) dates back to December 1993, when he sought medical assistance because of progressive hoarseness, stridor and shortness of breath. He reported the onset of hoarseness in his early childhood without further examination or treatment. In addition, he mentioned atopy to several allergens, such as grass, pollen, pigeon feathers and wool. He was diagnosed with asthma and received medication with no substantial remission of the symptoms.

In November 1994, he was admitted to our department presenting with worsening hoarseness, dyspnea on exertion, stridor and cough with blood-streaked sputum. Chest examination revealed diffuse in- and expiratory wheezing. Otherwise the physical examination was unremarkable. Laboratory tests showed a slight increase of total IgE. Arterial blood gases were normal. Spirometry showed decreased FEV<sub>1</sub>, FVC, FEV<sub>1</sub>%, FEF<sub>25–75%</sub> and FIV<sub>1</sub> (63, 71, 75, 52 and 70% of predicted values); compatible with intra- and extrathoracic obstruction. Computed tomography showed multiple polypoid formations throughout the larynx and in the upper third and mid-trachea. No lesions were noted in the lung parenchyma.

Indirect laryngoscopy showed laryngeal papillomas on the vocal cords interfering with vocal cord closure during phonation. Fiberoptic bronchoscopy revealed multiple polypoid papillomas in the upper

two thirds of the trachea resulting in significant obstruction ([fig. 1a](#)). Biopsy confirmed the diagnosis of laryngotracheal papillomatosis. Molecular testing using polymerase chain reaction (PCR) identified HPV types 6 and 11 in papilloma tissue.

Surgical removal of the papillomata was performed by carbon dioxide (CO<sub>2</sub>) and neodymium-yttrium aluminum garnet (Nd:YAG) laser for the laryngeal and tracheal papillomata, respectively. The patient achieved partial response. But the rate of papilloma recurrence accelerated, necessitating monthly bronchoscopic laser vaporization of the lesions. From March 1995, adjuvant medical treatment was started in an attempt to control papilloma regrowth by daily inhalation of nebulized interferon-alpha (3 MU/m<sup>2</sup> of body surface) in combination with isotretinoin (40 mg p.o. per day for two months, then escalated to 80 mg/day). In addition, intralesional injection of interferon-alpha (2.5 MU/m<sup>2</sup> of body surface) at the anterior commissure was performed. Four months later, isotretinoin was discontinued because of side effects. Inhaled interferon-alpha was continued for 28 months.

This regimen led to increased intervals for resection and finally complete disappearance of the tracheal papillomas and substantial regression of the laryngeal lesions. At present, 13 years after the cessation of adjuvant therapy, the disease still remains in remission without regrowth of papillomas in the trachea and only a small residual papilloma at the anterior commissure ([fig. 1b, c](#)). Spirometry parameters are normalized (FEV1: 86%, FVC: 85%, FEF25–75%: 80%, FIV1: 96% of predicted values). The patient's voice has also been improved and laser treatment is only done at a yearly routine visit compared to one every month before combined therapy.

#### Case 2

A 27-year-old female was admitted in March 1989 with a mass in the right upper lobe and an ill-defined opacity in the left upper lobe associated with mediastinal widening ([fig. 2a, b](#)). Since infancy, she suffered from persistent hoarseness and she was diagnosed with laryngeal papillomatosis at nine months of age. She had undergone annual surgical excisions of the papillomas. There was no information regarding maternal genital HPV infection. Already two years prior to referral, chest X-ray had shown a lesion in the right upper lobe. A clinical diagnosis of pneumonia had been made and the patient had received several courses of antibiotics but the lesion was growing. Fiberoptic bronchoscopy revealed typical papillomas in the larynx and trachea and an exophytic mass obstructing the right upper lobe ([fig. 2c, d](#)). Biopsies from laryngotracheal lesions confirmed papillomatosis, whereas the occluding mass was a well-differentiated squamous cell carcinoma. HPV serotypes 6 and 11 were detected in biopsies from the papillomata by virological examination. The patient received radiotherapy with no response. Then, she underwent radical right upper lobectomy with mediastinal lymph node dissection as well as resection of the contralateral tumor. Dot blot hybridization with radioactive marked oligonucleotide probes on postoperative specimens showed infection with HPV 11 exclusively in carcinoma tissue, metastasis, papillomas and metaplastic tissue by PCR. However, all specimens from normal bronchial mucosa and normal lung tissue were negative [9]. Shortly after surgery the patient died from septic shock.

#### Discussion

RRP is a rare condition characterized by the presence of benign papillomatous (wart-like) growths within the respiratory tract [1]. Its incidence is estimated at 2 per 100,000 in adults and 4 per 100,000 in children [1, 10]. The disease presents in 2 forms according to the age at onset. Juvenile RRP occurs in patients under 5 years, with 25% of the cases presenting during infancy [11]. The first presentation in adults is usually in the third and fourth decade of life. The juvenile form is considered to be more aggressive than the adult type, although severe cases of RRP can occur in adults [1, 12]. We assume that an infection with more aggressive HPV strains results in faster proliferation of papillomas and an earlier onset of symptoms.

It is well-documented that HPV is the causative agent of RRP [3]. Vertical transmission of the virus during gestation or during delivery is considered to be the major route of contracting the disease in children. The risk is thought to be higher in women with overt anogenital warts or disease from a recent HPV infection at the time of delivery [13]. The majority of patients with juvenile papillomatosis are vaginally delivered, first-born children of HPV-infected teenage mothers compared to controls, representing a clinical triad that has been determined as a predisposing risk factor for RRP [14]. In adults, the infection is generally agreed to represent either a reactivation of a slowly progressing latent HPV infection or a newly acquired sexually transmitted disease following oral-genital contact.

According to DNA studies, 130 different HPV types have been identified, classified into low- and high-risk types in their potential for malignant degeneration. Low-risk types 6 and 11 are almost universally involved in RRP. The same types are strongly associated with genital warts. HPV high-risk types 16, 18, 31 and 33 have rarely been described in RRP [3, 15]. Patients infected by type 11 develop more aggressive disease (e.g. significant airway obstruction), requiring frequent surgical procedures and adjuvant medical therapies, sometimes even tracheotomy to keep the airway patent [16]. HPV has a predilection for the stratified epithelium of either the cutaneous or mucosal surface. RRP is induced by HPV stem cell infection (principally keratinocyte) within the basal layer of airway mucosa [17]. HPV can activate the epidermal growth factor receptor (EGFR) pathway and inactivate several tumor-suppressor proteins, thus leading to cellular proliferation and defective epithelial differentiation [18]. These mechanisms eventually result in 'cauliflower-like' exophytic growths, the typical RRP lesions. They occur most commonly in anatomical areas where squamous epithelium is adjacent to ciliated columnar epithelium. Therefore, the major anatomic sites for RRP are the vestibule of the nose, the nasopharyngeal surface of the soft palate, the midline of the laryngeal surface of the epiglottis, the upper and lower margins of the laryngeal ventricle, the lower surface of the vocal folds, the carina and upper trachea (especially at tracheostomy sites). In addition, distal tracheal spread extending into the bronchi and pulmonary parenchyma has been observed [4].

Patients with RRP usually present with symptoms of airway involvement. Progressive hoarseness, stridor, dyspnea or acute respiratory distress and chronic cough are most frequent. However, the disease is easily misdiagnosed as asthma (as in our first patient), croup, chronic bronchitis and vocal nodules further delaying its definitive diagnosis and treatment [1, 11, 19]. The average time from onset of the symptoms to diagnosis ranges from 1 to 8 years [2].

Although basically benign, RRP causes significant morbidity and occasional mortality due to recurrence and spread throughout the respiratory tract, requiring frequent operations in cases of severe exacerbation. The natural history of RRP is quite variable including spontaneous regression, persistence and dissemination of lesions causing airway compromise and in rare instances progression to carcinoma. This unpredictable course is a challenge for the clinician.

Therapeutic goals in the treatment of RRP include papilloma reduction, restoration of airway patency, amelioration of symptoms, prevention of disease spread and decrease in hospitalization for interventions [5, 17]. Although currently there is still no definite curative treatment in eradicating RRP, surgery remains the mainstay of treatment. The

aim is to remove papillomatous lesions as radically as possible to maintain a safe airway and functional phonation without damaging normal structures that would lead to complications such as dysphonia, excessive airway scarring and stenosis. Various techniques and instruments have been used to minimize the complications of surgery, including endoscopic debulking with microdebriders, excision with phonosurgical instruments and laser ablation. The preferred methods are resection using CO<sub>2</sub>, Nd:YAG laser, pulse-dye laser and endoscopic microdebrider. Surgical treatment is relatively safe and effective for the management of RRP [20]. Despite successful removal, recurrence after surgery is common. Persistence of HPV genome within the tissue adjacent to lesions has been proposed as the main cause [21]. However, in our second case with cancer transformation, no HPV was found in adjacent normal mucosa, suggesting why in the first case radical local resection resulted in complete remission.

Roughly, 20% of patients with RRP require adjunctive medical treatment in addition to surgery to control the disease. The current criteria for adjuvant therapy are the necessity for more than 4 surgical procedures annually, rapid regrowth of papillomata with airway compromise and/or remote multisite spread of the disease [11, 17]. The majority of treatments focus on immunomodulation, disruption of molecular signaling cascades or HPV replication resulting in apoptosis, inhibition of proliferation, growth arrest and/or promotion of normal differentiation in HPV-infected cells. The list includes antiviral agents (acyclovir, ribavirin, cidofovir), interferon, retinoids (oral metabolites or analogues of vitamin A), photodynamic therapy, zinc, anti-reflux medications, cyclooxygenase-2 inhibitors, therapeutic/preventive vaccines (mumps vaccine, quadrivalent HPV vaccine, heat shock protein E7) and gene therapy (EGFR tyrosine kinase inhibitors) [22]. However, most therapies have been described only in small series or as anecdotal case reports showing some benefit but have not adequately been evaluated in powered randomized controlled trials to provide sufficient evidence for their consideration in RRP treatment.

The most extensively investigated adjuvant therapy is interferon-alpha. Several studies have demonstrated its positive influence on outcome of patients. Leventhal and coworkers [23] showed that continuous application of interferon-alpha (median duration 18 months) achieved a good response in 47 of 60 patients with RRP (22 complete and 25 partial remissions). They suggest a 6-month trial of interferon-alpha initially. If there is no response after 6 months, treatment should be discontinued. With partial response and tolerable toxicity, continued treatment is justified. With complete remission, treatment should end. Gerein et al. [24] reported higher efficacy of interferon in RRP patients with HPV 6 as compared with HPV 11. Szeps et al. [25] observed better response in HPV 6 disease without difference in viral load and hyperproliferation of HPV-infected epithelium after treatment. In two recent studies, the beneficial effect of prolonged use of interferon-alpha in patients with RRP has been reported reducing the number of required laser therapy sessions drastically [26, 27]. However, it appears that interferon does not significantly modify the course of RRP when lung involvement occurs [6]. Drug toxicity should be monitored although it can be minimized by administering injections at bedtime and using preparations produced by recombinant DNA techniques.

The first patient in the present study had complete remission 13 years after interferon-alpha cessation. The drug was administered by daily inhalation continuously for a total of 28 months in an attempt to avoid its systemic side effects that would hinder the completion of our treatment strategy. We believe that our patient's favorable clinical

course is due to this continuous and prolonged use of interferon-alpha, according to the observations in Leventhal et al.'s study [23].

The most recent antiviral agent that has been added in RRP treatment is cidofovir. It seems to be effective in improving the outcome of patients with RRP although concerns have been raised about its safety profile (e.g. oncogenic potential) [17]. However, a recent study showed no cidofovir-induced dysplastic changes in HPV-infected epithelium, it has been recommended that the drug should be considered as a treatment option in patients with severe refractory disease [28].

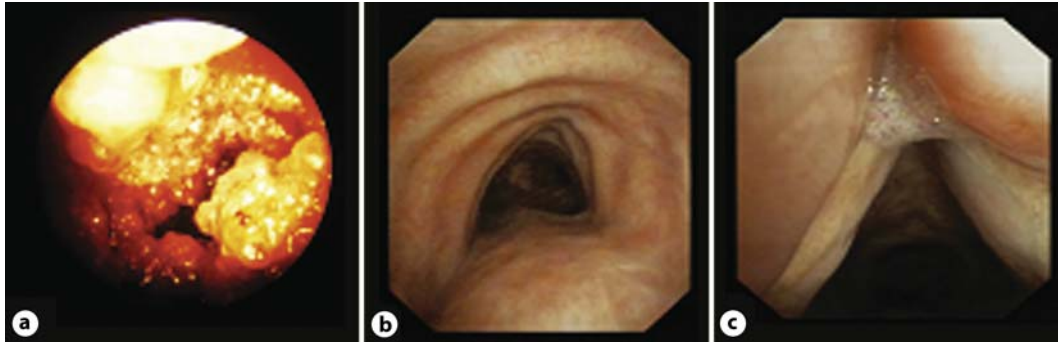
RRP has the potential for malignant transformation to squamous lung cell carcinoma with a dismal prognosis [5, 6]. Malignant degeneration is a rare complication and the incidence varies among series. In juvenile RRP, Derkay [29] reported a transformation rate of <1%, while in adults a rate of 3–7% has been described [3]. Data from clinical cases indicate that HPV 11 is associated with a greater risk of producing lung cancer than HPV 6, as was the case in our second patient, although rarely HPV 6 can cause bronchial carcinomas [30]. Risk factors for malignant transformation in RRP include smoking, prior irradiation and HPV type itself. From the history of the second case in our study we inferred that the patient was a non-smoker and has had no exposure to radiation prior to her admission, thus implying that HPV was the only factor for lung cancer development.

The precise pathogenesis of malignant transformation in RRP remains elusive. However, it has been proposed that HPV exerts its oncogenic power through interfering with the cell-cycle. Especially, its oncoproteins E6 and E7 seem to play a key role in carcinogenesis, as they promote rapid degradation of tumor suppressor proteins (p53 and pRB-retinoblastoma) thus interfering with cell growth control [3]. Not enough data are available on the development of mutations and progression to lung cancer in RRP patients due to the limited number of patients with lung involvement and lack of HPV typing. Nevertheless, molecular studies have confirmed the above-mentioned hypothesis, demonstrating that p53 protein mutation or overexpression in the malignant lung tissue samples from patients with RRP may result in progressive genetic instability which ultimately leads to lung cancer [31–34].

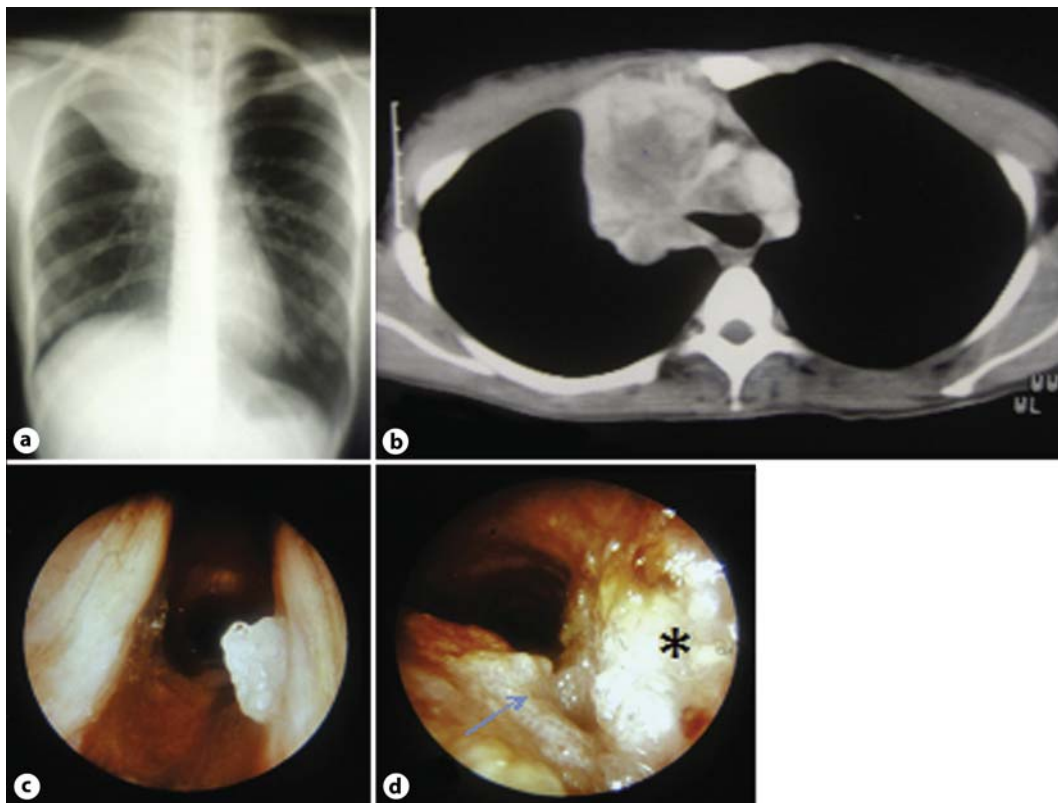
High-risk HPV are the principal causative agents for cervical malignancies, as has clearly been shown in the pioneer studies by zur Hausen [35]. They are found in almost 100% of all cervical cancer cases. In the early 1980s, Syrjanen [36] first described morphological changes in bronchial squamous cell carcinomas quite identical to those seen in genital HPV lesions, thus leading to the assumption that HPV could play a role in lung carcinogenesis. Since then, there is accumulating evidence implicating an association between HPV infection and bronchial cancer given that the well-known risk factors of lung cancer (e.g. smoking, occupational exposure, air pollution) cannot explain all lung cancer cases [37]. HPV DNA has been found in approximately 20% of all lung cancer cases investigated to date, with HPV types 16 and 18 most frequently detected. HPV integration itself cannot fully explain an active role of the virus in carcinogenesis without formation of papillomas. A recent study showed the presence of E6 and E7 oncogenes and their transcripts in HPV-positive lung cancer cases that are prerequisite for cancer development, thus reinforcing further the hypothesis that HPV could be a co-factor in bronchial carcinogenesis [38].

In conclusion, RRP is a relatively rare disease that can cause life-threatening airway compromise. Its recurrent nature and numerous palliative treatments have a tremendous

influence on patients' quality of life. Clinicians should be aware of the disease to make an early diagnosis that is pivotal for the patients' clinical outcome. In addition, because of the tendency for recurrences and malignant transformation, meticulous follow-up of patients including HPV typing is indispensable for early detection and treatment.



**Fig. 1.** Bronchoscopy showing multiple polypoid papillomas in the upper two thirds of the trachea (a). Bronchoscopy demonstrating disease remission 13 years after the cessation of interferon-alpha treatment; disappearance of tracheal papillomas (b) and a small residual papilloma at the anterior commissure (c).



**Fig. 2.** Chest X-ray and computed tomography showing a mass in the right upper lobe associated with mediastinal widening (**a**, **b**). Fiberoptic bronchoscopy revealing typical papillomas in the larynx (**c**) and trachea (**d**, arrow) and an exophytic mass obstructing the right upper lobe (**d**, asterisk).

## References

- 1 Goon P, Sonnec C, Jani P, Stanley M, Sudhoff H: Recurrent respiratory papillomatosis: an overview of current thinking and treatment. *Eur Arch Otorhinolaryngol* 2008;265:147–151.
- 2 Alkotob ML, Budev MM, Mehta AC: Recurrent respiratory papillomatosis. *J Bronchol Intervent Pulmonol* 2004;11:132–139.
- 3 Donne AJ, Hampson L, Homer JJ, Hampson IN: The role of HPV type in recurrent respiratory papillomatosis. *Int J Pediatr Otorhinolaryngol* 2010;74:7–14.
- 4 Kashima H, Mounts P, Leventhal B, Hruban RH: Sites of predilection in recurrent respiratory papillomatosis. *Ann Otol Rhinol Laryngol* 1993;102:580–583.
- 5 Gallagher TQ, Derkay CS: Recurrent respiratory papillomatosis: update 2008. *Curr Opin Otolaryngol Head Neck Surg* 2008;16:536–542.
- 6 Gelinas JF, Manoukian J, Cote A: Lung involvement in juvenile onset recurrent respiratory papillomatosis: a systematic review of the literature. *Int J Pediatr Otorhinolaryngol* 2008;72:433–452.
- 7 Lindman JP, Lewis LS, Accortt N, Wiatrak BJ: Use of the Pediatric Quality of Life Inventory to assess the health-related quality of life in children with recurrent respiratory papillomatosis. *Ann Otol Rhinol Laryngol* 2005;114:499–503.
- 8 Bishai D, Kashima H, Shah K: The cost of juvenile-onset recurrent respiratory papillomatosis. *Arch Otolaryngol Head Neck Surg* 2000;126:935–939.



- 9 Eberlein-Gonska M, Gaweco A, Becker HD: Humanes Papillomavirus (HPV) Typ 11 bei juveniler Papillomatose des Laryngo-Tracheo-Bronchialsystems mit Entwicklung eines Plattenepithelkarzinoms. Untersuchungen auf der DANN-Ebene mittels der Polymerase-Chain-Reaction (PCR). *Verh Dtsch Ges Path* 1991;75:471.
- 10 Reeves WC, Ruparella SS, Swanson KI, Derkay CS, Marcus A, Unger ER: National registry for juvenile-onset recurrent respiratory papillomatosis. *Arch Otolaryngol Head Neck Surg* 2003;129:976–982.
- 11 Stamataki S, Nikolopoulos TP, Korres S, Felekis D, Tsangaroulakis A, Ferekidis E: Juvenile recurrent respiratory papillomatosis: still a mystery disease with difficult management. *Head Neck* 2007;29:155–162.
- 12 Leung R, Hawkes M, Campisi P: Severity of juvenile onset recurrent respiratory papillomatosis is not associated with socioeconomic status in a setting of universal healthcare. *Int J Pediatr Otorhinolaryngol* 2007;71:965–972.
- 13 Silverberg MJ, Thorsen P, Lindeberg H, Grant LA, Shah KV: Condyloma in pregnancy is strongly predictive of juvenile-onset recurrent respiratory papillomatosis. *Obstet Gynecol* 2003;101:645–652.
- 14 Kashima HK, Shah FK, Lyles A: A comparison of risk factors in juvenile-onset and adult-onset recurrent respiratory papillomatosis. *Laryngoscope* 1992;102:9–13.
- 15 Draganov P, Todorov S, Todorov I: Identification of HPV DNA in patients with juvenile-onset recurrent respiratory papillomatosis using SYBR Green real-time PCR. *Int J Pediatr Otorhinolaryngol* 2006;70:469–473.
- 16 Wiatrak BJ, Wiatrak DW, Broker TR, Lewis L: Recurrent respiratory papillomatosis: a longitudinal study comparing severity associated with human papilloma viral types 6 and 11 and other risk factors in a large pediatric population. *Laryngoscope* 2004;114:1–23.
- 17 Derkay CS, Wiatrak B: Recurrent respiratory papillomatosis: a review. *Laryngoscope* 2008;118:1236–1247.
- 18 Vambutas A, DiLorenzo TP, Steinberg BM: Laryngeal papilloma cells have high levels of epidermal growth factor receptor and respond to epidermal growth factor by a decrease in epithelial differentiation. *Cancer Res* 1993;53:910–914.
- 19 Xue Q, Wang H, Wang J: Recurrent respiratory papillomatosis: an overview. *Eur J Clin Microbiol Infect Dis* 2010;29:1051–1054.
- 20 Johnson K, Derkay C: Palliative aspects of recurrent respiratory papillomatosis. *Otolaryngol Clin N Am* 2009;42:57–70.
- 21 Pignatari S, Smith EM, Gray SD: Detection of human papillomavirus infection in diseased and nondiseased sites of the respiratory tract in recurrent respiratory papillomatosis patients by DNA hybridization. *Ann Otol Rhinol Laryngol* 1992;101:408–412.
- 22 Gallagher TQ, Derkay CS: Pharmacotherapy of recurrent respiratory papillomatosis: an expert opinion. *Expert Opin Pharmacother* 2009;10:645–655.
- 23 Leventhal BG, Kashima HK, Mounts P: Long-term response of recurrent respiratory papillomatosis to treatment with lymphoblastoid interferon-alfa-N1. Papilloma study Group. *N Engl J Med* 1991;325:613–617.
- 24 Gerein V, Rastorguev E, Gerein J, Jecker P, Pfister H: Use of interferon-alpha in recurrent respiratory papillomatosis: 20-year follow-up. *Ann Otol Rhinol Laryngol* 2005;114:463–471.
- 25 Szeps M, Dahlgren L, Aaltonen LM: Human papillomavirus, viral load and proliferation rate in recurrent respiratory papillomatosis in response to alpha interferon treatment. *J Gen Virol* 2005;86:1695–1702.
- 26 Nodarse-Cuni H, Iznaga-Marin N, Viera-Alvarez D: Interferon alpha-2b as adjuvant treatment of recurrent respiratory papillomatosis in Cuba: National Programme (1994–1999 report). *J Laryngol Otol* 2004;118:681–687.
- 27 Hae-Seong N, Won-Jung K, Gee-Young S: Efficacy of long-term interferon-alpha therapy in adult patients with recurrent respiratory papillomatosis. *Tuberculosis and Respiratory Diseases* 2008;65:390–395.
- 28 Sajan JA, Kerschner JE, Merati AL: Prevalence of dysplasia in juvenile-onset recurrent respiratory papillomatosis. *Arch Otolaryngol Head Neck Surg* 2010;136:7–11.
- 29 Derkay CS: Task force on recurrent respiratory papillomas. A preliminary report. *Arch Otolaryngol Head Neck Surg* 1995;121:1386–1391.
- 30 DiLorenzo TP, Tamsen A, Abramson AL, Steinberg BM: Human papillomavirus type 6a DNA in the lung carcinoma of a patient with recurrent laryngeal papillomatosis is characterized by a partial duplication. *J Gen Virol* 1992;73:423–428.
- 31 Rady PL, Schnadig VJ, Weiss RL: Malignant transformation of recurrent respiratory papillomatosis associated with integrated human papillomavirus type 11 DNA and mutation of p53. *Laryngoscope* 1998;108:735–740.
- 32 Reidy PM, Dedo HH, Rabah R: Integration of human papillomavirus type 11 in recurrent respiratory papilloma-associated cancer. *Laryngoscope* 2004;114:1906–1909.
- 33 Lele SM, Pou AM, Ventura K: Molecular events in the progression of recurrent respiratory papillomatosis to carcinoma. *Arch Pathol Lab Med* 2002;126:1184–1188.

- 34 Go C, Schwartz MR, Donovan DT: Molecular transformation of recurrent respiratory papillomatosis: viral typing and p53 overexpression. *Ann Otol Rhinol Laryngol* 2003;112:298–302.
- 35 zur Hausen H: Papillomaviruses and cancer: from basic studies to clinical application. *Nature Rev Cancer* 2002;2:342–350.
- 36 Syrjanen KJ: Epithelial lesions suggestive of a condylomatous origin found closely associated with invasive bronchial squamous cell carcinomas. *Respiration* 1980;40:150–160.
- 37 Li YJ, Tsai YC, Chen YC, Christiani DC: Human papilloma virus and female lung adenocarcinoma. *Semin Oncol* 2009;36:542–552.
- 38 Giuliani L, Favalli C, Syrjanen K, Ciotti M: Human papillomavirus infection in lung cancer. Detection of E6 and E7 transcripts and review of the literature. *Anticancer Res* 2007;27:2697–2704.