

Pyoderma gangrenosum in a patient with chronic granulomatous disease

A case report

Sideris Nanoudis, MD*, Afroditi Tsona, MD, PhD, Olga Tsachouridou, MD, PhD, Petros Morfesis, MD, Georgia Loli, MD, Adamantini Georgiou, MD, Pantelis Zebekakis, MD, PhD, Symeon Metallidis, MD, PhD

Abstract

Rationale: The simultaneous occurrence of pyoderma gangrenosum (PG) and chronic granulomatous disease (CGD) is uncommon and few cases have been reported worldwide.

Patient concerns: PG is a rare, chronic, ulcerative, neutrophilic skin disease of unknown etiology that requires immunosuppressive treatment. CGD belongs to Primary Immune Deficiencies in which the main defect lies in an inability of the phagocytic cells to generate superoxide making patients susceptible to serious, potentially life-threatening bacterial and fungal infections.

Diagnoses: In this manuscript, we present a case of ulcerative pyoderma gangrenosum in a 28-year-old man with recent diagnosis of chronic granulomatous disease during hospitalization for resistant pulmonary tuberculosis complicated with *Aspergillus* infection.

Interventions: Second-line therapy with dapsons and intravenous immunoglobulin was initially administered but eventually corticosteroids were added to treatment because of disease progression and further ulceration.

Outcomes: Patient's ulcers were gradually healed with no side effects.

Lessons: Corticosteroids could be used under close monitoring for the treatment of PG in a patient with CGD, despite the increased risk for infections.

Abbreviations: ANA = antinuclear antibody, ANCA = antineutrophilic cytoplasmic antibody, BCG = Bacillus Calmette Guerin, CGD = chronic granulomatous disease, CRP = C-reactive protein, CT = computed tomography, DHR = dihydrorhodamine, ESR = erythrocyte sedimentation rate, Hb = Hemoglobin, IVIG = intravenous immunoglobulin, NADPH = nicotinamide adenine dinucleotide phosphate, PG = pyoderma gangrenosum, RF = rheumatoid factor.

Keywords: Pyoderma gangrenosum, Chronic granulomatous disease, Primary immunodeficiency

1. Introduction

Pyoderma gangrenosum (PG) is an idiopathic, ulcerative, neutrophilic, non-infective chronic inflammatory dermatitis of low frequency (10 per 1,000,000 individuals) that requires corticosteroids and immunosuppressive treatment.^[1–3] On the other hand, chronic granulomatous disease (CGD) is a rare (8 per 1,000,000 individuals), inherited disorder of the immune system characterized by an inability of the phagocytic cells (neutrophils, monocytes, and macrophages) to produce superoxides. As a result, these patients suffer from recurrent infections, often of unusual pathogens or of unusual severity and frequency and should take

lifelong antibacterial and antifungal prophylaxis.^[4–6] The simultaneous coexistence of both diseases has been reported only a few times in literature^[7–10] and, furthermore, imposes cautious management of PG, due to the underlying pathophysiology.

2. Patient information

A 28-year-old Caucasian man, former intravenous drug user, was admitted to our Internal Medicine Department, because of 2 ulcerative cutaneous lesions (indicative of pyoderma gangrenosum), 1 on the right thigh (about a year old) and a 2nd one on the right forearm (3 months old) (Figs. 1 and 2). A 3rd lesion was also present on the left forearm resembling to furuncle erupted a week ago (Fig. 3). The patient was diagnosed with CGD only 2 years ago, during a hospitalization for resistant, miliary tuberculosis complicated with *Aspergillus* pulmonary infection. Dihydrorhodamine (DHR) flow cytometry was initially used to detect reduced superoxide production of stimulated neutrophils, followed by molecular mutation analysis which revealed a defect in p47^{phox} component of nicotinamide adenine dinucleotide phosphate (NADPH) oxidase. He received a total of 18 months of antituberculosis treatment consisted of 7 agents (isoniazid, rifampicin, ethambutol, pyrazinamide, levofloxacin, amikacin, and cycloserine) which was completed 3 months before his first admission to our department. Bacillus Calmette Guerin (BCG) vaccine was administered at the age of 6, but no evidence of local or disseminated complications indicative of BCG infection due to the underlying CGD were mentioned.^[11–13] His rest medical history consists of recurrent infections throughout childhood,

Editor: Dan Lipsker.

Written informed consent was given by the patient.

Authors have no conflicts of interest to disclose.

1st Department of Internal Medicine, AHEPA University Hospital, Aristotle University of Thessaloniki, Thessaloniki, Greece.

* Correspondence: Sideris Nanoudis, 1st Department of Internal Medicine, AHEPA University Hospital, Aristotle University of Thessaloniki, 1 St. Kyriakidi Street, 54636, Thessaloniki, Greece (e-mail: sidnanoudis@yahoo.gr).

Copyright © 2017 the Author(s). Published by Wolters Kluwer Health, Inc. This is an open access article distributed under the Creative Commons Attribution-ShareAlike License 4.0, which allows others to remix, tweak, and build upon the work, even for commercial purposes, as long as the author is credited and the new creations are licensed under the identical terms.

Medicine (2017) 96:31(e7718)

Received: 10 March 2017 / Received in final form: 4 July 2017 / Accepted: 6 July 2017

<http://dx.doi.org/10.1097/MD.0000000000007718>

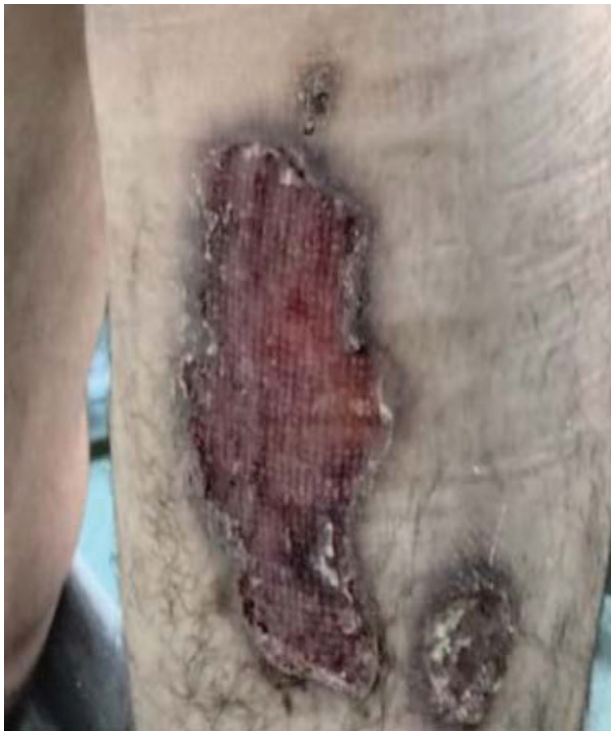

Figure 1. Pyoderma gangrenosum on the right thigh (12 months old).

adolescence, and adulthood including meningitis at the age of 9, respiratory and urinary tract infections, *Staphylococcus* skin infections and inactive chronic hepatitis C with undetectable HCV viral load (VL below 15 IU/mL). Conversely, there was no

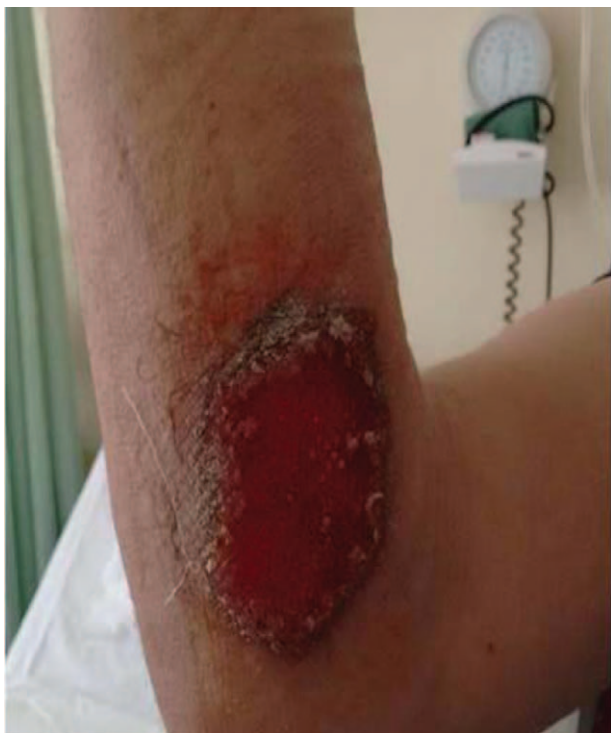

Figure 2. Pyoderma gangrenosum on the right forearm (3 months old).

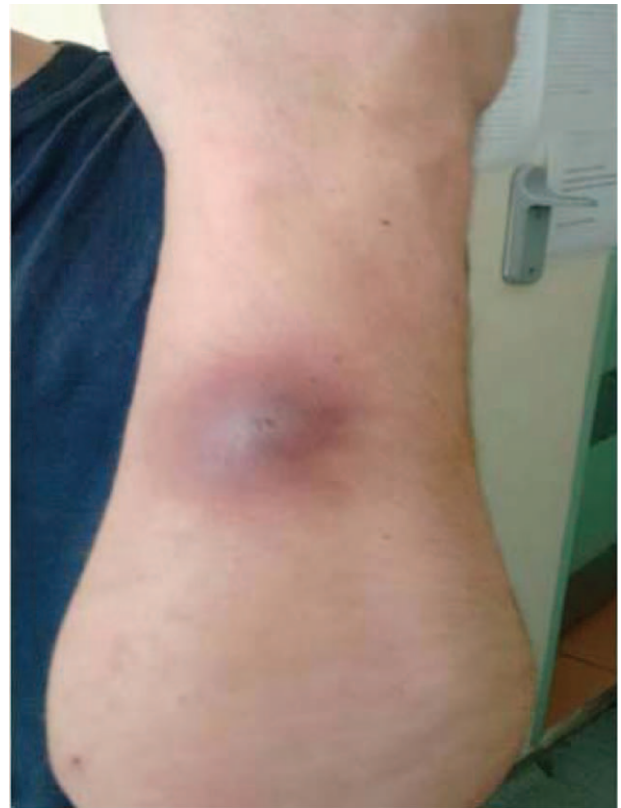

Figure 3. Cutaneous lesion, resembling a furuncle, on the left forearm appeared a week ago.

family history of CGD and patient's parents as well as his sister did not suffer from severe or frequent infections.

2.1. Clinical findings

Physical examination revealed no pathological signs. The patient, apart from the cutaneous lesions, was asymptomatic and afebrile. Interestingly, a pathergy sign was positive on the right thigh as satellites lesions proximal to the primary skin lesion appeared after accidental injury. His blood pressure was 120/75 mmHg and pulse rate 75 beats per minute. Oxygen saturation was also normal.

2.2. Diagnostic assessment

The laboratory tests revealed a moderate microcytic, hypochromic anemia (Hb 9.5 g/dL), C-reactive protein (CRP) level of 4 mg/dL (normal range 0–0.8 mg/dL), and erythrocyte sedimentation rate (ESR) level of 50 mm/h (normal range <15 mm/h). On the other hand, rheumatoid factor (RF), antinuclear antibody (ANA), antineutrophilic cytoplasmic antibody (ANCA), anti-phospholipid antibody, and test for cryoglobulins were all negative. Triplex ultrasound revealed no venous or arterial thrombosis while computed tomography (CT) of thorax and abdomen confirmed merely slight hepatosplenomegaly. Ulcer cultures derived from skin biopsy were negative for common bacteria, fungus, *Mycobacterium tuberculosis*, and atypical mycobacterium. Moreover, histological findings were indicative of pyoderma gangrenosum characterized by epidermal ulceration and granulomatous inflammation consisting of neutrophils,

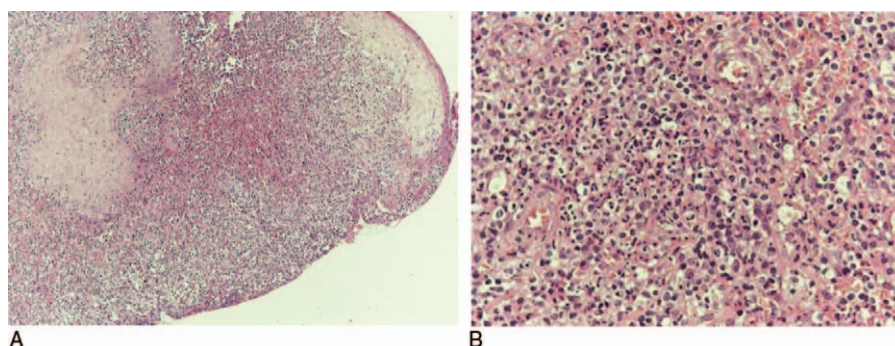


Figure 4. (A, B): Skin biopsy presenting epidermal ulceration with exudation and inflammatory granulomatous tissue (A), having areas with central abscess formation, surrounded by granulomatous inflammation (B) (A: HE $\times 100$, B: HE $\times 400$).

lymphocytes, and plasma cells, and, also, excluded vasculitis and cancer. In addition, Periodic acid–Schiff (PAS) stain did not show any evidence of fungal infection (Fig. 4).

2.3. Therapeutic intervention

High dose corticosteroids are usually the first line systemic therapy for PG. Cyclosporine A is added as a steroid sparing agent or because of incomplete response to corticosteroids.^[14–16] However, in our case, due to the underlying CGD and the recent medical history of miliary tuberculosis accompanied with *Aspergillus* infection it was decided to administer a second line combination therapy with dapsone 100 mg twice a day and 6 courses of 2-day administration of intravenous immunoglobulin (IVIG) of 1 g/kg/d monthly, along with local wound care. Itraconazole 300 mg per day and Sulfamethoxazole/Trimethoprim 800/160 mg once a day were also added as a prophylaxis for the CGD. One month later, not only no improvement was marked, but also the lesion on the left forearm had progressed to a third ulcer (Fig. 5A and B). Upon being informed of the potential risks of his decision, the patient consented to escalate his therapy by adding corticosteroids with close clinical and

laboratory observation. Initially, intravenous pulse methylprednisolone 1 g/d was administered for 5 days and after that, oral methylprednisolone 16 mg twice a day which was tapered 4 mg every 4 days. The remaining dose of methylprednisolone was 4 mg every 2 days while simultaneous treatment with dapsone 100 mg twice a day and 2-day IVIG 1 g/kg/d monthly was continued.

2.4. Follow-up and outcomes

The patient's condition gradually improved, with the lesions being healed over time 3 months after the administration of methylprednisolone (Fig. 6A, B, C). Blood tests were also improved with increase of hemoglobin and restoration of inflammatory markers (Hb 11.7 g/dL, CRP 0.1 mg/dL, and ESR 5 mm/h) while the patient had no sign of infection or other side effect from the corticosteroid treatment.

3. Discussion

Pyoderma gangrenosum is a chronic, ulcerative, non-infective, neutrophilic skin disorder of unknown etiology.^[1–3] Cutaneous lesions usually begin as pustule or vesiculopustule and progress to an ulcer or deep erosion^[2,22] (in our patient, however, they began as a furuncle). Apart from the classic ulcerative PG, there are, also, other clinical variants, such as pustular PG, bullous PG, vegetative PG, and peristomal PG.^[1–2,14,16,17] Diagnosis is mainly clinical and derives from exclusion of other causes of cutaneous ulceration.^[1–3,14] On the other hand, cutaneous manifestations of CGD, apart from skin infections, include discoid lupus erythematosus-like lesions, photosensitive rashes, and aphthous ulceration (they are, also, common in X-linked female carriers) as well as seborrheic dermatitis, vesicular lesions, and facial granulomata.^[4,6,18–21] In our case, however, there was a higher suspicion of PG, but due to the underlying CGD, a skin infection had to be excluded. Cultures from the lesions and all the microbiological and blood tests were negative for infection, while laboratory screening for vasculitis, thrombophilic states, and vascular insufficiency were, also, negative. Finally, the biopsy was indicative of pyoderma gangrenosum and excluded vasculitis and cancer. PG is associated with systemic illnesses in half of the cases and the most common are inflammatory bowel disease, rheumatoid arthritis, systemic lupus erythematosus, hematologic diseases, and solid tumors, all of which were excluded in our patient during the diagnosis process.^[2,3,15]

Both differences and similarities in the pathophysiology of those two diseases are extremely interesting, since as already

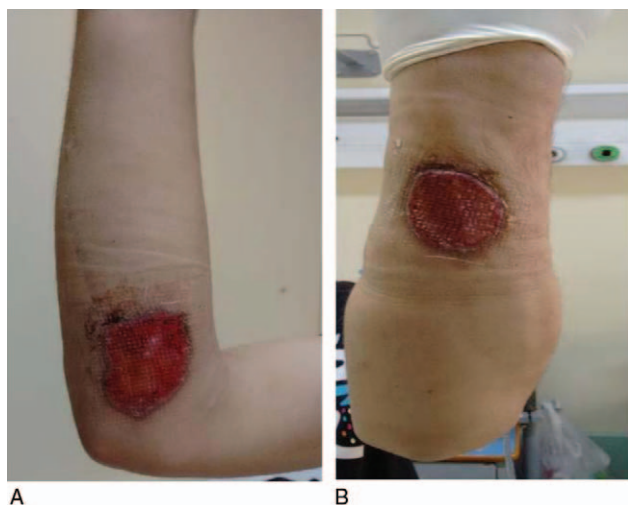


Figure 5. (A, B): After 1 month of treatment with dapsone and intravenous immunoglobulin no improvement was noticed on the right forearm (A) and the lesion on the left forearm (B), also, progressed to ulcerative pyoderma gangrenosum.

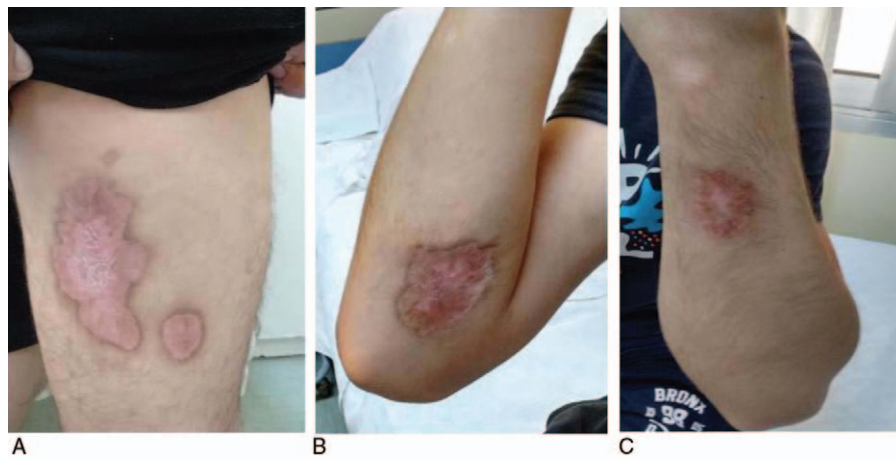


Figure 6. (A, B, C): All 3 lesions were healed 3 months after adding methylprednisolone to treatment.

mentioned PG is a neutrophilic dermatitis while, on the contrary, CGD's main defect lies in phagocytic cells (neutrophils, monocytes, and macrophages).^[2,4] More precisely, neutrophils from CGD patients fail to exhibit a respiratory burst and produce superoxides due to the absence of 1 of the components of NADPH oxidase,^[4-6] which in our patient was p47^{phox}. Affected individuals are, therefore, susceptible to severe, potentially life-threatening bacterial and fungal infections (especially from *Staphylococcus aureus* and *Aspergillus* spp).^[4-6,23-25] Nevertheless, apart from the inability to produce superoxides, phagocytic cells maintain other functions, like activation from cytokines, chemotaxis, and the ability to infiltrate tissues as well as normal formation of other hydrolytic enzymes in the phagosome.^[26-29] This fact could explain the coexistence of both diseases in our patient. On the other hand, pathophysiology of PG is poorly understood but neutrophilic dysfunction seems to play significant role, including altered neutrophil chemotaxis and defects in phagocytosis and host defense against bacterial infections.^[30,31] Furthermore, abnormal leucocyte trafficking and disorganized NADPH oscillations with numerous frequencies are described in neutrophils from patients with PG, compared with sinusoidal metabolic oscillations of healthy individuals, increasing neutrophilic infiltration.^[32] However, it is ambiguous whether the neutrophilic dysfunction in PG is primary or secondary to other causes, such as inflammasome activation and overexpression of proinflammatory mediators, such as TNF- α , IL-1 β , and IL-8.^[30]

Mutations in p47^{phox} component of NADPH is an autosomal recessive inherited form of CGD and accounts for 25% of all cases.^[4-6] Autosomal recessive inherited CGD is considered to have better prognosis and is related with milder infections compared with X-linked gp91^{phox} deficient form (65% of all cases),^[4-6] however, in our case, recurrent infections since childhood, including meningitis, staphylococcus skin infections, and resistant pulmonary tuberculosis complicated with *Aspergillus fumigatus* coinfection were preceded. Noticeably, mycobacterium tuberculosis is not among the typical pathogens of CGD, but even so, patient not only was infected but also suffered from the resistant, military form.

Treating pyoderma gangrenosum in a patient with CGD remains a challenge. These patients must take lifelong antibacterial and antifungal prophylaxis with cotrimoxazole and itraconazole and, sometimes, treatment with interferon-gamma is also required to avoid recurrent infections.^[4-6] The only

successful and permanent treatment that can cure the underlying genetic defect in CGD is hematopoietic stem cell transplantation and maybe gene therapy in the future.^[4-6,33,34] On the other hand, although there are no specific guidelines for the treatment of PG due to lack of large randomized controlled trials, most authors recommend high doses of corticosteroids for a long time (plus cyclosporine A when required) as first line therapy in PG.^[1-2,16-17] Dapsone, IVIG, and other immunosuppressants, including azathioprine, mycophenolate mofetil, chlorambucil, and infliximab could be used as alternative steroid-sparing agents or in presence of steroid related side effects.^[1-2,14-17] In addition, dapsone is considered by some authors as drug of first choice, however, in aggressive forms of PG dapsone should not be used as monotherapy but as an adjuvant agent to oral corticosteroids.^[14,17,35,36] Corticosteroids, however, although increasing the risk of infection, may be useful and necessary in CGD patients in case of complications due to chronic granulomatous inflammation, which is also a characteristic of this syndrome, such as colitis, gastric outlet obstruction, pericarditis, and urethral stricture.^[4-6] Indeed, in fulminant mulch pneumonitis steroids are mandatory and should be administered as soon as possible along with antifungal treatment.^[4,6] This excessive inflammatory process may represent an overwhelming response to a resolved past infection by normal cells of the immune system (such as T and B lymphocytes), and defects in phagocytosis along with increased cytokine responses due to poor superoxide generation.^[5,37,38] Nevertheless, steroids should always be administered under close observation and sometimes, indeed, specialist's opinion may be useful, especially where there is suspicion of coexisting infection or history of fungal infection.^[4]

Apart from CGD, PG is also infrequently associated with other congenital or acquired immune deficiencies, demonstrating that dysregulation of immune system might play an important role in the pathophysiology of this disease.^[2,14] PG has been reported in patients with common variable primary immunodeficiency,^[39,40] Bruton's X-linked agammaglobulinemia,^[41,42] C7 deficiency,^[43] leukocyte adhesion deficiency type 1,^[44,45] as well as in HIV-positive individuals.^[46,47] However, the simultaneous occurrence of PG and CGD is very rare worldwide and, to the best of our knowledge, there are only a few case reports in the literature.^[7-10] In one of these references features of hyper-IgE syndrome were, also, present^[7] while others were related to peristomal PG^[8,10] (see, Table 1). Immunosuppressants, including corticosteroids

Table 1**Previous clinical presentations of pyoderma gangrenosum in patients with chronic granulomatous disease.**

Reference	Type of PG	Comorbidities	Treatment	Result
Robinson et al ^[7]	Classical	Hyper-IgE syndrome	Salicylazosulfapyridine	Lesions were eventually healed but followed by <i>Aspergillus</i> osteomyelitis
Minhas et al ^[8]	Peristomal	Not reported	Corticosteroids	Lesions were healed with no side-effects
Bellak et al ^[9]	Classical	Not reported	Prednisone + cyclosporine	Lesions were healed with no side-effects
Alvarez-Downing et al ^[10]	Peristomal (4 cases)	Not reported	Immunosuppressants (unspecified)	One death due to fulminant CMV colitis. Unspecified result for the rest 3 cases

CMV = cytomegalovirus, IgE = immunoglobulin E, PG = pyoderma gangrenosum.

were used with caution to treat these patients and, eventually, the lesions were healed through time with no side effects.^[7–9] In our patient, however, it was initially decided to administer a more conservative second-line therapy with dapsone and intravenous immunoglobulin, under the fear of a severe infection (considering, also, the recent *A. fumigatus* infection) or relapse of the previous tuberculosis if corticosteroids were used.^[2,3,14,16,17] Patient was informed that dapsone has a slow onset of action. However, a month later and after the onset of a third ulcer as a progression of the existing furuncle on the left forearm, the patient himself asked for escalation of the treatment with steroids, understanding the potential risks of his decision. Methylprednisolone was added to treatment along with daily prophylaxis with cotrimoxazole and itraconazole. Dermatologist advice was requested for the dosage of methylprednisolone and decided to start with a 5-day intravenous pulse of 1 g/d and then proceed with a moderate dosage of about 0.5 mg/kg (16 mg twice a day) tapering 4 mg every 4 days, till the remaining dosage of 4 mg every 2 days. Systemic therapy with oral prednisone in substantial dosages of 0.5 to 1 mg/kg/d and sometimes up to 120 mg daily is usually the agent of choice in the treatment of PG.^[2,3,14,16,17] Nevertheless, the highest dosage of initial intravenous pulse steroid treatment was preferred (many authors recommend methylprednisone 1 g daily for 1–5 days),^[1,14,16,17] in order to have the advance of proceeding with lower doses of oral methylprednisolone (0.5 mg/kg/d) and taper down faster at the maintenance dose, aiming at fewer side effects. The lesions were gradually healed about 3 months later, fortunately with no adverse events and no signs of infection. Finally, the blood test results also improved, except for a remaining, mild, microcytic, hypochromic anemia that is often detected in CGD.^[4]

4. Conclusion

In conclusion, here we report a case of pyoderma gangrenosum in a patient with a known history of chronic granulomatous disease, highlighting the coexistence of these both rare conditions. In addition, the suggested treatment of PG with corticosteroids and immunosuppressants could potentially be harmful to a patient with CGD. This case report shows how combined therapy, including corticosteroids at proper dosage and close clinical and laboratory monitoring, can be applied to successfully treat pyoderma gangrenosum, overcoming the increased risk of infections.

References

- Gameiro A, Pereira N, Cardoso JC, et al. Pyoderma gangrenosum: challenges and solutions. *Clin Cosmet Investig Dermatol* 2015;3: 285–93.

- Saigal R, Singh Y, Mittal M, et al. Pyoderma gangrenosum. *J Assoc Physicians India* 2010;58:378–83.
- Wollina U. Pyoderma gangrenosum—a review. *Orphanet J Rare Dis* 2007;2:19.
- CGD Society. Chronic Granulomatous Disorder—A Guide for Medical Professionals. Available at: www.cgdsociety.org. Accessed 2012.
- Song E, Bala Jaishankar G, Saleh H, et al. Chronic granulomatous disease: a review of the infectious and inflammatory complications. *Clin Mol Allergy* 2011;9:10.
- Holland SM. Chronic granulomatous disease. *Clin Rev Allergy Immunol* 2010;38:3–10.
- Robinson MF, McGregor R, Collins R, et al. Combined neutrophil and T-cell deficiency. Initial report of a kindred with features of the hyper-IgE syndrome and chronic granulomatous disease. *Am J Med* 1982;73: 63–70.
- Minhas U, Cairns SA, Riddell AD, Patel G, Price PE, Harding KG. Rare occurrence of pyoderma gangrenosum in a patient with chronic granulomatous disease and its management—case study; 2009. EWMA Conference 2009/Poster 260.
- Bellak JM, Bell MC, Durrani SR, et al. Classical pyoderma gangrenosum associated with abnormal neutrophil oxidative burst. *J Allergy Clin Immunol* 2012;129:AB159doi:10.1016/j.jaci.2011.12.358.
- Alvarez-Downing MM, Kamal NIS, Inchauste SM, et al. The role of surgery in the management of patients with refractory chronic granulomatous disease colitis. *Dis Colon Rectum* 2013;56:609–14.
- Deffert C, Schäppi MG, Pache JC, et al. Bacillus Calmette-Guérin infection in NADPH oxidase deficiency: defective mycobacterial sequestration and granuloma formation. *PLoS Pathog* 2014;10:1–4.
- Movahedi Z, Norouzi S, Mamishi S, et al. BCGiosis as a presenting feature of a child with chronic granulomatous disease. *Braz J Infect Dis* 2011;15:83–6.
- Bustamante J, Aksu G, Vogt G, et al. BCG-osis and tuberculosis in a child with chronic granulomatous disease. *J Allergy Clin Immunol* 2007; 120:32–8.
- Callen JP. Pyoderma gangrenosum. *Lancet* 1998;351:581–5.
- Ye MJ, Ye JM. Pyoderma Gangrenosum: A Review of Clinical Features and Outcomes of 23 Cases Requiring Inpatient Management; 2014. Article ID 461467. Available at: <http://dx.doi.org/10.1155/2014/461467>. Accessed 2014.
- Crowson AN, Mihm MC, Magro C. Pyoderma gangrenosum: a review. *J Cutan Pathol* 2003;30:97–107.
- Powell FC, Su WP, Perry HO. Pyoderma gangrenosum: classification and management. *J Am Acad Dermatol* 1997;36:899–907.
- Dohil M, Prendiville JS, Crawford RI, et al. Cutaneous manifestations of chronic granulomatous disease. *J Am Acad Dermatol* 1997;36:899–907.
- Cale CM, Morton L, Goldblatt D. Cutaneous and other lupus-like symptoms in carriers of X-linked chronic granulomatous disease: incidence and autoimmune serology. *Clin Exp Immunol* 2007;148:79–84.
- Luis-Montoya P, del Mar Sáez-de Ocariz M, Vega-Memije ME. Chronic granulomatous disease: two members of a single family with different dermatologic manifestations. *Skinmed* 2005;4:320–2.
- Barbato M, Ragusa G, Civitelli F, et al. Chronic granulomatous disease mimicking early-onset Crohn's disease with cutaneous manifestations. *BMC Pediatr* 2014;14:1–4.
- Su WPD, Sctiroeter AL, Perry HO, et al. Histopathologic and immunopathologic study of pyoderma gangrenosum. *J Cutan Pathol* 1986;13:323–30.
- Johnston SL. Clinical immunology review series: an approach to the patient with recurrent superficial abscesses. *Clin Exp Immunol* 2008;152:397–405.

- [24] Wu J, Wang W, Zhang Y, Chen T. Clinical features and genetic analysis of 48 patients with chronic granulomatous disease in a single center study from Shanghai, China (2005-2015): new studies and a literature review. *J Immunol Res* 2017;2017:17Article ID 8745254. Available at: <https://doi.org/10.1155/2017/8745254>. Accessed 2017
- [25] Kuhns DB, Alvord WG, Heller T, et al. Residual NADPH oxidase and survival in chronic granulomatous disease. *N Engl J Med* 2010;363:2600–10.
- [26] Lekstrom-himes Ja, Kuhns DB, Alvord WG, et al. Peroxide and dysregulation in chronic granulomatous disease 1. *J Immunol* 2005;174:411–7.
- [27] van de Veerdonk FL, Smeekens SP, Joosten LAB, et al. Reactive oxygen species-independent activation of the IL-1beta inflammasome in cells from patients with chronic granulomatous disease. *PNAS* 2010;107:3030–3.
- [28] Foster CB, Lehrnbecher T, Mol F, et al. Host defense molecule polymorphisms influence the risk for immune-mediated complications in chronic granulomatous disease. *J Clin Invest* 1998;102:2146–55.
- [29] Immune Deficiency Foundation. Patient & Family Handbook for Primary Immunodeficiency Diseases (5th Edition). Available at: www.primaryimmune.org. Accessed 2015.
- [30] Braswell SF, Kostopoulos TC, Ortega-Loayza AG. Pathophysiology of pyoderma gangrenosum (PG): an updated review. *J Am Acad Dermatol* 2015;73:691–8.
- [31] Nerblla P, Guido MODI, Daniela A, et al. Leukocyte chemotaxis and pyoderma gangrenosum. *Int J Dermatol* 1985;24:45–7.
- [32] Adachi Y, Kindzelskii AL, Cookingham G, et al. Aberrant neutrophil trafficking and metabolic oscillations in severe pyoderma gangrenosum. *J Invest Dermatol* 1998;111:259–68.
- [33] Bortoletto P, Lyman K, Camacho A, et al. Chronic granulomatous disease—a large, single-center US experience. *Pediatr Infect Dis J* 2015;34:1110–4.
- [34] Kang EM, Marciano BE, DeRavin S, et al. Chronic granulomatous disease: overview and hematopoietic stem cell transplant. *J Allergy Clin Immunol* 2011;127:1319–26.
- [35] Chow RKP, Ho V. Treatment of pyoderma gangrenosum. *J Am Acad Dermatol* 1996;34:1047–60.
- [36] Altman J, Mopper C. Pyoderma gangrenosum treated with sulfone drugs. *Minn Med* 1966;49:22–6.
- [37] Bylund J, MacDonald KL, Brown KL, et al. Enhanced inflammatory responses of chronic granulomatous disease leukocytes involve ROS-independent activation of NF-κB. *Eur J Immunol* 2007;37:1087–96.
- [38] Brown JR, Goldblatt D, Buddle J, et al. Diminished production of anti-inflammatory mediators during neutrophil apoptosis and macrophage phagocytosis in chronic granulomatous disease (CGD). *J Leukoc Biol* 2003;73:591–9.
- [39] Bergler-Czop B, Brzezińska-Wcisło L. Pyoderma gangrenosum in a patient with common variable primary immunodeficiency. *Postep Dermatol Alergol* 2013;30:188–91.
- [40] Simsek O, Ulsan K, Orhan A, et al. Pyoderma gangrenosum with common variable immunodeficiency. *Woonds* 2015;27:19–33.
- [41] Schwartzfarb EM, Weir D, Conlan WAIII, et al. Pyoderma gangrenosum in a patient with Bruton's X-linked agammaglobulinemia shared pathogenesis of altered tumor necrosis factor alpha? *J Clin Aesthetic Derm* 2008;1:26–9.
- [42] Murray PR, Jain A, Uzel G, et al. Pyoderma gangrenosum-like ulcer in a patient with X-linked agammaglobulinemia: identification of helicobacter bilis by mass spectrometry analysis. *Arch Dermatol* 2010;146:523–6.
- [43] Friduss SR, Sadoff WI, Hern AE, et al. Fatal pyoderma gangrenosum in association with C7 deficiency. *J Am Acad Dermatol* 1992;27:356–9.
- [44] Hinze CH, Lucky AW, Bove KE, et al. Leukocyte adhesion deficiency type 1 presenting with recurrent pyoderma gangrenosum and flaccid scarring. *Pediatr Dermatol* 2010;27:500–3.
- [45] Bedlow AJ, Davies EG, Moss ALH, et al. Pyoderma gangrenosum in a child with congenital partial deficiency of leucocyte adherence glycoproteins. *Br J Dermatol* 1998;139:1064–7.
- [46] Paller AS, Sahn EE, Garen PD, et al. Pyoderma gangrenosum in pediatric acquired immunodeficiency syndrome. *J Pediatr* 1990;117:63–6.
- [47] Clark HH, Cohen PR. Pyoderma gangrenosum in an HIV-infected patient. *J Am Acad Dermatol* 1995;32:912–4.