



Contents lists available at ScienceDirect

International Journal of Surgery Case Reports

journal homepage: www.casereports.com

An atypical presentation of small bowel obstruction and perforation secondary to sporadic synchronous intra-abdominal desmoid tumours



Sala Abdalla^{a,*}, Michelle Wilkinson^a, Mark Wilsher^b, Aleksandras Uzkalnis^a

^a Department of General Surgery, University Hospital Lewisham, High Street, Lewisham, London, SE13 6LH, UK

^b Department of Histopathology, University Hospital Lewisham, High Street, Lewisham, London, SE13 6LH, UK

ARTICLE INFO

Article history:

Received 19 October 2015

Received in revised form 12 January 2016

Accepted 16 January 2016

Available online 1 February 2016

Keywords:

Desmoid
Sporadic
Polyposis
Sarcoma

ABSTRACT

INTRODUCTION: Desmoid tumours (DTs) are rare, soft tissue tumours which account for 0.03% of all neoplasms. They are characteristically locally invasive but do not metastasize. There is frequent association with females of reproductive age, a history of abdominal surgery or trauma and a family history of fibromatoses. Intra-abdominal DTs are infrequently sporadic and more commonly associated with inherited disorders such as familial adenomatous polyposis (FAP), attenuated FAP and Gardner's syndrome.

PRESENTATION OF CASE: The authors report a rare case of small bowel obstruction and perforation secondary to sporadic, synchronous intra-abdominal DTs in a 54-year old man with atypical symptoms and no risk factors or family history.

DISCUSSION: Intra-abdominal DTs have a worse prognosis as they can cause intestinal bleeding, obstruction and perforation. Due to the rarity of these tumours there are no clear guidelines on their management and this is instead based on small case series from specialist centres. In the non-acute setting patients with sporadic intra-abdominal DTs should be managed in a specialist sarcoma unit by a multidisciplinary team. In the presence of FAP or other polyposis syndromes patients with DTs should be managed at a specialist colorectal unit. Emergent presentations require emergency surgery in suitable candidates.

CONCLUSION: In non-emergency presentations of DTs, it is essential to exclude FAP, AFAP and other hereditary polyposis syndromes since this affects treatment and subsequent follow-up.

© 2016 The Authors. Published by Elsevier Ltd. on behalf of IJS Publishing Group Ltd. This is an open access article under the CC BY-NC-ND license (<http://creativecommons.org/licenses/by-nc-nd/4.0/>).

1. Introduction

Desmoid tumours (DTs), also known as fibromatoses, are rare soft tissue tumours that result from the abnormal proliferation of fibroblasts in musculo-aponeurotic structures. They account for 0.03% of all neoplasms and can occur in mesenchymal structures of the limb and limb girdle, intra-abdominally or within the abdominal wall [1,2]. Although they are thought to lack metastatic capacity, DTs can cause significant morbidity and even mortality due to size, compression and invasion of adjacent structures. Aetiological factors associated with DTs are female gender especially of reproductive age, a history of abdominal surgery or trauma, and a family history of fibromatoses [3]. Intra-abdominal DTs are more commonly associated with familial adenomatous polyposis (FAP), an autosomal dominant inherited disorder that arises from mutations of the APC tumour suppressor gene [4]. However, in approximately 5% of cases they can occur sporadically. An association with Gardner's syndrome and attenuated FAP has also been well documented. Desmoid tumours localized in the abdomen have a worse

prognosis as they can cause intestinal bleeding, obstruction and perforation. Retroperitoneal involvement can lead to compression of major blood vessels and ureteral obstruction. We report a rare case of a patient presenting in an acute confusional state who was found to have small bowel obstruction and perforation due to two large intra-abdominal DTs arising from the small bowel mesentery.

2. Presentation of case

A 54-year old Nigerian man presented to the emergency department in an acute confusional state. He had a background of three weeks of colicky abdominal pain which was associated with intermittent vomiting, hiccups and polydipsia. He had been opening his bowels daily and there was no history of weight-loss, haematemesis or rectal bleeding. He was scheduled to have an abdominal ultrasound scan and on the day prior to presenting to hospital he had an oesophago-gastro-duodenoscopy (OGD). This showed gastritis and a gastric ulcer in gastric antrum and prepyloric region, respectively, as well as a large volume of gastric content despite a 10-h fast. A tissue biopsy was taken. He had a history of hypertension and no relevant surgical or family history. Clinically he was acutely confused, dehydrated and pyrexial. Chest examination was unremarkable and there were no focal neurolog-

* Corresponding author.

E-mail address: sala3001@doctors.org.uk (S. Abdalla).

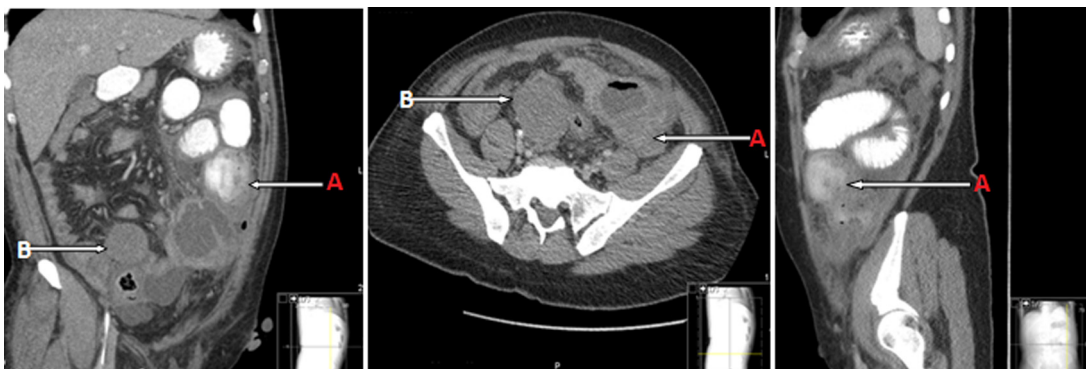


Fig. 1. Sections from computed tomography scan with oral and intravenous contrast enhancement demonstrating the locations of the two intra-abdominal desmoid tumours indicated by the arrows. Arrows “A” demonstrate the distal jejunal lesion and arrows “B” show the lesion in the ileocaecal region.

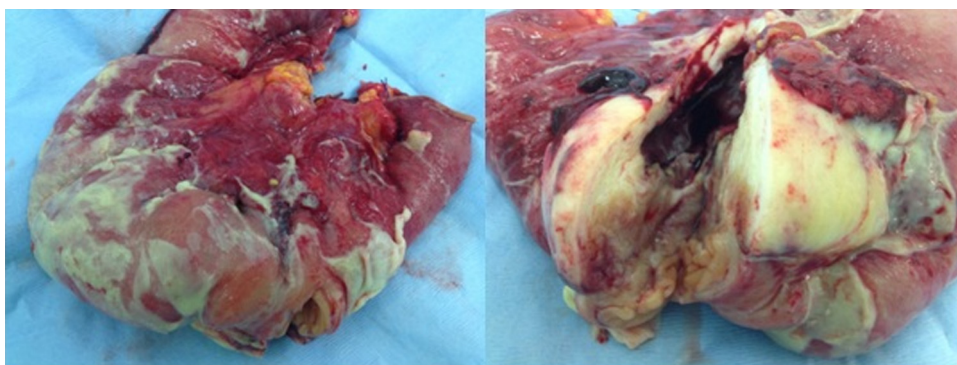


Fig. 2. 7 × 8 × 4 cm tumour arising from distal jejunal mesentery, involving the bowel wall. The bowel wall is covered in fibrinous exudates and there is associated congestion and haemorrhage in the mesentery.

ical signs. His abdomen was mildly distended and tender with no signs of peritonism or palpable masses. Bowel sounds were scanty and rectal examination was unremarkable.

Laboratory tests revealed a mild normocytic anaemia (Haemoglobin count 11.5 g/dL), raised inflammatory markers (White Cell Count $29.5 \times 10^9/L$, C-reactive protein 238 mg/L), impaired renal function (Urea 23.4 mmol/L, Creatinine 233, estimate GFR 25 mL/min/1.73), a significant hyponatraemia (Na 104 mmol/L) and a raised serum lactate (3.4 mmol/L). Serum osmolality, urinary Sodium and urinary osmolality were all decreased (244 mosmol/kg, 27 mmol/L and 206 mosmol/Kg, respectively).

An erect chest radiograph was unremarkable with no evidence of pneumoperitoneum. Computed tomography (CT) scanning of the head was unremarkable. However, a CT of the abdomen and pelvis revealed two soft tissue masses in the abdomen; the largest measuring 6.8 cm in the mid abdomen appeared to be causing proximal small bowel obstruction, and separate mass of similar tissue density measuring 5 cm adjacent to the ileocaecal region surrounded by a small amount of free fluid (Fig. 1). He was admitted into the intensive care unit for support and monitoring.

At laparotomy the next day he was found to have a necrotic 7 cm mass arising from the mesentery of the distal jejunum/proximal ileum invading the contiguous small bowel, causing obstruction and perforation (Fig. 2). A second mass measuring 6 cm was found arising from the mesoappendix and infiltrating into the ileocaecal region (Fig. 3). This was causing obstruction of the terminal ileum. Ileal and ileocaecal resections were carried out but due to the poor general condition of the patient four blind ending loops were left in the abdomen. A planned re-look laparotomy was undertaken 48 h later with formation of jejunio-ileal and ileocolic anastomosis. Five days later he had a third laparotomy for suspected anastomotic dehiscence and was found to have a defect

in the jejunio-ileal anastomosis. A controlled enterostomy using a Foley catheter was formed, and the abdomen was managed as a laparostomy for 10 days after which an abdominal VAC dressing was applied to facilitate abdominal wall closure.

Microscopically, both lesions involved the walls of each bowel segment and formed a mesenteric mass, involving the serosal surface, which was coated in acute inflammatory exudates. The lesions were formed of bland, uniform spindle cells and partially replaced muscularis propria. The spindle cells had a fibroblastic/myofibroblastic appearance. The ileocaecal mass displayed prominent keloid collagen (Fig. 4).

Immunohistochemical markers were performed. The lesional spindle cells in each mass expressed smooth muscle actin, Beta-catenin and Vimentin. Other immunomarkers were negative (ALK-1, Bcl-2, CD117, CD34, CD45, Desmin, EMA, MNF116, p63 and S100). A diagnosis of Desmoid type fibromatosis/synchronous DTs was made and confirmed by an external expert sarcoma histopathologist. The immunohistochemical profile excluded differential diagnoses of gastrointestinal stromal tumour (GIST), inflammatory myofibroblastic tumour, leiomyoma, peripheral nerve sheath tumour, spindle cell carcinoma, peripheral nerve tumour and metastatic spindle cell melanoma.

The patient's post-operative recovery was slow with a 49-day stay in the intensive care unit and multiple theatre sessions for change of abdominal VAC dressing. He was an inpatient for a total of 57 days and was eventually discharged with an abdominal VAC dressing, with planned community follow-up. He was seen in outpatients 6 weeks following discharge and was referred for a colonoscopy which did not show any evidence of colonic polyposis. As there was no family history of or clinical evidence for FAP he was referred to a specialist sarcoma centre for follow up.

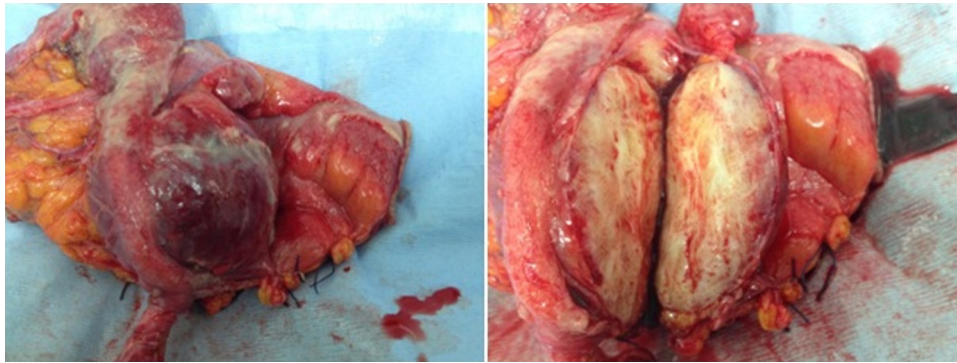


Fig. 3. 6 cm desmoid tumour arising from the meso-appendix.

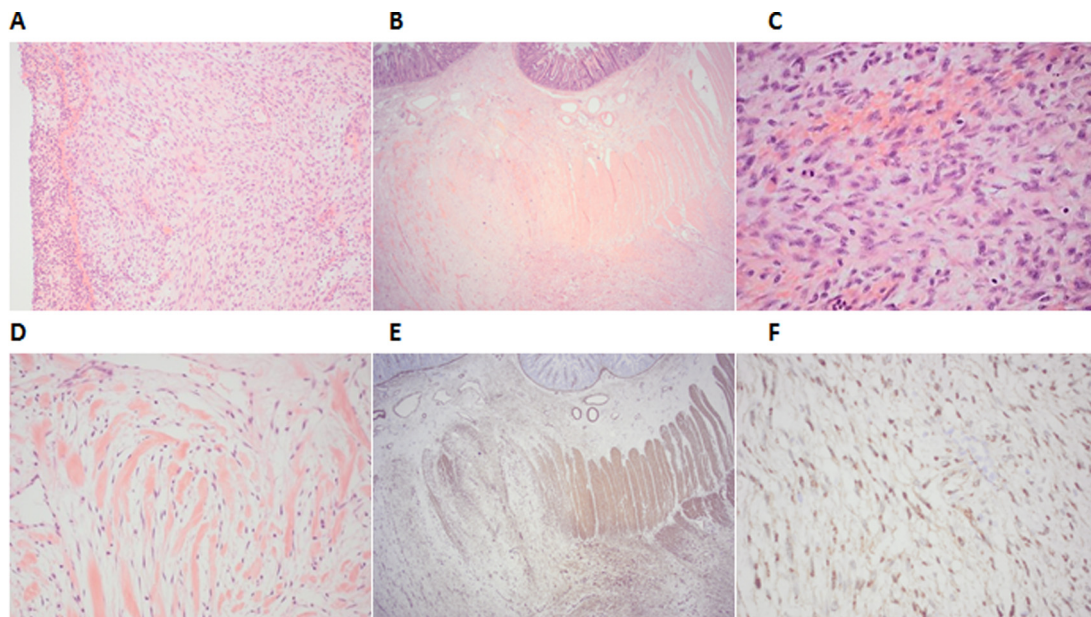


Fig. 4. (A) Ileal mass. Acute inflammatory exudate at serosal surface (left). (H&E medium power). (B) Ileal mass replacing the bowel wall (H&E scanning view). (C) Ileal mass. Fibromatosis, characterised by uniform spindle cells, red cell extravasation and occasional mitoses. (H&E high power). (D) Ileo-caecal mass with prominent keloidal collagen. (H&E medium power). (E) Ileal mass. Expression of smooth muscle actin (internal control = muscularis propria). (F) Ileal mass. Nuclear expression of Beta-catenin, a characteristic finding in fibromatosis.

3. Discussion

Only 5% of sporadic DTs are intra-abdominal. In contrast, 80% of patients with familial adenomatous polyposis (FAP)-associated desmoid tumours develop intra-abdominal disease. The majority of intra-abdominal DTs (85%) arise from the mesentery [5,6] and can cause significant morbidity and mortality due to their locally infiltrative behaviour which can result in bowel obstruction, perforation or fistula formation. The subject of this case report presented to the physicians in an acute confusional state with a history of polydipsia and finding of profound hyponatraemia (Na 104 mmol/L). Bowel obstruction was not initially considered in the differential diagnoses. The collateral history then revealed three weeks of abdominal pain and intermittent vomiting but there was no report of constipation. The patient had no prior history of surgery or trauma to the abdomen, and no family history of fibromatoses or FAP. The final diagnosis of bowel obstruction was not established until a CT scan of the abdomen and pelvis revealed the two intra-abdominal masses which were thought to represent GIST or lymphoma. The diagnosis of desmoid tumours was never considered. His demographics and lack of risk factors and/or family history made this diagnosis all the more unlikely. The final diagnosis was

established after histological analysis of the specimens and further confirmation by an external expert sarcoma histopathologist. The overall presentation was atypical for bowel obstruction and perforation from synchronous, mesenteric DTs.

The confirmation of the non-FAP status of the disease was made after the patient, who was in his mid-fifties, had a follow-up colonoscopy which revealed no colonic polyposis. It is essential to exclude FAP and investigate for attenuated FAP (AFAP) in all patients presenting with abdominal DTs since these two conditions carry a very high risk of development of colorectal cancer [7–11]. The diagnosis of FAP requires the presence of more than 100 colonic adenomas. Attenuated AFP (AFAP), where the mutation occurs at the extreme ends of the APC gene, is defined by the presence of three and 99 adenomas.

Histological assessment is mandatory for differentiating DTs from other neoplasms such as gastrointestinal stromal tumours, lymphoma, pleomorphic sarcoma and fibrosarcoma. Microscopically they are composed of spindle- or stellate-shaped fibroblastic cells embedded in a collagenous stroma. Genetic testing for FAP or AFAP was not performed as up to 30% of patients with a clear FAP phenotype and 75% with AFAP have no identifiable APC gene mutation [12].

Ultrasonography (USS), computed tomography (CT) and magnetic resonance imaging (MRI) can and have all been used to establish the nature, extension and anatomical relationship of DTs. On USS DTs appear as lesions of variable echogenicity and on CT scanning they are homogeneously enhanced with well-defined margins. Desmoid tumours appear hypo-intense on T1-weighted MRI and predominantly hyper-intense on T2-weighted MRI, reflecting the proliferation of fibroblasts [13,14].

Due to the rarity of these tumours there are no clear guidelines on their management and this is instead based on small case series from specialist centres [12,15]. Before consideration of surgery, in the non-acute setting, patients should be fully investigated for FAP, AFAP and other hereditary polyposis syndromes with a family history, full colonoscopy with dye spray (chromoendoscopy), random biopsies to identify microadenomas, and OGD to look for cystic gland polyps in the stomach and duodenal adenomas.

The management of desmoid tumours is then dependent on whether they are sporadic or not. In the presence of FAP or other polyposis syndrome the patient should be managed at a specialist colorectal unit. In these patients surgery is associated with high recurrence rates and is therefore only used when absolutely necessary. Instead medical therapies such as non-steroidal anti-inflammatory drugs, Tamoxifen and chemotherapy are trialed as first and often second line therapy.

This contrasts with the management of sporadic intra-abdominal DTs, which should be managed in a specialist sarcoma unit by a multidisciplinary team. They are thought to have low recurrence rates after resection and therefore surgery is recommended as the first-line treatment for amenable tumours.

Emergent presentations such as in this case require emergency laparotomy in suitable surgical candidates.

In our patient, the treatment of choice was small bowel and ileocaecal resections as resection of the mesenteric tumours alone would have interrupted the mesenteric blood supply to the bowel, resulting in bowel ischaemia. The significance of margins is controversial. Some studies suggest that margins are significant for predicting recurrence but others have demonstrated that they do not add prognostic value [16,17].

4. Conclusion

This is a rare case of sporadic, synchronous intra-abdominal DTs presenting with atypical symptoms. Sporadic DTs infrequently present with intra-abdominal manifestations. The patient made a good recovery following emergency surgery. In non-emergency settings it is essential to exclude FAP, AFAP and other hereditary polyposis syndromes since this affects treatment and subsequent follow-up.

Consent

Written informed consent for publication of this case report and any accompanying images was obtained from the patient.

Conflict of interest

The authors declare that there is no conflict of interest.

References

- [1] H.D. Suit, Radiation dose and response of desmoid tumors, *Int. J. Radiat. Oncol. Biol. Phys.* 19 (1990) 225–227.
- [2] S.K. Clark, K.F. Neale, J.C. Landgrebe, R.K. Phillips, Desmoid tumours complicating familial adenomatous polyposis, *Br. J. Surg.* 86 (9) (1999) 1185–1189.
- [3] J.J. Reitano, P. Hayry, E. Nykyri, E. Saxen, The desmoid tumor I. Incidence, sex-, age- and anatomical distribution in the Finnish population, *Am. J. Clin. Pathol.* 77 (1982) 665–673.
- [4] D.J. Lips, N. Barker, H. Clevers, A. Hennipman, The role of APC and beta-catenin in the aetiology of aggressive fibromatosis (desmoid tumors), *Eur. J. Surg. Oncol.* 35 (2009) 3–10.
- [5] I. Heiskanen, H.J. Jarvinen, Occurrence of desmoid tumours in familial adenomatous polyposis and results of treatment, *Int. J. Colorectal Dis.* 11 (4) (1996) 157–162.
- [6] A.L. Knudsen, S. Bulow, Desmoid tumor in familial adenomatous polyposis, *Ugeskr. Laeger* 162 (42) (2000) 5628–5631.
- [7] P. Galiatsatos, W.D. Foulkes, Familial adenomatous polyposis, *Am. J. Gastroenterol.* 101 (2006) 385–398.
- [8] C.N. Ellis, Colonic adenomatous polyposis syndromes: clinical management, *Clin. Colon Rectal Surg.* 21 (2008) 256–262.
- [9] H.F. Vasen, G. Moslein, A. Alonso, S. Aretz, I. Bernstein, L. Bertario, et al., Guidelines for the clinical management of familial adenomatous polyposis (FAP), *Gut* 57 (2008) 704–713.
- [10] D.W. Neklason, C.H. Solomon, A.L. Dalton, S.K. Kuwada, R.W. Burt, Intron 4 mutation in APC gene results in splice defect and attenuated FAP phenotype, *Fam. Cancer* 3 (2004) 35–40.
- [11] H.T. Lynch, T. Smyrk, T. McGinn, S. Lanspa, J. Cavalieri, J. Lynch, et al., Attenuated familial adenomatous polyposis (AFAP): a phenotypically and genotypically distinctive variant of FAP, *Cancer* 76 (1995) 2427–2433.
- [12] M.J. Wilkinson, J.E.F. Fitzgerald, J.M. Thomas, A.J. Hayes, D.C. Strauss, Surgical resection for non familial adenomatous polyposis related intra-abdominal fibromatosis, *Br. J. Surg.* 99 (2012) 706–713.
- [13] A.P. Brooks, R.H. Reznick, K. Nugent, K.C. Farmer, J.P. Thomson, R.K. Phillips, CT appearances of desmoid tumours in familial adenomatous polyposis: further observations, *Clin. Radiol.* 49 (1994) 601–607.
- [14] L. Azizi, M. Balu, A. Belkacem, M. Lewin, J.M. Tubiana, L. Arrive, MRI features of mesenteric desmoid tumors in familial adenomatous polyposis, *AJR Am. J. Roentgenol.* 184 (2005) 1128–1135.
- [15] A.R. Latchford, N.J. Sturt, K. Neale, P.A. Rogers, R.K. Phillips, A 10-year review of surgery for desmoid disease associated with familial adenomatous polyposis, *Br. J. Surg.* 93 (2006) 1258–1264.
- [16] J.T. Brodsky, M.S. Gordon, S.I. Hajdu, M. Burt, Desmoid tumors of the chest wall: a locally recurrent problem, *J. Thorac. Cardiovasc. Surg.* 104 (1992) 900–903.
- [17] A.K. Methrotra, S. Sheikh, A.D. Aaron, Fibromatoses of extremities: clinicopathologic study of 36 cases, *J. Surg. Oncol.* 74 (2000) 291–296.

Open Access

This article is published Open Access at sciendo.com. It is distributed under the [IJSCR Supplemental terms and conditions](#), which permits unrestricted non commercial use, distribution, and reproduction in any medium, provided the original authors and source are credited.