



OPEN ACCESS

# Difficulty removing a leadless pacemaker in a post-transfusion patient

Atomu Tajima,<sup>1,2</sup> Yoshiaki Mizutani ,<sup>1</sup> Masaaki Kanasiro,<sup>1</sup> Tetsuya Amano<sup>2</sup>

<sup>1</sup>Department of Cardiology, Yokkaichi Municipal Hospital, Yokkaichi, Japan  
<sup>2</sup>Aichi Medical University, Nagakute, Aichi, Japan

**Correspondence to**

Dr Yoshiaki Mizutani;  
yoshiaki522000@yahoo.co.jp

Accepted 2 October 2021

**SUMMARY**

A 99-year-old woman with atrial fibrillation bradycardia and symptomatic long pauses underwent a leadless pacemaker implantation after red blood cell transfusion due to anaemia. The patient's blood tests after transfusion showed hypercoagulability; haematocrit, haemoglobin and fibrinogen levels were increased from 24.5% to 33.2%, 76 g/L to 111g/L, and 346 mg/dL to 646 mg/dL, respectively. Blood tests showed no hereditary hypercoagulability disorder and she had no history of thrombophilia. A leadless pacemaker was implanted in the correct position in the right ventricle. Heparin was administered after sheath insertion and the leadless pacemaker system was thoroughly flushed with heparinised saline before the tether was cut; however, removing the tether after leadless pacemaker implantation was difficult because clots had formed on the tether.

**BACKGROUND**

Leadless pacemakers have been developed as a useful therapeutic option for patients who require single-chamber ventricular pacing<sup>1-3</sup>; when implanted, it can reduce the rate of procedural complications by 63% compared with the transvenous pacemaker.<sup>4</sup> Therefore, leadless pacemakers have sometimes been used as alternatives to the conventional transvenous type because they are less invasive, and are associated less with infections and vascular problems.<sup>1-3</sup> Although there are fewer problems associated with leadless pacemaker implantation, complications such as cardiac tamponade, elevated threshold, and dislodgement of the pacemaker have been reported to occur, mostly during pacemaker implantation before the tether is cut.<sup>4</sup> We performed a leadless pacemaker implantation in a patient with hypercoagulability and describe a rare case of difficulty during the removal of the tether after implantation.

**CASE PRESENTATION**

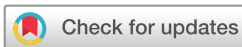A 99-year-old woman with long-standing persistent atrial fibrillation (AF) and dementia underwent a leadless pacemaker (Micra, Medtronic, Minneapolis, Minnesota, USA) implantation due to symptomatic long pauses; informed consent was obtained from the patient and her family. Preoperatively, blood tests revealed severe anaemia with haemoglobin level of 8 g/dL. She experienced respiratory distress on exertion (caused by anaemia). Therefore, she was transfused four units of red blood cell (RBC) to improve anaemic symptoms before pacemaker implantation. Meanwhile, the administration

of direct oral anticoagulant (DOAC) was interrupted for the treatment of anaemia preoperative. After transfusion, haematocrit, haemoglobin and fibrinogen levels were increased from 24.5% to 33.2%, 7.6 g/dL to 11.1 g/dL, and 346 mg/dL to 646 mg/dL, respectively. The D-dimer level was high (6.5 µg/mL). Blood tests showed no hereditary hypercoagulability disorder such as protein C and S deficiency, as the possible cause of the thrombus.<sup>5</sup> She had no history of thrombophilia.

The implantation was performed under fluoroscopic guidance at the Yokkaichi Municipal Hospital. A leadless pacemaker system was inserted through the right femoral vein using a 27-Fr introducer sheath (Medtronic). Heparin (5000 units) was administered after sheath insertion. The delivery system was washed with heparinised saline at a flow rate of 100 mL/hour; a leadless pacemaker was delivered into the RV in a conventional manner. The pacemaker was implanted in the middle septum of the RV at the first attempt. We confirmed that the two tines were hooked into the myocardium by the pull-and-hold test through fluoroscopy. Pacemaker implantation parameters were acceptable with an R-wave sensing amplitude of 7.0 mV, impedance of 690 Ω, and a pacing threshold of 0.63 V/0.24 ms. The inside of the leadless pacemaker sheath was flushed thoroughly with an adequate amount of saline before the tether was cut. Of the two tethers, the one which offered more resistance when being pulled was cut, while the other with lower resistance was pulled slowly and cautiously to avoid dislodgement of the pacemaker; the resistance increased when the tether was pulled. Pulling the tether seemed to pull on the pacemaker tines so hard that they seemed to dislodge from the myocardium (figure 1). The tether attached to the device was stored in the leadless pacemaker sheath system, so the tether was pulled and the pacemaker was stored in the sheath. The leadless pacemaker got stuck at the exit of the sheath and could not be removed so the entire sheath was removed. The tether was tangled after, and it proved difficult to pull the tether (figure 2). Furthermore, despite the leadless pacemaker system being thoroughly flushed with heparinised saline, the tether was still covered in blood clots (figure 3).

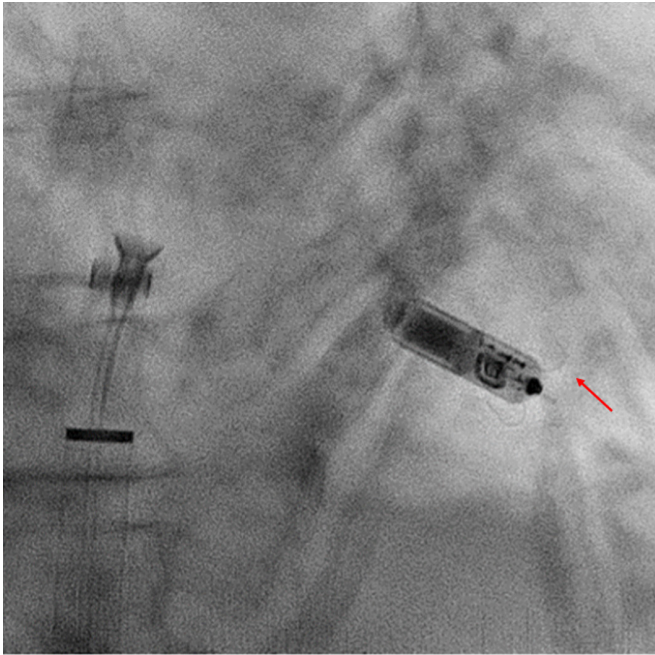
**OUTCOME AND FOLLOW-UP**

A new leadless pacemaker was successfully inserted through the contralateral femoral vein. No other complications occurred during or after the procedure. Three months after discharge, the patient had no symptoms of AF, and the pacemaker parameters were stable at the outpatient clinic follow-up.



© BMJ Publishing Group Limited 2021. Re-use permitted under CC BY-NC. No commercial re-use. See rights and permissions. Published by BMJ.

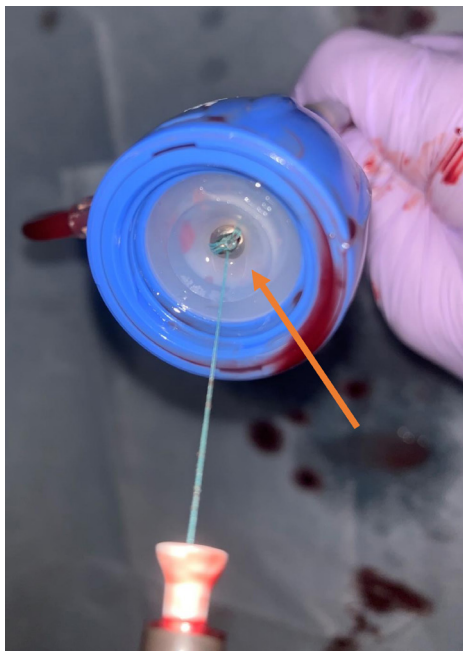
**To cite:** Tajima A, Mizutani Y, Kanasiro M, *et al.* *BMJ Case Rep* 2021;**14**:e246625. doi:10.1136/bcr-2021-246625



**Figure 1** Pulling one tether after cutting the other. The tether's resistance to pull was strong. Red arrow shows tine of leadless pacemaker. The leadless pacemaker was going to be dislodged.

## DISCUSSION

We report a very rare case of difficult leadless pacemaker implantation following RBC transfusion. Complications of leadless pacemaker implantation are fewer than those of transvenous pacemaker implantation, and mostly include tamponade, dislodgement and threshold elevation.<sup>1-3</sup> This case presented an unusual difficulty with tether removal; this was due to the accumulation of clots on the tether and not these three major complications.



**Figure 2** Leadless pacemaker system extraction. Orange arrow shows a tangle of two tethers.



**Figure 3** Clot on the tether after leadless pacemaker system extraction.

Few reports have demonstrated the difficulties encountered during leadless pacemaker implantation when pulling the tether.<sup>6,7</sup> Cipolletta *et al*<sup>6</sup> reported a clot on a tether. They implanted a leadless pacemaker in a 77-year-old man and experienced difficulty releasing the device and retracting the delivery due to a clot on the tether. Morani *et al*<sup>7</sup> reported a similar case; they discussed delivery system flushing and the design of the inner flushing tube system. Both reports did not mention coagulability. We, however, evaluated for coagulability and other clotting risk factors. Our patient was transfused preoperatively; RBC transfusion is a mediator of erythrocyte sedimentation and blood viscosity binding fibrinogen and can promote thrombus formation and enhance its stability.<sup>8,9</sup> This may have been the reason for the easy formation of clots. In fact, blood samples taken after transfusion showed hypercoagulability in this patient. Furthermore, the patient had no hereditary hypercoagulability disorders.

San Antonio *et al*<sup>10</sup> reported that the use of anticoagulant therapy did not increase the complications associated with leadless pacemaker implantation. In this case, DOAC was interrupted before the procedure due to anaemia. Uninterrupted DOAC therapy may have prevented thrombus formation.

However, clots covered the tether, which caused the two tethers to tangle despite heparin infusion and adequate use of heparinised saline for flushing. Washing the delivery system with heparinised saline at a velocity of 100–300 mL/hour is recommended to avoid thrombus formation.<sup>11</sup> However, this complication might not have been prevented by heparin infusion or heparinised saline flushes. Therefore, the transvenous approach may be a better choice for pacemaker implantation following blood transfusion. Careful pacemaker selection is needed when there is a tendency for thrombosis after blood transfusion.

## CONCLUSION

Clot formation on the tether is rare in leadless pacemaker implantation. However, if a leadless pacemaker is implanted after a blood transfusion, the tether may become entangled because of clots.

## Learning points

- ▶ Although there are fewer problems associated with leadless pacemaker implantation, complications have been reported to occur, mostly during pacemaker implantation before the tether is cut. However, this case presented an unusual difficulty with tether removal after the tether was cut.
- ▶ When the blood tests after red blood cell transfusion shows hypercoagulability, clots may cover the tether despite heparin infusion and adequate use of heparinised saline for flushing.
- ▶ If a leadless pacemaker is implanted after a blood transfusion, the tether may become entangled because of clots.

**Contributors** YM wrote the main manuscript, prepared figures and reviewed the manuscript. AT interpreted the data and helped to draft the manuscript. MK and TA critically reviewed and revised the manuscript. All authors discussed and approved the final manuscript.

**Funding** The authors have not declared a specific grant for this research from any funding agency in the public, commercial or not-for-profit sectors.

**Competing interests** None declared.

**Patient consent for publication** Consent obtained from next of kin.

**Provenance and peer review** Not commissioned; externally peer reviewed.

**Open access** This is an open access article distributed in accordance with the Creative Commons Attribution Non Commercial (CC BY-NC 4.0) license, which permits others to distribute, remix, adapt, build upon this work non-commercially, and license their derivative works on different terms, provided the original work is properly cited and the use is non-commercial. See: <http://creativecommons.org/licenses/by-nc/4.0/>.

## ORCID iD

Yoshiaki Mizutani <http://orcid.org/0000-0003-2373-7059>

## REFERENCES

- 1 El-Chami MF, Clementy N, Garweg C, *et al*. Leadless pacemaker implantation in hemodialysis patients: experience with the micra transcatheter pacemaker. *JACC Clin Electrophysiol* 2019;5:162–70.
- 2 Soejima K, Asano T, Ishikawa T, *et al*. Performance of leadless pacemaker in Japanese patients vs. rest of the world - Results from a global clinical trial. *Circ J* 2017;81:1589–95.
- 3 El-Chami M, Kowal RC, Soejima K, *et al*. Impact of operator experience and training strategy on procedural outcomes with leadless pacing: insights from the Micra transcatheter pacing study. *Pacing Clin Electrophysiol* 2017;40:834–42.
- 4 El-Chami MF, Al-Samadi F, Clementy N, *et al*. Updated performance of the Micra transcatheter pacemaker in the real-world setting: a comparison to the investigational study and a transvenous historical control. *Heart Rhythm* 2018;15:1800–7.
- 5 Wypasek E, Undas A. Protein C and protein S deficiency - practical diagnostic issues. *Adv Clin Exp Med* 2013;22:459–67.
- 6 Cipolletta L, Volpato G, Biffi M, *et al*. An indissoluble knot: an unexpected troubleshooting during Micra implantation. *Pacing Clin Electrophysiol* 2019;42:747–8.
- 7 Morani G, Bolzan B, Tomasi L, *et al*. Troubleshooting in PM Leadless: how to manage an indissoluble knot. *J Arrhythm* 2019;35:676–8.
- 8 Byrnes JR, Wolberg AS. Red blood cells in thrombosis. *Blood* 2017;130:1795–9.
- 9 Goel R, Patel EU, Cushing MM, *et al*. Association of perioperative red blood cell transfusions with venous thromboembolism in a North American registry. *JAMA Surg* 2018;153:826–33.
- 10 San Antonio R, Chipa-Casani F, Apolo J, *et al*. Management of anticoagulation in patients undergoing leadless pacemaker implantation. *Heart Rhythm* 2019;16:1849–54.
- 11 Arias MA, Rubio MA, Miguel Rde, *et al*. Thrombus formation at the tip of a leadless pacemaker causing multiple unnecessary repositioning. *Heart Rhythm* 2016;13:2265.

Copyright 2021 BMJ Publishing Group. All rights reserved. For permission to reuse any of this content visit <https://www.bmj.com/company/products-services/rights-and-licensing/permissions/>  
BMJ Case Report Fellows may re-use this article for personal use and teaching without any further permission.

Become a Fellow of BMJ Case Reports today and you can:

- ▶ Submit as many cases as you like
- ▶ Enjoy fast sympathetic peer review and rapid publication of accepted articles
- ▶ Access all the published articles
- ▶ Re-use any of the published material for personal use and teaching without further permission

## Customer Service

If you have any further queries about your subscription, please contact our customer services team on +44 (0) 207111 1105 or via email at [support@bmj.com](mailto:support@bmj.com).

Visit [casereports.bmj.com](http://casereports.bmj.com) for more articles like this and to become a Fellow