

# Familial Dermal Eccrine Cyndromatosis with Emphasis on Histology and Genetic Mapping

Dhir G, Makkar M, Suri V, Dubey VK

Department of Pathology, Adesh Institute of Medical Sciences and Research, Bathinda, Punjab, India

## Address for correspondence:

Dr. Manisha Makkar,  
Sector 4, House no. 231,  
Panchkula - 134 112, Haryana, India.  
E-mail: drmanishamakkar@yahoo.  
co.in

## Abstract

Familial cyndromatosis (FC) is an autosomal dominant disorder with apparently complete penetrance, but variable expression. There is an increasing evidence that FC is clinically, genetically, and histologically heterogeneous disorder as the simultaneous occurrence of cyndromas and other tumors of skin appendages within the affected individuals and families. The presence of multiple scalp cyndromas is often associated with autosomal dominant Brooke-Spielger syndrome, a condition in which there are co-existent facial trichoepitheliomas and spiradenomas. We present here a case of multiple cyndromatosis in a family affecting many members successively.

**Keywords:** Adenexal, Cyndromatosis, Turban

## Introduction

Cyndromas are benign skin adenexal tumor with ductal differentiation. It occurs mostly on the forehead and scalp. Lesions may cover the entire scalp like a turban (turban tumor). Less than 10% of cases may occur on trunk and limbs.<sup>[1]</sup> This is inherited in an autosomal dominant manner and presents as multiple, smooth, firm, pink to red, and pedunculated nodules of various size.

Clinically, cyndroma can present as: (i) A solitary type, occurring sporadically in patients who have no family history of similar lesions (ii) A variant of cutaneous cyndromas; the multiple type, occurring on the head and neck can also be seen on the trunk and the extremities. Solitary cyndromas are lesions that affect middle-aged and elderly persons. Multiple, inherited cyndromas usually begin in early adulthood and increase in size and number throughout the life.<sup>[2]</sup>

We are presenting here a case of familial cyndromatosis (FC), which was diagnosed cytologically and confirmed histopathologically along with genetic mapping study.

## Case Report

A 32-year-old woman presented to us with multiple asymptomatic swellings over the scalp, face, neck, legs, and chest for the past 12 years with a progressive increase in size and number over the years. There was a history of similar lesions in her family including her mother, aunt, cousins, grandfather, and her elder child [Figure 1].

On examination, multiple, rounded, smooth surfaced, firm, non-tender, skin colored to reddish papules and nodules of varying sizes were seen on scalp and face [Figure 2]. Lesion was also extending to nose, arms, and legs [Figure 3]. Examination of mucosa, nails, and hair showed no abnormalities.

All the laboratory investigations were within the normal range. Computed tomography brain showed multiple lobulated masses over scalp and face, which could represent neoplastic or inflammatory pathology [Figure 4]. Biopsy was suggested for further evaluation. Gene mapping was done. The susceptibility locus has been mapped to chromosome 16q12-q13.

Fine needle aspiration was performed and smears were stained with May-Grünwald stain (MGG). The most distinctive feature in the aspirated material was the homogenous hyaline globules stained purple with MGG. These globules were surrounded by cohesive benign epithelial cells with dark uniform nuclei. The background was clean and no mitosis was noticed.

Surgical excision along with the skin grafting was performed to improve the facial appearance of the patient. Specimen was

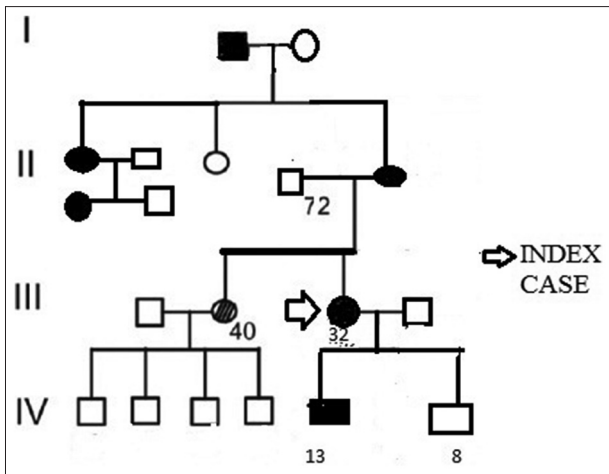
## Access this article online

### Quick Response Code:

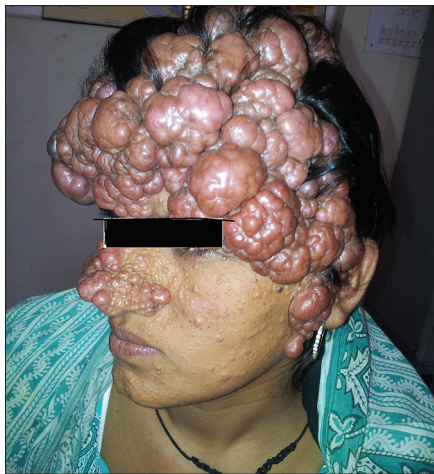

Website: [www.amhsr.org](http://www.amhsr.org)

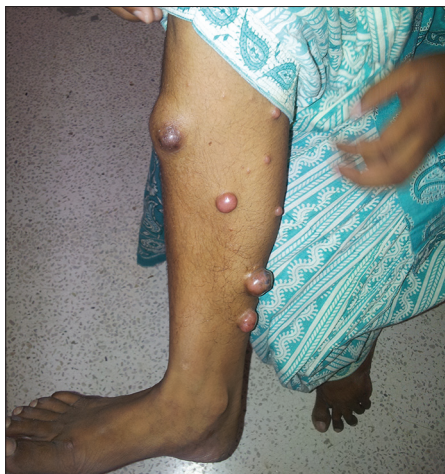DOI:  
10.4103/2141-9248.121207



**Figure 1:** Family pedigree chart showing affected members in four successive generations



**Figure 2:** Clinical photograph showing multiple papulonodular lesions on scalp and face



**Figure 3:** Patient showing multiple papulonodular lesions on leg

submitted in the histopathology section. On gross examination, the lesion was nodular with irregular surface [Figure 5]. Cut surface was solid and homogenously grey white.

Histopathologically, the lesion consisted of well-circumscribed islands of epithelial cells surrounded by a dense membrane material, and focally containing hyaline globules. Islands of epithelial cells fit together like pieces of “jig-saw” puzzle. Two distinct cell populations were seen; smaller peripheral basaloid cells in palisade arrangement and larger central cells with vesicular chromatin [Figure 6].

## Discussion

Term cylindroma was first introduced by Ansell in 1842.<sup>[3]</sup> Cylindromas occur as numerous papules, nodules or tumors of various sizes. Brooke-Spiegler syndrome (BSS) known as familial autosomal dominant cylindromatosis is a rare disorder characterized by various adnexal tumors including cylindromas, trichoepitheliomas, and spiradenomas.<sup>[4]</sup>

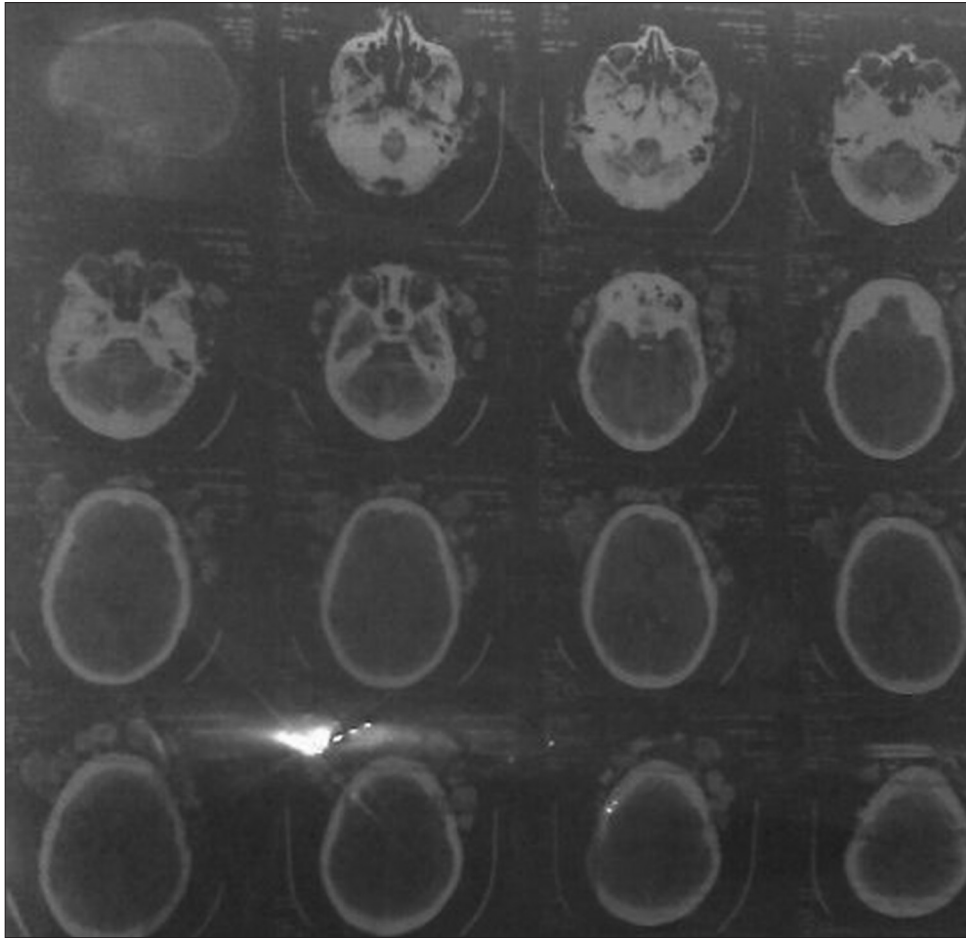
Cylindroma is a dermal tumor with no attachment to the epidermis. Tumor islands are composed of two cell types. Peripheral cells are small and highly basophilic. Larger, more pale-staining cells are seen centrally. The lesion is composed of numerous oval and polygonal nests molded into a jig-saw-like pattern. Masses of epithelial cells are surrounded and penetrated by a hyaline sheath closely resembling a basement membrane. This sheath separates the tumor from the dermal mesenchyme, yet does not interfere with tumor growth and proliferation.

Malignant cylindromas demonstrate islands of cells displaying marked anaplasia and pleomorphism of nuclei. Mitoses are increased and are abnormal. Besides invasion into surrounding tissue, loss of the delicate hyaline sheath occurs. Malignant transformation is rare. Death in such patients occur via visceral metastasis or hemorrhage or meningitis due to transcranial invasion/erosion.<sup>[5]</sup>

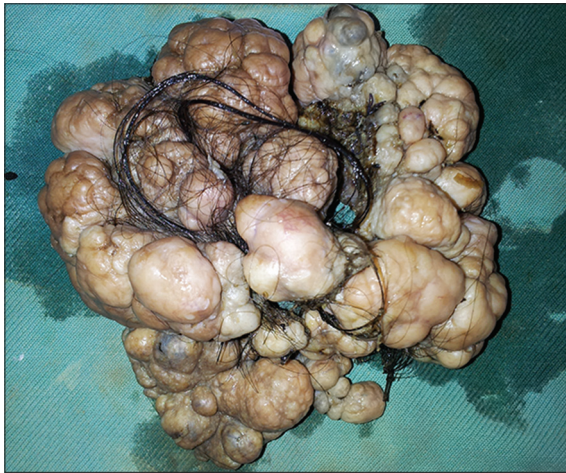FC is a condition involving multiple skin tumors that develop from structures associated with the skin (skin appendages), such as hair follicles and sweat glands. People with FC typically develop large numbers of tumors called cylindromas. Individuals with FC occasionally develop other types of tumors, including growths called spiradenomas and trichoepitheliomas.

Multiple cylindromas are usually seen as a component of BSS or as the only skin lesions of FC. Patients with BSS are predisposed to multiple skin appendage tumors such as cylindroma, trichoepithelioma, and spiradenoma. They are occasionally present in association with basal cell adenomas of the parotid glands, milia, organoid nevi, and basal cell carcinomas.<sup>[6,7]</sup>

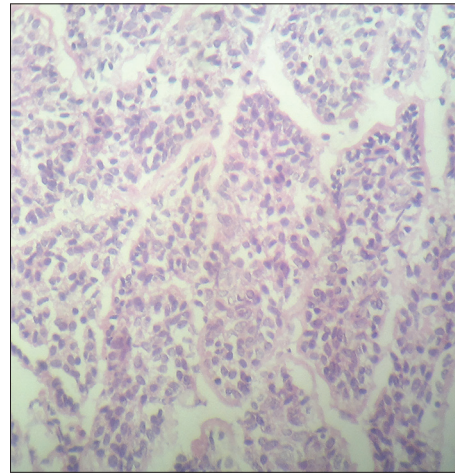
BSS as well as sporadic cylindromas results from mutations leading to loss of both alleles of the cylindromatosis gene (CYLD1). The CYLD gene is located on the long (q) arm of chromosome 16 at position 12.1. CYLD1 is a tumor suppressor gene, which has been shown to inhibit tumor cell



**Figure 4:** Computed tomography brain showing multiple lobulated masses over scalp and face



**Figure 5:** Gross photograph showing grayish brown growth with an irregular nodular surface



**Figure 6:** Photomicrograph of tumor composed of closely set tumor lobules forming mosaic-like masses with jigsaw puzzle pattern separated by thin bands of hyaline material (May-Grünwald, x400)

proliferation by blocking Bcl-3 dependent NF- $\kappa$ B signaling. Loss of CYLD1 function increases resistance to apoptosis.<sup>[8,9]</sup>

People with FC are born with a mutation in one of the two copies of the CYLD gene in each cell. For tumors to develop, a second mutation or deletion of genetic material involving the

other copy of the CYLD gene must occur in certain cells during a person's lifetime. There is no curative therapy yet available for multiple cylindromas. Treatment modalities for cylindromas include excision, dermabrasion, electrodesiccation, Carbon dioxide laser, cryotherapy, and radiotherapy. Currently, surgical excision or laser ablation is the treatment of choice in multiple



cylindromas multiple cylindromas usually require numerous tumor excisions or extensive plastic surgery with coverage by split thickness graft. Total scalp and forehead excision with coverage by skin grafts has been described in patients with turban tumors. Recently, a therapeutic attempt has been made to treat a single cylindroma in BSS with topically applied salicylic acid at varying concentrations. Salicylic acid acts by interfering with the NF- $\kappa$ B signaling pathway.<sup>[10,11]</sup>

Follow-up care of patients with multiple cylindromas is recommended because of the tendency for new lesions to develop. Follow-up care is also recommended because of the risk of malignant degeneration.

## Conclusion

This is a rare case of FC affecting many family members in the pedigree without association with other tumors involved in BSS and incidence of this case occurring now in the youngest member of the family.

## References

- Calonje E. Tumours of the skin appendages. In: Burns T, Breathnach S, Cox N, Griffiths C, editors. *Rook's Textbook of Dermatology*. 8<sup>th</sup> ed. Singapore: Wiley-Blackwell; 2010. p. 53.28-53.29.
- Nath AK, Udayashankar C. Multiple facial cylindromas: A case report. *Dermatol Online J* 2012;18:8.
- Ancell H. History of a remarkable case of tumours, developed on the head and face; accompanied with a similar disease in the abdomen. *Med Chir Trans* 1842;25:227-306.11.
- Lee DA, Grossman ME, Schneiderman P, Celebi JT. Genetics of skin appendage neoplasms and related syndromes. *J Med Genet* 2005;42:811-9.
- Elder ED, Elenitsas R, Murphy FG, Johnson LB, Xiaowei X. *Tumours of epidermal appendages. Lever's Histopathology of Skin* 2009. Philadelphia: Lippincott Williams and Wilkins; 2005. p. 881-3.
- Layegh P, Sharifi-Sistani N, Abadian M, Moghiman T. Brooke-Spiegler syndrome. *Indian J Dermatol Venereol Leprol* 2008;74:632-4.
- Taylor RS, Perone BJ, Kaddu S, Kerl H. Appendage tumors and hamartomas of the skin. In: Fitzpatrick TB, Wolff K, Goldsmith AL, Gilchrist AB, Paller SA, Leffell JD, editors. *Dermatology in General Medicine*. 7<sup>th</sup> ed. New York, NY: Mc-Graw-Hill; 2008. p. 1068-87.
- Massoumi R, Podda M, Fässler R, Paus R. Cylindroma as tumor of hair follicle origin. *J Invest Dermatol* 2006;126:1182-4.
- Manchanda K, Bansal M, Bhayana AA, Pandey S. Brooke-spiegler syndrome: A rare entity. *Int J Trichology* 2012;4:29-31.
- Rajan N, Trainer AH, Burn J, Langtry JA. Familial cylindromatosis and brooke-spiegler syndrome: A review of current therapeutic approaches and the surgical challenges posed by two affected families. *Dermatol Surg* 2009;35:845-52.
- Parren LJ, Bauer B, Hamm H, Frank J. Brooke-Spiegler syndrome complicated by unilateral hearing loss. *Int J Dermatol* 2008;47 Suppl 1:56-9.

**How to cite this article:** Dhir G, Makkar M, Suri V, Dubey VK. Familial dermal eccrine cylindromatosis with emphasis on histology and genetic mapping. *Ann Med Health Sci Res* 2013;3:S3-6.

**Source of Support:** Nil. **Conflict of Interest:** None declared.