

Combined lenvatinib and pembrolizumab as salvage therapy in advanced adrenal cortical carcinoma

Sara Bedrose ^{1,2}, Kevin Charles Miller,³ Lina Altameemi,¹ Mohamed S Ali,⁴ Sameh Nassar,⁵ Naveen Garg,⁵ Marilynne Daher,¹ Keith D Eaton,⁶ Jeffrey Thomas Yorio,⁷ Davey B Daniel,⁸ Matthew Campbell,⁹ Keith C Bible,¹⁰ Mabel Ryder,¹⁰ Ashish V Chintakuntlawar,¹⁰ Mouhammed Amir Habra ¹

To cite: Bedrose S, Miller KC, Altameemi L, *et al.* Combined lenvatinib and pembrolizumab as salvage therapy in advanced adrenal cortical carcinoma. *Journal for ImmunoTherapy of Cancer* 2020;**8**:e001009. doi:10.1136/jitc-2020-001009

SB and KCM contributed equally.

SB and KCM are joint first authors.

Accepted 18 June 2020

ABSTRACT

Background There is no effective systemic therapy for metastatic adrenal cortical carcinoma (ACC) after failure of platinum-based chemotherapy. The efficacies of single-agent oral multikinase inhibitors (MKIs) or salvage immune checkpoint inhibitors (CPIs) have been very limited. It is unknown whether combining CPIs, such as pembrolizumab (PEM), with other therapies, such as MKIs, could yield higher response rates in ACC, yet this combination has shown promise in other cancers. Herein, we describe the first case series using PEM in combination with the MKI lenvatinib (LEN) in patients with progressive, metastatic ACC.

Methods A retrospective case series describing the use of LEN/PEM as salvage therapy in patients with progressive/metastatic ACC.

Results Eight patients were treated with the LEN/PEM combination therapy. Half were female, and the median age at time of diagnosis was 38 years (range 21–49). Three (37.5%) patients had hormonally active ACC. The median number of prior lines of systemic therapy was 4 (range 2–9). Six (75%) patients had had disease progression on prior CPIs and five (62.5%) patients had progressed on prior MKI therapy. The median progression-free survival was 5.5 months (95% CI 1.8–not reached) and median duration of therapy was 8.5 months (range 2–22). Two (25%) patients had a partial response, one (12.5%) patient had stable disease, and five (62.5%) patients had progressive disease. None of the eight patients stopped therapy because of adverse events.

Conclusions In our small cohort of heavily pretreated patients with ACC, the combination of LEN/PEM was associated with objective responses in a subset of patients without significant toxicity. This combination should be formally investigated in phase II clinical trial with robust correlative studies to identify predictors for response.

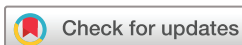BACKGROUND

Adrenal cortical carcinoma (ACC) is an aggressive malignancy that recurs in the vast majority of patients with a very high mortality rate. Both the rarity and aggressiveness of ACC have contributed to a lack of effective therapies to date. For recurrent/metastatic ACC, the combination of etoposide, doxorubicin, and

cisplatin (EDP), with or without mitotane, is considered the first-line treatment based on the First International Randomized Trial in Locally Advanced and Metastatic Adrenocortical Carcinoma Treatment (FIRM-ACT) trial.¹ However, this regimen (EDP+mitotane) has limited efficacy, as evidenced by an overall response rate of 23% and a median progression-free survival (PFS) of 5 months.² Salvage therapies for patients who progress after treatment with mitotane or cytotoxic chemotherapy are desperately needed.

Multiple trials have investigated the efficacy of vascular endothelial growth factor receptor (VEGFR) tyrosine kinase inhibitors in ACC, including sorafenib, axitinib, and sunitinib.^{3–4} However, these agents showed very limited efficacy as single-agent therapies for advanced ACC. Additionally, immune checkpoint inhibitors (CPIs) are an attractive option to investigate in ACC because of their efficacy in numerous solid malignancies. However, emerging data have shown limited efficacy for single-agent CPIs in ACC, with durable responses limited to a small subset of patients.^{5–7}

The combination of multikinase inhibitors (MKIs) with CPIs has shown promising data in multiple cancers.^{8–11} In particular, the MKI lenvatinib (LEN), which inhibits Vascular Endothelial Growth Factor Receptor 1–3 (VEGFR 1–3), Fibroblast Growth Factor Receptor 1–4 (FGFR 1–4), Platelet Derived Growth Factor Receptor- α (PDGFR- α), RET, and KIT, has been combined with the anti-PD-1 monoclonal antibody pembrolizumab (PEM) in phase I/II trials. Synergy between LEN and PEM is putatively due to LEN creating a more therapeutically advantageous tumor-immune microenvironment,¹² in part through blockade of immunosuppressive VEGFR signaling. This combination was approved by the United States Food and Drug Administration (FDA)



© Author(s) (or their employer(s)) 2020. Re-use permitted under CC BY-NC. No commercial re-use. See rights and permissions. Published by BMJ.

For numbered affiliations see end of article.

Correspondence to

Mouhammed Amir Habra;
mahabra@mdanderson.org

for advanced endometrial carcinoma in 2019,⁹ and is currently being studied as a salvage therapy for thyroid cancer,¹⁰ renal cell carcinoma,¹¹ head and neck cancer, and other solid tumors.⁸

There are no published data on use of the LEN/PEM combination in ACC. Herein, we report the clinical course of eight patients with recurrent/metastatic ACC who were treated with LEN/PEM, representing the first reported case series. The majority of the patients in our cohort progressed through several lines of therapy prior to LEN/PEM, including several who had previous disease progression while receiving single-agent CPIs and/or MKIs.

METHODS

Eight patients with recurrent and/or metastatic ACC were treated with combination LEN/PEM after disease progression on prior lines of therapy. After obtaining the Institutional Review Board approval, electronic medical records were reviewed. All pathologic diagnoses of ACC were confirmed on referral to MD Anderson and Mayo Clinic. The European Network for the Study of Adrenal Tumors staging system was used to define stage¹³ at the time of diagnosis. LEN and PEM were obtained through insurance or via patient assistance programs. LEN was administered orally at a starting dose of 24 mg (n=3), 20 mg (n=2), 18 mg (n=1), and 10 mg (n=2) according to clinicians' judgment about each patient's tolerability. PEM was administered intravenously at a dose of 200 mg every 3 weeks.

We used Response Evaluation Criteria in Solid Tumors (RECIST) V.1.1 criteria to evaluate objective response to prior lines of therapy and the LEN/PEM combination.¹⁴ PFS was defined as the time from the start of LEN/PEM combination therapy until either disease progression as defined by RECIST V.1.1 or death, whichever occurred first. Patients who remained alive and progression free were censored at the time of last follow-up, as of December 31, 2019. Median PFS, with 95% CIs, was estimated using

the Kaplan-Meier method. Adverse events (AEs) were evaluated using Common Terminology Criteria for Adverse Events (CTCAE) V.4.03.

RESULTS

Patient characteristics

Eight patients with ACC (four women, four men) were treated with LEN/PEM for recurrent/metastatic ACC. Their baseline characteristics and tumor genetics are summarized in [table 1](#). The median age at the time of diagnosis was 38 years (range 21–49). At diagnosis, three (37.5%) patients had stage IV ACC, while the remaining five (62.5%) patients developed metastases after their initial diagnosis with stage II (n=2) or III (n=3) ACC. Three (37.5%) patients had hormonally active ACC. Seven of the eight patients had somatic mutation testing for microsatellite instability or deficiency in mismatch repair genes and were found to be negative. The median number of prior lines of systemic therapy was four (range 2–9). Median time in months between initial ACC diagnosis and initiation of combination therapy was 42.5 months (range 5–86 months). Six (75%) patients had had disease progression while receiving prior CPIs, and five (62.5%) patients had progressed on prior MKI therapy (sorafenib, cabozantinib, and LEN, n=1; cabozantinib, n=2; single-agent LEN, n=2). No patients were on mitotane at the time of initiation of LEN/PEM therapy. Details of the individual patients' prior treatment modalities received are described in [table 2](#). All eight patients had progressive distant metastatic lesions on radiological staging scans prior to initiation of LEN/PEM combination therapy.

Efficacy of combined LEN and PEM

Objective responses are summarized in [table 3](#) as well as [figure 1](#). The median duration of LEN/PEM therapy

Table 1 Baseline characteristics

	Sex	Age at diagnosis (years)	Hormonal function	Stage at diagnosis	Sites of metastatic disease at initiation of LEN/PEM	Genetic findings
1	M	37	No	IV	Lungs, liver, bone	<i>PTEN</i> and <i>CDKN2B</i> mutations
2	F	22	No	III	Lung	No mutations
3	F	21	Yes	II	Lung, liver, adrenal bed	<i>TP53</i> mutation (germline)
4	M	39	No	IV	Liver, lung, retroperitoneum, and bone	No mutations
5	M	44	Yes	IV	Lung	<i>CDK4</i> , <i>MDM2</i> , and <i>CCND3</i> mutations
6	M	34	Yes	II	Lung, abdomen, and liver	<i>CTNNB1</i> and <i>TP53</i> mutation (germline)
7	F	41	No	III	Lung, abdomen, pelvis, and liver	<i>CTNNB1</i> , <i>ATRX</i> , <i>MUTYH</i> , and <i>RB1</i> mutations
8	F	49	No	II	Lung, abdomen, and liver	No mutations

LEN, lenvatinib; PEM, pembrolizumab.

Table 2 Lines of therapy as well as time since initial diagnosis until initiation of LEN and PEM combination therapy

Patient	Lines of therapy prior to LEN/PEM	PFS	Time since diagnosis till initiation of LEN/PEM therapy in months
1	1. Sorafenib	2 months	56 months
	2. Mitotane, etoposide, doxorubicin, and cisplatin	6 months	
	3. PD-1 inhibitor (nivolumab) and radiotherapy	4 months	
	4. ACAT inhibitor	3 months	
	5. Wee-1 inhibitor	4 months	
	6. Cabozantinib	2 months	
	7. PD-1 inhibitor (PEM) and LAG-3 inhibitor	4 months	
	8. Gemcitabine and capecitabine	4 months	
	9. LEN (single-agent)	12 months	
2	1. Mitotane	7 months	66 months
	2. PD-1 inhibitor (nivolumab)	5 months	
	3. CSF-1R inhibitor and PD-1 inhibitor (PEM)	2 months	
	4. Etoposide, doxorubicin, and cisplatin	2 months	
3	1. Mitotane	36 months	68 months
	2. Etoposide, doxorubicin, and cisplatin	1 month	
	3. Ipilimumab and PD-1 inhibitor (nivolumab)	2 months	
	4. LEN (single-agent)	6 months	
4	1. Mitotane and adjuvant radiotherapy	18 months	86 months
	2. Mitotane, etoposide, doxorubicin, and cisplatin	13 months	
	3. PD-1 inhibitor (PEM)	6 months	
	4. Carboplatin, etoposide, and mitotane	13 months	
	5. Cabozantinib	6 months	
5	1. Mitotane, etoposide, doxorubicin, and cisplatin	7 months	29 months
	2. Mitotane (single-agent)	5 months	
	3. PI3K inhibitor and PD-1 inhibitor (nivolumab)	4 months	
	4. Cabozantinib	2 months	
6	1. Etoposide, doxorubicin, and cisplatin	6 months	24 months
	2. Etoposide	3 months	
	3. Gemcitabine and docetaxel	1 month	
	4. Cyclophosphamide, vincristine, and dacarbazine	2 months	
	5. PD-1 inhibitor (PEM)	1 month	
7	1. Etoposide, doxorubicin, and cisplatin	1 month	5 months
	2. Gemcitabine and docetaxel	1 month	
8	1. Mitotane and adjuvant radiotherapy	4 months	10.5 months
	2. Mitotane, etoposide, doxorubicin, and cisplatin	1 month	
	3. Gemcitabine and docetaxel	3 months	
	4. LEN (single-agent)	1 month	

LEN, lenvatinib; PEM, pembrolizumab; PFS, progression-free survival.

was 8.5 months (range 2–22). Two (25%) patients had a partial response (PR) to the combination therapy: one patient had a maximum 90% reduction in tumor burden

at 19 months after initiating the combination therapy (figure 2); the other had 33% reduction in tumor burden at 9 months. One (12.5%) patient had stable disease (SD) with the LEN/PEM combination, lasting 8 months. Five (62.5%) patients developed progressive disease while receiving the combination therapy. The median PFS from the time of initiation of LEN/PEM for all eight patients was 5.5 months (95% CI 1.8–not reached, figure 3). Median duration of therapy was 8.5 months from the time of initiation of LEN/PEM therapy until either cessation of combination therapy (n=6) or last follow-up (n=2).

Adverse events

LEN/PEM combination therapy was well tolerated in our cohort of patients, and there were no severe AEs (CTCAE grade ≥ 3) during therapy. Grade 1–2 AEs were hand and foot syndrome (n=4), fatigue (n=4), hypertension (n=4), diarrhea (n=1), and acneiform rash (n=1). AEs detected by clinical laboratory testing were mild microcytic anemia (n=2), thyroid-stimulating hormone elevation (n=1), and transaminitis (n=1). None of the eight patients stopped LEN/PEM because of AEs.

DISCUSSION

To our knowledge, this is the first reported case series describing the use of MKIs in combination with Immune Checkpoint Inhibitor (ICPIs) as salvage therapy in recurrent/metastatic ACC. The clinical benefit rate from the combination therapy in our case series was 37.5%, with two patients achieving PR and one patient achieving SD lasting 8 months at the time of last follow-up. Observed responses occurred with LEN/PEM despite progression on multiple lines of prior therapy, including single-agent MKIs or CPIs.

VEGFR tyrosine kinase inhibitors have minimal single-agent efficacy in recurrent/metastatic ACC, with phase I/II trials of sorafenib plus metronomic paclitaxel,³ sunitinib,¹⁵ and axitinib⁴ showing no objective responses in a total of 61 patients. One putative contributor to this lack of efficacy is that mitotane, which is often employed with chemotherapy in ACC, significantly interferes with the pharmacokinetics due to marked cytochrome P450-3A4 induction. Another reason is that multiple tyrosine kinases are important for the malignant properties of ACC,^{16–18} including cMET and FGFR4. Thus, cabozantinib (a MKI that targets cMET, as well as VEGFR, AXL, and RET, and that is FDA approved in several solid tumor types) is now undergoing two parallel phase II studies (NCT03370718 and NCT03612232) in ACC. LEN targets FGFR 1–4 as well as VEGFR 1–3, PDGFR- α , RET, and KIT, but there are currently no ongoing clinical trials with single-agent LEN in ACC.

Meanwhile, several recent clinical trials have investigated using CPIs as a salvage therapy in ACC, although with limited efficacy. Le Tourneau *et al* reported the results of a study in which 50 patients with advanced ACC were treated with avelumab; the objective response rate

Table 3 Duration and outcomes of LEN/PEM combination therapy

Patient	Duration of LEN/PEM therapy	PFS	Status at time of last follow-up*	Patient on treatment at time of data cut-off
1	22 months	19 months	AWD	Yes
2	10 months	6 months	AWD	Yes
3	2 months	2 months	AWD	No
4	10 months	5 months	AWD	Yes
5	8 months	8 months	AWD	Yes
6	3 months	2 months	DOD	No
7	3 months	3 months	DOD	No
8	9 months	9 months	AWD	Yes

*Date of data cut-off: December 31, 2019.

AWD, alive with disease; DOD, died of disease; LEN, lenvatinib; PEM, pembrolizumab; PFS, progression-free survival.

was 6%, with a median PFS of just 2.6 months.⁶ Another trial where 10 patients were treated with nivolumab had similar results, with no confirmed objective responses and a median PFS of 1.8 months.¹⁹ Interestingly, Raj *et al* recently reported the results of treating 39 patients with single-agent PEM, with an objective response rate of 23%, and a small subset of patients achieving durable responses despite a median PFS of just 2.1 months.⁷ The investigators were unable to confirm any biomarkers that predicted for response, including PD-L1 staining, tumor-infiltrating lymphocyte score, or tumor mutational burden, but the findings did suggest that microsatellite-high and/or mismatch repair-deficient tumors were enriched for responses.

It is unknown whether combining CPIs with other therapies could yield higher response rates in ACC—the subject of this report. A small case series of six patients suggested that mitotane might augment the effect of CPIs, which was postulated to occur via immune micro-environment modulation.²⁰ In point of fact, the possible synergistic effect of the LEN/PEM combination might alternatively be in part due to the effect of LEN on the tumor microenvironment.^{12 21–23} Interestingly, LEN/PEM combination therapy has demonstrated promising anti-tumor activity in multiple cancers, including endometrial carcinoma⁹ and renal cell carcinoma.¹¹

This report demonstrates the ability of the LEN/PEM combination to produce objective responses in few

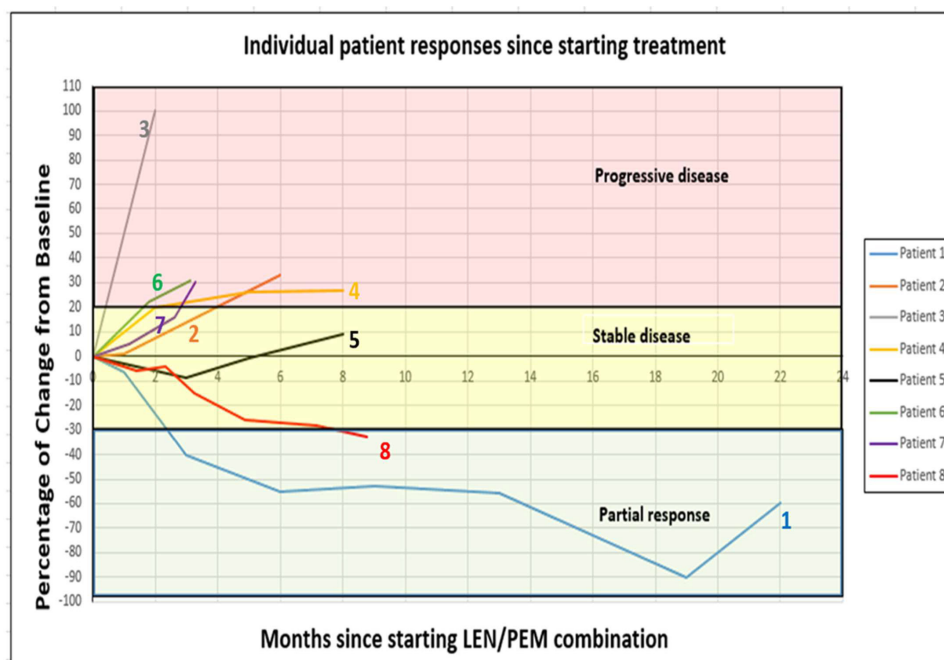


Figure 1 Individual patient responses to the combination of LEN/PEM. Spider plot depicts the change in tumor size (based on RECIST V.1.1) over time for each of the eight patients in the study, starting from initiation of LEN/PEM therapy. Based on percentage change from baseline tumor burden, responses were categorized as PR, SD, or PD. All patients had representative scans included until the time of progression or last follow-up. LEN, lenvatinib; PD, progressive disease; PEM, pembrolizumab; PR, partial response; SD, stable disease.

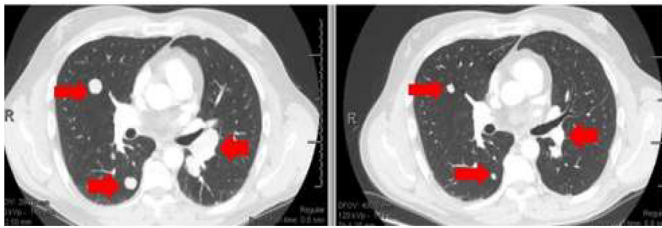


Figure 2 Representative CT chest images for patient #1, before and 3 months after starting LEN/PEM therapy. A PR of multiple lung metastases is illustrated (red arrows). LEN, lenvatinib; PEM, pembrolizumab; PR, partial response.

patients with heavily pretreated ACC. However, the lack of objective responses in six (75%) of the eight patients in our cohort suggests that the plurality of resistance mechanisms mitigating the activity of single-agent MKIs and CPIs are likely present in the context of combination therapy as well.

It is important to notice that none of the eight patients in our cohort had to discontinue LEN/PEM because of toxicity, and generally AEs were managed with dose modifications of LEN. Given the poor prognosis of ACC, particular attention should be paid to quality of life of patients being treated with these therapies in future prospective trials.

The limitations of our report include the potential for selection bias given that patients were referred to tertiary care centers, selecting for patients with greater baseline healthcare access, and possibly more indolent tumor biology. Further, our small sample size precludes the ability to make conclusions about the broader safety or efficacy of this combination. In addition, we did not have consistent genomic analysis of the tumor samples.

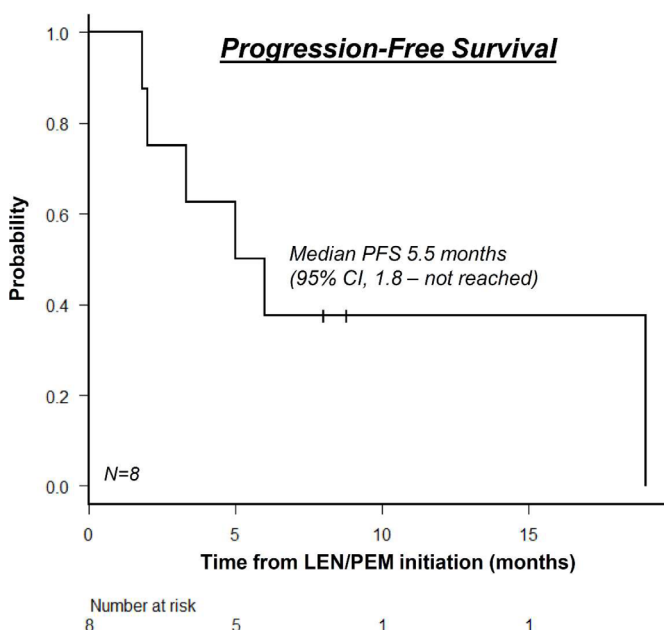


Figure 3 PFS from the time of initiation of LEN/PEM combination therapy. The median PFS was 5.5 months (95% CI 1.8–not reached). LEN, lenvatinib; PEM, pembrolizumab; PFS, progression-free survival.

Interestingly, two of the patients with the shortest PFS were cortisol producing which are patient 3 and patient 6 (PFS of 2 months for each) which raises the question if cortisol production may be associated with worse response to the therapy. However, Patient 5 who had SD with a PFS of 8 months was also cortisol producing; thus cortisol production status was not one of the predictors of poor response to LEN/PEM combination therapy in this particular case. Also, it should be noted that patients 3 and 6 had germline T53 mutation. It is unclear if T53 mutation is associated with worse response to combination therapy. Finally, we could not make conclusions regarding predictors of response to therapy, given the small sample size and relatively low rate of objective response.

In summary, ACC is a devastating malignancy with a paucity of effective therapies. The combination of LEN/PEM represents a salvage strategy for a subset of patients but should be formally investigated in phase II clinical trials with robust correlative studies to identify predictors for response.

Author affiliations

¹Department of Endocrine Neoplasia and Hormonal Disorders, Unit 1461, University of Texas MD Anderson Cancer Center, Houston, Texas, USA

²Section of Endocrinology, Diabetes and Metabolism, Baylor College of Medicine, Houston, Texas, USA

³School of Medicine, Mayo Clinic, Rochester, Minnesota, USA

⁴Section of Endocrinology, Diabetes and Metabolism, University of Texas Health Science Center at Houston, Houston, Texas, USA

⁵Department of Abdominal Imaging, University of Texas MD Anderson Cancer Center, Houston, Texas, USA

⁶Department of Medical Oncology, University of Washington, Seattle, Washington, USA

⁷Texas Oncology Austin Central, Austin, Texas, USA

⁸Tennessee Oncology, Chattanooga, Tennessee, USA

⁹Department of Genitourinary Medical Oncology, University of Texas MD Anderson Cancer Center, Houston, Texas, USA

¹⁰Division of Medical Oncology, Mayo Clinic, Rochester, Minnesota, USA

Twitter Jeffrey Thomas Yorio @jeffyorio

Acknowledgements Editorial assistance was provided by Sunita Patterson, Scientific Publications Services, Research Medical Library, MD Anderson Cancer Center, Houston, Texas, USA.

Contributors SB and KCM contributed equally as joint co-first authors. All authors have contributed to literature review, manuscript writing, creating figures and tables and have agreed to the final version of the manuscript.

Funding Supported in part by the National Institutes of Health/National Cancer Institute under award number P30CA016672 (used the Clinical Trials Office).

Competing interests KDE has received research funding from Mirati Therapeutics. MAH has received research funding from Exelixis. AVC received funding from Eisai Inc and Merck Inc for clinical trial unrelated to this work (both institutional grants).

Patient consent for publication Not required.

Ethics approval Two IRB-approved protocols were obtained to conduct this retrospective study (protocol PA12-0933 at The University of Texas MD Anderson Cancer Center and protocol 18-010500 at Mayo Clinic).

Provenance and peer review Not commissioned; externally peer reviewed.

Data availability statement All data relevant to the study are included in the article or uploaded as supplementary information.

Open access This is an open access article distributed in accordance with the Creative Commons Attribution Non Commercial (CC BY-NC 4.0) license, which permits others to distribute, remix, adapt, build upon this work non-commercially, and license their derivative works on different terms, provided the original work is

properly cited, appropriate credit is given, any changes made indicated, and the use is non-commercial. See <http://creativecommons.org/licenses/by-nc/4.0/>.

ORCID iDs

Sara Bedrose <http://orcid.org/0000-0003-1396-6384>

Mouhamed Amir Habra <http://orcid.org/0000-0002-4148-9637>

REFERENCES

- Fassnacht M, Terzolo M, Alolio B, et al. Combination chemotherapy in advanced adrenocortical carcinoma. *N Engl J Med* 2012;366:2189–97.
- Berruti A, Terzolo M, Pia A, et al. Mitotane associated with etoposide, doxorubicin, and cisplatin in the treatment of advanced adrenocortical carcinoma. Italian group for the study of adrenal cancer. *Cancer* 1998;83:2194–200.
- Berruti A, Sperone P, Ferrero A, et al. Phase II study of weekly paclitaxel and sorafenib as second/third-line therapy in patients with adrenocortical carcinoma. *Eur J Endocrinol* 2012;166:451–8.
- O'Sullivan C, Edgerly M, Velarde M, et al. The VEGF inhibitor axitinib has limited effectiveness as a therapy for adrenocortical cancer. *J Clin Endocrinol Metab* 2014;99:1291–7.
- Habra MA, Stephen B, Campbell M, et al. Phase II clinical trial of pembrolizumab efficacy and safety in advanced adrenocortical carcinoma. *J Immunother Cancer* 2019;7:253.
- Le Tourneau C, Hoimes C, Zarwan C, et al. Avelumab in patients with previously treated metastatic adrenocortical carcinoma: phase 1B results from the javelin solid tumor trial. *J Immunother Cancer* 2018;6:111.
- Raj N, Zheng Y, Kelly V, et al. Pd-1 blockade in advanced adrenocortical carcinoma. *J Clin Oncol* 2020;38:71–80.
- Taylor MH, Lee C-H, Makker V, et al. Phase Ib/II trial of lenvatinib plus pembrolizumab in patients with advanced renal cell carcinoma, endometrial cancer, and other selected advanced solid tumors. *J Clin Oncol* 2020;38:1154–63.
- Makker V, Rasco D, Vogelzang NJ, et al. Lenvatinib plus pembrolizumab in patients with advanced endometrial cancer: an interim analysis of a multicentre, open-label, single-arm, phase 2 trial. *Lancet Oncol* 2019;20:711–8.
- Iyer PC, Dadu R, Gule-Monroe M, et al. Salvage pembrolizumab added to kinase inhibitor therapy for the treatment of anaplastic thyroid carcinoma. *J Immunother Cancer* 2018;6:68.
- Grünwald V, Powles T, Choueiri TK, et al. Lenvatinib plus everolimus or pembrolizumab versus sunitinib in advanced renal cell carcinoma: study design and rationale. *Future Oncol* 2019;15:929–41.
- Capozzi M, De Divitiis C, Ottaiano A, et al. Lenvatinib, a molecule with versatile application: from preclinical evidence to future development in anti-cancer treatment. *Cancer Manag Res* 2019;11:3847–60.
- Fassnacht M, Johanssen S, Quinkler M, et al. Limited prognostic value of the 2004 International Union against cancer staging classification for adrenocortical carcinoma: proposal for a revised TNM classification. *Cancer* 2009;115:243–50.
- Eisenhauer EA, Therasse P, Bogaerts J, et al. New response evaluation criteria in solid tumours: revised RECIST guideline (version 1.1). *Eur J Cancer* 2009;45:228–47.
- Kroiss M, Quinkler M, Johanssen S, et al. Sunitinib in refractory adrenocortical carcinoma: a phase II, single-arm, open-label trial. *J Clin Endocrinol Metab* 2012;97:3495–503.
- Kroiss M, et al. Sunitinib inhibits cell proliferation and alters steroidogenesis by down-regulation of HSD3B2 in adrenocortical carcinoma cells. *Front Endocrinol* 2011;2:27.
- Brito LP, Ribeiro TC, Almeida MQ, et al. The role of fibroblast growth factor receptor 4 overexpression and gene amplification as prognostic markers in pediatric and adult adrenocortical tumors. *Endocr Relat Cancer* 2012;19:L11–13.
- Phan LM, Fuentes-Mattei E, Wu W, et al. Hepatocyte growth factor/cMET pathway activation enhances cancer hallmarks in adrenocortical carcinoma. *Cancer Res* 2015;75:4131–42.
- Carneiro BA, Konda B, Costa RB, et al. Nivolumab in metastatic adrenocortical carcinoma: results of a phase 2 trial. *J Clin Endocrinol Metab* 2019;104:6193–200.
- Head L, Kiseljak-Vassiliades K, Clark TJ, et al. Response to immunotherapy in combination with mitotane in patients with metastatic adrenocortical cancer. *J Endocr Soc* 2019;3:2295–304.
- Kimura T, Kato Y, Ozawa Y, et al. Immunomodulatory activity of lenvatinib contributes to antitumor activity in the Hepa1-6 hepatocellular carcinoma model. *Cancer Sci* 2018;109:3993–4002.
- Yi M, Jiao D, Qin S, et al. Synergistic effect of immune checkpoint blockade and anti-angiogenesis in cancer treatment. *Mol Cancer* 2019;18:60.
- Nuti M, Zizzari IG, Botticelli A, et al. The ambitious role of anti angiogenesis molecules: turning a cold tumor into a hot one. *Cancer Treat Rev* 2018;70:41–6.