

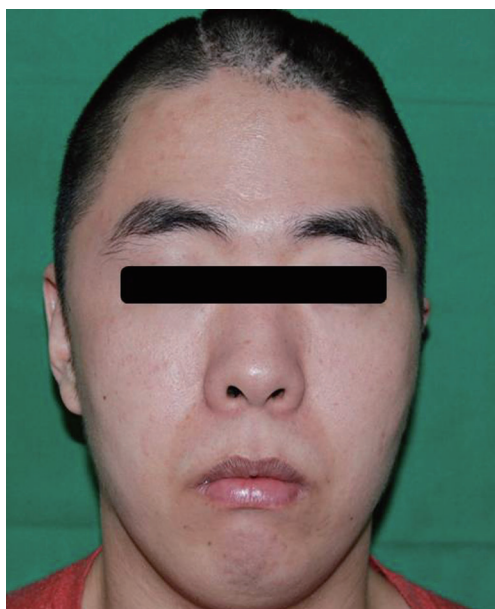Fig. 5.
Postoperative view after one month.

including infection and allergic reaction, and its use should definitely be avoided in the case of children, whose bones have not yet stopped growing. In the case of the sixteen-year-old patient in this study, while alloplastic cranioplasty was possible, as the growth of the skull bone was nearly complete, the patient and his guardian decided upon autologous cranioplasty. In cases of large autologous cranioplasty, such as the one reported in this study, using a patient-specific 3D model as a preoperative procedure can have several advantages. First, donor site complications can be reduced by performing a simulated operation using the 3D model in advance. Respiratory complications that can occur in split-rib cranioplasty can also be reduced with minimal rib resection. Second, aesthetically satisfactory results can be achieved. If resection is performed after preoperatively determining the ideal rib portion that best matches the defect's curvature through a 3D model, the surgeon can find the ideal portion of rib bone that will cover the skull defect.

Medical limitations can be overcome when new technology is introduced. Rapid advances in 3D printing technology have positively affected its application in the field of cosmetic surgery. Using various patient-specific 3D models in alloplastic cranioplasty addresses a number of limitations for various procedures. However, the application of 3D printing technology in autologous cranioplasty is limited. This study reports notable results when a 3D

printing model is utilized in autologous cranioplasty. Further studies are needed to verify the effectiveness of 3D printing technology in autologous cranioplasty.

References

1. Aydin S, Kucukyuruk B, Abuzayed B, et al. Cranioplasty: review of materials and techniques. *J Neurosci Rural Pract* 2011;2:162-7.
2. Moreira-Gonzalez A, Jackson IT, Miyawaki T, et al. Clinical outcome in cranioplasty: critical review in long-term follow-up. *J Craniofac Surg* 2003;14:144-53.
3. Gladstone HB, McDermott MW, Cooke DD. Implants for cranioplasty. *Otolaryngol Clin North Am* 1995;28:381-400.
4. Iwama T, Yamada J, Imai S, et al. The use of frozen autogenous bone flaps in delayed cranioplasty revisited. *Neurosurgery* 2003;52:591-6.
5. Dean D, Min KJ, Bond A. Computer aided design of large-format prefabricated cranial plates. *J Craniofac Surg* 2003;14:819-32.

Post-Traumatic Cutaneous Meningioma

Francisco Javier Pacheco Compañía¹, José Midón Míguez¹,
Edgar Mauricio Avellaneda Oviedo¹,
Eladio Busto Lodeiro²

*Departments of ¹Plastic Surgery and ²Pathology, Complejo
Hospitalario Universitario de A Coruña, A Coruña, Spain*

Correspondence: Francisco Javier Pacheco Compañía
Department of Plastic Surgery, Complejo Hospitalario Universitario de A
Coruña, Calle As Xubias, N° 84. CP: 15006, A Coruña, Spain
Tel: +34-651517226, Fax: +34-952702871
E-mail: javipacheco25@hotmail.com

No potential conflict of interest relevant to this article was reported.

Received: 23 Oct 2015 • Revised: 31 Jan 2016 • Accepted: 15 Feb 2016
pISSN: 2234-6163 • eISSN: 2234-6171
<http://dx.doi.org/10.5999/aps.2016.43.4.381>
Arch Plast Surg 2016;43:381-384



Copyright © 2016 The Korean Society of Plastic and Reconstructive Surgeons
This is an Open Access article distributed under the terms of the Creative Commons
Attribution Non-Commercial License (<http://creativecommons.org/licenses/by-nc/4.0/>)
which permits unrestricted non-commercial use, distribution, and reproduction in any
medium, provided the original work is properly cited.

Neurological tumors pose considerable challenges from the point of view of diagnosis and therapeutic management. Their location makes them difficult to study and to approach surgically, especially when

they are located within the skull or in the spinal canal. In contrast, skin tumors tend to be easier to identify and to approach surgically. We report the case of a patient with a neurological tumor that behaved like a skin tumor: a cutaneous meningioma secondary to a skull fracture.

A 51-year-old male with a history of a motorcycle accident that caused a skull fracture in the left temporoparietal region 15 years previously was referred to our outpatient clinic. He presented with a tumor that had increased in size over the previous four years in that area (Fig. 1A). A biopsy of the tumor revealed a cutaneous meningioma. An imaging study using magnetic resonance imaging (MRI) showed encephalomalacia with discrete foci of reactive gliosis in the frontal, medium, and temporal left gyrus. A left temporoparietal fracture, which may have been old, was identified, as well as a $24 \times 38 \times 39$ -mm mass of extracranial soft tissue reaching the skin (Fig. 1B). No infiltrations of the underlying bone or intracranial components were observed.

A bloc resection was performed, including a skin segment infiltrated by the tumor, the aponeurotic galea, the temporal muscle, and cranial periosteum, without affecting the bone (Fig. 2A). A paresis of the frontal branch of the left facial nerve was identified during follow-up in our outpatient clinic. An electrophysiological study was requested two months after the surgery, and a partial axonal injury was observed in the frontal branch of the left facial nerve, showing signs of reinnervation.

A histological study revealed multiple nests of elongated cells exhibiting a swirling pattern and with little nuclear pleomorphism. The tumor displayed an infiltrative character, infiltrating adipose tissue and muscle tissue (Fig. 3). It was located less than 1 mm from the deep surgical margin. An

immunohistochemical study was performed, and the tumor cells tested positive for vimentin, epithelial membrane antigen (EMA), and progesterone. MIB-1 proliferation index was approximately 3% of the total cell volume.

Seven months after surgery, the patient remains asymptomatic and has regained full mobility of the left frontal muscle (Fig. 2B).

Meningiomas are the most common tumors of neurological origin in adults, accounting for 15%–30% of all intracranial neoplasms [1]. They most commonly present intracranially. Extracranial meningiomas represent 1%–2% of all meningiomas [2]. The ectopic location of these tumors outside the central nervous system can result from the direct extension of intracranial tumors through the foramina, metastatic meningiomas, or meningiomas of primary origin.

Within primary ectopic meningiomas, cutaneous meningiomas are a rare anatomical variant. In 1974, Lopez et al. [3] classified cutaneous meningiomas into three groups. The first group (type I) is congenital. It presents at birth and usually appears on the scalp and paravertebral skin. It is caused by ectopic arachnoid cells trapped in the dermis and subcutaneous tissue during embryonic development.

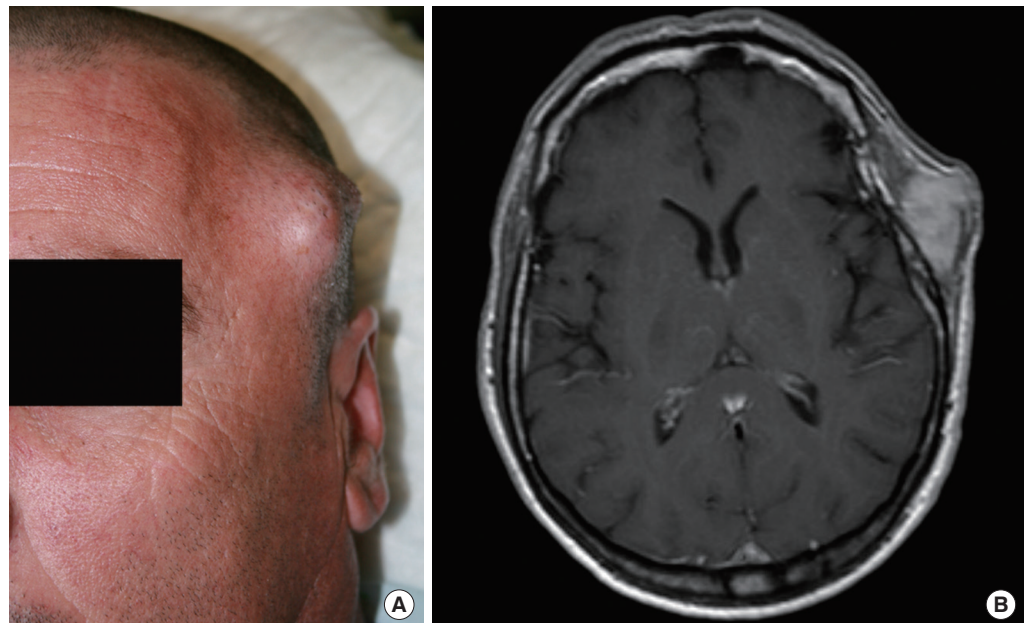


Fig. 1.
(A) Skin tumor in the temporoparietal region.
(B) T2-weighted magnetic resonance imaging. The tumor is hyperintense relative to the gray matter.

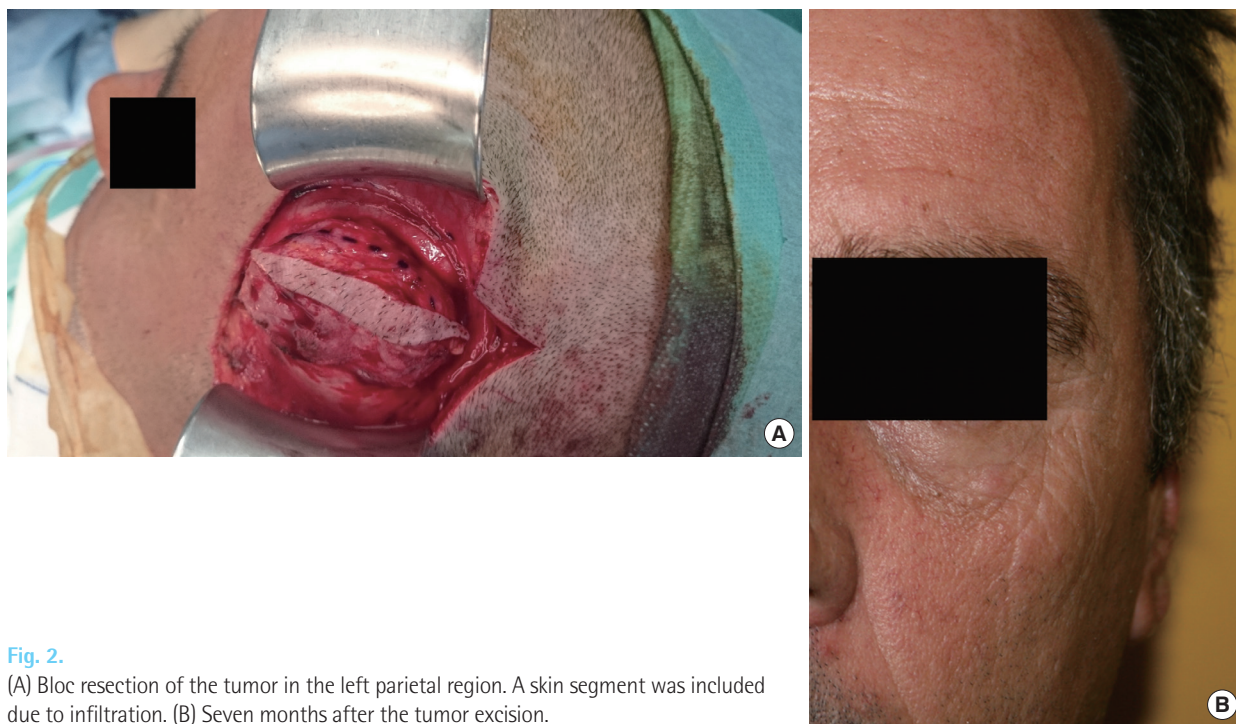


Fig. 2.

(A) Bloc resection of the tumor in the left parietal region. A skin segment was included due to infiltration. (B) Seven months after the tumor excision.

The second group (type II) consists of meningiomas extending to the skin through contiguity. They tend to appear in areas surrounding the eyes, ears, nose, and mouth. It has been hypothesized that they are formed by the remnants of arachnoid cells that extend through the cranial and spinal nerves [1]. The third group (type III) comprises meningiomas that have spread to the skin from intracranial tumors, traumatic defects, or surgical procedures. These tumors are more common in adults.

It has been postulated that post-traumatic cutaneous meningiomas appear due to the interruption of the craniofacial bone structures and the underlying meninges, leading to meningeal tissue migration within the dermis and resulting in a tumor some years later [2]. In our case, we observed a cutaneous meningioma belonging to type III according to Lopez's classification. Type III tumors are uncommon, although some cases of post-traumatic cutaneous meningioma have been reported in the literature [2,4,5].

Although the first group is composed of congenital tumors, they generally are not diagnosed until some years have passed. The mean age for the diagnosis of tumors belonging to the second group is 48 years, and 54 years for type III. The female-to-male ratio is 4:5. Pregnancy has been associated with tumor growth, in relation to baseline hormonal disorders.

In most cases, these tumors appear as firm

subcutaneous nodules. They are usually painless, but some cases have been reported in which the patient felt local pain. They can cause bone erosion and cystic cavities. Type II tumors can produce cranial nerve disorders.

The preferred imaging modality for these tumors is MRI, in which these tumors appear isointense relative to the gray matter on T1-weighted images and hyperintense on T2-weighted images [2].

The treatment of choice is surgical resection. The prognosis depends on the type of tumor. Type I tumors have a good prognosis after surgical resection, and cases of recurrence have not been documented. Type II and III tumors have less favorable prognoses, especially type III tumors with intracranial involvement. In our case, the patient remains free of signs of recurrence seven months after surgery.

Therapies using vascular endothelial growth factor and platelet-derived growth factor inhibitors are currently under investigation. In cases where complete resection is not possible, radiotherapy may be indicated.

The histological study of these tumors shows spindle-shaped cells with round nuclei arranged in small clusters. Immunohistochemical assays are positive for vimentin and epithelial membrane antigen, and negative for cytokeratin, S-100 protein, CD31, CD34, and actin [1].

In conclusion, cutaneous meningioma is a rare

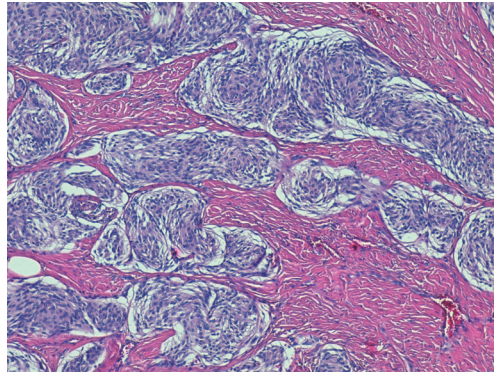


Fig. 3. Histological study (H&E, × 100). Multiple nests of elongated cells are found, with a swirling pattern and with little nuclear pleomorphism.

neurological tumor that presents as a skin tumor. This kind of tumor must be considered in patients with previous craniofacial fractures. The diagnosis requires an initial imaging study to confirm the intracranial or extracranial origin of the tumor. For this reason, preoperative MRI helps ensure that complications during the surgery are avoided.

ORCID

Francisco Javier Pacheco Compañía

<http://orcid.org/0000-0003-2791-5799>

References

1. Juarez A, Dominguez-Fernandez I, Santiago-Sanchez-Mateos D, et al. Cutaneous meningioma: extracranial extension from an intracranial tumour. *Clin Exp Dermatol* 2009;34:e1001-3.
2. Walters GA, Ragland RL, Knorr JR, et al. Posttraumatic cutaneous meningioma of the face. *AJNR Am J Neuroradiol* 1994;15:393-5.
3. Lopez DA, Silvers DN, Helwig EB. Cutaneous meningiomas--a clinicopathologic study. *Cancer* 1974;34:728-44.
4. Borggreven PA, de Graaf FH, van der Valk P, et al. Post-traumatic cutaneous meningioma. *J Laryngol Otol* 2004;118:228-30.
5. Francois P, N'Dri D, Bergemer-Fouquet AM, et al. Post-traumatic meningioma: three case reports of this rare condition and a review of the literature. *Acta Neurochir (Wien)* 2010;152:1755-60.

Cross-Leg Flap-Sharing Technique Using an Anterolateral Thigh Perforator Flap

Sa Hyeok Hong¹, Euicheol C. Jeong², Gordon K. Lee³

¹Department of Plastic and Reconstructive Surgery, Seoul National University Hospital, Seoul National University College of Medicine, Seoul; ²Department of Plastic and Reconstructive Surgery, SMG-SNU Boramae Medical Center, Seoul, Korea;

³Division of Plastic and Reconstructive Surgery, Stanford University Medical Center, Palo Alto, CA, USA

Correspondence: Euicheol C. Jeong

Department of Plastic Surgery, SMG-SNU Boramae Medical Center, 20 Boramae-ro 5-gil, Dongjak-gu, Seoul 07061, Korea
Tel: +82-2-870-2331, Fax: +82-2-831-2826, E-mail: ejeong.md@gmail.com

This article was presented as an E-presentation at Plastic and Reconstructive Surgery (PRS) Korea 2015 on November 13–15, 2015 in Seoul, Korea.

No potential conflict of interest relevant to this article was reported.

Received: 18 Nov 2015 • Revised: 18 Jan 2016 • Accepted: 7 Feb 2016

pISSN: 2234-6163 • eISSN: 2234-6171
<http://dx.doi.org/10.5999/aps.2016.43.4.384>
Arch Plast Surg 2016;43:384-387

Copyright © 2016 The Korean Society of Plastic and Reconstructive Surgeons
This is an Open Access article distributed under the terms of the Creative Commons Attribution Non-Commercial License (<http://creativecommons.org/licenses/by-nc/4.0/>) which permits unrestricted non-commercial use, distribution, and reproduction in any medium, provided the original work is properly cited.



The need for free tissue transfer to cover defects of the lower legs has been increasing due to the rise in the number of diabetic patients and traumatic injuries, and free tissue transfer has therefore become more popular over the past few decades. It allows for the transfer of well-vascularized tissue to the wound site in a single stage, which leads to early ambulation and improved quality of life. Free tissue transfer has frequently been used to treat defects in the lower extremity associated with trauma, but it has been performed with more reluctance in patients with vascular disease due to the lack of recipient vessels and the poor general condition of such patients, which interferes with prolonged anesthesia. If no acceptable recipient vessel is present in the wounded leg, cross-leg free flaps are available in the extremities. Selecting vessels in the contralateral lateral limb to cover the ipsilateral defect can play an effective role in providing sufficient blood circulation to the transferred tissue [1-3]. The flap-sharing technique was employed in the reconstruction of two feet wounds due to atherosclerosis, using one flap and a single recipient vessel in the foot to minimize the operation time under general anesthesia.