

# Crouzon Syndrome Associated with Congenital Coarctation of Aorta

Bing Meng, Hui Zhang

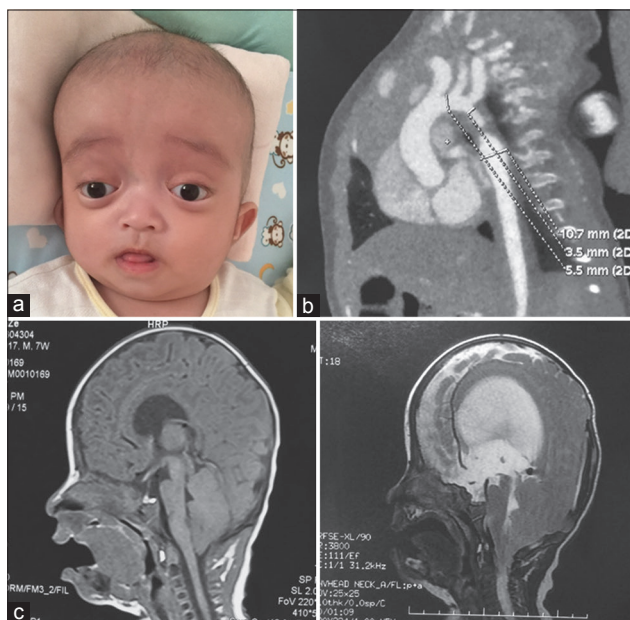
Department of Cardiac Surgery, Children's Hospital Affiliated to the Capital Institute of Pediatrics, Beijing 100020, China

To the Editor: Crouzon Syndrome (CS), also known as craniosynostosis, is an autosomal dominant genetic disorder linked to single-gene mutation of fibroblast growth factor receptor 2 (*FGFR2*).<sup>[1-3]</sup> The premature fusion of certain skull bones results in a series of dysmorphic features including underdeveloped maxilla, protruded mandible, shallow orbits, proptosis, and beaked nose. Other abnormalities were reported as visual impairment, hearing problems, and airway obstruction. It is not common that CS presents with congenital cardiac anomalies, making up only four cases across the world so far.<sup>[4-7]</sup>

A 4-month-old male baby was referred to Children's Hospital Affiliated to Capital Institute of Pediatrics for surgical correction of multiple deformities. The patient presented to a local hospital with a history of snoring breath, poor feeding, choking, progressing bulging of forehead, and exophthalmos [Figure 1a], which alerted the physician to conduct genetic test for the whole family. A potential new mutation in exon 8 of *FGFR2* located on chromosome 10q26 was only identified in this patient, which results in coding changes that cytosine is replaced with guanine in nitrogen bases and cysteine is substituted with serine in protein formation. The diagnosis of CS was made based on the clinical features and genetic test.

There was neither remarkable family history nor neonatal history; however, the heart murmur was detected in a scheduled infantile general checkup and further investigations revealed coarctation of aorta, aortic dysplasia, and bicuspid aortic valve. Echocardiography showed: aortic dysplasia, ascending aorta diameter was 11.5 mm, the aortic diameter after first, second and third branches were 5.9 mm, 5.0 mm, 3.6 mm. The narrowest place was located in 17 mm beyond the left subclavian artery, the narrowest diameter was 1.8 mm, where the velocity was 392 cm/s, differential pressure was 62 mmHg (1 mmHg=0.133 kPa). Computed tomography scan of cardiac and main blood vessel showed that the proximal ascending aorta diameter was 12.2 mm, proximal aortic arch diameter was 5.5 mm, distal aortic arch was 3.5 mm, and the beyond left subclavian artery was 8.0 mm. Aortic isthmus was severely narrow, almost interrupted, beyond which the vascular cavity diameter was 10.7 mm [Figure 1b].

The repeated magnetic resonance imaging demonstrated a few other comorbidities such as on-progression hydrocephalus, cerebellar infratentorial herniation, posterior laryngeal wall stenosis, and



**Figure 1:** Representative image of a 4-month-old male baby diagnosed with Crouzon Syndrome. (a) The patient presented with bulging of forehead and exophthalmos. (b) Computed tomography of the heart large vessel showed that aortic arch isthmus was very narrow, aortic arch dysplasia. (c) Magnetic resonance imaging of the brain showed the cerebral edema increased significantly and the herniation of the lower brain was increased after 1 month.

severe obstructive sleep apnea [Figure 1c]. Thereby, a cranial decompression procedure was performed, followed by a combined elective surgery involving cardiac and neurological surgical units on December 6, 2017. A ventriculoperitoneal shunt was established first and then the arterial ligament was cut off and the narrow

**Address for correspondence:** Dr. Hui Zhang,  
Department of Cardiac Surgery, Children's Hospital Affiliated to the  
Capital Institute of Pediatrics, Beijing 100020, China  
E-Mail: zhanghui7012@aliyun.com

## Access this article online

### Quick Response Code:



Website:  
www.cmj.org

DOI:  
10.4103/0366-6999.233963

This is an open access journal, and articles are distributed under the terms of the Creative Commons Attribution-NonCommercial-ShareAlike 4.0 License, which allows others to remix, tweak, and build upon the work non-commercially, as long as appropriate credit is given and the new creations are licensed under the identical terms.

© 2018 Chinese Medical Journal | Produced by Wolters Kluwer - Medknow

**Received:** 20-03-2018 **Edited by:** Xin Chen

**How to cite this article:** Meng B, Zhang H. Crouzon Syndrome Associated with Congenital Coarctation of Aorta. Chin Med J 2018;131:1498-9.

segment was enlarged with the bovine pericardium which was called an aortic arch constriction surgery. Postoperative cranial pressure was significantly reduced and the circulation was stable. The inner diameters of the transverse arch and descending aorta were about 7.0 mm and 12.0 mm from the isthmus, respectively, the inner diameter of the tube was about 5.0 mm, and the flow rate was 207 cm/s, and the pressure difference was 28 mmHg. As a result, the patient was discharged 8 days postoperatively.

Along with Apert Syndrome and Pfeiffer Syndrome, CS is one of more than 70 recognized types of premature craniosynostosis.<sup>[1]</sup> The related gene was first located on 10q25–26 in 1994, confirming that the disorder was caused by *FGFR2* gene mutation.<sup>[2,3]</sup> This case was induced by a possible new gene mutation, presenting with CS and multiple cardiac anomalies. Severe hydrocephalus and associated infratentorial herniation pushed the patient into a life-threatening condition. Hence, the combined surgical approach between cardiac surgery and neurosurgery was adopted to lower the perioperative risks and gain more time for advanced procedures. As stated above, congenital cardiac deformities can be one of the comorbidities of CS, which requires attention while making diagnosis of simple CS. In addition, our successful experience shines a light into the surgical treatment of pediatric patients with CS and cardiac anomalies.

### Declaration of patient consent

The authors certify that they have obtained all appropriate consent forms. In the form, the patient's parents have given their consent for the patient's images and other clinical information to be reported in the journal. The patient's parents understand that the patient's name and initials will not be published and due efforts will be made to conceal their identity, but anonymity cannot be guaranteed.

### Financial support and sponsorship

Nil.

### Conflicts of interest

There are no conflicts of interest.

### REFERENCES

1. Merritt L. Recognizing craniosynostosis. *Neonatal Netw* 2009;28:369-76. doi: 10.1891/0730-0832.28.6.369.
2. Britto JA, Chan JC, Evans RD, Hayward RD, Jones BM. Differential expression of fibroblast growth factor receptors in human digital development suggests common pathogenesis in complex acrosyndactyly and craniosynostosis. *Plast Reconstr Surg* 2001;107:1331-8. doi: 10.1097/00006534-200105000-00001.
3. Perlyn CA, Morriss-Kay G, Darvann T, Tenenbaum M, Ornitz DM. A model for the pharmacological treatment of Crouzon syndrome. *Neurosurgery* 2006;59:210-5. doi: 10.1227/01.NEU.0000224323.53866.1E.
4. Hazan F, Aykut A, Unalp A, Mese T, Unal N, Onay H, *et al*. Ventricular septal defect in Crouzon syndrome: Case report. *Genet Couns* 2012;23:519-22.
5. Rokicki W, Rokicka A. Coexistence of Crouzon syndrome with ventricular septal defect. *Wiad Lek* 2003;56:298-9.
6. Schulz C, Kress W, Schömig A, Wessely R. Endocardial cushion defect in a patient with Crouzon syndrome carrying a mutation in the fibroblast growth factor receptor (FGFR)-2 gene. *Clin Genet* 2007;72:305-7. doi: 10.1111/j.1399-0004.2007.00861.x.
7. Beck R, Sertie AL, Brik R, Shinawi M. Crouzon syndrome: Association with absent pulmonary valve syndrome and severe tracheobronchomalacia. *Pediatr Pulmonol* 2002;34:478-81. doi: 10.1002/ppul.10176.