

Case report: successful emergent transcatheter pulmonary valve replacement within failing pulmonary artery conduit in the setting of cardiogenic shock with extracorporeal membrane oxygenation support

Nabil Sabbak  and Joanna Ghobrial *

Cleveland Clinic Foundation, Heart Vascular and Thoracic Institute, 9500 Euclid Ave, J2-4, Cleveland, OH 44195, USA

Received 14 February 2021; first decision 22 March 2021; accepted 13 July 2021; online publish-ahead-of-print 25 October 2021

Background

To the best of our knowledge, this is the first reported case of transcatheter pulmonary valve replacement (TPVR) with extracorporeal membrane oxygenation (ECMO) support with successful decannulation as a bridge to recovery in a young adult with complex congenital heart disease.

Case summary

We describe a 24-year-old male patient with a history of D-transposition of the great arteries with ventricular septal defect status post-Rastelli repair at age three lost to follow-up and presenting with severe biventricular failure, left ventricular thrombus, and critical pulmonary conduit stenosis, deemed non-surgical and non-transplant candidate, who underwent conduit stenting and TPVR in the setting of cardiogenic shock. Upon intubation for general anaesthesia, the patient suffered from ventricular tachycardia arrest requiring cardiopulmonary resuscitation and veno-arterial ECMO. Once stabilized, conduit stenting and TPVR was performed with significant haemodynamic improvement and immediate ECMO decannulation with subsequent biventricular function improvement.

Discussion

In critically ill patients with complex congenital heart disease that are neither surgical nor transplant candidates, ECMO support can be used as a means of support during a transcatheter intervention to improve haemodynamics and a bridge to recovery, allowing time for future potential candidacy for surgery or transplantation as indicated. Patients with congenital heart disease need regular follow-up in specialty clinics to prevent the development of such critical illness.

Keywords

Adult Congenital Heart Disease (ACHD) • Extracorporeal membrane oxygenation (ECMO) • Transcatheter Pulmonary Valve Replacement (TPVR) • D-Transposition of the great arteries (D-TGA) • Case report

* Corresponding author. Tel: +1 216 444 5923, Email: ghorij@ccf.org

Handling Editor: Mohammed Al-Hijji

Peer-reviewers: Christoph Sinning and Flemming Javier Olsen

Compliance Editor: Daniel Tardo

Supplementary Material Editor: Nida Ahmed

© The Author(s) 2021. Published by Oxford University Press on behalf of the European Society of Cardiology.

This is an Open Access article distributed under the terms of the Creative Commons Attribution-NonCommercial License (<https://creativecommons.org/licenses/by-nc/4.0/>), which permits non-commercial re-use, distribution, and reproduction in any medium, provided the original work is properly cited. For commercial re-use, please contact journals.permissions@oup.com

Learning points

- Severe right ventricular to pulmonary artery conduit stenosis can lead to biventricular heart failure if left untreated.
- Extracorporeal membrane oxygenation (ECMO) can be used to support critically ill patients during high-risk transcatheter interventions.
- Transcatheter interventions with or without ECMO support can be used in congenital heart disease patients as a bridge to recovery or transplantation, especially in those that need more time to become transplant candidates.
- This case stresses the importance of regular follow-ups in specialty clinics for patients with congenital heart disease as they grow older, which could have prevented such a critical presentation.

Introduction

The Rastelli procedure is a widely accepted surgical treatment of D-transposition of the great arteries (D-TGA), ventricular septal defect (VSD), and pulmonary stenosis. It involves patch repair of the VSD, with routing of the left ventricle (LV) to the aortic valve, and placement of a right ventricle (RV) to pulmonary artery (PA) conduit. The other commonly used surgical treatments include atrial switch and arterial switch. While advancements in surgical techniques have resulted in excellent long-term outcomes, conduit stenosis remains the most common indication for re-intervention.^{1–3} This case demonstrates the consequences of severe conduit stenosis if left untreated leading to severe biventricular failure and cardiogenic shock. The case also stresses the importance of regular follow-up in specialty clinics for patients with congenital heart disease as they grow older, which could have prevented such a critical presentation.

Timeline

1997, 3 years of age	Rastelli surgical repair with pulmonary homograft
23 July 2019	Admission with biventricular failure
26 July 2019	Cardiogenic shock requiring inotropic support
1 August 2019	Transcatheter pulmonary valve replacement, extracorporeal membrane oxygenation (ECMO), ECMO decannulation
4 August 2019	Transfer from intensive care unit to nursing floor
21 August 2019	Hospital discharge

Case presentation

A 24-year-old male patient with a history of D-TGA with VSD who underwent Rastelli repair at age three and subsequently lost to follow-up was admitted for worsening dyspnoea on exertion and fatigue for 1 month duration.

Transthoracic echocardiography (TTE) revealed severe left ventricular (LV) dysfunction with ejection fraction (EF) of 25% with a 1.5 cm LV thrombus (*Figure 1A and B* and *Videos 1–3*). The RV was moderately dilated with severe systolic dysfunction and suprasystemic RV pressure. The RV was markedly hypertrophied with an apical RV thrombus as well. There was moderate pulmonary regurgitation and critical homograft stenosis (*Supplementary material online, Video S1*) with mean and peak gradients of 42 and 79 mmHg, respectively.

Over the course of the hospitalization, he developed cardiogenic shock requiring inotropic support and intravenous vasodilators. He was deemed not a candidate for advanced therapies given history of incarceration and poor social support, and was at prohibitive surgical risk. After multi-disciplinary discussion and discussion with the patient, it was felt given his young age, an attempt at a high-risk transcatheter pulmonary valve replacement (TPVR) was warranted, understanding that there is no surgical or transplant back-up.

The patient was taken to the cardiac catheterization lab and underwent intubation given he was unable to lie flat. Vascular access was obtained and as angiography was being performed the patient suffered cardiac arrest. As cardiopulmonary resuscitation (CPR) was performed the patient underwent peripheral cannulation of veno-arterial extracorporeal membrane oxygenation (VA-ECMO) with a 24 Fr venous cannula and an 18 Fr arterial cannula and ultimately he achieved return of spontaneous circulation after several rounds of CPR and defibrillation.

Once the patient was stabilized the pulmonary conduit was crossed using a 4 Fr angled glide catheter and a wholey wire as it was too critically stenosed to allow a wedge catheter to cross. Haemodynamics were tenuous when dilating the conduit despite being on ECMO support. Serial dilations of the conduit were performed with 6.0 and 8.0 mm × 40 mm Charger balloons at 16 atm (*Figure 2*). The wholey was exchanged with a Lunderquist wire over the glide catheter into the distal left PA for better support. An 18 Fr curved sheath was then advanced into the RV and the conduit was further serially dilated with a 12 through 20 mm VIDA balloons (*Figure 3A*) with angiography ruling out rupture or contrast extravasation, and coronary angiography during homograft balloon dilation without any evidence of coronary compression. The sheath was advanced further across the conduit, and a 10-Zig 4.5 mm Cheatham Platinum (CP) stent crimped onto a 20 mm Balloon-in-Balloon (BIB) was used to stent the conduit (*Figure 3B*), which was post-dilated with 22 and 24 mm VIDA balloons to reach a stent diameter of 20 mm. Transcatheter pulmonary valve replacement with a 22 mm Melody valve over a 22 mm ensemble was then performed within the CP stent (*Figure 3C* and *Supplementary material online, Video S2*). Pulmonary angiogram post-deployment showed no regurgitation (*Supplementary material online, Videos S3 and S4*), and invasive gradient of <5 mmHg (*Figure 4*).

Given significant improvement in haemodynamics immediately post-TPVR, the patient underwent ECMO weaning and decannulation the same day. Intra-aortic balloon pump insertion was performed first to safely transition off ECMO support. Post-procedural transoesophageal echocardiogram revealed a well-seated Melody valve with no pulmonary insufficiency and a gradient of 4 mmHg.

The patient recovered well and he was started on a heart failure medication regimen and ultimately discharged home. The intracardiac

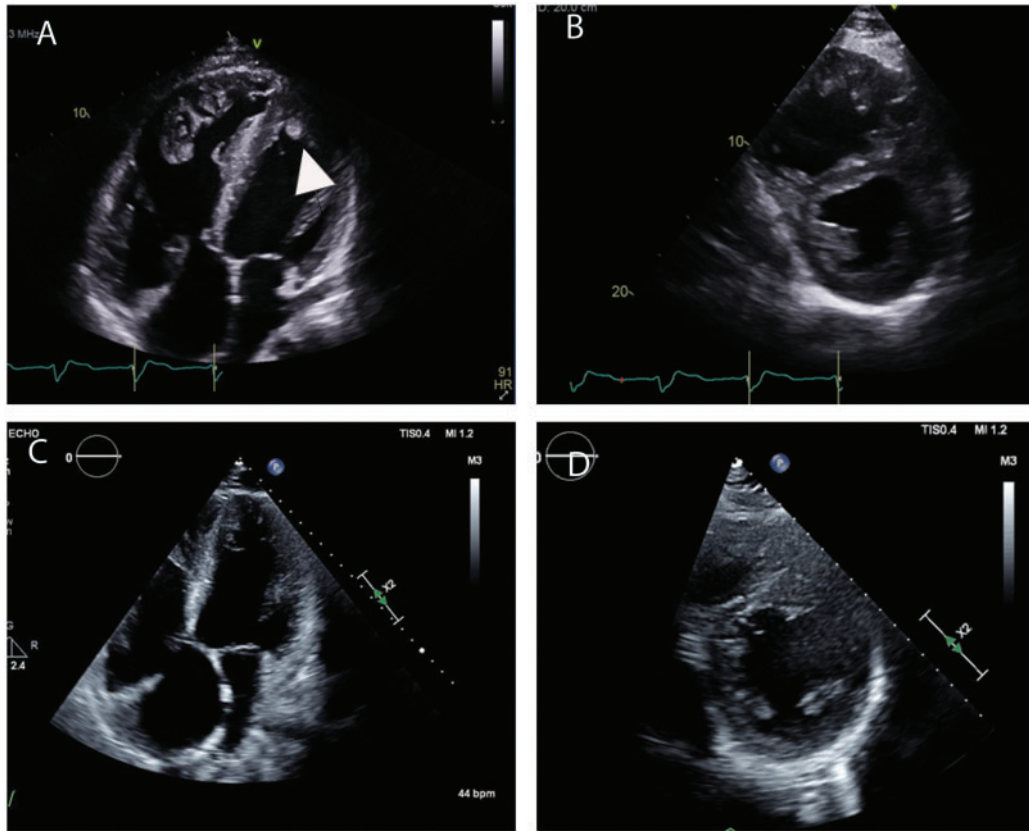
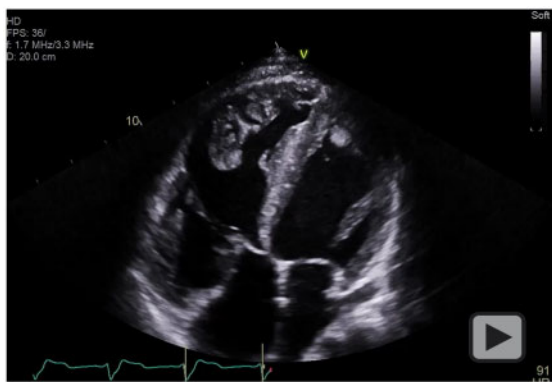
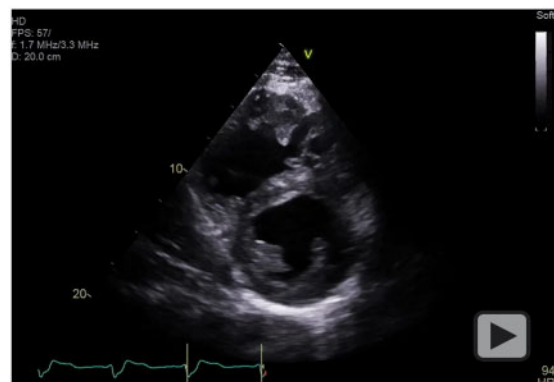

Figure 1 Two-dimensional transthoracic echocardiography demonstrating apical four-chamber and short-axis views of the right ventricle and left ventricle before transcatheter pulmonary valve replacement with biventricular dysfunction, right ventricle pressure and volume overload and hyper-trophy and apical left ventricle thrombus (A and B) and post-transcatheter pulmonary valve replacement with interval improvement in right ventricle pressure overload and biventricular function (C and D).



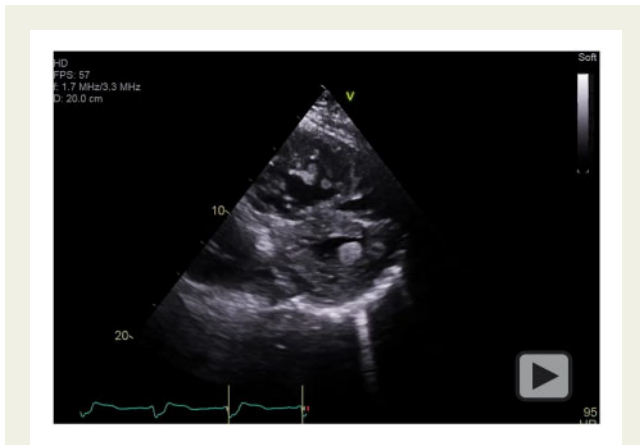
Video 1 Two-dimensional echocardiography of apical four-chamber view with biventricular dysfunction and apical left ventricle thrombus.



Video 2 Two-dimensional echocardiography of short-axis view demonstrating right ventricle pressure and volume overload with septal flattening.

thrombi resolved with anticoagulation during the hospital stay and anti-coagulant was discontinued. He had a follow-up TTE 5 months later demonstrating improved LVEF to 35%, moderate RV dysfunction

(Figure 1C and D and Supplementary material online, Videos S5 and S6), and mean and peak gradients across the Melody valve of 22 and 40 mmHg, respectively.



Video 3 Two-dimensional echocardiography of short-axis view demonstrating apical left ventricle thrombus.

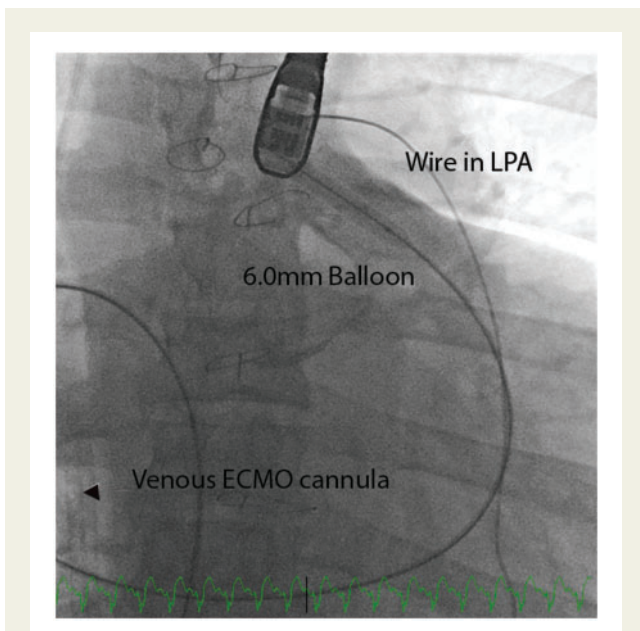


Figure 2 Fluoroscopy cranial view of the dilation of the critically stenosed conduit with a 6.0mm balloon after extracorporeal membrane oxygenation cannulation. ECMO, extracorporeal membrane oxygenation; LPA, left pulmonary artery.

Discussion

Severe RV to PA conduit stenosis markedly impairs cardiac output and as this case illustrates can lead to severe biventricular failure and cardiogenic shock. The evolution of TPVR has resulted in the ability to avoid surgical repair of RV to PA conduits, potentially reducing the burden of redo open heart surgery in these patients.^{4,5} In particular, TPVR with the Melody valve has been shown to provide good long-term haemodynamic and clinical outcomes.⁶

We describe the first reported case of successful emergent TPVR in a patient with critical homograft stenosis and cardiogenic shock.

As this patient was deemed not a candidate for advanced therapies or redo open heart surgery, TPVR was the only available treatment option. Cardiac arrest likely occurred as a consequence of a drop in preload with induction and mechanical ventilation exacerbated by severe RV dysfunction and critical conduit stenosis. The patient was peripherally cannulated on VA-ECMO affording temporary RV unloading as a bridge to TPVR. Large bore arterial access was obtained at the start of the procedure allowing for prompt cannulation. Consideration of mechanical support upfront may have avoided the need for emergent ECMO.


The severity of stenosis required several serial dilations starting with a 6 mm balloon in order to minimize waist and allow for optimal pre-stenting. As one of the most common causes of Melody valve failure is stenosis related to stent fracture, pre-dilation and pre-stenting is a crucial step shown to reduce such incidence, but can increase the afterload on an already severely dysfunctional RV. Venous-arterial ECMO allowed for this process with significantly less haemodynamic fluctuations in such a critically ill patient.

Transcatheter pulmonary valve replacement resulted in significant haemodynamic improvement, allowing for prompt ECMO decannulation, as well as relative interval biventricular function improvement. With the addition of heart failure medical therapy, the patient was able to be discharged home.

Conclusion

This is the first reported case of successful emergent TPVR with ECMO support in a patient with critical homograft stenosis and cardiogenic shock. As cardiac arrest most likely resulted from preload reduction in the setting of intubation and severe RV dysfunction, upfront mechanical support can be considered in future similar scenarios of critically ill patients. Furthermore, this case illustrates that in complex congenital heart disease patients who are neither surgical nor transplant candidates, ECMO support can be used as a means of support during a transcatheter intervention to improve haemodynamics and a bridge to recovery, allowing time for future potential candidacy for surgery or transplantation as indicated. Finally, this case stresses the importance of regular follow-up for patients with congenital heart disease as they grow older, in specialty adult congenital heart disease clinic for the more complex, as this could have prevented such a critical presentation.

Lead author biography



Dr Nabil Sabbak is a general cardiology fellow at the Cleveland Clinic and will be starting his interventional cardiology fellowship in the next year.

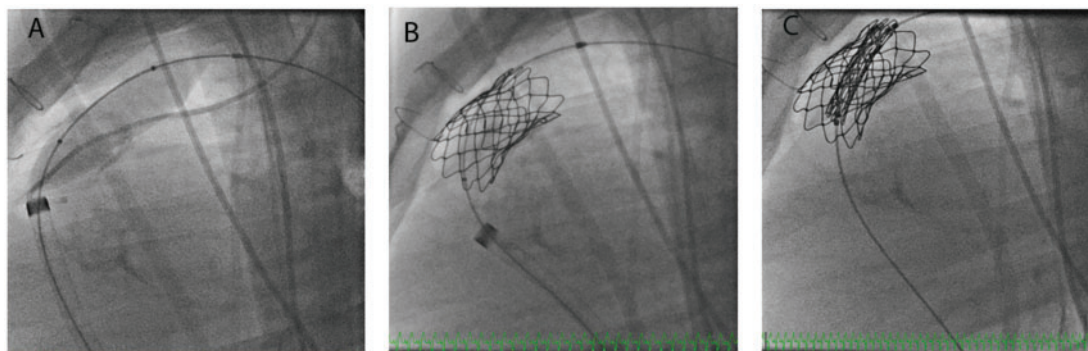


Figure 3 Fluoroscopy lateral view. (A) Dilation of the pulmonary homograft with a 20 mm VIDA balloons at 16 atm introduced through an 18 Fr curved venous sheath over a Lunderquist wire advanced to the distal left pulmonary artery. (B) A 10-Zig 4.5 mm CP stent deployed within the conduit on a 20 mm. (C) A 22 mm Melody valve over a 22 mm ensemble is positioned within the CP stent.

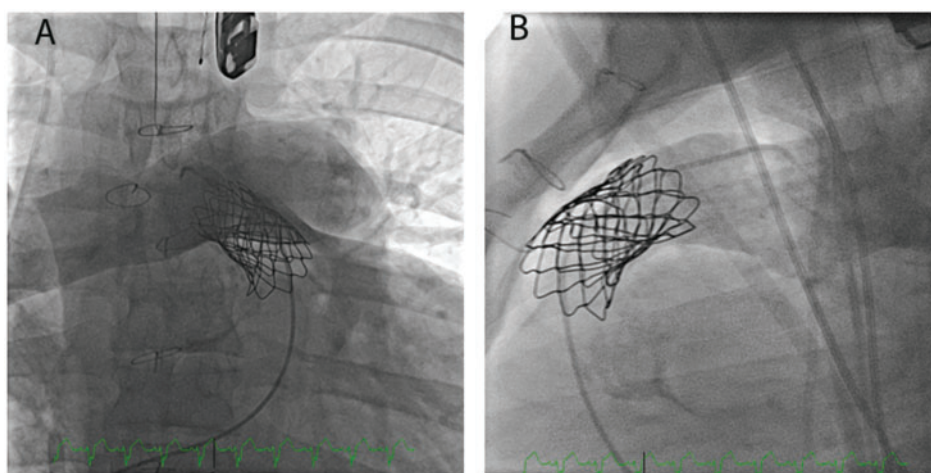


Figure 4 Pulmonary angiogram post-deployment in right anterior oblique/cranial (A) and lateral (B) views demonstrating no regurgitation.

Supplementary material

Supplementary material is available at *European Heart Journal - Case Reports* online.

Slide sets: A fully edited slide set detailing this case and suitable for local presentation is available online as [Supplementary data](#).

Consent: The authors confirm that written consent for submission and publication of this case report including images and associated text has been obtained from the patient in line with COPE guidance.

Conflict of interest: None declared.

Funding: None declared.

References

- Huang ES, Herrmann JL, Rodefeld MD, Turrentine MW, Brown JW. Rastelli operation for D-transposition of the great arteries, ventricular septal defect, and pulmonary stenosis. *World J Pediatr Congenit Heart Surg* 2019;**10**:157–163.
- Stout K, Daniels CJ, Aboulhosn JA, Bozkurt B, Broberg CS, Colman JM et al. 2018 AHA/ACC Guideline for the management of adults with congenital heart disease: executive summary: a report of the American College of Cardiology/American Heart Association Task Force on clinical practice guidelines. *Circulation* 2019;**139**: e637–e697.
- Baumgartner H, De Backer J, Babu-Narayan SV, Budts W, Chessa M, Diller GP et al.; ESC Scientific Document Group. 2020 ESC Guidelines for the management of adult congenital heart disease. *Eur Heart J* 2021;**42**: 563–645.
- Lurz P, Coats L, Khambadkone S, Nordmeyer J, Boudjemline Y, Schievano S et al. Percutaneous pulmonary valve implantation: impact of evolving technology and learning curve on clinical outcome. *Circulation* 2008;**117**: 1964–1972.
- Cabalka AK, Hellenbrand WE, Eicken A, Kreutzer J, Gray RG, Bergersen L et al. Relationships among conduit type, pre-stenting, and outcomes in patients undergoing transcatheter pulmonary valve replacement in the prospective North American and European Melody Valve Trials. *JACC Cardiovasc Interv* 2017;**10**: 1746–1759.
- Cheatham JP, Hellenbrand WE, Zahn EM, Jones TK, Berman DP, Vincent JA et al. Clinical and hemodynamic outcomes up to 7 years after transcatheter pulmonary valve replacement in the US melody valve investigational device exemption trial. *Circulation* 2015;**131**:1960–1970.