

[CASE REPORT]

First Experience of Robotic-assisted Percutaneous Coronary Intervention in Japan

Koutaro Kagiya, Takafumi Ueno, Yoshiaki Mitsutake, Kazunori Yamaji, Takashi Ishimatsu, Ken-ichiro Sasaki and Yoshihiro Fukumoto

Abstract:

In 2018, the CorPath GRX system (Corindus) was approved for use in Japan, marking the introduction of the first robotic-assisted system for percutaneous coronary intervention (PCI) in the country. The present report describes the first experience of robotic-assisted PCI for four coronary lesions in two cases in a single center. All procedures succeeded without any complications, although one procedure was converted to manual PCI by the operator's decision. Post-marketing surveillance to assess the impact of this novel system on both Japanese patients and physicians is currently ongoing in Japan.

Key words: robotic technology, interventional innovation, percutaneous coronary intervention, coronary artery disease

(Intern Med 58: 3415-3419, 2019)

(DOI: 10.2169/internalmedicine.3272-19)

Introduction

Conventional percutaneous coronary intervention (PCI) is performed under fluoroscopic guidance with the operator standing near the patient while manipulating the devices manually. The interventional cardiologist is routinely exposed to radiation. Long-term radiation exposure, even at low doses, is well known to be associated with cancer (1), cataracts (2) and other medical problems (3). In order to minimize radiation exposure, the operator is covered with a heavy protective apron and subjected to other protective measures. However, the conventional protective methods result in an environment unfriendly to the operator, which can result in orthopedic complications (3).

To address these limitations associated with current PCI procedures, a remote-controlled robotic-assisted system, known as the CorPath System (Corindus, Waltham, USA), was developed. In 2018, the CorPath GRX system (Corindus) was approved for use in Japan, marking the introduction of the first robotic-assisted system for PCI in the country.

We herein report the first experience of robotic-assisted PCI in Japan.

Case Reports

The details of the CorPath system have been described, elsewhere (4-7). In brief, the CorPath GRX system consists of an interventional cockpit and a bedside unit (Fig. 1). The interventional cockpit is a radiation-shielded mobile workstation that contains a console with joysticks and touch-screen controls to control the movement of the balloon/stent delivery system, guidewire, or guide catheter. The bedside unit consists of a single-use cassette, articulating arm, and robotic drive. During the PCI procedure, the single-use cassette is loaded with interventional equipment and mounted on a robotic drive, which translates commands from the cockpit to independently manipulate each device. The system allows the operator to remotely control the movement of PCI devices by increments as small as 1 mm proximally or distally. In addition, the system allows the operator to measure lesion lengths during guidewire or balloon catheter movement. The system fits all commercial 0.014-inch guidewires and rapid-exchange balloon/stent catheters as well as standard coronary guide catheters of various sizes.

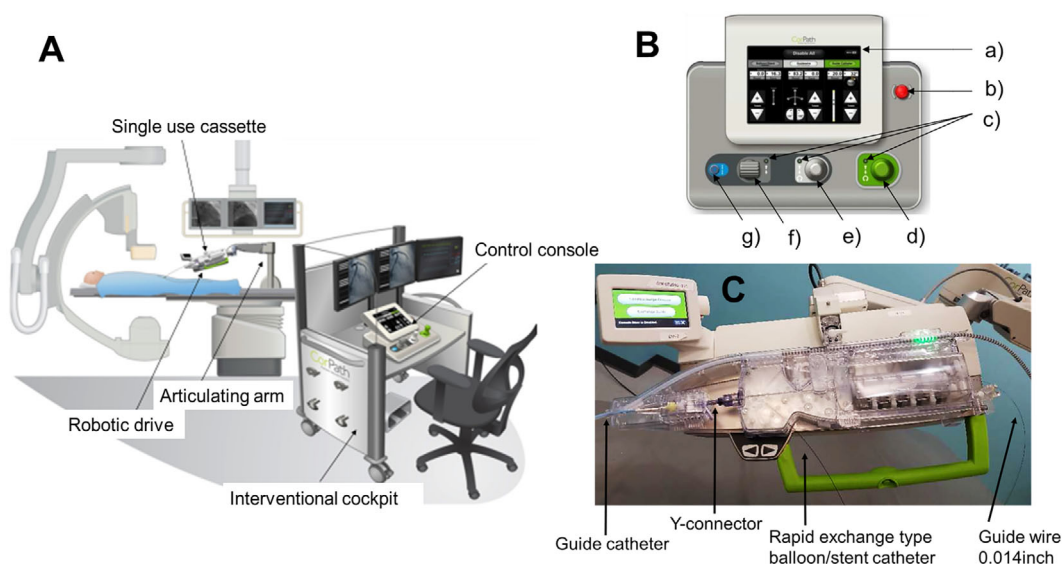


Figure 1. The CorPath GRX system. **A:** Overview of the CorPath GRX system in the catheterization laboratory. **B:** Control console. a) Touch screen. b) Emergency stop button. c) Active joystick light-emitting diode (LED). d) Guide catheter joystick. e) Guidewire joystick. f) Balloon/stent catheter joystick. g) Turbo button.

Case 1

A 72-year-old woman with 2-vessel disease presented with stable angina. The initial target lesion was severe stenosis in the proximal right coronary artery (RCA). A 6-Fr JR3.5 guide catheter was used to engage the RCA manually, using right radial artery access. A 0.014-inch SION blue guidewire (ASAHI INTECC, Seto, Japan) was advanced across the lesion in the RCA using the CorPath system. A 2.5×15-mm Sapphire II Pro semi-compliant balloon catheter (OrbusNeich, Hong Kong) was then inserted into the lesion robotically. After predilation with the balloon, the lesion length was measured by a robotic measurement function, and then intravascular ultrasound (IVUS) was performed manually by the assistant operator. A 3.0×32-mm Synergy drug-eluting stent (DES) (Boston Scientific, Marlborough, USA) was placed robotically and deployed.

An excellent result was obtained (Fig. 2A-C). There were no periprocedural complications in this session. The procedural time from the initial guidewire insertion to the guidewire removal, fluoroscopy time, and contrast volume was 29 minutes, 12.7 minutes, and 56 mL, respectively.

Seven days later, a second session to resolve severe stenosis in the left circumflex (LCX) artery was performed. The access site was the right radial artery. The left coronary artery (LCA) was engaged manually with a 6-Fr JL3.5 guide catheter. A 0.014-inch SION blue guidewire was crossed over the lesion using the rotate on retract (R on R) function of the CorPath system, which rotates the guidewire whenever it is retracted by the operator, changing the guidewire tip's orientation in preparation for the next advancement. After predilation with a 2.25×15-mm Sapphire II Pro semi-compliant balloon catheter, IVUS was performed manually

by the assistant operator. A 2.25×38-mm XIENCE SIERRA DES (Abbott Vascular, Santa Clara, USA) was implanted with a good result (Fig. 2D-F).

The procedural time from the initial guidewire insertion to the guidewire removal, fluoroscopy time, and contrast volume was 23 minutes, 12.5 minutes, and 55 mL, respectively.

Case 2

A 70-year-old man on hemodialysis with a history of PCI to the RCA and left anterior descending artery (LAD) presented with worsening angina. Coronary angiography revealed chronic total occlusion (CTO) inside the stent in the mid RCA and tight in-stent restenosis (ISR) in the proximal LAD.

The target lesion of robotic-assisted PCI was the ISR in the LAD. The LCA was engaged with a 6-Fr JL4.0 guide catheter manually using right femoral artery access. A 0.014-inch Runthrough NS (Terumo, Tokyo, Japan) guidewire was inserted into the LAD robotically. After manual IVUS observation, predilation was performed using 3.5×15-mm Hiryu Plus semi-compliant balloon (Terumo). A Sequent Please 3.5×15-mm drug-coated balloon (B. Braun, Berlin, Germany) was used in the ISR lesion with a good result (Fig. 3).

For the RCA CTO lesion, the operator decided to convert to a manual PCI procedure. Ultimately, an excellent result was obtained. The total procedural time from the initial guidewire insertion to the guidewire removal, fluoroscopy time, and contrast volume was 105 minutes, 39.3 minutes, and 205 mL, respectively. The procedural time for robotic PCI was 19 minutes.

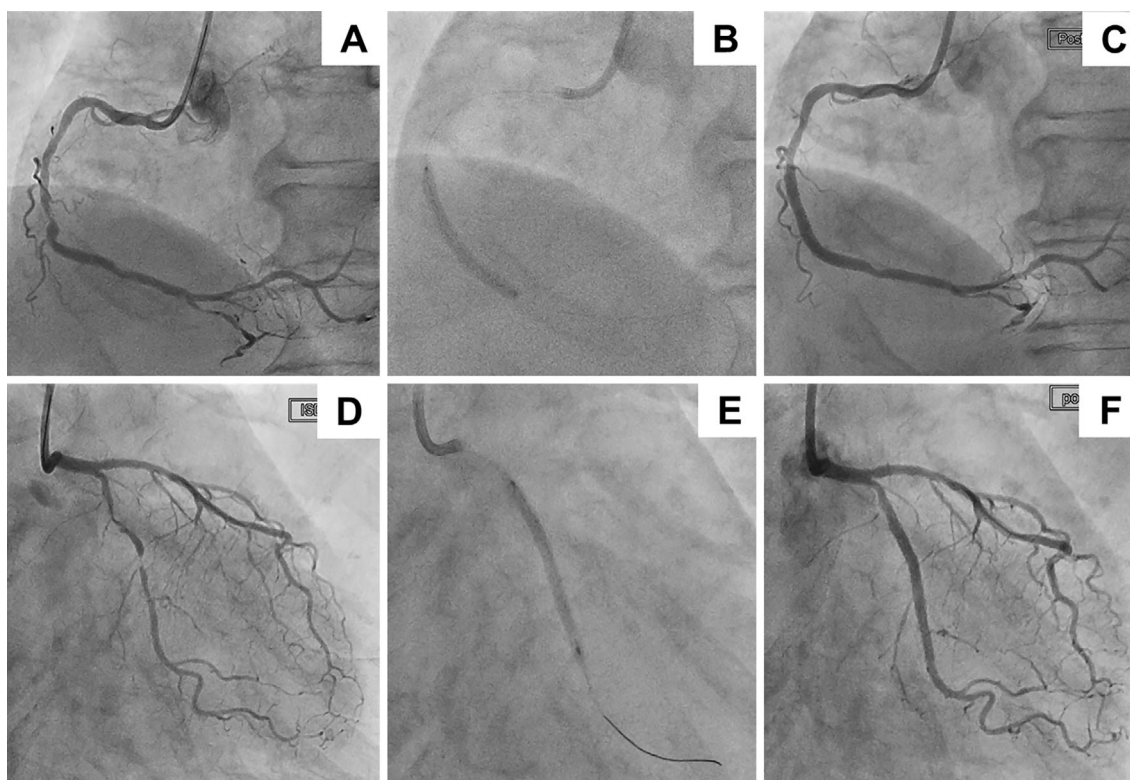


Figure 2. Case 1. Robotic-assisted PCI for the RCA lesion and LCX lesion. A: Coronary angiography revealed tight stenosis in the mid RCA. B: After robotically wiring across the lesion and predilation with a 2.5×15-mm balloon, a 3.0×32-mm Synergy stent was delivered robotically and deployed. C: The final angiogram showed an excellent result. D: Coronary angiography revealed severe stenosis in the mid LCX. E: After robotically wiring across the lesion and predilation with a 2.25×15-mm balloon, a 2.25×38-mm XIENCE Sierra stent was delivered robotically and implanted. F: An excellent result was obtained.

Discussion

We herein report the first experience of robotic-assisted PCI in Japan. All procedures were completed successfully without any complications by a single operator trained using the CorPath system training program. One of four procedures was converted to manual PCI by the operator's decision. The case with manual conversion involved a CTO lesion. In the complex robotically assisted percutaneous coronary intervention trial (CORA-PCI) study, which assesses the feasibility of robotic-assisted PCI in cases of complex coronary artery disease, the rate of manual conversion was 11.1% (6). Previous study reports have cited adverse events, technical limitations of the robotic platform, and device-uncrossable lesions as reasons for manual conversion (7). These are potential limitations with the CorPath system. The most important factor dictating the successful completion of procedures without complications will be each operator's decision on whether or not to convert to a manual procedure. Thus, all robotic-assisted PCI operators need to familiarize themselves with the performance and limitations of this system.

While the radiation exposure dose to the operator was not

determined in this report, it may have dramatically decreased. However, there is concern as to whether or not robotic-assisted PCI is associated with an increased procedure time, fluoroscopy time, and contrast volume, which have an unfavorable effect on patients. Regarding this point, Smilowitz et al. actually reported a shorter fluoroscopy time with robotic-assisted PCI than with conventional PCI (10.1 vs. 12.3 minutes; $p=0.05$) (8). However, that report involved a small number of cases and was a single-center investigation. Therefore, further clinical data are warranted in order to clarify whether or not robotic-assisted PCI is associated with an increased procedure time, fluoroscopy time, and contrast volume. In the PRECISE study, the mean robotic system procedure time was 24.4 minutes with an average fluoroscopy time of 11.1 minutes, and the mean contrast volume was 144.2 mL (4). Regarding Japanese clinical data in conventional PCI, the mean procedure time is 44.9 minutes (9) and the mean fluoroscopy time is 29.7 minutes (10). Compared with these data, the present results appear acceptable.

Little information is available on the benefits enjoyed by patients who have undergone robotic-assisted PCI procedures. As described above, Smilowitz's report suggested a shorter fluoroscopy time with robotic-assisted PCI than with

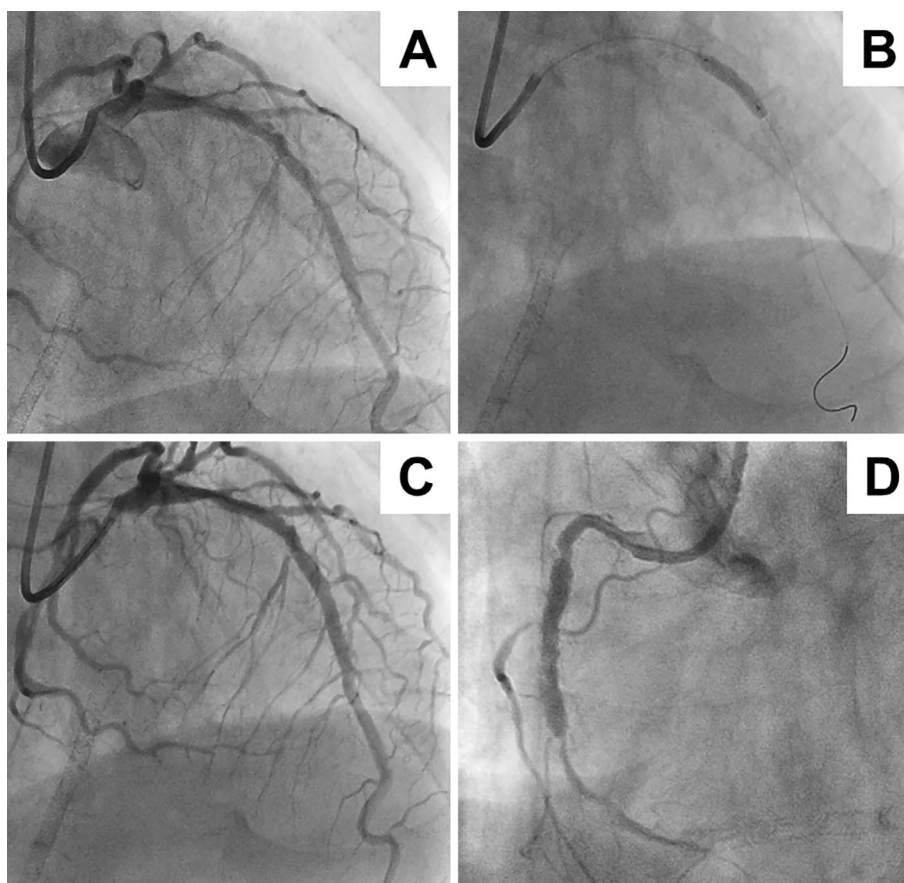


Figure 3. Case 2. Robotic-assisted PCI for the LAD ISR lesion. A: Coronary angiography revealed in-stent restenosis in the mid LAD. B: After robotically wiring across the lesion and predilatation with a 2.25×15-mm balloon, a 2.25×38-mm XIENCE Sierra stent was delivered robotically and implanted. C: An excellent result was obtained. D: The RCA CTO lesion was treated manually.

manual PCI (8). Therefore, the CorPath system may have the potential to reduce radiation exposure to patients as well as operators. Another potential benefit for patients may be a reduction in the incidence of lesion-stent mismatch, which is referred to as longitudinal “geographic miss”. Campbell et al. reported that the computer-assisted lesion length measurements made using the CorPath system can reduce the rate of improper stent size selection (11). However, these previous reports have involved a small number of patients and been single-center investigations. Thus, prospective, randomized clinical trials with larger sample sizes are warranted.

This case series is part of a post-marketing surveillance in Japan. The overall surveillance results will be announced in the near future.

Conclusion

We herein report the first experience of robotic-assisted PCI in Japan. Although one of the four procedures was converted to manual PCI by the operator’s decision, all attempted procedures were completed successfully without any complications. Post-marketing surveillance to assess the impact of this novel system on both Japanese patients and physicians is currently ongoing in Japan.

The authors state that they have no Conflict of Interest (COI).

Acknowledgement

The authors gratefully acknowledge the technical assistance of Miss Eiko Ogura.

References

1. Roguin A, Goldstein J, Bar O. Brain tumours among interventional cardiologists: a cause for alarm? Report of four new cases from two cities and a review of literature. *Eurointervention* **7**: 1081-1086, 2012.
2. Vano E, Kleiman NJ, Duran A, Rehani MM, Echeverri D, Cabrera M. Radiation cataract risk in interventional cardiology personnel. *Radiat Res* **174**: 490-495, 2010.
3. Goldstein JA, Balter S, Cowley M, Hodgson J, Klein LW; Interventional Committee of the Society of Cardiovascular Interventions. Occupational hazards of interventional cardiologists: prevalence of orthopedic health problems in contemporary practice. *Catheter Cardiovasc Interv* **63**: 407-411, 2004.
4. Weisz G, Metzger DC, Caputo RP, et al. Safety and feasibility of robotic percutaneous coronary intervention: PRECISE (percutaneous robotically-enhanced coronary intervention) study. *J Am Coll Cardiol* **61**: 1596-1600, 2013.
5. Smitson CC, Ang L, Pourjabbar A, Reeves R, Patel M, Mahmud E. Safety and feasibility of a novel, second-generation robotic-assisted system for percutaneous coronary intervention: first-in-human report. *J Invasive Cardiol* **30**: 152-156, 2018.

6. Mahmud E, Naghi J, Ang L, et al. Demonstration of the safety and feasibility of robotically assisted percutaneous coronary intervention in complex coronary lesions: results of the CORA-PCI study (Complex Robotically Assisted Percutaneous Coronary Intervention). *JACC Cardiovasc Interv* **10**: 1320-1327, 2017.
7. Harrison J, Ang L, Naghi J, et al. Robotically-assisted percutaneous coronary intervention: reasons for partial manual assistance or manual conversion. *Cardiovasc Revasc Med* **19**: 526-531, 2018.
8. Smilowitz NR, Moses JW, Sosa FA, et al. Robotic-enhanced PCI compared to the traditional manual approach. *J Invasive Cardiol* **26**: 318-321, 2014.
9. Kimura T, Kozuma K, Tanabe K, et al.; ABSORB Japan Investigators. A randomized trial evaluating everolimus-eluting Absorb bioresorbable scaffolds vs. everolimus-eluting metallic stents in patients with coronary artery disease: ABSORB Japan. *Eur Heart J* **36**: 3332-3342, 2015.
10. Inohara T, Kohsaka S, Yamaji K, et al.; J-PCI Registry Investigators. Impact of institutional and operator volume on short-term outcomes of percutaneous coronary intervention: a report from the Japanese nationwide registry. *JACC Cardiovasc Interv* **10**: 918-927, 2017.
11. Campbell P, Kruse K, Kroll C, Patterson J, Esposito M. The impact of precise robotic lesion length measurement on stent length selection: ramifications for stent savings. *Cardiovasc Revasc Med* **16**: 348-350, 2015.

The Internal Medicine is an Open Access journal distributed under the Creative Commons Attribution-NonCommercial-NoDerivatives 4.0 International License. To view the details of this license, please visit (<https://creativecommons.org/licenses/by-nc-nd/4.0/>).

© 2019 The Japanese Society of Internal Medicine
Intern Med 58: 3415-3419, 2019