



## Xanthogranulomatous orchitis: A rare case of testicular mass

Trent A. Pattenden<sup>a,\*</sup>, Andrew Morton<sup>a,b</sup>, Andrew Keller<sup>a</sup>

<sup>a</sup> Department of Urology, Ipswich Hospital, QLD, Australia

<sup>b</sup> Faculty of Medicine, University of Queensland, QLD, Australia

### ARTICLE INFO

#### Keywords:

Xanthogranulomatous inflammation  
Testis  
Orchitis

### ABSTRACT

Xanthogranulomatous orchitis is a rare non-malignant condition. This study reports a new case of xanthogranulomatous orchitis in a 77-year-old male, who presented with acute right scrotal mass. Ultrasound and computed tomography showed a heterogenous lesion involving the testis, with a loculated collection in the overlying scrotal wall. Scrotal exploration revealed an abscess involving the scrotal skin, with hard mass involving the testis, with histological evidence of infiltration and replacement of most testicular parenchyma. This case highlights this important consideration for xanthogranulomatous orchitis in the differential of testicular mass, particularly when associated with a purulent collection.

#### Section headings:

- Inflammation and Infection
- General Urology

### 1. Introduction

Xanthogranulomatous orchitis (XGO) is rare benign cause of testicular mass, often associated with a suppurative collection. The main differential diagnosis is testicular cancer, while differentials include malakoplakia, Rosai Dorfman disease, and atypical infections. XGO is difficult to diagnose without tissue histology, therefore orchidectomy is the most common treatment reported. This article describes a new case of XGO, along with reviewing the aetiology and differential diagnoses. It highlights why reaching the correct diagnosis is important, by summarising differences in the management of these differential diagnoses.

### 2. Case presentation

A 77-year-old male, presented to the emergency department with an acute right scrotal mass. His background history included type-one neurofibromatosis, localised low-risk prostate cancer on active surveillance, recurrent urinary tract infections, lymphoplasmacytic lymphoma under observation, primary hypertension, and stage-two chronic kidney disease. He reported increasing right scrotal swelling, accompanied by pain for the past two days, without any other localised or systemic

symptoms.

On examination the right scrotum was tender and enlarged, with skin oedema and erythema. The right testis was indistinct due to a fluctuant collection surrounding the testis and extending into the right scrotal wall. The left scrotum and testis examined unremarkably.

Full blood count revealed leukocytosis ( $17.4 \times 10^9$ ) with elevated neutrophils ( $14.6 \times 10^9$ ), while serum C-reactive protein was elevated 77 mg/L (reference: <2 mg/L). Post-contrast CT scan showed a heterogenous enlarged right testis adjacent a 5x3x4 cm septate abscess (Fig. 1, panes a and b). Scrotal ultrasound showed a heterogenous mass (4x3x2 cm) involving the right testis with minimal normal testicular parenchyma identified. This communicated with a collection (4x2x1 cm) within the right scrotal wall (Fig. 1, panes c and d). Lactate dehydrogenase was 170 units/L (reference: 120–250 units/L), while alpha fetoprotein (AFP) and human chorionic gonadotropin (HCG) were not collected.

This man was immediately treated with intravenous antibiotics; ceftriaxone 1g twice daily, and metronidazole 500mg twice daily. He was diagnosed with right epididymo-orchitis, associated with a testicular and scrotal wall abscess. The differential diagnosis was a testicular neoplasm complicated by abscess formation. He underwent a simple

*Abbreviations:* PAS, Periodic Acid-Schiff; XGO, Xanthogranulomatous orchitis; LDH, Lactate Dehydrogenase; AFP, Alpha Fetoprotein; HCG, Human Chorionic Gonadotropin.

\* Corresponding author. Department of Urology Ipswich Hospital, West Morton Health, Ipswich, 4305, QLD, Australia.

E-mail address: [pattendentrent@gmail.com](mailto:pattendentrent@gmail.com) (T.A. Pattenden).

<https://doi.org/10.1016/j.eucr.2022.102111>

Received 11 March 2022; Received in revised form 1 May 2022; Accepted 4 May 2022

Available online 7 May 2022

2214-4420/© 2022 Published by Elsevier Inc. This is an open access article under the CC BY-NC-ND license (<http://creativecommons.org/licenses/by-nc-nd/4.0/>).

right orchidectomy plus abscess drainage. The associated oedema and loculations made dissection difficult, prevented identification of the testis within the intravaginal plane, and led to extravaginal ligation of the cord structures.

Histopathologic examination revealed a yellowish mass involving the testis and adjacent tissue, with effacement of residual uninvolved testicular parenchyma (Fig. 2). Microscopically the mass consisted of sheets of histiocytes with foamy cytoplasm, along with small numbers of lymphocytes, plasma cells, and scattered granulocytes (Fig. 3). There were areas of cavitory necrosis with suppuration, along with foci of granulomatous inflammation, and giant cell reaction. This process had replaced most of the testicular parenchyma, without involving the epididymis. There was no evidence of micro-organisms after Ziehl-Neelsen, Wade Fite, Periodic Acid-Schiff (PAS) or Grocott stains, and no evidence of emperipolesis. This was consistent with a diagnosis of XGO.

The culture of intraoperative pus specimen grew a multi-resistant *Escherichia coli* that required a three-week course cefepime 6g daily. At routine clinical follow up 6 weeks post-operatively his wound had fully healed.

### 3. Discussion

XGO is a rare manifestation of xanthogranulomatous inflammation, where the kidney is the most common urinary organ affected. Incidence of XGO is limited to case reports, where a systematic search identified 26 cases. Previously reported cases found it difficult to diagnose XGO without histological assessment.<sup>1-3</sup> While germ-cell tumour markers (AFP, HCG and LDH) may be helpful if elevated, normalcy doesn't exclude malignancy. Two cases of XGO managed without orchidectomy have previously been reported, one diagnosed on frozen section, the other by enucleation of the tumour with testis preservation.<sup>1,2</sup> While the treatment triad of orchidectomy, abscess drainage, and antibiotics are most reported, there is a potential for reporting bias. Cases managed without orchidectomy are unlikely to have been diagnosed as XGO.

While the aetiology of XGO is unknown, possible causes have been proposed based on mechanisms in other organ systems, and co-occurring conditions in case reports.<sup>2</sup> Chronic infection is the most

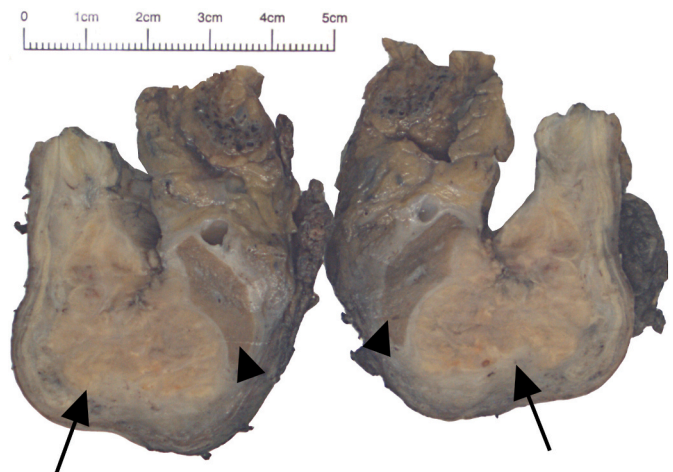


Fig. 2. Bivalved right testis. Xanthogranulomatous 3.3 × 2.5 × 2.0 cm lesion (black arrow) effacing remaining testicular parenchyma (arrow-head).

frequent proposed aetiology, based on upon its occurrence in xanthogranulomatous inflammation in other organs and cases of XGO, including this case. Other potential causes include spermatic cord obstruction, ischaemia, abnormal lipid metabolism, lymphatic obstruction, dyslipidaemia, diabetes mellitus, and trauma.<sup>1-3</sup> XGO has not previously been associated with lymphoplasmacytic lymphoma, however given this patient's stable and indolent disease over 16 years, any contribution remains unclear.

Differential diagnoses for XGO include malakoplakia, Rosai Dorfman disease, and atypical infections, which need exclusion before forming the diagnosis of XGO. Malakoplakia is a rare granulomatous condition, thought due to defects in histiocyte function, secondary to chronic bacterial infection, commonly *E. coli*.<sup>4</sup> The urogenital tract is most often involved, and typically appear as yellowish nodules or plaques. Microscopically it is characterised by large histiocytes with eosinophilic cytoplasm (Von Hansemann cells) containing calcified phagosomes (Michaelis-Gutmann bodies). While often localised, malakoplakia can recur or spread. No treatment guidelines for malakoplakia exist.

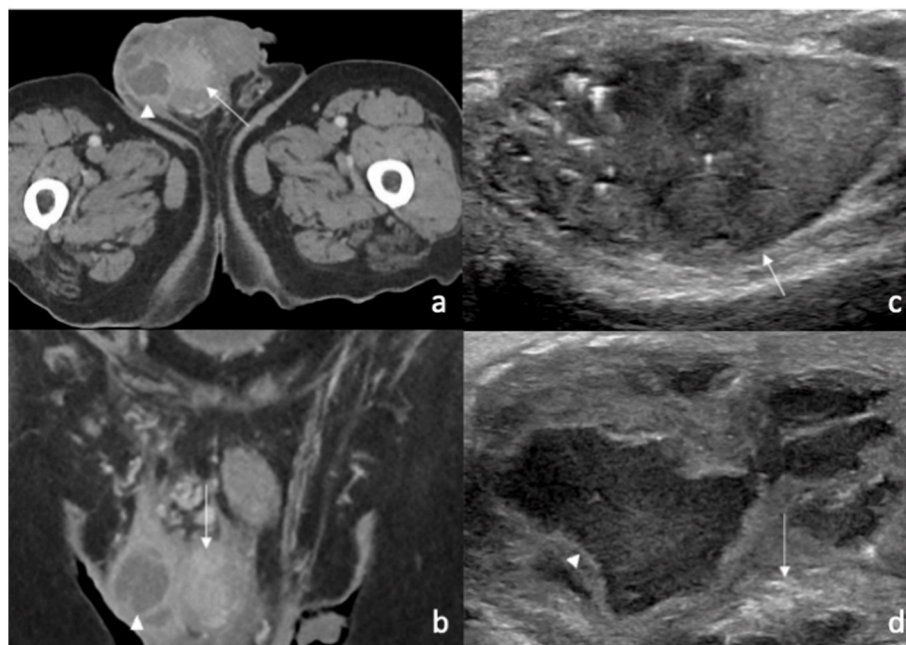
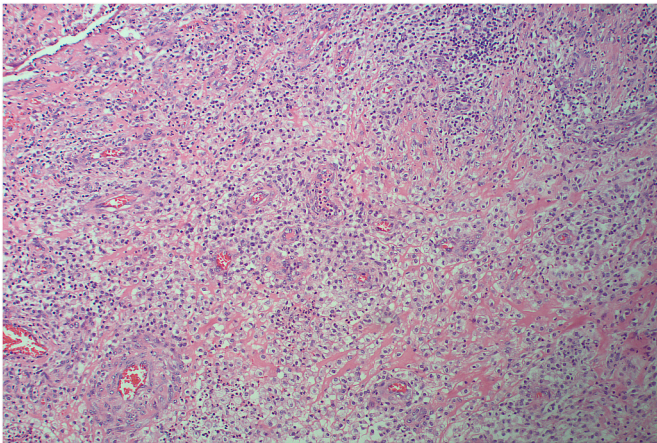


Fig. 1. CT and ultrasound imaging of right scrotum. Legend: Right testis (white arrow), Scrotal wall abscess (white arrow-head). a) CT Axial, b) CT Coronal, c) Ultrasound Sagittal, d) Ultrasound Axial.



**Fig. 3.** H&E micrograph (x100 magnification) showing xanthogranulomatous orchitis. Sheets of histiocytes, most with foamy cytoplasm, along with small lymphocytes, plasma cells, and lesser numbers of granulocytes.

However, typically antibiotics are first-line, with surgery reserved for extensive or nonresponding cases.<sup>4</sup>

Rosai Dorfman disease is a non-Langerhans cell histiocytosis, classically causing painless lymphadenopathy. However, 40% of cases have extra-nodal involvement, including many with testis involvement. Microscopically, histiocytes display emperipolesis and stain positive for S100. Treatment of the condition varies depending on the extent of disease, including observation, corticosteroids, surgical resection and chemotherapy.<sup>5</sup>

Atypical infections, particularly mycoplasma or fungal organisms may present with granulomatous reactions. These organisms require correct identification, to guide targeted antimicrobial treatment. This is achieved using special stains; Ziehl-Neelsen for *Mycobacterium*

*tuberculosis*, Wade Fite for *Mycobacterium leprae*, and Grocott and PAS stains for fungal organisms.

#### 4. Conclusion

XGO is a rare disease, reflected in the limited number of reported cases. While differentiating from a testicular neoplasm preoperatively is difficult, testicular neoplasms rarely present with an infectious picture. Orchidectomy formed part of the treatment of most reported cases, allowing for their histological diagnosis, however other cases successfully managed without surgery may have gone undiagnosed. This case is a reminder of the rare differential diagnosis for testicular pathology and adds another example to the medical literature.

#### Funding

This research did not receive any specific grant from funding agencies in the public, commercial, or not-for-profit sectors.

#### References

1. Repetto P, Bianchini MA, Ceccarelli PL, et al. Bilateral xanthogranulomatous funiculitis and orchiepididymitis in a 13-year-old adolescent boy. *J Pediatr Surg.* 2012;47(10):e33–e35. <https://doi.org/10.1016/j.jpedsurg.2012.05.011> (In eng).
2. Yamashita S, Umamoto H, Kohjimoto Y, Hara I. Xanthogranulomatous orchitis after blunt testicular trauma mimicking a testicular tumor: a case report and comparison with published cases. *Urol J.* 2017;14(3):3094–3096 (In eng).
3. Vaidyanathan S, Mansour P, Parsons KF, et al. Xanthogranulomatous funiculitis and epididymo-orchitis in a tetraplegic patient. *Spinal Cord.* 2000;38(12):769–772. <https://doi.org/10.1038/sj.sc.3101045> (In eng).
4. Dong H, Dawes S, Philip J, Chaudhri S, Subramonian K. Malakoplakia of the urogenital tract. *Urology Case Reports.* 2015;3(1):6–8. <https://doi.org/10.1016/j.eucr.2014.10.002>.
5. Abba O, Jacobsen E, Picarsic J, et al. Consensus recommendations for the diagnosis and clinical management of Rosai-Dorfman-Destombes disease. *Blood.* 2018;131(26):2877–2890. <https://doi.org/10.1182/blood-2018-03-839753>.