



Contents lists available at ScienceDirect

## International Journal of Surgery Case Reports

journal homepage: [www.casereports.com](http://www.casereports.com)

# Primary malignant melanoma of the female urethra: Report of a rare neoplasm of the urinary tract



Namita Bhutani<sup>a</sup>, Pradeep Kajal<sup>b,\*</sup>, Devendra Pawar<sup>c</sup>

<sup>a</sup> Deptt. of Pathology, PGIMS, Rohtak, Haryana, India

<sup>b</sup> Deptt. of Paediatric Surgery, PGIMS, Rohtak, Haryana, India

<sup>c</sup> Deptt. of Urology, PGIMS, Rohtak, Haryana, India

## ARTICLE INFO

### Article history:

Received 3 September 2017

Received in revised form 2 November 2017

Accepted 2 November 2017

Available online 8 November 2017

### Keywords:

Case report

Female urethral cancer

Immunohistochemistry

Malignant melanoma

Urethral neoplasm

## ABSTRACT

**INTRODUCTION:** Melanoma is a malignant tumor that can affect any area of the anatomical economy. Its occurrence in the female urethra is extremely rare. We report a case of primary malignant urethral melanoma developed in an elderly female patient.

**PRESENTATION OF CASE:** A 70 years old female presented with dysuria, poor stream, gross haematuria, intermittent blood spots, and a painful mass. On physical examination, there were no suspicious lesions on the skin. On external genital examination, a lesion at the level of the urethral meatus was observed. The mass was removed by wide local excision under spinal anaesthesia. The pathological diagnosis was malignant melanoma of the urethra.

**DISCUSSION:** The common presentations include bleeding and/or discharge per urethra, voiding dysfunction and the presence of tumor mass. Survival depends on the stage, location and size of the neoplasm at the time of diagnosis. Despite major surgery, radiotherapy or immunotherapy; malignant melanoma usually has a poor prognosis.

**CONCLUSION:** Melanoma of the female urethra is an extremely uncommon pathology leading to paucity of literature and any definite recommendations regarding management. The histological and immunohistochemical findings can be helpful in making an early and accurate diagnosis of malignant melanoma in the urogenital region.

© 2017 Published by Elsevier Ltd on behalf of IJS Publishing Group Ltd. This is an open access article under the CC BY-NC-ND license (<http://creativecommons.org/licenses/by-nc-nd/4.0/>).

## 1. Introduction

Melanoma is a malignant tumor that can affect any area of the anatomical economy. Primary malignant melanoma of the genitourinary tract is extremely rare, accounting for less than 1% of all cases of melanoma [1,2]. Primary malignant melanoma of the urethra in females represents only 0.2% of all malignant melanomas, with approximately 121 cases in indexed literature since 1966 [3]. It was described for the first time in 1896 by Reed [4]. It is more common in females in a ratio of 3:1 with average age of presentation being 68 years, ranging from 32 to 80 years of age [5,6]. Since the clinical presentation of urethral melanoma is similar to that of urothelial carcinoma, there is frequently a delay in diagnosis [7]. Most malignant melanomas of the female urethra are located at the meatus and/or in the distal urethra [8]. The common presentations include bleeding, discharge, voiding dysfunction and the presence

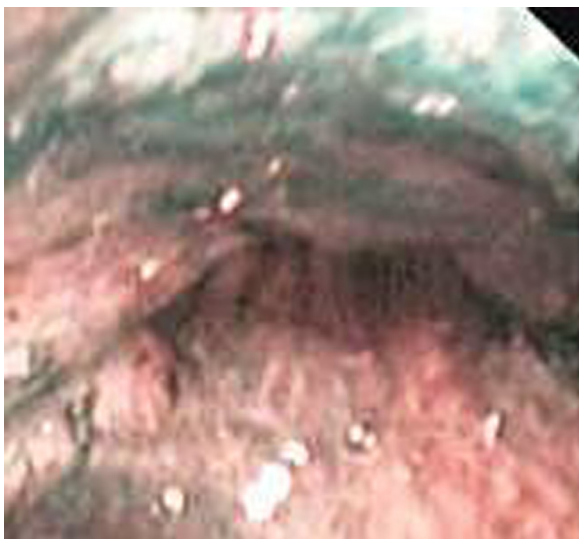
of tumor mass. Survival depends on the stage, location and size of the neoplasm at the time of diagnosis. Despite major surgery, radiotherapy or immunotherapy; malignant melanoma usually has a poor prognosis [11]. In this report, we present a case of malignant melanoma originating from the urethra in an elderly female and discuss the histological and immunohistochemical findings.

## 2. Case report

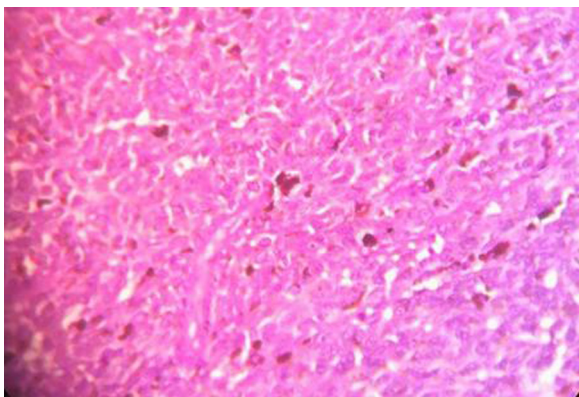
A 70-years-old woman presented to urology outpatient with history of dysuria, poor stream, gross haematuria and blood spots on undergarments intermittently. On examination, a firm, rounded, pedunculated, black pigmented, friable and haemorrhagic lesion of about 0.5 × 0.5 cm was found at the posterior wall of the urethral meatus. The findings on the per speculum and vaginal examination of the cervix and general physical examination were unremarkable. No organomegaly or lump was found on an abdominal examination and no superficial lymph nodes were palpable. On cystourethroscopy, it was evident that the lesion partially occluded the distal third of the urethra (Fig. 1). The mass was removed by a wide local excision with the patient under spinal anaesthesia.

\* Corresponding author at: 23/8FM, Medical Campus, Rohtak, Haryana 124001, India.

E-mail addresses: [namitabhutani89@gmail.com](mailto:namitabhutani89@gmail.com) (N. Bhutani), [drpradeepkajal@gmail.com](mailto:drpradeepkajal@gmail.com), [pradeepkajal98@gmail.com](mailto:pradeepkajal98@gmail.com) (P. Kajal), [pawar.devendra71@gmail.com](mailto:pawar.devendra71@gmail.com) (D. Pawar).



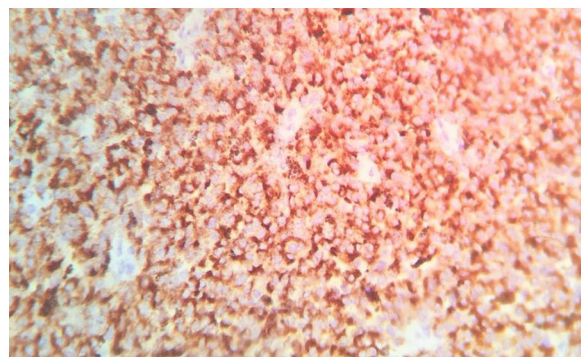
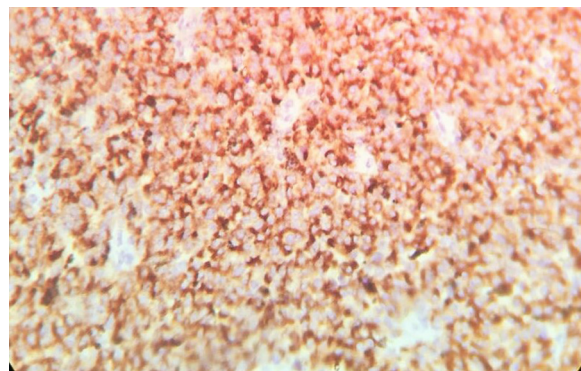
**Fig. 1.** On cystourethroscopy: A black colored lesion partially occluding the distal third of the urethra.



**Fig. 2.** On light microscopy: the large epitheloid tumor cells have dusty brown melanin pigments and frequent mitotic figures (H&E, ×400).

Gross examination of the resected specimen revealed a polypoidal solid mass (0.5 × 0.5 × 0.3 cm) with a dark-brown cut surface. The mass was covered with pinkish mucosa with surface ulceration. Histopathological analysis revealed polypoidal tumor with surface partially ulcerated and partially covered with squamous and transitional epithelium. The tumor was composed of loosely cohesive nests of atypical epitheloid and spindle shaped melanocytes showing diffuse and nested growth pattern. The neoplastic cells had abundant eosinophilic cytoplasm, large hyperchromatic nuclei with prominent nucleoli, and brisk mitotic activity (15/10 HPF). Most of the tumor cells contained coarsely granular melanocytic pigment (Fig. 2). No vascular/lymphatic invasion was seen histologically. Immunohistochemically tumor cells showed strong cytoplasmatic reactivity for HMB45 and S100 (Fig. 3A and B).

The clinical examination revealed no history of previous cutaneous biopsy or existence of recent suspicious pigmented lesion at any other location, and a diagnosis of primary melanoma was rendered. Initial metastatic evaluation, including computerized tomography scan of the chest, abdomen and pelvis revealed no evidence of disseminated disease. The patient showed no evidence of disease during a five year follow-up period.



**Fig. 3.** On IHC: The tumor cells were immunoreactive for HMB-45(A) and S-100 protein(B).

### 3. Discussion

Malignant melanoma originates from melanoblasts differentiated from neuroectodermal neural crest cells. Neural crest cells differentiate to melanocytes in the skin, oral mucosa, nasal mucosa and vulva; therefore, malignant melanoma occurs in these regions. Most malignant melanomas develop in the skin, accounting for 81% of all cases of melanoma. In contrast, the incidence of mucosal malignant melanomas is 17%, and these lesions mostly develop in the eyelid and eyeball. Malignant urethral melanomas, which usually originate from the distal urethra, account for 0.2% of all malignant melanomas and 4% of all urethral cancers [1–3]. The first case of malignant urethral melanoma was reported by Tyrell and Reed more than 100 years ago [4]. Malignant urethral melanoma is three times as common in females as in males and is more frequent in the Caucasian population, with an average age of 64 years at presentation [5,6]. Presenting symptoms include vaginal bleeding, masses, haematuria and dysuria with a decreased urinary stream [9]. Since one-fifth of primary malignant urethral melanomas are amelanotic [6], physicians should carefully differentiate primary neoplasms involving the urethra. Urethral melanomas are frequently misdiagnosed clinically, which leads to a delayed diagnosis. So, patients with this tumor usually show a poor prognosis [9]. Grossly, the tumor may be easily confused with a caruncle [10]. Primary malignant melanoma of the female urethra tends to metastasize at the early stage via the superficial lymphatics to the vulva and vagina, by the deep lymphatics to the inguinal lymph nodes and occasionally to distant sites by the haematogenous route.

Histogenesis of melanomas arising in mucous membranes still remains in dispute and several theories have been proposed. A possible alternative mechanism is the metaplasia of squamous and glandular epithelium into pigment-producing cells. Finally, neural crest elements may be transformed into melanocytes and nevus cells [12].

Malignant urethral melanomas frequently present as polypoidal tumors and are mistaken for other malignant diseases and even benign lesions, including urethral polyps, caruncles, mucosal prolapse or chancres [9,10]. The melanoma is usually pigmented and varies in colour from black to blue or light brownish; the lesions are firm, nodular, and often ulcerated. Ulceration in melanomas presumably reflects very aggressive tumor growth that infiltrates and destroys the mucosal membrane. Microscopic examination demonstrates, a wide histologic spectrum of patterns including diffuse, nested, fascicular, and storiform growth of pleomorphic cells [13]. This variability has made immunohistochemical markers for melanocyte differentiation a central part in making an accurate diagnosis. The most frequently used melanocytic markers are S-100 protein and HMB-45. Monoclonal antibodies against S-100 protein react with more than 90% of melanomas. However, although HMB-45 is quite specific for melanocytic neoplasms, it is less sensitive than S-100 protein for diagnosing melanoma [14].

The thickness of the tumor and the mitotic index have to be taken into account on microscopic examination, since tumors more than 1.5 mm thick and with more than one mitotic figure in every high power field carry a worse prognosis [5]. The presence of junctional activity in the area adjacent to the lesion is of primary importance in this determination. Urethral melanoma should be differentiated from benign pigmented lesions including genital lentiginosis, atypical melanocytic nevi and atypical lentiginous hyperplasia. Differential diagnosis include sarcoma, spindle cell carcinoma, small cell carcinoma, lymphoma and plasmocytoma [1,5,8].

The treatment recommendations primarily depend on the tumor location and the clinical stage. The principles of melanoma treatment are wide local excision with sentinel lymph node dissection. This is based on the concept that the sentinel lymph node is the first station of metastasis. Another treatment option could be partial urethrectomy, radical urethrectomy with a continent urinary diversion or even anterior pelvic exenteration with or without vulvectomy, as long as there is no clinical evidence of metastasis. Regional lymphadenectomy is done only in the case of positive metastasis in the sentinel lymph node, decreasing the morbidity of the procedure. Those patients with depth up to 3 mm can benefit from anterior pelvic exenteration. Radical surgery is contraindicated in cases of inguinal metastasis and in large-sized tumors [15].

The optimum treatment for urethral melanomas in women has not yet been defined. Several different surgical approaches were used in the cases with long-term survival that have been described in the literature, but no definitive conclusions can be drawn because of the limited number of patients and the lack of information about the depth of invasion in some of these cases. Radical surgical resection with postoperative adjuvant chemotherapy or immunotherapy is recommended, but little clinical experience exists to support such adjuvant treatment. Different regimens of adjuvant immunotherapy have been described with interferon alpha or interferon beta, with or without dacarbazine, vincristine and cyclophosphamide chemotherapy [16]. In the present case, we performed wide local excision. In addition, we recommended additional radical urethrectomy with bladder preservation to obtain a wide enough surgical margin and to prevent the progression of the disease.

The urethral malignant melanoma has a worse prognosis than a malignant melanoma of a cutaneous origin, partly because of the frequent finding of a vertical growth phase and lymph node metastasis at the time of initial diagnosis and partly because the location often results significant delays in making the diagnosis [16]. Primary malignant melanoma of the female urethra tends to metastasize at an early stage to adjacent areas, the regional lymph nodes, and occasionally distant sites by the haematogenous route.

The most significant prognostic factors for local control and overall survival is anatomic localization and tumor extension. Generally speaking, the prognosis in this case is poor due to the tendency to locally invade the vagina and the vulva. Also, distant recurrence may occur after primary resection at the level of lymph nodes or in the lung and less frequently in the liver [15]. In addition, more recently defined criteria, such as presence of melanoma cells in the peripheral blood have been shown to correlate with prognosis and overall survival as well [1,7].

#### 4. Conclusion

Melanoma of the female urethra is an extremely uncommon pathology leading to paucity of literature and any definite recommendations regarding management. Radical surgery with adjuvant chemotherapy appears to provide some response in an otherwise very poor prognostic scenario. The histological and immunohistochemical findings can be helpful for making an early and accurate diagnosis of malignant melanoma in the urogenital region as in our case.

#### Conflicts of interest

There is no conflict of interest amongst the authors.

#### Funding

There was no source of funding for our research.

#### Ethical approval

Not applicable as it is a case report.

#### Consent

Written informed consent was obtained from the patients' guardians for publication of this case series and any accompanying images.

We state that the work has been reported in line with the SCARE criteria [17].

We also declare that there are no conflicts of interest amongst the authors.

We also state that there was no source of funding for this study.

#### Author contribution

Namita Bhutani – Reviewed the literature and wrote the article.  
Pradeep Kajal – Supervised the article and did the final editing.  
Devendra Pawar – Operated upon the patient and gave important inputs regarding the management of the case.

#### Registration of research studies

Not applicable.

#### Guarantor

Pradeep Kajal.

#### References

- [1] R. Gupta, S.S. Bhatti, A.K. Dinda, M.K. Singh, Primary melanoma of the urethra: a rare neoplasm of the urinary tract, *Int. Urol. Nephrol.* 39 (2007) 833–836.
- [2] P. Das, N. Kumar, A. Ahuja, A. Jain, R. Ray, C. Sarkar, S.D. Gupta, Primary malignant melanoma at unusual sites: an institutional experience with review of literature, *Melanoma Res.* 20 (2010) 233–239.

- [3] A. Akbas, T. Akman, M.R. Erdem, B. Antar, I. Kilicarslan, S.Y. Onol, Female urethral malignant melanoma with vesical invasion: a case report, *Kaohsiung J. Med. Sci.* 26 (2010) 96–98.
- [4] C.A. Reed, Melanosarcoma of the female urethra: urethrectomy recovery, *Am. J. Obstet. Gynecol.* 34 (1896) 864–872.
- [5] D.S. DiMarco, C.S. DiMarco, H. Zincke, M.J. Webb, G.L. Keeney, S. Bass, et al., Outcome of surgical treatment for primary malignant melanoma of the female urethra, *J. Urol.* 171 (2004) 765–767.
- [6] E. Oliva, T.R. Quinn, M.B. Amin, J.N. Eble, J.I. Epstein, J.R. Srigley, et al., Primary malignant melanoma of the urethra: a clinicopathologic analysis of 15 cases, *Am. J. Surg. Pathol.* 24 (2000) 785–796.
- [7] E.E. Katz, K. Suzue, M.A. Wille, T. Krausz, D.E. Rapp, M.H. Sokoloff, Primary malignant melanoma of the urethra, *Urology* 65 (2005) 389.
- [8] C.J. Kim, K. Pak, A. Hamaguchi, A. Ishida, Y. Arai, T. Konishi, Y. Okada, T. Tomoyoshi, Primary malignant melanoma of the female urethra, *Cancer* 71 (1993) 448–451.
- [9] L.A. Filipkowski, M.A. Barker, M.M. Karram, Primary genitourinary melanoma presenting as voiding dysfunction, *Int. Urogynecol. J. Pelvic Floor Dysfunct.* 20 (2009) 1141–1143.
- [10] T. Nakamoto, Y. Inoue, T. Ueki, N. Niimi, Y. Iwasaki, Primary amelanotic malignant melanoma of the female urethra, *Int. J. Urol.* 14 (2) (2007) 153–155.
- [11] R.E. Poore, D.L. McCullough, Urethral carcinoma, in: J.Y. Gillenwater, J.T. Grayhalk, S.S. Howard (Eds.), *Adult and Pediatric Urology*, 3rd ed., Mosby, Missouri, 1996, pp. 1837–1850.
- [12] L.J. Markovič-Puč, A. Relji, B. Krušlin, Primarni maligni melanom 'enske uretre, *Liječ. Vjesn* 121 (1999) 98–99.
- [13] R.W. Jones, J. Baranyai, S. Stables, Trends in squamous cell carcinoma of the vulva: the influence of vulvar intraepithelial neoplasia, *Obstet. Gynecol.* 90 (3) (1997) 448–452.
- [14] M.V. Sheffield, H. Yee, C.C. Dorvault, K.N. Weilbaeher, I.A. Eltoum, G.P. Siegal, G.P. Siegal, G.P. Siegal, Comparison of five antibodies as markers in the diagnosis of melanoma in cytologic preparations, *Am. J. Clin. Pathol.* 118 (930) (2002) 6.
- [15] V. Gunther, I. Alkatout, C. Lez, S. Altarac, R. Fures, H. Cupic, et al., Malignant Melanoma of the Urethra: A Rare Histologic Subdivision of Vulvar Cancer with a Poor Prognosis, *Case Rep. Obstet. Gynecol.* (2012), 385175, <http://dx.doi.org/10.1155/2012/385175>.
- [16] V.E. Sugiyama, J.K. Chan, D.S. Kapp, Management of melanomas of the female genital tract, *Curr. Opin. Oncol.* 20 (2008) 565–569.
- [17] R.A. Agha, A.J. Fowler, A. Saetta, I. Barai, S. Rajmohan, D.P. Orgill, for the SCARE Group, The SCARE statement: consensus-based surgical case report guidelines, *Int. J. Surg.* 34 (2016) 180–186.

#### Open Access

This article is published Open Access at [sciedirect.com](http://sciedirect.com). It is distributed under the [IJSCR Supplemental terms and conditions](#), which permits unrestricted non commercial use, distribution, and reproduction in any medium, provided the original authors and source are credited.