

## Technical Note

# Temporary clamping of bilateral external carotid arteries for surgical excision of a complex dural arteriovenous fistula

Shih-Chieh Shen, Wen-Hsieh Chen<sup>1</sup>, Se-Yi Chen<sup>2</sup>, Ming-Hsi Sun<sup>2</sup>, Chiung-Chyi Shen<sup>2</sup>,  
Yuang-Seng Tsuei<sup>2</sup>

Departments of Surgery, Tri-Service General Hospital Songshan Branch, Taipei, <sup>1</sup>Radiology, <sup>2</sup>Neurosurgery, Taichung Veterans General Hospital, Taichung, Taiwan

E-mail: Shih-Chieh Shen - [james701004@yahoo.com.tw](mailto:james701004@yahoo.com.tw); Wen-Hsieh Chen - [whchen@vghtc.gov.tw](mailto:whchen@vghtc.gov.tw); Se-Yi Chen - [s861085@gmail.com](mailto:s861085@gmail.com);  
Ming-Hsi Sun - [mgsun@vghtc.gov.tw](mailto:mgsun@vghtc.gov.tw); Chiung-Chyi Shen - [shengeorge@yahoo.com](mailto:shengeorge@yahoo.com); \*Yuang-Seng Tsuei - [astrocytoma2001@yahoo.com.tw](mailto:astrocytoma2001@yahoo.com.tw)

\*Corresponding author:

Received: 18 June 13 Accepted: 18 December 13 Published: 23 January 14

### This article may be cited as:

Shen S, Chen WH, Chen S, Sun M, Shen C, Tsuei Y. Temporary clamping of bilateral external carotid arteries for surgical excision of a complex dural arteriovenous fistula. Surg Neurol Int 2014;5:10.

Available FREE in open access from: <http://www.surgicalneurologyint.com/text.asp?2014/5/1/10/125780>

Copyright: © 2014 Shen SC. This is an open-access article distributed under the terms of the Creative Commons Attribution License, which permits unrestricted use, distribution, and reproduction in any medium, provided the original author and source are credited.

## Abstract

**Background:** Some complex dural arteriovenous fistulas (DAVFs) are lesions that typically have numerous arterial feeders. Surgery, including resection of fistulas or skeletonization of the diseased sinus, is still one of the important treatments for these lesions. However, major blood loss is usually encountered during craniotomy because of abundant arterial feeders from the scalp and transosseous vessels. We present a novel approach for obliteration of the fistulas with less blood loss.

**Methods:** Our first case was a 52-year-old male who suffered from syncope and seizure. Cerebral digital subtraction angiography (DSA) revealed complex DAVFs with numerous arterial feeders from bilateral external carotid arteries (ECAs) and drainage into the superior sagittal sinus with cerebral venous reflux. The second case was a 48-year-old male presenting with chronic headache. His DSA also showed complex DAVFs along the superior sagittal sinus with cerebral venous reflux. In both cases, we performed the surgical procedure to obliterate the pathological fistulas after temporary clamping of bilateral ECAs and noted less blood loss than in the conventional surgery.

**Results:** The follow-up DSA showed successful obliteration of the complex DAVFs on the first case and partial improvement on the second case followed by transarterial embolization (TAE). The symptoms of the both patients were relieved after surgery with good recovery.

**Conclusion:** Temporary clamping of bilateral ECAs can improve the safety and ease the surgical excision for complex DAVFs. By using this technique, neurosurgeons can deal with aggressive DAVFs more confidently and calmly.

**Key Words:** Dural arteriovenous fistula, external carotid arteries, temporary clamping

### Access this article online

#### Website:

[www.surgicalneurologyint.com](http://www.surgicalneurologyint.com)

#### DOI:

10.4103/2152-7806.125780

#### Quick Response Code:



## INTRODUCTION

Surgical excision of complex dural arteriovenous fistulas (DAVFs) usually encounters massive blood

loss during the skull approach because of abundant scalp and transosseous feeders mainly from branches of bilateral external carotid arteries (ECAs).<sup>[7,11]</sup> Although preoperative transcatheter embolization can help reduce

blood loss, it is neither feasible nor cost-effective to embolize all feeders. Here, we present two cases of complex DAVFs in which temporary clamping of bilateral ECAs reduced blood loss successfully without complications related to temporary occlusion.

## CASE PRESENTATION

### Case 1

A 52-year-old male presented with head heaviness and headache, which he had for 3 weeks. He was sent to our emergency room due to his syncope and seizure. Computed tomography (CT) angiography of the brain revealed no intracranial hemorrhage but did show numerous engorged vessels in bilateral cerebral hemisphere and superficial scalp. However, digital subtraction angiography (DSA) showed numerous arterial feeders from the bilateral parietal-occipital scalp and dura, which shunted into superior sagittal sinus with cerebral venous reflux, compatible with DAVFs, Cognard type IIb [Figure 1a and b]. Urgent surgical intervention for excision of fistulas and skeletonization of the diseased sinus was performed after temporary clamping of bilateral ECAs. Intraoperative angiogram showed complete obliteration of fistula and normal venous return [Figure 1e and f]. Eventually, the patient had good recovery without any morbidity. The modified Rankin scale (mRS) was also zero at discharge.

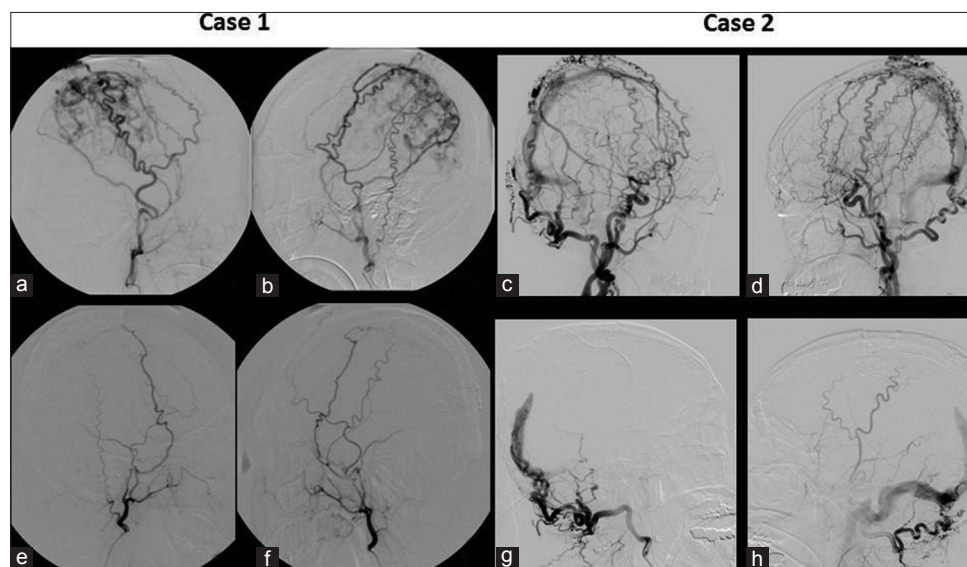
### Case 2

A 48-year-old male presented with chronic headache, which he had suffered for several years, with pulsatile bruit sound over the bilateral ears. Neurological examination revealed no specific neurological deficit.

CT angiography of the brain revealed no intracranial hemorrhage but did show numerous engorged vessels in bilateral cerebral hemisphere and superficial scalp. DSA showed DAVFs, Cognard type IIb, in sagittal-torcular region with numerous arterial feeders from bilateral ECAs with cerebral venous reflux [Figure 1c and d]. It is risky to excise fistulas involving torcular region so surgical excision of arterial feeders and skeletonization of diseased sinus as possible was planned. The purpose of surgery is to reduce abnormal shunting flow and to prepare for further endovascular embolization or radiosurgery while identifying the exact fistula well. Using temporary clamping of bilateral ECAs, the partial excision of the complex DAVFs became easy [Figure 1g and h]. Later, transarterial embolization (TAE) with Onyx (ev3, Irvine, California) was performed to obliterate the residual DAVFs successfully. The mRS was also zero at discharge.

### Surgical procedure

Both cases received surgical intervention for their complex DAVFs in the hybrid operating room equipped with Artis Zeego multi-axis system (Siemens, Germany). The patient was placed in a supine position with head raised about 30 degrees. Then, an angiographic catheter was inserted into the right femoral artery for intraoperative DSA first. Skin sterilization and draping were prepared over both the neck and the vertex. Before the craniotomy was performed over the bilateral parietal region, bilateral ECAs were isolated surgically [Figure 2a]. After temporary clamping of the bilateral ECAs by vessel clamps, confirmed by intraoperative angiography, we performed a large, open-book scalp incision over the convexity [Figure 2b] followed by craniotomy and skeletonization of diseased sinus within 60 minutes. Then,



**Figure 1:** (a) Preoperative angiograms of right ECAs; (b) left ECAs showing numerous and tortuous arterial feeders and DAVFs along superior sagittal sinus in case 1; (c) Preoperative angiograms of right ECAs; (d) left ECAs showing numerous and tortuous arterial feeders, superior sagittal sinus and torcular DAVFs in case 2; (e and f) total obliteration of fistulas after surgery in case 1; (g and h) showing obliteration of DAVF at superior sagittal sinus but residual DAVFs near torcular area after surgery in case 2

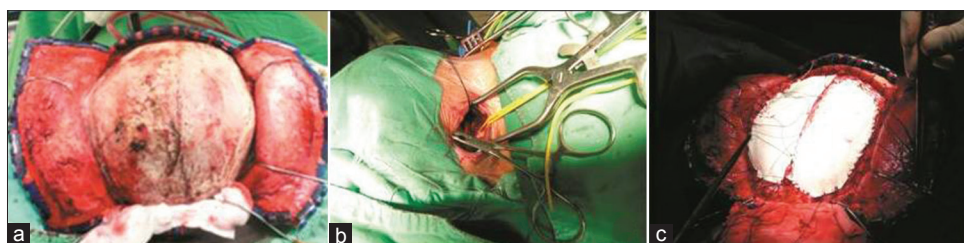we released the clamping and checked the postoperative cerebral DSA before the wound closure. Total blood loss was about 150-200 ml by estimate in each case, even less than the conventional craniotomy.

## DISCUSSION

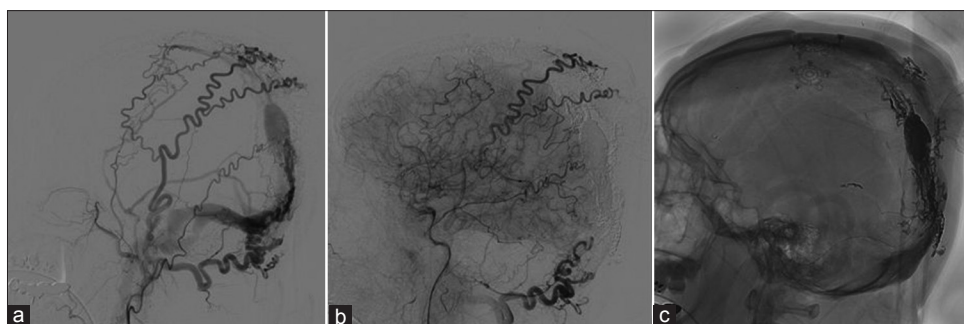
High-grade intracranial DAVFs, which were classified into Borden type II and III<sup>[2]</sup> or Cognard type IIb, III and IV,<sup>[3]</sup> predispose patients to the risk of hemorrhage presentation and nonhemorrhagic neurological deficit.<sup>[5]</sup> In general, aggressive treatment of DAVFs should be considered in any clinical scenario that predisposes to produce a permanent injury to the central nervous system or is life-threatening. As advance endovascular techniques and stereotactic radiosurgery developed, the results and outcomes of the patients markedly improved in the past decade.<sup>[10]</sup> However, surgical consideration is indicated in some circumstances including DAVFs with numerous and/or tortuous arterial feeders not appropriate for embolization, an arterial feeder with prominent branches into normal structures near or at the fistulous connection, a long and tortuous feeder that is difficult to navigate, or a persistent fistula after endovascular or radiosurgical therapy.<sup>[11]</sup> Conventional surgical treatments include simple occlusion of the draining veins, or sinus skeletonization by cutting the dura along both sides of the sinus, to interrupt the drainage of the feeding arteries into it.<sup>[4,6,8]</sup> During the surgical approach, the scalp, transosseous and dural feeders from bilateral ECAs may be markedly hypervascular that would cause rapid and massive blood loss, even fatal hemorrhage when the

exposure is close to the involved sinus.<sup>[7,12]</sup> There is no real amount of blood loss recorded in relative literature. However, according to our experience of dealing with these complex DAVFs, estimated blood loss more than 500 ml was reached when the craniotomy had just been done. Our purpose is to reduce the blood loss during the surgery, significantly cut the arterial feeders to isolate the involved sinus and obliterate the cerebral venous reflux.

Temporary clamping bilateral ECAs has been used for surgery of convexity and parasagittal meningiomas,<sup>[9,13]</sup> which also presented an effective technique without significant complication. By our two cases, we presented here illustrate a simple but effective technique to minimize blood loss by temporary clamping bilateral ECAs. Then numerous and tortuous arterial feeders can be removed by excision of pathological dura replaced by artificial one [Figure 2c]. Occlusion of bilateral ECAs might be complicated with skin necrosis, wound infection or facial pain due to the ischemic effect. Thrombus formation due to clamping of atherosclerotic vessels might cause an embolic phenomenon and permanent occlusion of distal vessels. Therefore, especially in older patients, such vessels should be manipulated very gently and carefully. Ocular ischemic syndrome after the occlusion of bilateral ECAs has been reported.<sup>[1]</sup> In our two cases, which the clamping lasted about 90 minutes, there was no ischemic effect after temporary clamping of bilateral ECAs. Careful control of ischemic time is necessary to prevent related complications. The mRS of both our cases were zero at discharge. There were good wound healing and no complaint about the facial discomfort of both cases.



**Figure 2:** Intraoperative photos of case 2; (a) Bifrontal-parietal craniotomy following "open-book" scalp incision; (b) Temporary clamping bilateral ECAs (c) Skeletonization of diseased superior sagittal sinus and replacing the pathological dura



**Figure 3:** (a) Preembolization angiogram showing residual DAVFs above torcular area in case 2; (b) Angiogram after transarterial embolization with Onyx showing total obliteration of the fistula; (c) Lateral plain view showing the Onyx cast postembolization

A limitation of our report is that we just completely obliterated all fistulas primarily on our first case, but the second did not. Residual DAVFs involving the sagittal-torcular region on the second case was identified by postoperative cerebral angiogram [Figure 3a]. TAE with Onyx was performed later and obliterated the residual DAVFs successfully [Figure 3b and c]. It could be expected because the second case had partial superior sagittal sinus DAVFs close to torcular region that our surgical approach did not reach. At least, downgrading or simplification of the aggressive, high-grade DAVFs was achieved. Besides, we understand better about the complex shunting point on the initial angiogram. Further endovascular embolization or radiosurgery could be performed more efficiently.

## CONCLUSION

Thus, we conclude that temporary clamping of bilateral ECAs can improve the safety and ease the surgical excision for complex DAVFs. There also may be economic advantages because of the reduction in blood transfusion and length of hospital stay. By using this technique, neurosurgeons can deal with aggressive DAVFs more confidently and calmly.

## REFERENCES

1. Alizai AM, Trobe JD, Thompson BG, Izer JD, Cornblath WT, Deveikis JP. Ocular ischemic syndrome after occlusion of both external carotid arteries. *J Neuroophthalmol* 2005;25:268-72.
2. Borden JA, Wu JK, Shucart WA. A proposed classification for spinal and cranial dural arteriovenous fistulous malformations and implications for treatment. *J Neurosurg* 1995;82:166-79.
3. Cognard C, Gobin YP, Pierot L, Bailly AL, Houdart E, Casasco A, et al. Cerebral dural arteriovenous fistulas: Clinical and angiographic correlation with a revised classification of venous drainage. *Radiology* 1995;194:671-80.
4. D'Aliberti G, Talamonti G, Collice M. Sinus skeletonization. *J Neurosurg* 1996;85:738-40.
5. Gross BA, Du R. The natural history of cerebral dural arteriovenous fistulae. *Neurosurgery* 2012;71:594-602.
6. Hugosson R, Bergstrom K. Surgical treatment of dural arteriovenous malformation in the region of the sigmoid sinus. *J Neurol Neurosurg Psychiatry* 1974;37:97-101.
7. Kakarla UK, Deshmukh VR, Zabramski JM, Albuquerque FC, McDougall CG, Spetzler RF. Surgical treatment of high-risk intracranial dural arteriovenous fistulae: Clinical outcomes and avoidance of complications. *Neurosurgery* 2007;61:447-57.
8. Lucas CP, De Oliveira E, Tedeschi H, Siqueira M, Lourenzi M, Piske RL, et al. Sinus skeletonization: A treatment for dural arteriovenous malformations of the tentorial apex. Report of two cases. *J Neurosurg* 1996;84:514-7.
9. Mukherjee KK, Salunke P, Chhabra R, Adhikari S, Bharti N. Temporary bilateral external carotid artery clamping to reduce blood loss during removal of calvarial meningioma: A technical note. *Br J Neurosurg* 2011;25:127-9.
10. Piippo A, Niemelä M, van Popta J, Kangasniemi M, Rinne J, Jääskeläinen JE, et al. Characteristics and long-term outcome of 251 patients with dural arteriovenous fistulas in a defined population. *Clinical article. J Neurosurg* 2013;118:923-4.
11. Pradilla G, Coon AL, Huang J, Tamargo RJ. Surgical treatment of cranial arteriovenous malformations and dural arteriovenous fistulas. *Neurosurg Clin N Am* 2012;23:105-22.
12. Sundt TM Jr, Piepgras DG. The surgical approach to arteriovenous malformations of the lateral and sigmoid dural sinuses. *J Neurosurg* 1983;59:32-9.
13. Yadav YR, Parihar V, Agarwal M, Bhatele PR. Temporary clamping of external carotid artery in convexity, parasagittal and temporal base meningioma. *Turk Neurosurg* 2012;22:44-9.