

Efficacy of arthrocentesis versus arthrocentesis with sodium hyaluronic acid in temporomandibular joint osteoarthritis: A comparison

ABSTRACT

Introduction: Temporomandibular joint osteoarthritis (TMJ OA) is a degenerative disease characterized by deterioration of articular tissue with concomitant osseous changes in the condyle and/or articular eminence, joint positive for TMJ noise with jaw movement or function, crepitus detected on palpation on opening, closing, right/left lateral, or protrusive movement. Hyaluronic acid (HA) is a polysaccharide of the family of glycosaminoglycans. HA has been shown to improve and restore normal lubrication in joint, provide nutrition to the avascular articulating disc, and stabilize the joint.

Materials and Methods: Twenty patients with OA of TMJ with age limit between 18 and 60 years of age were enrolled in this study. Patients were randomly divided into two groups, in which one group received arthrocentesis only, and another group received arthrocentesis plus intra-articular injection of sodium HA (0.5 ml) in superior joint space in a cycle of 5 weekly arthrocentesis (one per week). Patients were followed at regular interval of 1st day, 5th day, 7th day, 4 weeks, 6 weeks, and 12 weeks. Assessment of clinical outcome was done in terms of reduction in pain (visual analog scale score), maximum mouth opening (MMO) in millimeters, painful/pain-free lateral or protrusive jaw movement, and clicking/crepitus in joint.

Results: Significant reduction in pain was observed in both the groups. MMO, lateral and protrusive movements improved significantly in both groups; however, arthrocentesis with sodium HA was superior to arthrocentesis alone.

Conclusion: Combination of arthrocentesis with HA injection showed much better outcome than arthrocentesis alone.

Keywords: Arthrocentesis, hyaluronic acid, osteoarthritis, temporomandibular joint

INTRODUCTION

Osteoarthritis (OA) is a degenerative joint disease that progresses slowly over the years causing destruction of joint structures. Diagnosis of degenerative joint disorders is made on the basis of criteria described by Dworkin and LeResche, namely, deterioration of articular tissue with concomitant osseous changes in the condyle and/or articular eminence, joint positive for temporomandibular joint (TMJ) noise with jaw movement or function, crepitus detected on palpation on opening, closing, right/left lateral, or protrusive movement. OA commonly affects the TMJ causing chronic pain, affecting function, and also causing deformity in long-standing cases.^{1,2} Several conservative methods of treatment have been applied in the management of TMJ OA, namely, physical therapy,

pharmacological, steroid injection, hyaluronic acid (HA) injection, and acupuncture. Arthrocentesis combined with viscosupplementation has shown to have positive effects on TMJ OA. Beneficial results of HA injection in larger joints^{3,4} have led to its use in TMJ OA.

TIKARAM GURUNG, R. K. SINGH, SHADAB MOHAMMAD, U. S. PAL, ABAS ALI MAHDI¹, MANOJ KUMAR²

Departments of Oral and Maxillofacial Surgery and

¹Biochemistry, KGMU, ²Department of Radiodiagnosis,


King George Medical University, Lucknow, Uttar Pradesh, India

Address for correspondence: Dr. Tikaram Gurung,
King George's Medical University, Lucknow, Uttar Pradesh, India.
E-mail: gtika@hotmail.com

This is an open access article distributed under the terms of the Creative Commons Attribution-NonCommercial-ShareAlike 3.0 License, which allows others to remix, tweak, and build upon the work non-commercially, as long as the author is credited and the new creations are licensed under the identical terms.

For reprints contact: reprints@medknow.com

How to cite this article: Gurung T, Singh RK, Mohammad S, Pal US, Mahdi AA, Kumar M. Efficacy of arthrocentesis versus arthrocentesis with sodium hyaluronic acid in temporomandibular joint osteoarthritis: A comparison. Natl J Maxillofac Surg 2017;8:41-9.

Access this article online	
Website: www.njms.in	Quick Response Code 
DOI: 10.4103/njms.NJMS_84_16	

HA is a polysaccharide which is produced by chondrocytes and synoviocytes of the joints. HA has been shown to improve and restore normal lubrication in joint, provide nutrition to the avascular articulating disc, and stabilize the joint. The therapeutic mechanism of action of HA in OA is chondroprotection, effect on proteoglycan and glycosaminoglycan synthesis, anti-inflammatory, mechanical (viscosupplementation), effect on subchondral bone, and analgesic.

Brusie *et al.*, 1992^[5] combined sodium hyaluronate with joint lavage in treating septic arthritis in horses and found it more beneficial than lavage alone. Kopp *et al.*^[6] compared short-term effect of intra-articular injection of sodium hyaluronate in sample of 33 patients who had pain and tenderness to palpation in TMJ for at least 6 months duration that had not responded to conservative treatment. They injected 0.5 ml of drugs in superior joint space twice in 2-week interval and subjective symptoms, clinical signs, and bite force was assessed. Both drugs reduced symptoms and signs significantly, and no significant difference was found between the effects of two drugs. Therefore, owing to various side effects of corticosteroids, new era of use of sodium hyaluronate in TMJ disorders evolved.

The aim of this study was to compare the efficacy of arthrocentesis alone and arthrocentesis with sodium HA in TMJ OA.

MATERIALS AND METHODS

The present study comprised twenty patients with OA of TMJ with age limit between 18 and 60 years of age that had a diagnosis of OA as per the Research Diagnostic Criteria/ temporomandibular disorders (TMDs). Axis I Group IIIb was included in the study. Out of twenty patients, three patients were referred from the Department of Orthopedics and two from the Department of ENT. Informed consent to participate in the study was obtained from the patients, and ethical clearance was obtained from Institutional Ethical Committee, King George's Medical University, Lucknow. Patients having debilitated diseases, systemic autoimmune diseases, disturbed coagulation ability, severe allergic reaction to multiple medication, pain from traumatic injury and patients not willing to give consent or not willing to participate in the study were excluded.

Patients were randomly divided (computer-generated randomization) into two groups: Group A patients were treated with arthrocentesis with Ringer's lactate solution (100–300 ml) in a cycle of 5 weekly arthrocentesis (one per week) [Figures 1-3]. Group B patients were treated

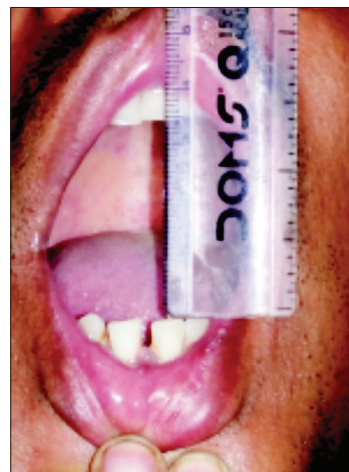

Figure 1: Preoperative mouth opening

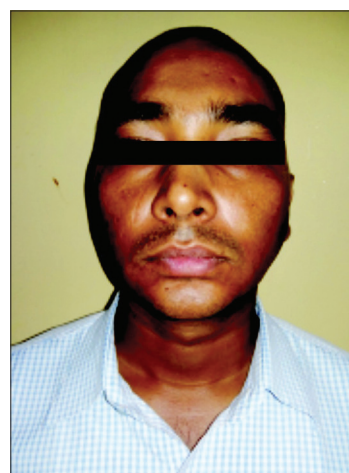

Figure 2: Preoperative photograph

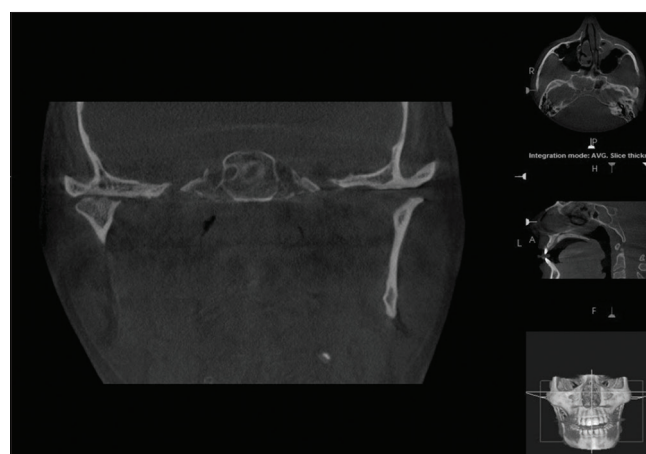


Figure 3: Preoperative cone beam computed tomography

with arthrocentesis with Ringer's lactate solution plus intra-articular injection of sodium HA (IA-HA) (0.5 ml) in superior joint space in a cycle of 5 weekly arthrocentesis (one per week) [Figures 4-6].

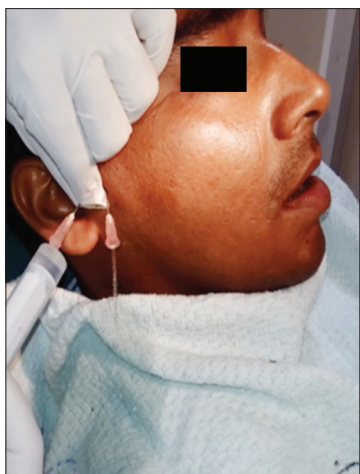

Figure 4: Arthrocentesis

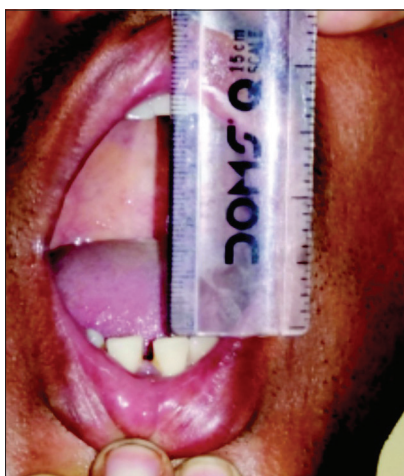


Figure 5: Postoperative 6 weeks

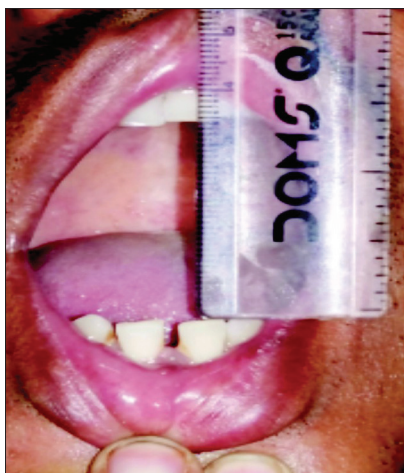

Figure 6: Postoperative 12 week

This procedure was done under local anesthesia. The patients are seated inclined at a 45° angle with the head turned to contralateral side. The points of needle insertion on the skin, according to the method suggested by McCain (1988) for the

performance for arthroscopy, are as follows: a line is drawn from the middle of the tragus to the outer canthus of the eye. The posterior entrance point is located along the canthotragal line, 10 mm from the middle of the tragus line and 2 mm below, the anterior entrance point is placed 10 mm further forward (total 20 mm) along the line and 10 mm below it [Figure 7]. Lidocaine 2% with adrenaline 1:100,000 is injected at the planned entrance points. An 18-gauge needle connected to a 5 ml syringe with the Ringer's lactate solution is then inserted into the superior compartment at the articular fossa (posterior point), and solution is injected to distend the upper joint space. Another 18-gauge needle is then inserted into the distended compartment in the area of articular eminence to enable the free flow of Ringer's lactate solution through the superior compartment [Figure 8]. Approximately 100–300 ml of Ringer's lactate solution is passed through the joint space [Figure 8]. During the lavage, the mandible is moved through opening, excursive, and protrusive movements to facilitate lysis of adhesions. In Group B patients, once arthrocentesis is completed an ampule of sodium HA (synolife 20 mg/ml, Reliance Life Sciences) was connected to the needle *in situ* and 0.5 ml injected into the superior joint space. Pressure dressing was placed in site of injection [Figure 9].

Patients were followed at regular interval of 1st day, 5th day, 7th day, 4 weeks, 6 weeks, and 12 weeks [Figure 10]. Subjective and objective outcome variables were assessed to test the efficacy of the treatment protocol. Postoperative assessment was done in terms of reduction in pain (visual analog scale [VAS] score), swelling following arthrocentesis if any, maximum mouth opening (MMO) in millimeters [Figure 7], painful/pain-free lateral or protrusive jaw movement, and clicking/crepitus in the joint and radiological assessment of joint with cone-beam computed tomography (CBCT) [Figures 11 and 12]. Determination of tumor necrosis factor alpha (TNF- α) and interleukin (IL)-6 in lavage fluid was done preoperatively and 3 months postoperatively.

RESULTS

A total of twenty patients with painful TMJ were enrolled in the present study. Out of these 10 patients were treated with temporomandibular lavage (arthrocentesis) alone (Group A) and next 10 patients were treated with arthrocentesis with sodium HA (Group B). The patients were followed up to 12 weeks. Majority of the patients of both Group A (60%) and Group B (80%) were males. Most of the patients were of younger age group. Improvement in pain was assessed in VAS. Significant reduction in pain was observed in both groups by 12th postoperative week, but reduction in pain was more in Group B [Table 1]. In Group A, nine patients reported with

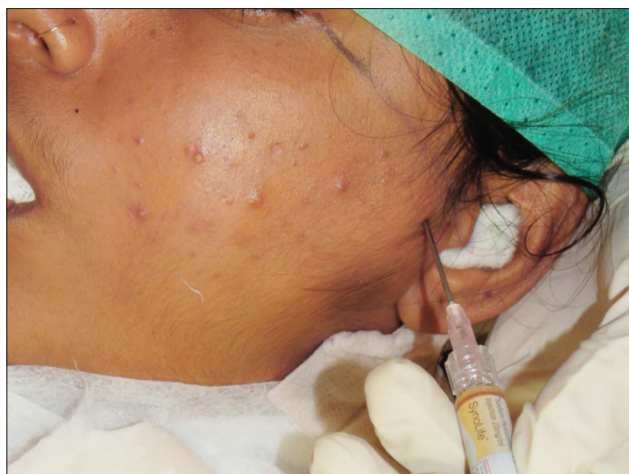

Figure 7: Intra-articular injection of hyaluronic acid

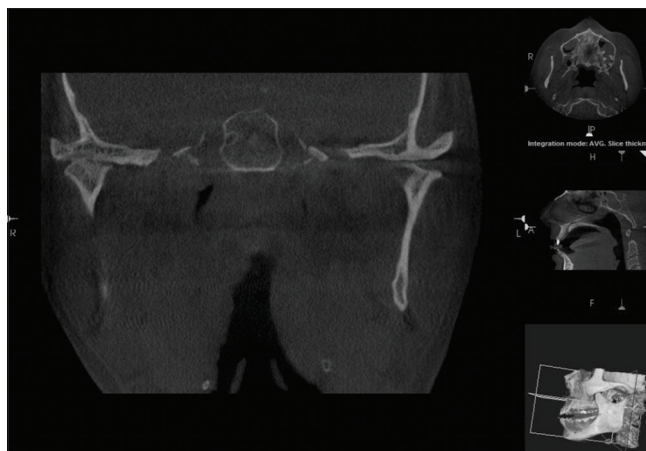


Figure 8: Postoperative cone-beam computed tomography

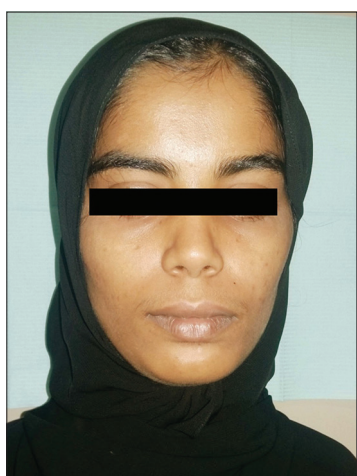

Figure 9: Group B patient preoperative photograph

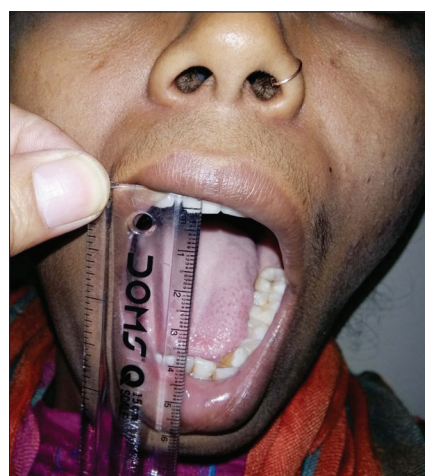


Figure 10: Group B postoperative 12 weeks

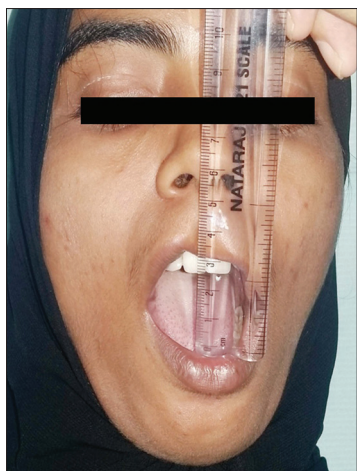

Figure 11: Group B preoperative mouth opening

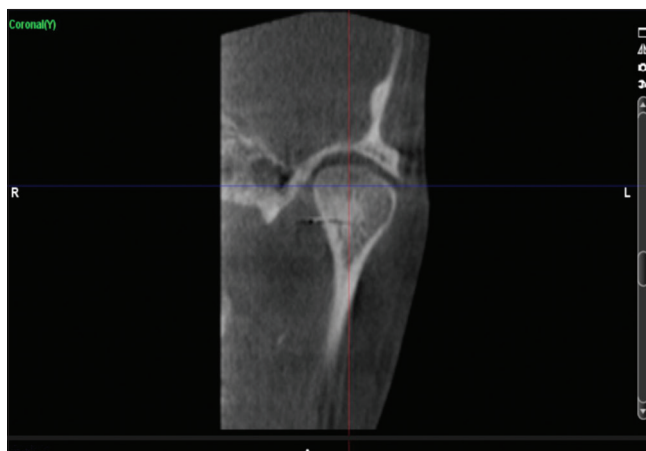

Figure 12: Group B preoperative cone beam computed tomography

moderate pain and one patient reported with severe pain preoperatively. On day 1, day 5, day 7 follow-up, nine patients had moderate pain, and one had no to mild pain. On 4th week, only 4 patients had moderate pain. By 12th week, all patients

had no to mild pain, i.e., pain was significantly decreased. In Group B, two patients had severe pain, and eight patients had moderate pain preoperatively, and by 4th week, nine patients had no to mild pain. And by 12th week postoperatively, all patients were relieved of pain [Table 2].

MMO was recorded in millimeters preoperatively and in subsequent follow-up visits. Significant increase in MMO was observed in both groups, but early and significant improvement in MMO was observed in Group B patients receiving arthrocentesis plus HA injection [Table 3]. Lateral and protrusive movements were also found to be improved [Figures 7 and 13], and lateral excursive movements of jaw were pain free by 12th week of follow-up [Table 4, Figures 10 and 14]. Lavage fluid was collected preoperatively and 3 months postoperatively, and level of IL-6 and TNF- α was estimated. A significant decrease in the level of IL-6 in lavage fluid was observed from preoperative to 3 months postoperative in both Group A ($P = 0.0001$) and Group B ($P = 0.0001$) [Table 5]. The decrease in IL-6 was higher in Group B compared to Group A. Similarly, a significant decrease in the level of TNF- α in lavage fluid was observed from preoperative to 3 months postoperative in both Group A ($P = 0.0001$) and Group B ($P = 0.0001$) [Table 6]. The decrease in TNF- α was higher in Group B compared to Group A.

DISCUSSION

OA is a degenerative disease characterized by progressive degradation of cartilage, subchondral bone remodeling,

Table 1: Comparison of pain across time interval between groups

Time period	Mean \pm SD		P
	Group A	Group B	
Pre-op	5.40 \pm 0.94	5.90 \pm 0.73	0.28
Day 1	6.20 \pm 1.22	5.00 \pm 1.05	0.04*
Day 5	5.20 \pm 1.22	4.00 \pm 1.05	0.03*
Day 7	4.70 \pm 1.05	3.20 \pm 0.78	0.003*
Week 4	3.60 \pm 1.43	2.80 \pm 0.91	0.24
Week 6	3.30 \pm 1.25	1.90 \pm 0.31	0.004*
Week 12	2.40 \pm 1.07	1.30 \pm 0.48	0.007*

* $P < 0.05$ significant

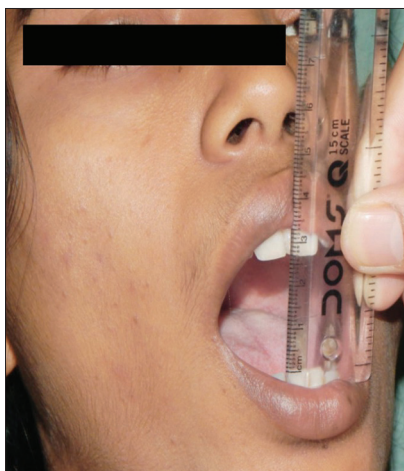

Figure 13: Group B postoperative 6 weeks

synovitis, and chronic pain. In TMJ OA, the cause is likely complex, multifactorial, or simply not yet known. Speculation has focused on excessive mechanical loading of normal articular cartilage or normal mechanical loading on impaired cartilage, which begins the disruptive process leading to OA.

Traditional treatment for TMJ OA includes nonsurgical options such as physical therapy, occlusal splints, nonsteroidal anti-inflammatory drugs, and arthrocentesis with lubrication or corticosteroids. The goal is to manage symptoms, halt disease progression, and restore TMJ function. IA-HA has been proposed to have many therapeutic mechanisms of action in the OA, namely, chondroprotection, effect on proteoglycan and glycosaminoglycan synthesis, anti-inflammatory, mechanical, effect on subchondral bone and analgesic.^[7]

There has been increasing clinical application of TMJ arthrocentesis in TMJ disorders. In patients with reduced range of jaw movements, the technique of arthrocentesis helps to break adhesions and adherences, thus increasing mouth opening.^[8] Studies on larger joints have suggested that viscosupplementation has positive effects on inflammatory degenerative diseases of larger joints, thus providing rationale for the use of HA injections in TMJ OA.^[9,10]

Theories supporting the role of viscosupplementation of HA in TMJ has led to introduction of HA injections alone or with arthrocentesis in TMJ disorders.^[11,12]

The present study was conducted to compare the clinical outcomes of patients with TMJ OA who were treated with arthrocentesis only and arthrocentesis with HA.

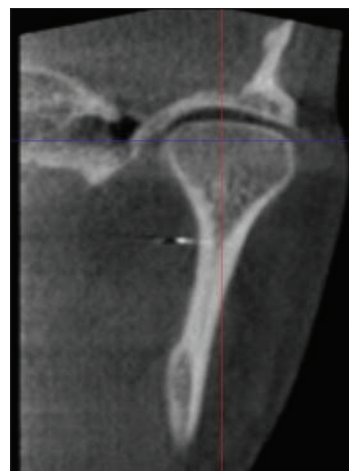

Figure 14: Group B postoperative cone-beam computed tomography

Table 2: Pain according to severity

PAIN (VAS) scale	No. of patients						
	Pre op	Day 1	Day 5	Day 7	4 th week	6 th Week	12 th week
Group A							
No pain to mild pain	0	1	1	1	6	7	10
Moderate pain	9	9	9	9	4	3	0
Severe pain	1	0	0	0	0	0	0
Worst pain	0	0	0	0	0	0	0
Group B							
No pain to mild pain	0	0	2	8	9	10	10
Moderate pain	8	9	8	2	1	0	0
Severe pain	2	1	0	0	0	0	0
Worst pain	0	0	0	0	0	0	0

Table 3: Comparison of maximum mouth opening across time interval between groups

Time period	Mean ± SD		P
	Group A	Group B	
Pre-op	37.20 ± 2.09	35.80 ± 1.61	0.11
Day 1	36.40 ± 2.31	37.20 ± 1.54	0.37
Day 5	36.40 ± 2.71	38.70 ± 1.56	0.03*
Day 7	38.60 ± 2.41	40.30 ± 0.94	0.05
Week 4	40.20 ± 0.63	41.40 ± 0.96	0.004*
Week 6	41.00 ± 2.10	43.50 ± 1.58	0.008*
Week 12	42.50 ± 2.36	45.60 ± 1.83	0.004*

*P < 0.05 significant

Table 4: Comparison of lateral and protrusive movement across time interval between groups

	Group		P
	Group A N (%)	Group B N (%)	
Pre-op			
Painful	10 (100.0)	10 (100.0)	NA
Painless	0 (0.0)	0 (0.0)	
Day 1			
Painful	10 (100.0)	10 (100.0)	NA
Painless	0 (0.0)	0 (0.0)	
Day 5			
Painful	10 (100.0)	10 (100.0)	NA
Painless	0 (0.0)	0 (0.0)	
Day 7			
Painful	10 (100.0)	6 (60.0)	0.02*
Painless	0 (0.0)	4 (40.0)	
Week 4			
Painful	7 (70.0)	2 (20.0)	0.02*
Painless	3 (30.0)	8 (80.0)	
Week 6			
Painful	1 (10.0)	0 (0.0)	0.30
Painless	9 (90.0)	10 (100.0)	
Week 12			
Painful	2 (20.0)	0 (0.0)	0.13
Painless	8 (80.0)	10 (100.0)	

*P < 0.05 significant

All patients subjectively had moderate to severe pain preoperatively. There was significant difference in the

Table 5: Comparison of interleukin 6 (pg/ml) in lavage fluid between groups

	Mean ± SD		P
	Group A	Group B	
Immediate post-op	35.14 ± 5.95	35.81 ± 7.30	0.82
3 months	26.09 ± 7.30	24.03 ± 11.56	0.62
P	0.0001*	0.0001*	

*P < 0.05 significant

Table 6: Comparison of TNF alpha (pg/ml) in lavage fluid between group

	Mean ± SD		P
	Group A	Group B	
Immediate post-op	30.60 ± 9.01	21.43 ± 8.56	0.03*
3 months	26.66 ± 8.02	13.34 ± 4.60	0.0001*
P	0.0001*	0.0001*	

*P < 0.05 significant

pain between the groups at day 1 (P = 0.04), day 5 (P = 0.03), day 7 (P = 0.003), week 6 (P = 0.004), and week 12 (P = 0.007) [Table 1]. Reduction in pain was more in Group B than Group A. In Group A, nine patients reported with moderate pain, and one patient reported with severe pain preoperatively. During postoperative follow-up, pain progressively decreased. All patients had no to mild pain at the end of 4th week follow period. In Group B, two patients reported with severe pain and eight patients reported with moderate pain preoperatively. By 6th week, all patients had no to mild pain, i.e., pain significantly decreased by 4th week [Table 2].

Alpaslan and Alpaslan 2001 compared the efficacy of TMJ arthrocentesis with and without injection of sodium hyaluronate in the treatment of internal derangement (ID) of TMJ. Patients were randomly divided into two groups. One group received arthrocentesis with sodium hyaluronate and another group received arthrocentesis only. They reported a significant reduction in TMJ pain after 24 months in both groups, but the sodium hyaluronate was superior to arthrocentesis alone.

Manfredini *et al.* 2009^[13] also reported a significant decrease in pain score following arthrocentesis plus HA injection and attributed this improvement in pain to synergistic effect of arthrocentesis (washing joint) before each HA infiltration. The pain reduction is attributed to the high-pressure irrigation which washes away inflammatory mediators and providing pain relief.

Mouth opening was observed to be increased across the period in both groups; however, the mouth opening was significantly higher in Group B than in Group A at day 5 ($P = 0.03$), week 4 ($P = 0.004$), week 6 ($P = 0.008$), and week 12 ($P = 0.004$) [Table 3, Figures 6 and 7].

This finding is consistent with the findings in a study by Manfredini *et al.* 2009,^[13] who reported a significant increase in mouth opening after arthrocentesis plus HA injection. Yeung *et al.*, 2006^[14] in their study reported a significant increase in MMO after HA injection and attributed this improvement to reduction of the frictional coefficient in TMJ. In our study, there was no significant difference in MMO between preoperative and 7th day postoperative follow-up; however, significant difference was observed in MMO between preoperative and 4th week postoperative follow-up in both groups with Group B showing more MMO than Group A. This finding can be attributed to fact that HA possesses viscoelastic and analgesic properties. Arthrocentesis under sufficient pressure can also remove adhesions, widen the joint spaces, and improve mouth opening.^[15]

In this study, the lateral and protrusive movement was found to be painless in all patients in Group B, and 80% patients in Group A had pain-free lateral and protrusive movement by 12th week postoperatively [Table 4]. There was a significant difference in lateral and protrusive movement between the groups at day 7 and 4th week. At 4th week, 80% of patients in Group B had pain-free TMJ, but only 30% patients in Group A had pain-free TMJ. In the study by Alpaslan and Alpaslan 2001,^[11] it was found that lateral movement improved in both groups, i.e., in group receiving arthrocentesis only and in group receiving arthrocentesis plus HA. However, this improvement was significant only in group who received arthrocentesis plus HA injection. HA maintains lubrication and minimizes wear and tear mechanically or plays a role in nutrition of the avascular parts of disc and condylar cartilage.^[16]

In terms of clinically detectable clicking and crepitus sound, there was no significant difference in clicking among the groups at all the time intervals. However, clicking was absent in 50% and 70% of patients in Group A and Group B, respectively,

by the 12th weeks of follow-up. Yeung *et al.* 2006^[14] reported in their study that clicking sound significantly decreased from preinjection to 1 year after injection, but there was no significant change in joint crepitus. Alpaslan and Alpaslan 2001^[11] reported a significant decrease in clicking sound in patients who received arthrocentesis + HA injection, but no significant decrease was found in patients receiving arthrocentesis only.

In our study, IL-6 and TNF- α were estimated in lavage fluid preoperatively and postoperatively in both the groups.

The mean level of IL-6 in lavage fluid in Group A and Group B patients preoperatively was 35.14 ± 5.98 pg/ml and 35.81 ± 7.30 pg/ml, respectively. After 3 months of treatment, mean IL-6 level in lavage fluid of patients in Group A and Group B was 26.09 ± 7.30 and 24.03 ± 11.56 pg/ml, respectively, [Table 5]. A significant decrease in level of IL-6 was seen from preoperative to 3-month postoperative in both groups. There was no significant difference in IL-6 levels between the groups, but the decrease in IL6 level was higher in Group B than in Group A. It has been shown that IL-1, IL-6, IL-11, and TNF- α do not exist in healthy TMJs, and some biochemical agents in the synovial fluid play an important roles in ID of TMJs.^[17] Gulen *et al.* 2009^[18] studied the levels of proinflammatory mediators in TMJ synovial fluid before and after arthrocentesis and found significant decrease in levels of cytokines and IL-6 was totally cleared away when measured 2 weeks after arthrocentesis. In our study, the level of IL-6 was significantly decreased postoperatively but was not totally cleared away. Sezgin *et al.* 2005^[19] studied effects of HA injection on cytokines in knee OA. They observed that the IL-6 level decreased significantly in control and study group, but the decrease was more significant in group receiving HA injection (study group). In recent years, it has been reported that the cytokines associated with inflammatory reactions (IL-1 β , IL-2, IL-6, IL-8, TNF- α , interferon gamma, and leukocyte inhibition factor) increase in the synovium and that this increase may be an indicator of articular inflammation.^[20,21]

The mean level of TNF- α in lavage fluid in Group A and Group B patients preoperatively was 30.60 ± 9.01 pg/ml and 21.43 ± 8.56 pg/ml, respectively [Table 6]. After 3 months of treatment, mean TNF- α level in lavage fluid of patients in Group A and Group B was 26.66 ± 8.02 pg/ml and 13.34 ± 4.60 pg/ml, respectively. A significant decrease was observed in levels of TNF- α from preoperative to 3 months postoperative in both Group A ($P = 0.0001$) and Group B ($P = 0.0001$). This decrease was more significant in Group B than in Group A. Emshoff *et al.* 2000^[22] reported a significant intraoperative decrease in

levels of TNF- α after arthrocentesis. Gulen *et al.* 2009^[18] found a significant decrease in TNF- α levels after arthrocentesis but were still detectable in some patients. In our study also, we found a significant decrease in TNF- α level postoperatively but was still detectable. Takahashi *et al.* 1998^[17] reported that excessive production of IL-1, TNF α , and IL-6 in the synovial fluid may contribute to synovitis, and these cytokines were correlated with arthralgia of the TMJ. However, it may be said that palpation on tenderness and clinical picture is affected by TNF levels.^[23]

The present study has been used to compare the efficacy of arthrocentesis alone with arthrocentesis with sodium HA. This approach to treatment of TMDs is based on the recent observations indicating that an increase in joint friction coefficient is the main risk factor for degenerative joint pathologies.^[24] Being an essential component of joint lubrication, HA has a role in reducing joint friction.^[12,25] The treatment protocol of 5 cycles of HA injection with arthrocentesis is based on the positive finding described with same approach in other joints. Studies on patients with OA of knee joint has shown significant improvement in patient's symptoms and also showed that 5 cycle injection protocol is most effective to maintain improvement over time.^[26,27]

In the present study, clinical parameters such as pain, MMO, lateral and protrusive movement of jaws, and improved significantly in both the treatment protocol (arthrocentesis alone and arthrocentesis with HA). However, more significant improvement in pain, MMO, lateral and protrusive movement was observed in patients receiving arthrocentesis with HA protocol. The cytokines (IL-6 and TNF- α) in lavage fluid reduced significantly after treatment, and this reduction in cytokine level was more in patients receiving arthrocentesis with HA.

Radiological assessment preoperatively and postoperative 3 months with CBCT did not show any significant difference from preoperative to postoperative period. Although erosion on condyles disappeared in few patients in both groups, it was insignificant. This can be attributed to the fact that follow-up period of 3 months was insufficient to show radiological remodeling of condyles and glenoid fossa. Li *et al.* 2015^[28] studied OA changes (of TMJ) in CBCT in patients who received HA injection in superior joint and reported cortical bone formation and remodeling of severe degenerative changes by 9 months follow-up. Partial new bone formation was seen in some patients at 3 months.

This improvement in clinical outcomes after arthrocentesis can be attributed to the facts that the flow of liquid under

pressure in joint causes flushing of catabolites, distension of joint with breakage of adhesions, and mobilization of disc.^[29] Apart from providing viscosupplementation to joints, HA has anti-inflammatory effects. Reduced cytokine level in lavage fluid can be attributed to anti-inflammatory effect of HA combined with lavage. IL-1 β is the key mediator in anti-inflammatory effects of HA and is regulated through HA-CD44 binding.^[30] IL-1 β suppression results in downregulation of matrix metalloproteinases which also aids in anti-inflammatory effects of HA^[31] and further suppression of pro-inflammatory mediators IL-8, IL-6, prostaglandin E2, and TNF- α provides anti-inflammatory effects of intra-articular HA treatment.^[32,33]

Very few complications were reported related to the procedure in our study. Four patients suffered transient facial paresis after local anesthetics, but no patients were eliminated from the study. No complications/adverse reactions were reported related to intra-IA-HA.

CONCLUSION

The combination of arthrocentesis with HA injection showed much better outcome than arthrocentesis alone. It can be concluded that HA injection combined with arthrocentesis is effective protocol in relieving symptoms in inflammatory degenerative diseases of TMJs. However, long-term follow-ups with larger patient number are required to evaluate the effect of arthrocentesis alone and arthrocentesis with HA.

Declaration of patient consent

The authors certify that they have obtained all appropriate patient consent forms. In the form the patient(s) has/have given his/her/their consent for his/her/their images and other clinical information to be reported in the journal. The patients understand that their names and initials will not be published and due efforts will be made to conceal their identity, but anonymity cannot be guaranteed.

Financial support and sponsorship

Nil.

Conflicts of interest

There are no conflicts of interest.

REFERENCES

1. Dworkin SF, LeResche L. Research diagnostic criteria for temporomandibular disorders: Review, criteria, examinations and specifications, critique. *J Craniomandib Disord* 1992;6:301-55.
2. Schiffman E, Ohrbach R, Truelove E, Look J, Anderson G, Goulet JP, *et al.* Diagnostic criteria for temporomandibular disorders (DC/TMD) for

- clinical and research applications: Recommendations of the international RDC/TMD consortium network* and orofacial pain special interest group†. *J Oral Facial Pain Headache* 2014;28:6-27.
3. Gadek A, Miskowicz K, Wordliczek J, Liszka H. Effectiveness and safety of intra-articular use of hyaluronic acid (Suplasyn) in the treatment of knee osteoarthritis. *Przegl Lek* 2011;68:307-10.
 4. Khalaj N, Abu Osman NA, Mokhtar AH, George J, Abas WA. Effect of intra-articular hyaluronic injection on postural stability and risk of fall in patients with bilateral knee osteoarthritis. *ScientificWorldJournal* 2014;2014:815184.
 5. Brusie RW, Sullins KE, White NA 2nd, Coffin PC, Parker GA, Anver MR, *et al.* Evaluation of sodium hyaluronate therapy in induced septic arthritis in the horse. *Equine Vet J Suppl* 1992;(11):18-23.
 6. Kopp S, Wenneberg B, Haraldson T, Carlsson GE. The short-term effect of intra-articular injections of sodium hyaluronate and corticosteroid on temporomandibular joint pain and dysfunction. *J Oral Maxillofac Surg* 1985;43:429-35.
 7. Moreland LW. Intra-articular hyaluronan (hyaluronic acid) and hylans for the treatment of osteoarthritis: Mechanisms of action. *Arthritis Res Ther* 2003;5:54-67.
 8. Yura S, Totsuka Y. Relationship between effectiveness of arthrocentesis under sufficient pressure and conditions of the temporomandibular joint. *J Oral Maxillofac Surg* 2005;63:225-8.
 9. Altman RD. Intra-articular sodium hyaluronate in osteoarthritis of the knee. *Semin Arthritis Rheum* 2000;30 2 Suppl 1:11-8.
 10. Barbucci R, Lamponi S, Borzacchiello A, Ambrosio L, Fini M, Torricelli P, *et al.* Hyaluronic acid hydrogel in the treatment of osteoarthritis. *Biomaterials* 2002;23:4503-13.
 11. Alpaslan GH, Alpaslan C. Efficacy of temporomandibular joint arthrocentesis with and without injection of sodium hyaluronate in treatment of internal derangements. *J Oral Maxillofac Surg* 2001;59:613-8.
 12. Cascone P, Fonzi Dagger L, Aboh IV. Hyaluronic acid's biomechanical stabilization function in the temporomandibular joint. *J Craniofac Surg* 2002;13:751-4.
 13. Manfredini D, Bonnini S, Arboretti R, Guarda-Nardini L. Temporomandibular joint osteoarthritis: An open label trial of 76 patients treated with arthrocentesis plus hyaluronic acid injections. *Int J Oral Maxillofac Surg* 2009;38:827-34.
 14. Yeung RW, Chow RL, Samman N, Chiu K. Short-term therapeutic outcome of intra-articular high molecular weight hyaluronic acid injection for nonreducing disc displacement of the temporomandibular joint. *Oral Surg Oral Med Oral Pathol Oral Radiol Endod* 2006;102:453-61.
 15. Dolwick MF. The role of temporomandibular joint surgery in the treatment of patients with internal derangement. *Oral Surg Oral Med Oral Pathol Oral Radiol Endod* 1997;83:150-5.
 16. Neo H, Ishimaru JI, Kurita K, Goss AN. The effect of hyaluronic acid on experimental temporomandibular joint osteoarthrosis in the sheep. *J Oral Maxillofac Surg* 1997;55:1114-9.
 17. Takahashi T, Kondoh T, Fukuda M, Yamazaki Y, Toyosaki T, Suzuki R. Proinflammatory cytokines detectable in synovial fluids from patients with temporomandibular disorders. *Oral Surg Oral Med Oral Pathol Oral Radiol Endod* 1998;85:135-41.
 18. Gulen H, Ataoglu H, Haliloglu S, Isik K. Proinflammatory cytokines in temporomandibular joint synovial fluid before and after arthrocentesis. *Oral Surg Oral Med Oral Pathol Oral Radiol Endod* 2009;107:e1-4.
 19. Sezgin M, Demirel AC, Karaca C, Ortancil O, Ulkar GB, Kanik A, *et al.* Does hyaluronan affect inflammatory cytokines in knee osteoarthritis? *Rheumatol Int* 2005;25:264-9.
 20. Bertazzolo N, Punzi L, Stefani MP, Cesaro G, Pianon M, Finco B, *et al.* Interrelationships between interleukin (IL)-1, IL-6 and IL-8 in synovial fluid of various arthropathies. *Agents Actions* 1994;41:90-2.
 21. Nishimura M, Segami N, Kaneyama K, Suzuki T, Miyamaru M. Proinflammatory cytokines and arthroscopic findings of patients with internal derangement and osteoarthritis of the temporomandibular joint. *Br J Oral Maxillofac Surg* 2002;40:68-71.
 22. Emshoff R, Puffer P, Strobl H, Gassner R. Effect of temporomandibular joint arthrocentesis on synovial fluid mediator level of tumor necrosis factor-alpha: Implications for treatment outcome. *Int J Oral Maxillofac Surg* 2000;29:176-82.
 23. Shafer DM, Assael L, White LB, Rossomando EF. Tumor necrosis factor-alpha as a biochemical marker of pain and outcome in temporomandibular joints with internal derangements. *J Oral Maxillofac Surg* 1994;52:786-91.
 24. Nitzan DW, Kreiner B, Zeltser R. TMJ lubrication system: Its effect on the joint function, dysfunction, and treatment approach. *Compend Contin Educ Dent* 2004;25:437-8, 440, 443-4.
 25. Tanaka E, Iwabe T, Dalla-Bona DA, Kawai N, van Eijden T, Tanaka M, *et al.* The effect of experimental cartilage damage and impairment and restoration of synovial lubrication on friction in the temporomandibular joint. *J Orofac Pain* 2005;19:331-6.
 26. Altman RD, Moskowitz R. Intraarticular sodium hyaluronate (Hyalgan) in the treatment of patients with osteoarthritis of the knee: A randomized clinical trial. Hyalgan Study Group. *J Rheumatol* 1998;25:2203-12.
 27. Axe MJ, Shields CL Jr. Potential applications of hyaluronans in orthopaedics: Degenerative joint disease, surgical recovery, trauma and sports injuries. *Sports Med* 2005;35:853-64.
 28. Li C, Long X, Deng M, Li J, Cai H, Meng Q. Osteoarthritic changes after superior and inferior joint space injection of hyaluronic acid for the treatment of temporomandibular joint osteoarthritis with anterior disc displacement without reduction: A cone-beam computed tomographic evaluation. *J Oral Maxillofac Surg* 2015;73:232-44.
 29. Emshoff R, Rudisch A. Temporomandibular joint internal derangement and osteoarthrosis: Are effusion and bone marrow edema prognostic indicators for arthrocentesis and hydraulic distention? *J Oral Maxillofac Surg* 2007;65:66-73.
 30. Waddell DD, Kolomytkin OV, Dunn S, Marino AA. Hyaluronan suppresses IL-1beta-induced metalloproteinase activity from synovial tissue. *Clin Orthop Relat Res* 2007;465:241-8.
 31. Sasaki A, Sasaki K, Kontinen YT, Santavirta S, Takahara M, Takei H, *et al.* Hyaluronate inhibits the interleukin-1beta-induced expression of matrix metalloproteinase (MMP)-1 and MMP-3 in human synovial cells. *Tohoku J Exp Med* 2004;204:99-107.
 32. Lajeunesse D, Delalandre A, Martel-Pelletier J, Pelletier JP. Hyaluronic acid reverses the abnormal synthetic activity of human osteoarthritic subchondral bone osteoblasts. *Bone* 2003;33:703-10.
 33. Chang CC, Hsieh MS, Liao ST, Chen YH, Cheng CW, Huang PT, *et al.* Hyaluronan regulates PPARγ and inflammatory responses in IL-1β-stimulated human chondrosarcoma cells, a model for osteoarthritis. *Carbohydr Polym* 2012;90:1168-75.