

# Spontaneous Rupture of Uterine Vessels in the Third Trimester of Pregnancy Resulting in Severe Hemoperitoneum and Fetal Death: A Case Report and Literature Review

Kidus Kebede Abadi <sup>1</sup>, Abdikani Hassan Jama <sup>1</sup>, Hezron Adinew Addi<sup>2</sup>, Awol Yemane Legesse <sup>3</sup>, Akebom Kidanemariam Gebremichael <sup>4</sup>

<sup>1</sup>Daruxannan General Hospital, Burao, Somaliland, Somalia; <sup>2</sup>Burao Imaging Center, Burao, Somaliland, Somalia; <sup>3</sup>Department of Obstetrics and Gynecology, Mekelle University, Mekelle, Tigray, Ethiopia; <sup>4</sup>Saint Peter's Specialised Hospital, Addis Ababa, Ethiopia

Correspondence: Kidus Kebede Abadi, Email [Kiduskebedetox@gmail.com](mailto:Kiduskebedetox@gmail.com)

**Abstract:** Spontaneous hemoperitoneum during pregnancy, caused by rupture of uterine vessels, is a rare and dangerous complication that can lead to maternal and foetal death. We presented a case of a 25-year-old primigravid woman with severe abdominal pain, distension, and hemodynamic instability at 33 weeks of gestation. An ultrasound and computed tomography scan of the abdomen and pelvis revealed intraperitoneal fluid collection with a non-viable intrauterine pregnancy. Following this, we did an emergency exploratory laparotomy with suturing the ruptured uterine vessel and delivered a freshly dead fetus. This case highlighted the rare occurrence of spontaneous hemoperitoneum due to rupture of the uterine vessel during pregnancy and the need for urgent intervention to avoid complications.

**Keywords:** spontaneous hemoperitoneum, uterine vessel rupture, pregnancy

## Introduction

Spontaneous hemoperitoneum during pregnancy is a rare complication, with significantly high maternal and perinatal mortality rates.<sup>1</sup> The incidence in developing countries is not well known. However, from studies done in Italy and Netherlands, the incidence ranges from 0.004 in 1000 births to 4.9 in 100,000 births, respectively.<sup>2,3</sup> The differential diagnosis includes rupture of utero-ovarian vessels and solid organs, including the spleen and liver.<sup>4</sup> It occurs most often after the second half of pregnancy and its presentation is sometimes vague. However, common manifestations include abdominal pain and distension associated with derangement of vital signs, anaemia, and signs of fluid accumulation in the peritoneum.<sup>5</sup> In addition to the clinical findings, investigation like complete blood count and abdomino-pelvic imaging using ultrasound and computerised tomography are essential to reach into diagnosis.

Commonly identified risk factors include endometriosis, multiple pregnancies, advanced age, artificial reproductive technology, and connective tissue disorders.<sup>2,6,7</sup> Although perinatal complications remain high, thorough assessment and a high suspicion index, with adequate replacement of fluid and appropriate emergency surgical interventions, help to decrease maternal complications and mortality.<sup>3</sup>

Herein, we highlight the importance of early diagnosis and intervention in a rare case of spontaneous hemoperitoneum during the third trimester of pregnancy due to rupture of uterine vessels.

## Case Report

A 25-year-old Somalian, primigravid lady at 33 weeks of gestation presented to the emergency department at Daruxannan hospital with complaints of acute abdominal pain and abdominal distention for 16 hours. In addition,

she experienced four episodes of non-projectile vomiting and light headedness. She denied abdominal trauma or a chronic personal or family history of medical illness. Upon admission, she was haemodynamically unstable, with a blood pressure of 90/60 mmHg, pulse rate of 110 beats per minute, respiratory rate of 20 breaths per minute, and axillary temperature of 36.5°C. Her oxygen saturation (spO<sub>2</sub>) was 97%, and Glasgow coma scale of 15/15. Abdominal examination revealed a distended abdomen with significant direct and rebound tenderness, and absent foetal heartbeat. Laboratory investigations revealed elevated white blood cell count with 80% granulocyte count, and a slightly reduced haemoglobin level. Urine analysis also revealed +2 ketones, and +1 proteinuria (Table 1).

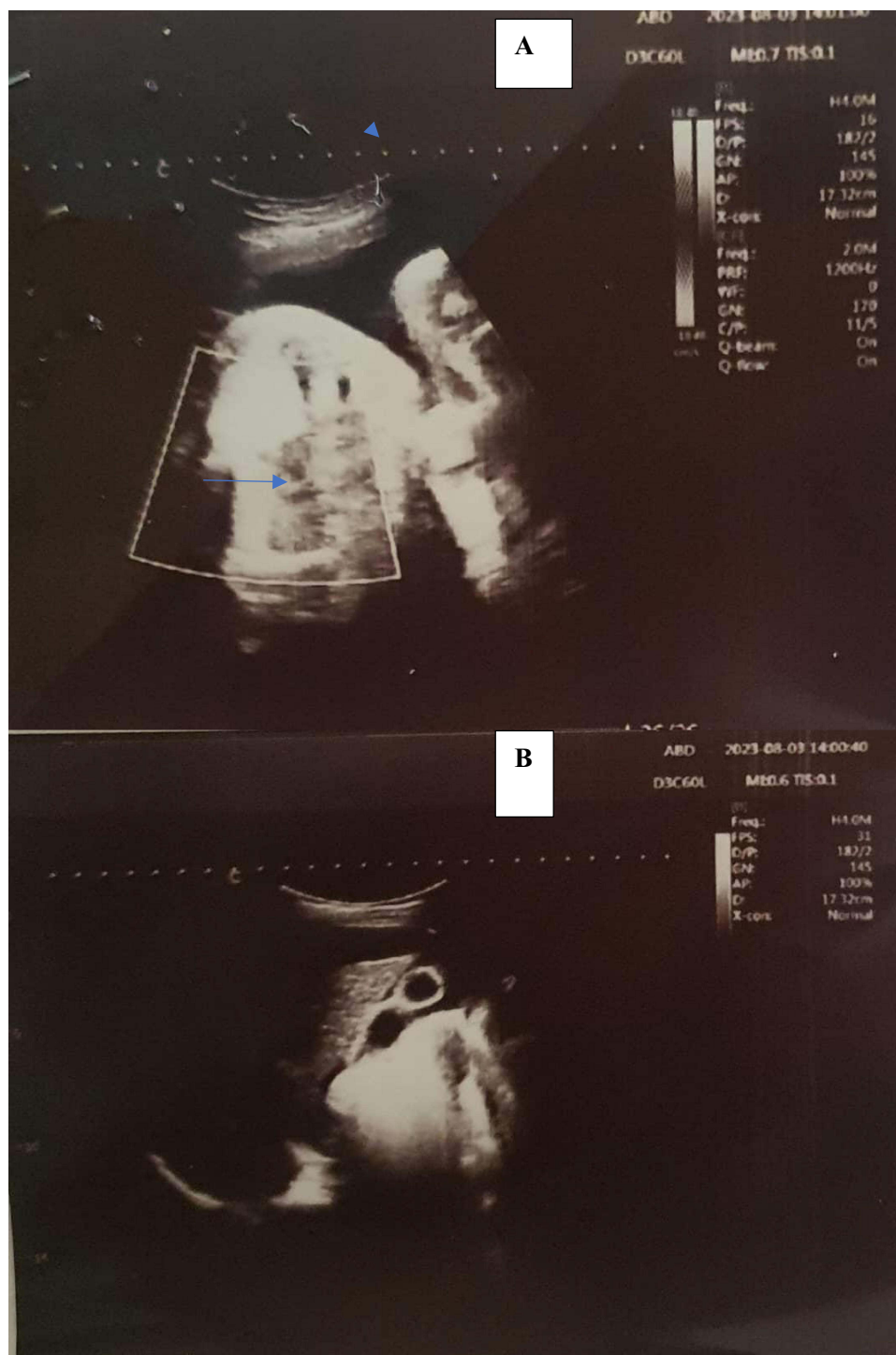After securing initial resuscitative measures with two litres of intravenous normal saline and providing anti-pain, patient was directed for abdominal imaging. Abdominopelvic and obstetric ultrasound showed a singleton non-viable intrauterine pregnancy with a gestational age of 33 weeks and an estimated foetal weight of 2200 gram. Free fluid with echo debris was observed in the peritoneal cavity, including the culde sac, paracolic gutter, and the hepatorenal recess (Figure 1). Otherwise, the solid intra-abdominal organs and the bowel loops were unremarkable.

Since the ultrasound finding was inconclusive, the patient was subjected to cross-sectional tomography. Abdominopelvic Contrast-enhanced Computed tomography scan showed significant free fluid in the peritoneal cavity with an average density of 33 HU, uninterrupted uterine wall enhancement, and a well-formed foetus without contrast in the vascular system, indicating non-viability of the foetus (Figure 2). The placenta was observed in the right lateral aspect of the uterus and showed a contrast bushing. No signs of inflammation or wall defects were observed in the bowel. All solid intra-abdominal organs were found to be normal.

The patient was diagnosed with spontaneous hemoperitoneum of indeterminate origin. The differential diagnoses considered were ruptured solid intraperitoneal organs and possible hollow organ perforations. Cross-matched fresh whole blood was transfused in addition to two liters of ringer lactate solution. Ampicillin 2 gram intravenous four times a day, Gentamicin 80 mg intravenous three times a day, and Metronidazole 500 mg intravenous three times a day were administered to the patient considering possibility of sepsis. Upon involving a General Surgeon, immediate surgical intervention and an emergency laparotomy were performed. A subumbilical midline abdominal incision was done. Upon entry, 2000 mL of hemoperitoneum was evacuated. A freshly dead foetus was delivered through an incision in the lower uterine segment. After delivery, the uterus was exteriorised, and active bleeding was detected in the ruptured left posterior uterine venous vessel (Figure 3). The ruptured uterine vein was carefully clamped and sutured with a delayed absorbable suture size 0 and round body needle. Bleeding vessels were sutured to ensure proper closure both above and below the bleeding sites. The uterine incision was closed in two layers. After inserting the uterus back and placing an intraperitoneal

**Table 1** Laboratory Investigations, a Case of Spontaneous Rupture of Uterine Venous Vessels in the Third Trimester of Pregnancy, Somalia, 2023

Lists of Investigation	Results	Reference Range
Haemoglobin	10.1g/dl	12–16 g/dl
White blood cells	30,900/ul	4000–10,000/ul
Platelet	351,000/ul	150,000–450,000/ul
Aspartate aminotransferase	30 U/L	0–42 U/L
Alanine aminotransferase	35 U/L	0–37.9 U/L
Creatinine	1.2 mg/dl	0.5–1/1 mg/dl
Blood urea nitrogen	40mg/dl	10–50 mg/dl
Urine Analysis	+proteinuria and +ketoneuria	Not available

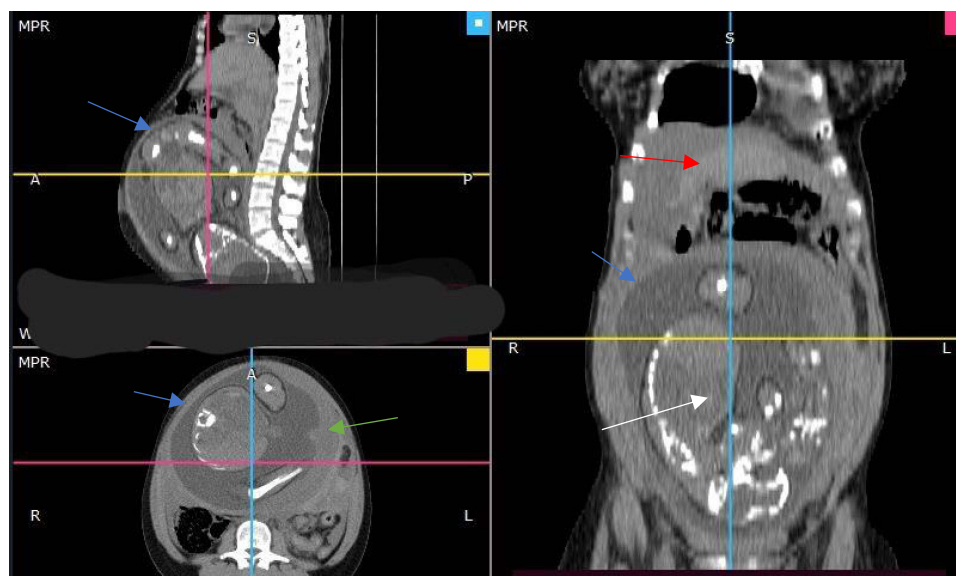


**Figure 1** Abdomino-pelvic ultrasound, 25 years old pregnant lady at 33 weeks gestation with spontaneous hemoperitoneum due to rupture of uterine vessels.

**Notes:** The image labeled (A) showing intrauterine pregnancy, blue arrow showing no colour flow on the fetal heart. The image labelled (B) showing right upper quadrant abdominal ultrasound, white arrow showing free fluid in the hepatorenal recess.

drain, the abdominal wall was closed layer-by-layer. Three units of cross-matched fresh whole blood were administered intraoperatively.

Post operatively, the patient continued intravenous antibiotics; maintenance fluid with Ringer lactate solution was continued; and she was strictly followed for vital sign, urine output, and abdominal conditions. Her haemoglobin on her second day of operation was 13grams/dl and her white blood cell count was 1500/ $\mu$ l with 75% granulocyte. Her



**Figure 2** Abdomino-pelvic contrast enhanced computerised tomography, 25 years old pregnant lady at 33 weeks gestation with spontaneous hemoperitoneum due to rupture of uterine vessels.

**Note:** CT multiplanar reconstruction image, blue arrow showing intact uterine outlines, white arrow showing intrauterine fetus, green arrow placenta attached to left uterine wall, and red arrow showing intraperitoneal fluid collection.

**Abbreviations:** R, right; L, left; S, sagittal.

recovery period was smooth. She was discharged after five days of in-hospital stay and her subsequent follow-ups were uneventful.

## Discussion

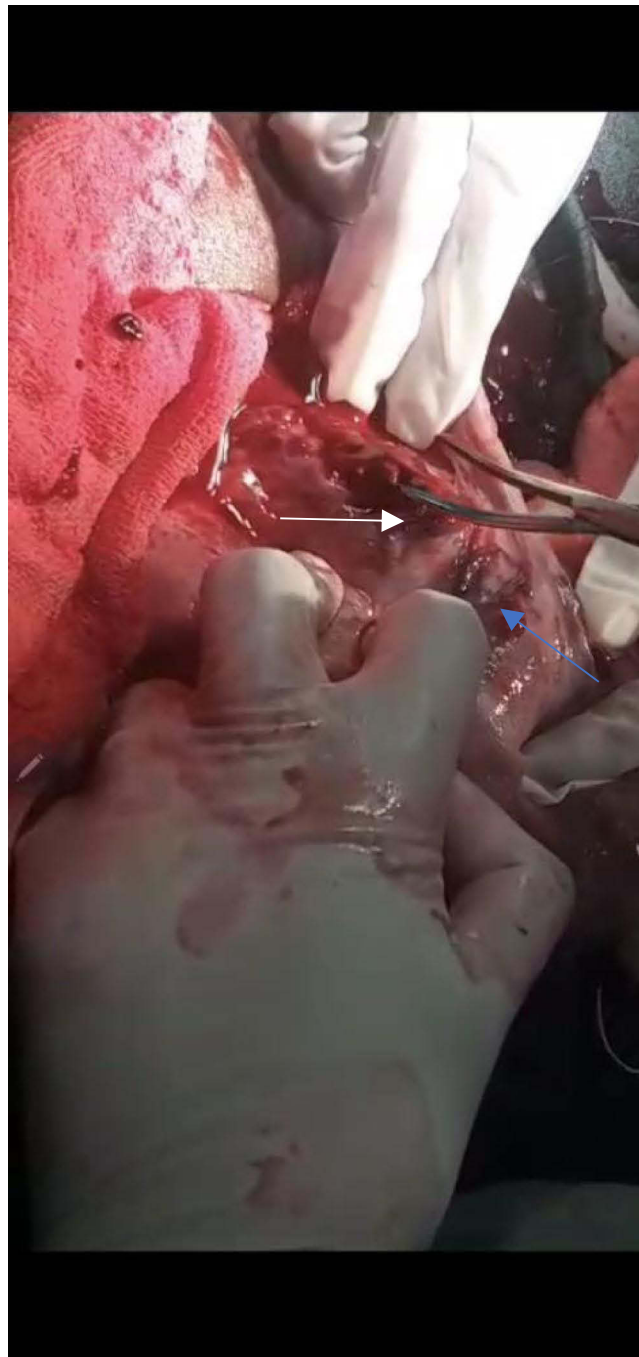Spontaneous hemoperitoneum in pregnancy due to rupture of uterine vessels is an unusual case that presents a risk of maternal and foetal death. Several reports have shown spontaneous rupture of the uterine vessels during pregnancy, particularly during the third trimester and puerperium.<sup>8–11</sup> Our case report also showed the appearance of this extremely unusual condition in the third trimester of pregnancy, with foetal death and life-threatening maternal complications.

Several risk factors for spontaneous rupture of uterine vessels have been identified during pregnancy, including endometriosis, artificial reproductive technology, connective tissue disease, and elevated venous pressure, especially during labour.<sup>2,6,7</sup> In our case, a significantly tortuous utero-ovarian venous plexus was identified, which may have contributed to this condition.

Typically, pregnant patients with spontaneous hemoperitoneum experience severe abdominal pain and signs of hypovolaemia. Similarly, our patient presented with abdominal pain associated with hemodynamic instability, evidence of intraabdominal fluid collection, and no obvious history of trauma or vaginal bleeding. Imaging, including abdominal ultrasound and contrast CT scan with contrast, is extremely important for detecting free fluid in the abdomen and ruling out potential causes, including uterine rupture, solid abdominal organ rupture, perforated viscous, and appendicitis.<sup>2–4,12</sup> However, owing to the vague patient presentations and rare occurrences, a high index of suspicion is particularly important for diagnosis.

Cases of spontaneous rupture of the uterine venous plexus with insidious onset and different clinical manifestations have been reported. A case report illustrated that a pregnant woman in her first pregnancy at 33 weeks of gestation presented with signs and symptoms of preterm labour and was treated with tocolytics, analgesics, and steroids for lung maturation. Despite extensive investigations, the cause of the patient's presentation remains unknown. However, during undergoing caesarean section, the patient had a spontaneous uterine venous plexus and ovarian rupture.<sup>10</sup> In contrast to the aforementioned case, our patient presented with acute and life-threatening complications in the mother and intrauterine foetal death. This contrasts with the stable hemodynamic condition and favourable foetal outcomes observed in other cases.

In a different case report, a 32-year-old mother in her third pregnancy at 16 weeks of gestation presented severe abdominal pain associated with hypovolemic shock after spontaneous rupture of the uterine vessels was diagnosed using abdominal imaging, and an immediate surgical intervention with ligation of the ruptured vessel was performed.<sup>13</sup> Although the presentation of the case was



**Figure 3** Intraoperative finding, 25 years old pregnant lady at 33 weeks gestation with spontaneous hemoperitoneum due to rupture of uterine vessels.  
**Note:** Intraoperative finding, white arrow showing the site of the ruptured uterine venous plexus and blue arrow showing left uterine cornua.

acute and similar to that of our case, the pregnancy was viable, occurred in the early second trimester of pregnancy, and was managed to reach term with a subsequent good foetal outcome. In our case, the foetus was nonviable, and delivery was performed during laparotomy. Most importantly, early detection and management are essential to optimise outcomes for both the mother and the foetus.

The clinical approach and treatment of acute abdominal syndrome during pregnancy pose diagnostic and management challenges. Prioritisation during evaluation should be performed to detect patients with a life-threatening cause of their symptoms and to identify those who require immediate surgical exploration. Most importantly, spontaneous hemoperitoneum cases during pregnancy, prompt diagnosis, and immediate replacement of intravascular volume with urgent surgical intervention are invaluable in reducing the high maternal and perinatal mortality associated with this rare

**Table 2** Literature Review of Case Reports of Spontaneous Rupture of Uterine Vessels in Pregnancy

Author, Year	Age	Parity	Mode of Conception	Number of Gestations	GA (Weeks)	Ruptured Vessel	Clinical Presentation	Diagnostic Modality	Surgical Intervention	Complications	Follow Up
Dogeret al, 2013 <sup>8</sup>	26	Nulliparous	IVF	Twin	32 weeks	Utero-ovarian vein	Abdominal pain	Clinical	Laparotomy, C/S, Uterine vein branch sutured	PTB	Un eventful
Andrés-Orós et al, 2010 <sup>9</sup>	30	Parous	Natural	Twin	33	Uterine vein	Abdominal pain	Clinical	Uterine Vein Sutured, C/S	IUFD	Un eventful
Ruan et al, 2023 <sup>10</sup>	24	Nulliparous	Natural	Singleton	33	Uterine venous combined with ovarian rupture	Lower abdominal pain	Abdominal Ultrasound and US guided abdominal Puncture, Exploratory Laparotomy	Exploratory Laparotomy, ligation of bleeding points, CS	PTB	Uneventful
Wanget al, 2021 <sup>11</sup>	32	Nulliparous	Natural	Singleton	Post partum	Left Uterine vein	Signs of shock, abdominal pain and tenderness	Abdominal Ultrasound, abdominal Puncture	Exploratory laparotomy, suturing of the ruptured vessel	DIC, Massive blood transfusion	Uneventful
Jayalath et al, 2021 <sup>13</sup>	32	Parous	Natural	Singleton	16 weeks	Uterine artery	Acute Abdominal pain, Signs of hypovolemia	Abdominal Ultrasound	Emergency Laparotomy, Suturing of ruptured artery	None	Her pregnancy was continued until 36 weeks
Hamedah et al, 2017 <sup>14</sup>	38	Parous	Natural	Singleton	38	Left utero-ovarian venous plexus	Abdominal pain	Clinical diagnosis	Exploratory laparotomy, ligation of bleeding vessels, caesarean section	None	Uneventful
Lim et al 2016. <sup>15</sup>	24	Parous	Natural	Singleton	37	Venous plexus in the posterior wall of the uterus	Lower abdominal pain	Clinical diagnosis and abdominal ultrasound	Exploratory laparotomy, ligation of bleeding vessels, caesarean section	None	

Williamson et al 2011 <sup>16</sup>	37	Parous	Natural	Singleton	Postpartum	Left uterine vein	Abdominal pain and Tenderness	Clinical diagnosis and CT scan of the pelvis	Spontaneous vaginal delivery and conservative management	None	Follow up MRI after 4 months showed severe endometriosis
Roche et al, 2009 <sup>17</sup>	32	Parous	IVF	Twin	33	Right uterine vessels	Acute abdominal pain and hypovolemic shock	Abdominal Ultrasound and exploratory laparotomy	Exploratory laparotomy and dissection of the uterus	None	Uneventful
Zhang et al, 2009 <sup>18</sup>	38	Parous	IVF	Twin	29	Uterine varix on the posterior surface of uterine wall	Acute abdominal pain, anaemia	CT scan and abdominal paracentesis	Exploratory laparotomy, ligation of bleeding vessels, caesarean section	IUFD	Uneventful
Zhang et al, 2009 <sup>18</sup>	35	Parous	IVF	Single	35	Right side uterine veins	Acute abdominal pain, and hypovolemic shock	Clinical diagnosis, Exploratory laparotomy	Exploratory laparotomy, ligation of bleeding vessels, caesarean section	Massive transfusion	Uneventful
Zhang et al, 2009 <sup>18</sup>	34	Parous	IVF	Single	30	Left corneal vein	Acute abdominal pain, and hypovolemic shock	Abdominal ultrasound and Exploratory laparotomy	Exploratory laparotomy, ligation of bleeding vessels, and caesarean section	Massive transfusion and neonatal asphyxia	Uneventful
<b>Our case</b>	25	Nulliparous	Natural	Singleton	33	Left posterior uterine venous plexus	Acute abdominal pain, and hypovolemic shock	Abdominal ultrasound, Computerized Tomography scan, and Exploratory laparotomy	Exploratory laparotomy, ligation of bleeding vessels, and caesarean section	Blood transfusion, IUFD	Uneventful

**Abbreviations:** IUFD, Intra Uterine Fetal Death; CT, Computerised Tomography; GA, Gestational Age; DIC, Disseminated intravascular Coagulation; PTB, Preterm Birth.

condition. Finally, addressing all potential causes and risk factors contributes to decreasing recurrence and optimising subsequent pregnancy outcomes (Table 2).

## Conclusion

Spontaneous rupture of the uterine vessels during pregnancy can lead to severe hemoperitoneum and foetal death. Usually, patients will present with sudden onset of abdominal pain, shock, and distended tender abdomen. A CT of the abdomen and pelvis can help in diagnoses. These cases require urgent surgical intervention to avoid complications. Ideally, exploratory laparotomy with suturing of ruptured uterine vessels should be done.

## Data Sharing Statement

Data important for case reports were included in the article, and additional sources of information were not needed.

## Ethical Consent

Written informed consent for the publication of the case and images obtained from the patient. Ethical approval was obtained from the Institutional Review Board of Burao University.

## Acknowledgment

We would like to especially thank all the teams involved in the management of the case and the patient for giving her consent to report her case scenario.

## Disclosure

The authors report no conflicts of interest in this work.

## References

- González Rosales R, Cerón Saldaña MA, Ayala Leal I, Cerda López JA. Rotura espontanea de los vasos uterinos durante el embarazo: comunicacion de un caso revision bibliografica [Uterine vessels spontaneous rupture during pregnancy: case report and literature review]. *Ginecol Obstet Mex.* 2008;76(4):221–223. Spanish.
- Mazzocco MI, Donati S, Maraschini A, et al. Spontaneous hemoperitoneum in pregnancy: Italian prospective population-based cohort study. *Acta Obstet Gynecol Scand.* 2022;101(11):1220–1226. doi:10.1111/aogs.14431
- Schreurs AMF, Overtoom EM, de Boer MA, et al. Spontaneous haemoperitoneum in pregnancy: nationwide surveillance and delphi audit system. *BJOG.* 2023. doi:10.1111/1471-0528.17556
- Yang L, Liu N, Long Y. Intra-abdominal hemorrhage during pregnancy: four case reports. *World J Clin Cases.* 2020;8(14):3074–3081. doi:10.12998/wjcc.v8.i14.3074
- Zilberman Sharon N, Shiber Y, Vaknin Z, Betser M, Copel L, Maymon R. Spontaneous hemoperitoneum in pregnancy and endometriosis: a new challenge in a known disease. *Obstet Gynecol Surv.* 2023;78(3):165–170. doi:10.1097/OGX.0000000000001107
- Lier MCI, Malik RF, Ket JCF, Lambalk CB, Brosens IA, Mijatovic V. Spontaneous hemoperitoneum in pregnancy (SHiP) and endometriosis — a systematic review of the recent literature. *Eur J Obstet Gynecol Reprod Biol.* 2017;219:57–65. doi:10.1016/j.ejogrb.2017.10.012
- Hirata T, Fujino S, Inoue T, Matsumoto Y, Hyodo H. Spontaneous hemoperitoneum in pregnancy after in vitro fertilization, associated with endometriosis. *J Obstet Gynaecol Canada.* 2022. doi:10.1016/j.jogc.2022.10.014
- Doger E, Cakiroglu Y, Yildirim Kopuk S, Akar B, Caliskan E, Yucesoy G. Spontaneous rupture of uterine vein in twin pregnancy. *Case Rep Obstet Gynecol.* 2013;2013:1–3. doi:10.1155/2013/596707
- Andrés-Orós MP, Server-de Castro L, Roy-Ramos V, Vela-Lete A. Rotura espontanea de variz uterine durante le gestacion. Descripcion de dos cases y revision bibliografica [Spontaneous uterine venous rupture during pregnancy. Description of two cases and bibliographical review]. *Ginecol Obstet Mex.* 2010;78(2):128–131. Spanish.
- Ruan J, Zhao G. Spontaneous uterine venous plexus complicated with ovarian rupture in the third trimester of pregnancy: a case report. *BMC Pregnancy Childbirth.* 2023;23(1):250. doi:10.1186/s12884-023-05556-y
- Wang HF, Rong SR, Zhang AH, Yang AL, Liang Q. Shock caused by spontaneous rupture uterine vessels during puerperal period: a case report and literature review. *Eur Rev Med Pharmacol Sci.* 2021;25(13):4451–4455. doi:10.26355/eurrev\_202107\_26235
- Mercier AM, Caldwell MG, Rabie NZ, Pagan M, Ramseyer AM, Magann EF. Spontaneous uterine vessel rupture during pregnancy or in the puerperium: a review of the literature. *Obstet Gynecol Surv.* 2022;77(4):227–233. doi:10.1097/OGX.0000000000001012
- Jayalath GKC, Pathiraja R, Jayarathna GVIGB. Case Report: severe hemoperitoneum due to spontaneous rupture of uterine vessels during the second trimester of pregnancy. *F1000Res.* 2021;10:568. doi:10.12688/f1000research.54139.2
- Hamadeh S, Addas B, Hamadeh N, Rahman J. Spontaneous intraperitoneal hemorrhage in the third trimester of pregnancy: clinical suspicion made the difference. *J Obstet Gynaecol Res.* 2018;44(1):161–164. doi:10.1111/jog.13479
- Lim PS, Ng SP, Shafiee MN, Kampan N, Jamil MA. Spontaneous rupture of uterine varicose veins: a rare cause for obstetric shock. *J Obstet Gynaecol Res.* 2014;40(6):1791–1794. doi:10.1111/jog.12402



16. Williamson H, Indusekhar R, Clark A, Hassan IM. Spontaneous severe haemoperitoneum in the third trimester leading to intrauterine death: case report. *Case Rep Obstet Gynecol*. 2011;2011:1–4. doi:10.1155/2011/173097
17. Roche M, Ibarrola M, Lamberto N, Larrañaga C, García MÁ. Spontaneous hemoperitoneum in a twin pregnancy complicated by endometriosis. *J Maternal Fetal Neonatal Med*. 2008;21(12):924–926. doi:10.1080/14767050802353572
18. Zhang Y, Zhao Y, Wei Y, Li R, Qiao J. Spontaneous rupture of subserous uterine veins during late pregnancy after in vitro fertilization. *Fertil Steril*. 2009;92(1):395.e13–395.e16. doi:10.1016/j.fertnstert.2009.03.096

### International Medical Case Reports Journal

Dovepress

### Publish your work in this journal

The International Medical Case Reports Journal is an international, peer-reviewed open-access journal publishing original case reports from all medical specialties. Previously unpublished medical posters are also accepted relating to any area of clinical or preclinical science. Submissions should not normally exceed 2,000 words or 4 published pages including figures, diagrams and references. The manuscript management system is completely online and includes a very quick and fair peer-review system, which is all easy to use. Visit <http://www.dovepress.com/testimonials.php> to read real quotes from published authors.

Submit your manuscript here: <https://www.dovepress.com/international-medical-case-reports-journal-journal>