



Reverse Total Shoulder Arthroplasty With Humeral Head Autograft Fixed Onto Glenoid for Treatment of Severe Glenoid Retroversion

Zaamin B. Hussain, B.A., Jonathan A. Godin, M.D., M.B.A., George Sanchez, B.S., Nicholas I. Kennedy, M.D., Mark E. Cinque, M.S., Márcio B. Ferrari, M.D., and CAPT Matthew T. Provencher, M.D., M.C., U.S.N.R.

Abstract: Advanced glenohumeral osteoarthritis can transform glenoid morphology and, in some cases, is found in association with severe glenoid retroversion. The associated glenoid retroversion leads to difficulty in fixation of the glenoid component in reverse total shoulder arthroplasty. In the context of extreme glenoid wear, structural grafts can be used to restore glenoid volume and version in order for the glenoid component of the reverse total shoulder arthroplasty to be more easily implanted. Nevertheless, literature regarding structural grafts remains limited, with optimal graft choice and technique still controversial at best. This article details our technique for humeral head autograft transplantation before reverse total shoulder arthroplasty in the context of extreme glenoid retroversion with advanced osteoarthritis.

Glenohumeral osteoarthritis is characterized by loss of articular cartilage, glenoid bone loss, and increased glenoid retroversion with posterior subluxation of the humeral head in advanced cases.^{1,2} Progression after asymmetrical posterior force distribution on the glenoid or shoulder dysplasia can lead to a transformation in glenoid morphology, as classified by Walch et al.,³ to a type C glenoid with retroversion greater than 25°. Arthroplasty is indicated in symptomatic patients who have debilitating pain and range-of-motion deficits, but in this setting the

procedure is technically challenging and characterized by higher rates of complications and revisions.⁴

Preoperative posterior glenoid erosion not only is a risk factor for glenoid loosening but also results in worse outcomes for function and pain.^{5,6} Current glenoid components are designed to rest on the subchondral bone of the glenoid with fixation points drilled and burred through the subchondral plate into the cancellous bone of the glenoid vault. However, excessive posterior retroversion and the associated glenoid bone loss make the remaining subchondral bone inadequate for support, rendering glenoid component fixation especially challenging.

Glenoid version correction must be balanced against preservation of glenoid bone stock.⁴ Lesser degrees of bone loss can be compensated for by changing the humeral component version, lowering the high side of the glenoid with asymmetrical reaming, or using an augmented glenoid component.⁷ These methods are inappropriate when severe glenoid wear and extreme retroversion presents; however, placement of structural grafts can be used to restore glenoid volume and version so that the glenoid component can be implanted. The literature surrounding structural grafts used in this context is currently limited, with the optimal graft choice remaining controversial. This article details our technique for humeral head autograft transplantation to restore glenoid volume and version, before reverse

From the Steadman Philippon Research Institute (Z.B.H., J.A.G., G.S., N.I.K., M.E.C., M.B.F., M.T.P.) and The Steadman Clinic (J.A.G., M.T.P.), Vail, Colorado, U.S.A.

The authors report the following potential conflict of interest or source of funding: M.T.P. receives support from Arthrex, JRF Ortho. Consultant. Patent numbers (issued) 9226743, 20150164498, 20150150594, 20110040339. Arthrex, SLACK. Publishing royalties. Full ICMJE author disclosure forms are available for this article online, as [supplementary material](#).

Received April 1, 2017; accepted June 26, 2017.

Address correspondence to CAPT Matthew T. Provencher, M.D., M.C., U.S.N.R., Steadman Philippon Research Institute, 181 W Meadow Dr, Ste 1000, Vail, CO 81657, U.S.A. E-mail: mprovencher@thesteadmanclinic.com

© 2017 by the Arthroscopy Association of North America. Published by Elsevier. This is an open access article under the CC BY-NC-ND license (<http://creativecommons.org/licenses/by-nc-nd/4.0/>).

2212-6287/17492

<http://dx.doi.org/10.1016/j.eats.2017.06.025>

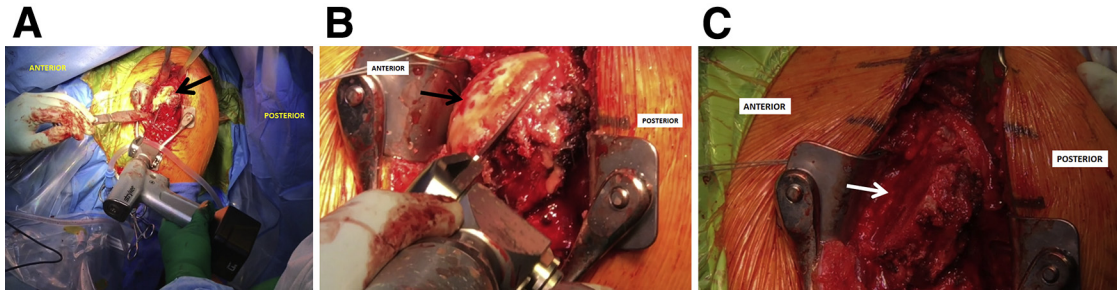


Fig 1. The left shoulder is externally rotated, and the humeral head (black arrows) is thoroughly exposed. By use of an electrocautery device, the position for the cut is marked at the proximal aspect of the humerus. After this, an oscillating saw is used (A, B) to cut the portion of the humeral head to be prepared into an autograft (C, white arrow).

total shoulder arthroplasty (rTSA), in the context of extreme glenoid retroversion.

Surgical Technique

[Video 1](#) provides an overview of the described surgical technique.

Patient Positioning and Anesthesia

The patient is placed in the supine position on the operating table, and general anesthesia is used for induction. Single-shot or catheter-infusion regional anesthesia may be used as well. The patient is then brought into the beach-chair position with care taken to pad all bony prominences. Moreover, the head and neck positioning should be carefully assessed before the procedure is started. We do not use an arm positioner; rather, the operative extremity is draped free with a well-padded Mayo stand placed under the elbow.

Objective Diagnosis

Preoperative evaluation should start with a thorough history and physical examination. Diagnostic imaging should consist of shoulder radiographs to assess for osseous abnormalities, including glenoid and humeral head bone loss. Magnetic resonance imaging of the shoulder allows confirmation of the extent of osteoarthritis, as well as any concomitant loose bodies or labral or other soft-tissue injuries. A computed tomography scan should be obtained to accurately assess glenoid version and bone loss. In this case example, the patient was noted to have approximately 38° of glenoid retroversion.

Operative Technique

General endotracheal anesthesia may be combined with regional nerve blocks to maximize postoperative pain control. Perioperative antibiotic prophylaxis is administered intravenously before incision. The procedure is begun with a standard deltopectoral approach. Subcutaneous flaps are created medially and laterally, and the cephalic vein is mobilized laterally. The clavicular fascia is incised proximally to the coracoid, and a Kolbel retractor is placed under the conjoined tendon

and deltoid for deep retraction. Throughout the procedure, the axillary and musculocutaneous nerves are protected with careful retraction. The anterior circumflex vessels are cauterized, and the shoulder is externally rotated. Next, the lateral border of the subscapularis tendon is identified just medial to the bicipital groove and tagged with a heavy nonabsorbable suture, and the subscapularis tendon is carefully dissected from the underlying capsule. The long head of the biceps tendon is identified within the bicipital groove, and a soft-tissue tenodesis is performed immediately proximal to the superior border of the pectoralis major tendon.

A glenohumeral capsular release is then performed anteriorly, inferiorly, and posteriorly with a Cobb elevator. Throughout the capsular release, the axillary nerve is palpated and protected at all times. The shoulder is externally rotated and extended to aid exposure of the humeral head. Electrocautery is used to mark a 135° humeral head cut, which is subsequently performed with an oscillating saw ([Fig 1](#)). It is important to note the rotation of the shoulder when performing the humeral head resection to avoid under- or over-resection. Thereafter, canal preparation is carried out. In this case, an 11-mm reamer and 11-mm broach

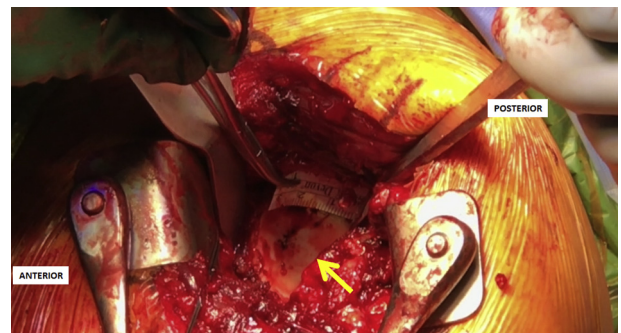


Fig 2. The glenoid (arrow) is exposed in the left shoulder, and the amount of retroversion is then evaluated. A ruler is used to measure the height, width, and depth of the glenoid, and these measurements are then compared with the preoperative imaging evaluation. These measurements will be used to achieve the correct size of the graft.

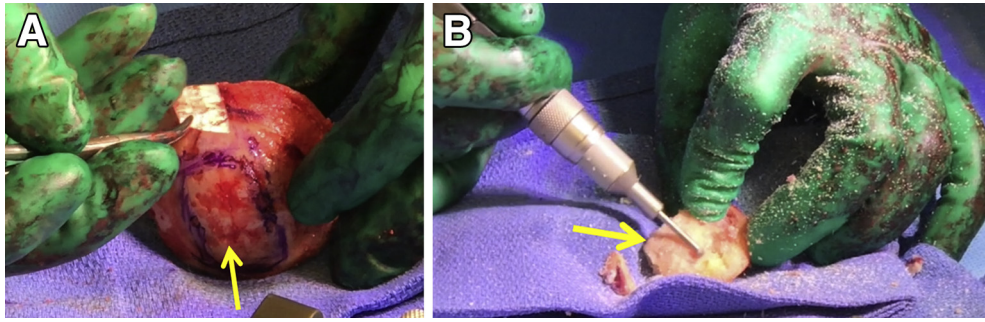


Fig 3. Once the measurements of the glenoid have been performed in the left shoulder, attention is turned to the preparation of the graft on the back table. (A) By use of a surgical pen and ruler, the humeral head autograft to be prepared is outlined (arrow). (B) A combination of a small oscillating saw and high-speed burr is used to achieve the desired size and shape of the graft (arrow).

(Arthrex, Naples, FL) were used. The humeral metaphysis is then reamed.

Next, attention is turned to glenoid preparation. Further anterior, inferior, and posterior capsular releases should be performed at this time. A ruler is used to measure the following: the height of the glenoid; the width of the glenoid superiorly, at the equator, and inferiorly; and the depth required to correct the retroversion (Fig 2). These measurements can be generated ahead of time with 3-dimensional computed tomography–based operative planning software, but intraoperative measurements should be carried out for confirmation. Thereafter, the humeral head is cut on the back table with a handheld sagittal saw and high-speed burr to the measured dimensions (Fig 3). Two 0.057 inch diameter Kirschner wires are drilled into the humeral head autograft to aid placement in the posterior glenoid (Fig 4). If preoperative planning affords the creation of a sterile 3-dimensionally printed template, the autograft may be placed on the template to assess fit at this time (Fig 5).

The posterior glenoid is prepared with a high-speed burr to establish a bleeding surface. The humeral head autograft is then positioned, and the K-wires are advanced into the native glenoid. A cannulated drill is placed over the K-wires, and headless compression screws (3.0-mm titanium headless compression screws; Arthrex) are used to fix the autograft in place, thereby restoring approximately 10° of retroversion (Fig 6). In this case, 3 headless compression screws were used, with care taken to avoid placement in the future position of the baseplate central peg or locking screws. The baseplate and glenosphere (Univers Revers; Arthrex) are then placed on top of the glenoid and humeral head autograft.

The humeral stem broach is removed. Three nonabsorbable sutures are then placed through 1.6-mm drill tunnels in the proximal humeral lesser tuberosity for later subscapularis repair. Trial

components and reduction are performed to assess stability and range of motion. Tension should be critically assessed to ensure there is no translation and the conjoined tendon and deltoid are under tension. There should also be no impingement at full adduction or full internal rotation, as well as no liftoff at 60° of external rotation and no shuck inferiorly. The final humeral stem, cup, spacer, and liner components (Univers Revers) are implanted.

The wound is thoroughly irrigated, and the subscapularis tendon is repaired with the shoulder in approximately 40° of external rotation. Hemostasis is obtained with electrocautery. The deltoid and pectoralis major muscle are repaired with a side-to-side closure using absorbable suture. The subcutaneous layer is repaired with No. 2-0 interrupted absorbable suture, and finally, a No. 3-0 suture is used for skin closure. The skin closure is supported by Steri-Strips (3M, St. Paul, MN). The advantages and disadvantages associated with the described technique are listed in Table 1, and pearls and pitfalls are shown in Table 2.



Fig 4. After preparation of the graft, two 0.057 K-wires (arrows) are drilled perpendicular to the humeral head autograft and parallel with one another. The wires will be used to provide transfer of the graft to the native glenoid in the left shoulder.

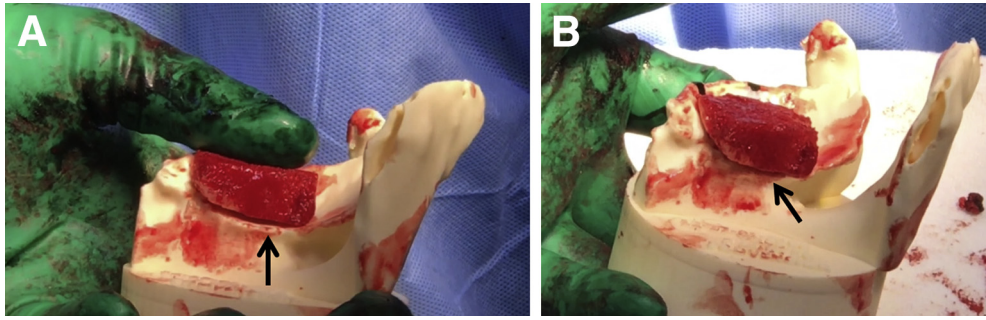


Fig 5. (A, B) If a sterile 3-dimensional model of the patient's glenoid is available, the graft (arrows) can be placed over the model to verify positioning and shape before fixation in the left shoulder. If adjustments to the graft that will be placed in the left shoulder are needed, they are performed at this time through use of a small oscillating saw and/or high-speed burr.

Postoperative Rehabilitation

The patient is placed in a sling for 3 weeks. Passive range of motion is begun immediately. Active and active-assisted range of motion is allowed 3 weeks after surgery. No resisted elbow flexion is permitted until 6 weeks postoperatively. A standard postoperative rehabilitation protocol for rTSA with progression to early-strengthening and full-strengthening exercises should be prescribed.

Discussion

This article details our technique for humeral head autograft transplantation to restore glenoid volume and version, preceding concomitant rTSA, in the context of extreme glenoid retroversion. This provides a biological option for patients with severe bone loss so that the glenoid component can be implanted (Fig 7). However, concerns with bone grafting have included nonunion, resorption, and subsidence, in addition to the technical demands of graft placement and fixation.⁴ The literature is limited regarding this type of procedure, and the optimal graft choice remains controversial.

Reverse total shoulder arthroplasty has been used less frequently alongside a bone graft. Mizuno et al.⁸ reviewed 27 rTSAs performed for the treatment of

primary glenohumeral osteoarthritis with a biconcave glenoid with functional rotator cuff. The mean preoperative retroversion was 32°, and humeral head subluxation rate was 87%. A bone graft was required in 10 patients: 6 from autogenous humeral head grafts and 4 from the iliac crest. Three of those from the iliac crest were performed in a 2-stage procedure. The Constant score increased from 31 to 76 points ($P < .0001$) at a mean follow-up of 54 months, with 93% of patients satisfied or very satisfied. The complication rate was 15%. The authors concluded that rTSA offers a viable solution for the treatment of severe static posterior glenohumeral instability and severe glenoid erosion.

Several other studies have reported the use of bone grafts with anatomic total shoulder arthroplasty. Neer and Morrison⁹ reviewed 19 patients at a mean follow-up of 52 months, with 16 patients having excellent results. Walch et al.⁶ reported on 75 patients with biconcave glenoids, with 7 patients requiring structural bone grafting because of the inability to correct retroversion to less than 10° while retaining enough glenoid volume for the placement of a keeled component. However, at a minimum follow-up of 2 years, they found that posterior bone grafting was associated with worse results with respect to active elevation, Constant score, mobility, and strength.

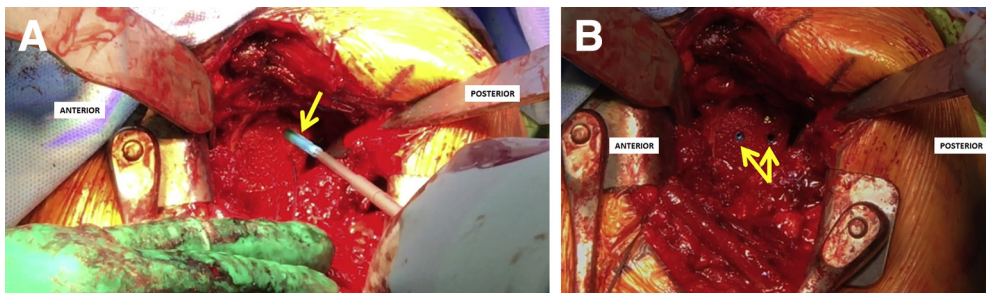


Fig 6. (A, B) The graft is transported into the native glenoid in the left shoulder. Once in the correct position, the K-wires are advanced into the native glenoid to provide provisional fixation and guide drilling. After this, 3.0-mm titanium headless compression screws (Arthrex; arrows) are used to definitively fix the autograft in place.

Table 1. Advantages and Disadvantages

Advantages	
The glenoid retroversion can be corrected without the need for allograft or donor-site morbidity.	
The measurements can be performed preoperatively, and a 3-dimensional model in the operating room ensures the correct size of the graft.	
Disadvantages	
The procedure is technically demanding.	
A 3-dimensional glenoid model adds cost to the procedure.	

Sabesan et al.¹⁰ reviewed the results of glenoid bone grafting in 12 patients who had preoperative retroversion greater than 20°, with a mean of 44°. The technique differed in that the bone graft was trapezoidal and was incorporated into a step-cut glenoid with posterior screw fixation. Of the patients, 2 had failure of graft incorporation at a mean of 4.4 years' follow-up and required revision surgery whereas 10 had excellent results.

As such, the clinical results of glenoid bone grafting are mixed and have been associated with a high percentage of complications including periprosthetic radiolucencies, glenoid component failure, graft complications, and instability.⁴ In addition, it is thought that rTSA may offer improved fixation and constraint over an anatomic prosthesis.⁴ The mixed results may be a result of the various grafting techniques, implants, and confounding patient variables. We recommend our described technique of humeral head autograft transplantation to restore glenoid volume and version, before rTSA, in the context of extreme glenoid retroversion, but we encourage further studies to assess outcomes after our surgical technique.

Table 2. Pearls and Pitfalls

Pearls	
Intraoperative measurements of the glenoid should be used for autograft preparation because preoperative measurements are more prone to error.	
The assistant must provide saline solution irrigation while preparing the graft to avoid thermal necrosis.	
Using a glenoid 3-dimensional model allows for a better understanding of optimal graft placement and reduces surgical time.	
Two K-wires should be used to transfer the graft into the native glenoid.	
Compression screws should be used to fix the graft into the native glenoid.	
Pitfalls	
A graft of the wrong size can jeopardize the procedure because it will not properly correct the severe glenoid retroversion.	
A fracture of the graft may occur if graft preparation is not performed carefully.	
A greater amount of surgical time is possible without the use of a glenoid 3-dimensional model.	

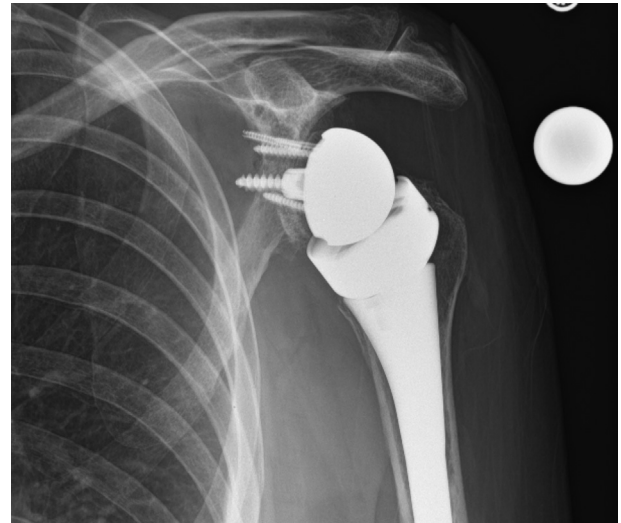

Fig 7. Anteroposterior postoperative radiograph of the left shoulder at 6 weeks after surgery showing appropriate healing and integration of the implant.

References

1. Neer CS II. Replacement arthroplasty for glenohumeral osteoarthritis. *J Bone Joint Surg Am* 1974;56:1-13.
2. Neer CS II, Watson KC, Stanton FJ. Recent experience in total shoulder replacement. *J Bone Joint Surg Am* 1982;64:319-337.
3. Walch G, Badet R, Boulahia A, Khoury A. Morphologic study of the glenoid in primary glenohumeral osteoarthritis. *J Arthroplasty* 1999;14:756-760.
4. Stephens SP, Paisley KC, Jeng J, Dutta AK, Wirth MA. Shoulder arthroplasty in the presence of posterior glenoid bone loss. *J Bone Joint Surg Am* 2015;97:251-259.
5. Iannotti JP, Norris TR. Influence of preoperative factors on outcome of shoulder arthroplasty for glenohumeral osteoarthritis. *J Bone Joint Surg Am* 2003;85:251-258.
6. Walch G, Moraga C, Young A, Castellanos-Rosas J. Results of anatomic nonconstrained prosthesis in primary osteoarthritis with biconcave glenoid. *J Shoulder Elbow Surg* 2012;21:1526-1533.
7. Nam D, Kepler CK, Neviasser AS, et al. Reverse total shoulder arthroplasty: Current concepts, results, and component wear analysis. *J Bone Joint Surg Am* 2010;92:23-35 (suppl 2).
8. Mizuno N, Denard PJ, Raiss P, Walch G. Reverse total shoulder arthroplasty for primary glenohumeral osteoarthritis in patients with a biconcave glenoid. *J Bone Joint Surg Am* 2013;95:1297-1304.
9. Neer CS II, Morrison DS. Glenoid bone-grafting in total shoulder arthroplasty. *J Bone Joint Surg Am* 1988;70:1154-1162.
10. Sabesan V, Callanan M, Ho J, Iannotti JP. Clinical and radiographic outcomes of total shoulder arthroplasty with bone graft for osteoarthritis with severe glenoid bone loss. *J Bone Joint Surg Am* 2013;95:1290-1296.