



Cryptococcal nasopharyngeal polypoid mass in a cat

Véronique Livet, Romain Javard, Kate Alexander, Christiane Girard and Marilyn Dunn

Journal of Feline Medicine and Surgery
Open Reports
 1–6

© The Author(s) 2015
 Reprints and permissions:
sagepub.co.uk/journalsPermissions.nav
 DOI: 10.1177/2055116915597238
jfmsopenreports.com



Abstract

Case summary An indoor 9-year-old castrated male domestic cat was referred with a 4 month history of increased upper airway noise. Computed tomography revealed a nasopharyngeal polypoid mass, which was removed endoscopically with basket forceps. Histopathology was compatible with a polypoid granulomatous pharyngitis with *Cryptococcus*-like organisms. This was supported by a positive serum latex cryptococcal antigen agglutination test (LCAT). Minimal inflammation of the nasal tissue was noted on histopathology, with no evidence of fungus. Following endoscopic removal of the mass, the patient was treated with systemic antifungal medication (itraconazole). One year after diagnosis, the LCAT titer was negative and the cat remained free of clinical signs.

Relevance and novel information This case report emphasizes the importance of considering *Cryptococcus* species as a potential etiology in cats presented with signs of nasopharyngeal obstruction with an isolated nasopharyngeal polypoid mass, even if kept indoors.

Accepted: 10 May 2015

Case description

An indoor 9-year-old castrated male domestic cat was referred to the Veterinary Teaching Hospital (University of Montreal) with a 4 month history of increased upper airway noise. A 2 week course of amoxicillin/clavulanic acid resulted in no clinical improvement and the cat was referred for computed tomography (CT) imaging and rhinoscopy.

On physical examination, there was no ocular or nasal discharge, or nasal deformity. The noise the owners reported was heard upon inspiration and originated from the nasal cavity or nasopharynx. The cat presented a breathing pattern compatible with inspiratory dyspnea with marked stertor. Ocular retropulsion and fundic examination were normal. Flow through nasal air columns was normal bilaterally and no polyp was seen on otoscopic or oral examination. A left parasternal grade II/VI holosystolic murmur was ausculted. Complete blood count and serum chemistry revealed a moderate eosinophilia (1600 cells/ μ l [range 100–790 cells/ μ l]) and hyperglycemia (16.08 mmol/l [range 3.95–8.84 mmol/l]). Fructosamine was measured and was normal (256 μ mol/l [range 240–420 μ mol/l]).

After induction of general anesthesia, a CT scan (16-slice helical; GE Lightspeed) of the nasal cavities, neck and chest revealed a well-defined homogeneous soft

tissue mass measuring 2.1 cm in length by 1 cm in width that occupied the entire nasopharynx (Figure 1), caudal to the nasal choanae. The caudal aspect of the mass extended to the most caudal aspect of the soft palate. Following administration of intravenous contrast medium (12 ml) (Iovue 300; ER Squibb), there was a mild enhancement of the contour, as well as heterogeneous uptake within the mass. A small amount of fluid was visible within the two compartments of the right tympanic bulla. A moderate amount of fluid was present inside the nasal cavities at their rostral and middle thirds. The presence of fluid was symmetrical between the two nasal cavities and was associated with a decrease of the normal contour, enhancement and number of the nasal turbinates. A small amount of fluid was also visible in the rostroventral aspect of left frontal sinus. Regional

Companion Animal Research Group, Department of Clinical Sciences, University of Montreal, Saint-Hyacinthe, QC, Canada

Corresponding author:

Véronique Livet DVM, Companion Animal Research Group, Department of Clinical Sciences, University of Montreal, Saint-Hyacinthe, QC J2S 7C6, Canada
 Email: veronique.livet25@gmail.com



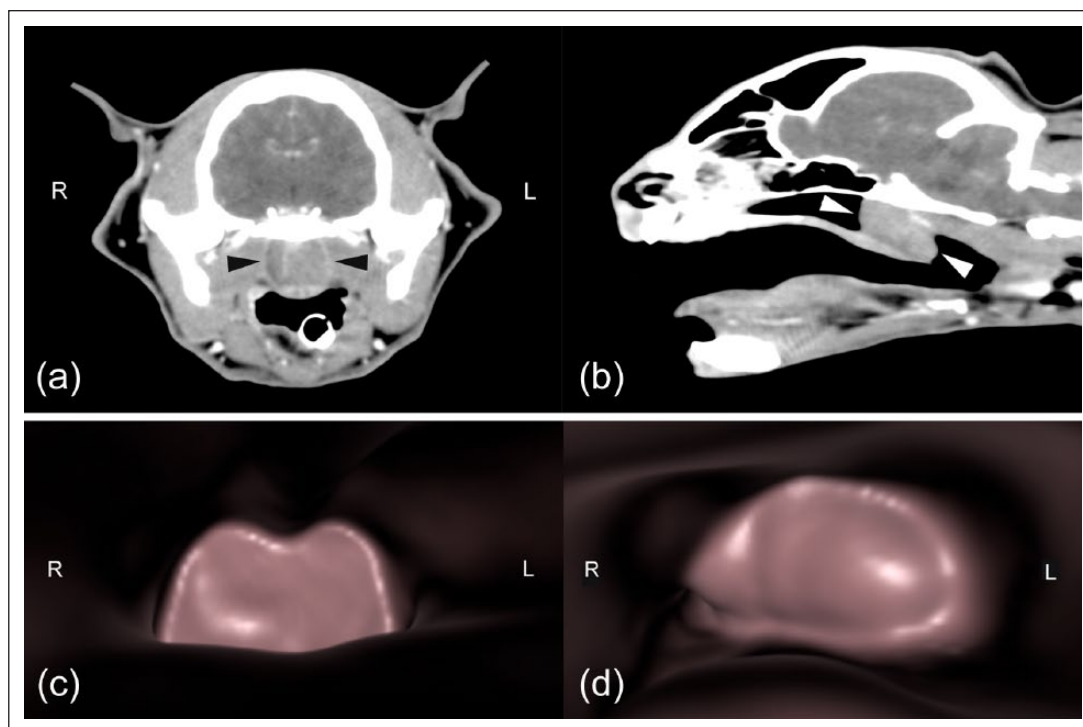


Figure 1 (a) Transverse postcontrast computed tomography (CT) image of the nasopharynx showing the rim-enhancing polypoid mass completely occupying the nasopharyngeal lumen (black arrowheads). (b) Sagittal reformatted postcontrast CT image showing the rim-enhancing polypoid mass completely occupying the nasopharyngeal lumen (white arrowheads). (c) Three-dimensional (3D) CT image in a rostrocaudal (antegrade) direction showing the polypoid mass. (d) 3D CT image in a caudorostral (retrograde) direction showing the polypoid mass protruding slightly beyond the caudal margin of the soft palate

lymph nodes were normal. Diagnosis following CT scan was a nasopharyngeal mass most compatible with a polyp and associated with mild right otitis media and bilateral chronic inflammatory rhinitis. CT scan of the thorax was normal.

Following identification of a nasopharyngeal mass on CT scan, nasopharyngoscopy was performed using a 3.5 mm flexible endoscope (Olympus BF-160 5.3 mm). A well-defined pedunculated smooth, shiny, yellow-brown nasopharyngeal mass was identified caudal to the nasal choanae. An elliptical retrieval basket forcep was introduced through the working channel of the scope in order to grasp the mass. The forceps were inserted through the channel prior to retroflexion of the scope into the nasopharynx. Upon inspection, the mass was determined to be attached by a stalk to the left aspect of the nasopharynx, dorsal to the soft palate, and its removal was possible by grasping it at the level of the peduncle. The macroscopic appearance of the mass was most compatible with a polyp (Figure 2). Severely inflamed nasal choanae were apparent after withdrawal of the mass. Bilateral rostral nasal biopsies were performed at the end of the procedure and immediately placed in neutral buffered formalin for histopathological analysis along with the mass.

Histopathology revealed that the mass was compatible with polypoid granulomatous pharyngitis. The polypoid mass was covered by a stratified squamous epithelium and was composed of a collagenous stroma severely infiltrated by macrophages associated with some clusters of neutrophils. Numerous round organisms with thick capsules ('bubble soap' appearance) measuring 10–30 μm in diameter were present in the cytoplasm of macrophages or free in the stroma and were compatible with fungi. Periodic acid–Schiff and Grocott's methenamine silver stains revealed the presence of bodies with a narrow budding, suggestive of *Cryptococcus* (Figure 3). Biopsies of the nasal turbinates revealed the presence of few neutrophils and eosinophils in the lumen of blood vessels and in the lamina propria without fungal elements in the tissues examined. A serum latex cryptococcal antigen agglutination test (LCAT; New York State Veterinary Laboratory, Cornell University, Ithaca, New York), was performed and a strong positive antigenic titre of 256 was found.

Following excision of the polypoid mass, audible stertor resolved and the respiratory pattern of the patient returned to normal. Treatment with itraconazole (Sporanox 100 mg capsules; Janssen-Cilag) was initiated at a dose of 50 mg q24h for 4 months but was

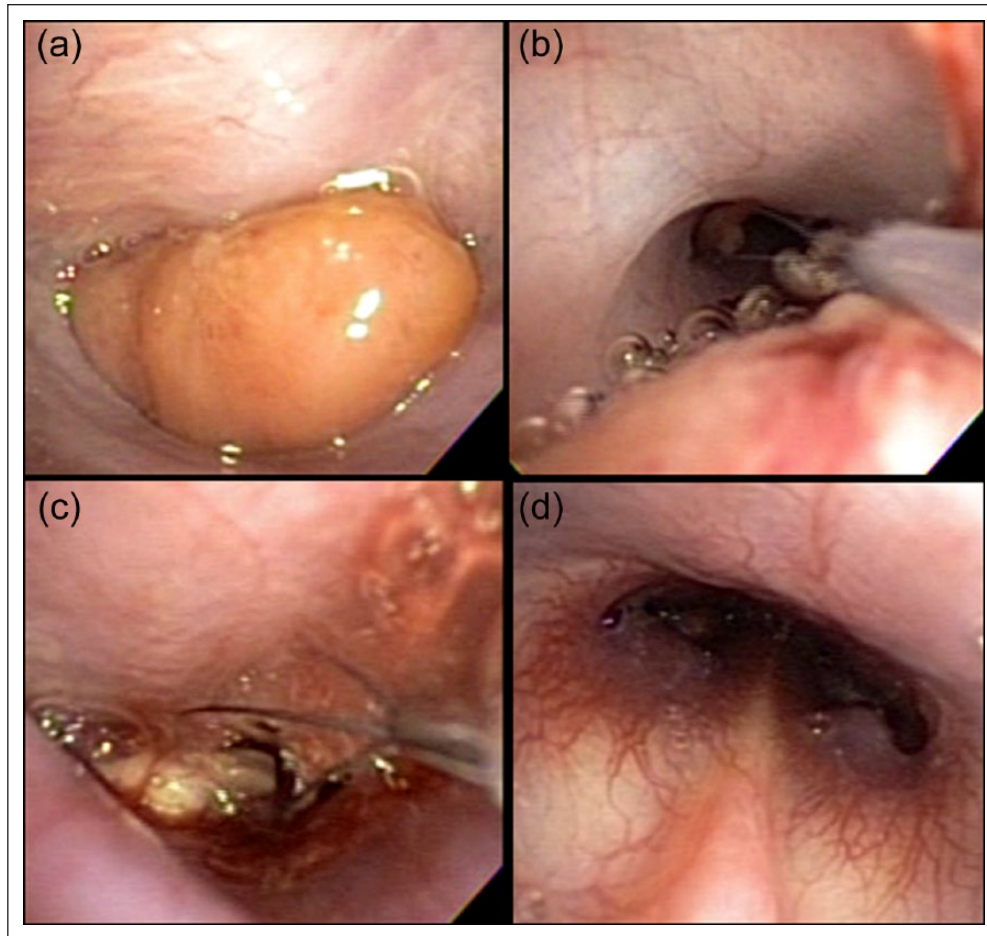


Figure 2 Nasopharyngoscopy in a cat with a nasopharyngeal polypoid mass. (a) Note the well-defined appearance of the mass completely filling the nasopharynx prior to withdrawal. (b) A grasping basket passed through the channel of the endoscope is advanced cranial to the mass. (c) The basket is opened and then pulled caudally in order to grasp the entire mass. (d) Severely inflamed nasal choanae are visible following mass removal

discontinued after only 1 month due to client error. Four months after the procedure, no recurrence of clinical signs was observed and a 32× decrease in the LCAT titre (titre of 8) was observed, indicating a positive response despite only 1 month of therapy. Itraconazole was restarted at the same dose for 4 months following the second LCAT titer. One year after diagnosis, the LCAT titer was negative and the cat remained free of clinical signs.

Discussion

This case report describes a polypoid granulomatous pharyngitis associated with *Cryptococcus* species in a cat. Nasopharyngeal polyps are benign, non-neoplastic, inflammatory growths arising from the mucosa of the nasopharynx, auditory tube or middle ear.¹ In this case report, history, physical examination, CT scan and nasopharyngoscopic findings were all highly suggestive of a nasopharyngeal polyp. Histologically, polyps consist of a core of loosely arranged fibrovascular tissue containing scattered lymphocytes, plasma cells

and macrophages covered by a stratified squamous-to-ciliated columnar epithelial layer. The polyp stalk may originate from the mucosa of the nasopharynx, auditory tube or tympanic bulla. Because the mucosal lining between these regions is continuous and histologically similar, identifying the exact anatomical origin of these polyps is sometimes difficult.² In this case report, the mass was covered by stratified squamous epithelium without evidence of ciliated epithelium, which is not a common histological feature for a nasopharyngeal polyp. However, both ciliated and squamous epithelium can sometimes be found in polyp tissue depending of its origin.^{3,4} The history, physical examination, CT scan and nasopharyngoscopic findings were highly suggestive of a polyp but were not supported by histopathology. We therefore defined this nasopharyngeal tissue in the present report as being a polypoid mass.

The etiology of nasopharyngeal polyps is incompletely understood.⁵ One theory is that they arise as a

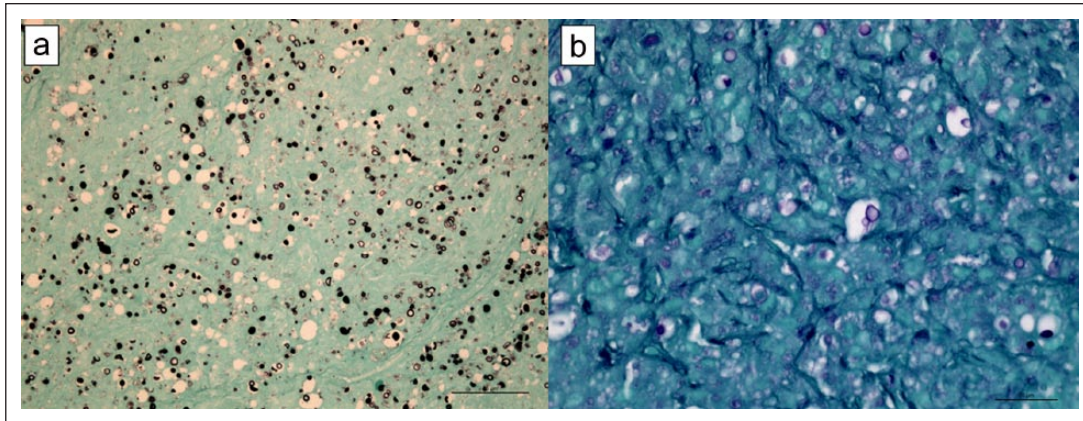


Figure 3 Histopathology of the polypoid granulomatous pharyngitis. (a) Gomori methenamine silver stain. The polypoid mass contains numerous yeast measuring 4–8 μm in diameter. (b) Periodic acid–Schiff stain. The yeast are surrounded by a clear zone corresponding to the capsule. Narrow-based budding, highly suggestive of *Cryptococcus*, is present

result of chronic inflammation.⁶ Chronic inflammation may lead to the formation of a polyp, and nasopharyngeal disease may be associated with a wide variety of underlying conditions: infectious (viral, bacterial, fungal [ie, *Cryptococcus* species] and parasitic), neoplastic, foreign body, vascular, traumatic or congenital.⁷ A recent study failed to demonstrate a consistent association between some infectious agents (feline calicivirus, feline herpesvirus type 1, *Mycoplasma* species or *Chlamydia* species) and the presence of nasopharyngeal polyps.⁸ In human medicine, it is recognized that certain particularly proinflammatory forms of chronic sinusitis, such as allergic fungal sinusitis and aspirin-exacerbated respiratory disease, are both characterized by a strong predilection for nasal polyp growth, concomitant with the presence of an eosinophilic infiltrate into the sinus cavity.^{9–11} Recent research indicates a significant association between nasal polyposis and the presence of tissue eosinophilia; however, both the presence and extent of eosinophilia in nasal polyps can be variable, and a large subset of nasal polyps observed in patients with idiopathic nasal polyposis do not demonstrate eosinophilia.^{12–15} In the case described here, a mild eosinophilic rhinitis was diagnosed but there was no evidence of eosinophils in the polypoid mass removed. It remains unknown whether this polypoid mass is primary or secondary to the fungal infection but *Cryptococcus* species could be responsible for the development of a granulomatous inflammation, leading to the development of a solitary polypoid mass in the nasopharynx. Thus, our report reinforces the importance of analyzing all nasopharyngeal masses that are removed, despite their appearance.

Cryptococcus species are primarily airborne pathogens, and the nasal cavity is usually the primary site of infection in cats and dogs. In most cases, there is only a subclinical colonization without the invasion of the epithelium. When invasion of mucosal tissues occurs,

disease develops locally and/or systemically. In both humans and cats, the infection is caused by *Cryptococcus neoformans* or *Cryptococcus gattii* and may follow ingestion of desiccated yeast cells and basidiospores, or, more rarely, cutaneous inoculation of fungal forms. *C neoformans* has a worldwide distribution and is mainly isolated from feces of pigeons and other birds, whereas *C gattii* occurs mainly in areas of tropical and subtropical climates, and is mainly isolated from wood decay of different species of trees.¹⁶ The incubation period varies from months to years, and the source of infection often remains unknown. In this case report, the species is unknown but *C neoformans* appears to be most likely given the geolocation of infection. The cat described here was an indoor cat, living in Quebec, Canada, where the disease is considered to be uncommon. However, there is no endemic area for *Cryptococcus* species as outbreaks remain rare or sporadic, and lifestyle does not appear to be a risk factor as the disease has already been reported in other indoor cats.¹⁷ An unusual cluster of human and animal cryptococcosis was identified in British Columbia, Canada, in the summer of 2001 with 18 cats, 17 dogs and 50 humans affected.¹⁸

Cryptococcosis is an important differential in cats with chronic nasal discharge, regardless of whether or not facial swelling and/or skin ulceration is present.¹⁷ This fungal disease can present in several different clinical forms, including nasal, central nervous system,¹⁹ cutaneous and systemic forms. The nasal form is the most common in cats, presenting as a chronic sinonasal disease, either alone or together with local spread to the skin, subcutis, bones and regional lymph nodes.^{20–22} Nasopharyngeal cryptococcal granuloma was previously described in five cats; however, it was consistently associated with cryptococcal rhinitis.²³ To our knowledge, this is the first description of feline nasopharyngeal cryptococcosis without cryptococcal rhinitis. However, the

presence of cryptococcal rhinitis cannot be completely excluded because of the small size of the biopsies and the restricted location to rostral areas. The atypical presentation of this patient emphasizes the importance of considering *Cryptococcus* species as a potential etiology in patients presenting with an isolated nasopharyngeal polypoid mass.

Different treatment options exist for nasopharyngeal mass removal. Traction/avulsion is the simplest form of treatment, requiring minimal equipment.²⁴ Vigorous flushing with saline by passing a urinary catheter in a caudal direction from the nares is also reported.²⁵ In this case report, the mass was not accessible for traction/avulsion and was detached at its stalk by endoscopic-guided basket forceps. If manual or endoscopic retrieval is impossible, more invasive approaches may be necessary, including ventral bulla osteotomy, total ear canal ablation, lateral bulla osteotomy, myringotomy and lateral wall resection or via a longitudinal incision in the soft palate.^{24,25} These procedures carry greater risks of morbidity and a specialist surgeon should be consulted.²⁴ The cat we described was successfully managed with a minimally invasive procedure and was discharged the day of the procedure.

No prospective controlled studies exist on the treatment of feline cryptococcosis and all data are based on retrospective studies and case reports. Amphotericin B, ketoconazole, fluconazole and itraconazole have all been used to treat cats. With regard to the effect of different therapeutic protocols, there was no significant difference in outcome between cats treated with amphotericin B-containing protocols and those treated with azole monotherapy using fluconazole or itraconazole.²⁶ In the present case, we chose to use itraconazole because of reasonable costs, low toxicity and no evidence of central nervous system involvement. No adverse effects were recorded by the owners during therapy. The median duration of treatment for itraconazole-treated cats with nasal or all forms of cryptococcus is 9 months, and therapy is usually continued until a negative LCAT is obtained.²⁶ In our case, the patient received a total of 5 months of treatment and the LCAT titre was negative 1 year after the initial presentation. On re-evaluation 4 months after the procedure, despite a 32× decrease, the LCAT titre was still positive and the antifungal treatment was reinstated. However, it has been reported that the titer can continue to decrease after stopping therapy in cats with clinical resolution and some may remain positive long term without any active disease.²⁶ This finding emphasizes the importance of nasopharyngeal polypoid mass removal in this particular case and raises the issue of the necessity of systemic antifungal treatment following removal.

Conclusions

To our knowledge, this is the first description of a feline nasopharyngeal polypoid cryptococcal mass without documented evidence of *Cryptococcus* species rhinitis. This case report emphasizes the relevance of analyzing all nasopharyngeal masses after their removal and the importance of considering *Cryptococcus* as a potential pathogen in cats presented with signs of nasopharyngeal obstruction.

Funding The authors received no specific grant from any funding agency in the public, commercial or not-for-profit sectors for the preparation of this case report.

Conflict of interest The authors do not have any potential conflicts of interest to declare.

References

- Esterline ML, Radlinsky MG and Schermerhorn T. **Endoscopic removal of nasal polyps in a cat using a novel surgical approach.** *J Feline Med Surg* 2005; 7: 121–124
- Muilenburg RK and Fry TR. **Feline nasopharyngeal polyps.** *Vet Clin North Am Small Anim Pract* 2002; 32: 839–849.
- Akbay E, Ozgur T and Cokkeser Y. **Is there any relationship between the clinical, radiological and histopathologic findings in sinonasal polyposis?** *Turk Patoloji Derg* 2013; 29: 127–133
- Njaa BL and Wilcook BP. **The ear and eye.** In: Zachary JF and Donald McGavin M (ed). *Pathologic basis of veterinary diseases.* St Louis, MO: Elsevier, 2012, pp 1182–1183.
- Holt DE. **Nasopharyngeal polyps.** In: King LG (ed). *Textbook of respiratory disease in the dog and cat.* St Louis, MO: Saunders, 2004, pp 328–332.
- Little C. **Nasopharyngeal polyps.** In: August JR (ed). *Consultations in feline internal medicine 3.* Philadelphia, PA: WB Saunders, 1997, pp 310–316.
- Reed N and Gunn-Moore D. **Nasopharyngeal disease in cats: 1. Diagnostic investigation.** *J Feline Med Surg* 2012; 14: 306–315.
- Klose TC, MacPhail CM, Schultheiss PC, et al. **Prevalence of select infectious agents in inflammatory aural and nasopharyngeal polyps from client owned cats.** *J Feline Med Surg* 2010; 12: 769–774.
- Sladek K, Dworski R, Soja J, et al. **Eicosanoids in bronchoalveolar lavage fluid of aspirin-intolerant patients with asthma after aspirin challenge.** *Am J Respir Crit Care Med* 1994; 149: 940–946
- Mascia K, Borish L, Patrie J, et al. **Chronic hyperplastic eosinophilic sinusitis as a predictor of aspirin-exacerbated respiratory disease.** *Ann Allergy Asthma Immunol* 2005; 94: 652–657
- Rosenfeld RM, Andes D, Bhattacharyya N, et al. **Clinical practice guideline: adult sinusitis.** *Otolaryngol Head Neck Surg* 2007; 137 Suppl: S1–31
- Elovic A, Wong DT, Weller PF, et al. **Expression of transforming growth factors-alpha and beta 1 messenger RNA and product by eosinophils in nasal polyps.** *J Allergy Clin Immunol* 1994; 93: 864–869
- Baraniuk JN and Maibach H. **Pathophysiological classification of chronic rhinosinusitis.** *Respir Res* 2005; 6: 149.

- 14 Van Zele T, Claeys S, Gevaert P, et al. **Differentiation of chronic sinus diseases by measurement of inflammatory mediators.** *Allergy* 2006; 61: 1280–1289.
- 15 Polzehl D, Moeller P, Riechelmann H, et al. **Distinct features of chronic rhinosinusitis with and without nasal polyps.** *Allergy* 2006; 61: 1275–1279
- 16 Cardoso PH, Baroni Fde A, Silva EG, et al. **Feline nasal granuloma due to *Cryptococcus gattii* type VGII.** *Mycopathologia* 2013; 176: 303–307.
- 17 Pennisi MG, Hartmann K, Lloret A, et al. **Cryptococcosis in cats: ABCD guidelines on prevention and management.** *J Feline Med Surg* 2013; 15: 611–618.
- 18 Craig S, Lester S, Black W, et al. **Multispecies outbreak of cryptococcosis on southern Vancouver Island, British Columbia.** *Can Vet J* 2002; 43: 792–794.
- 19 Berthiaume DR and Kline KL. **What is your neurologic diagnosis?** *J Am Vet Med Assoc* 2012; 241: 1437–1439.
- 20 McGill S, Malik R, Saul N, et al. **Cryptococcosis in domestic animals in Western Australia: a retrospective study from 1995–2006.** *Med Mycol* 2009; 47: 625–639.
- 21 O'Brien CR, Krockenberger MB, Wigney DI, et al. **Retrospective study of feline and canine cryptococcosis in Australia from 1981 to 2001: 195 cases.** *Med Mycol* 2004; 42: 449–460.
- 22 Malik R, Wigney DI, Muir DB, et al. **Cryptococcosis in cats: clinical and mycological assessment of 29 cases and evaluation of treatment using orally administered fluconazole.** *J Vet Mycol* 1992; 30: 133–144.
- 23 Malik R, Martin P, Wigney DI, et al. **Nasopharyngeal cryptococcosis.** *Aust Vet J* 1997; 75: 483–488.
- 24 Reed N and Gunn-Moore D. **Nasopharyngeal disease in cats: 2. Specific conditions and their management.** *J Feline Med Surg* 2012; 14: 317–326.
- 25 Hunt GB, Perkins MC, Foster SF, et al. **Nasopharyngeal disorders of dogs and cats: a review and retrospective study.** *Compend Contin Educ Pract Vet* 2002; 24: 184–200.
- 26 O'Brien CR, Krockenberger MB, Martin P, et al. **Long-term outcome of therapy for 59 cats and 11 dogs with cryptococcosis.** *Aust Vet J* 2006; 84: 384–392.