


# Leucocytoclastic vasculitis secondary to COVID-19 infection in a young child

Gurinder Kumar ,<sup>1</sup> Shanta Pillai,<sup>1</sup> Paige Norwick,<sup>2</sup> Hulya Bukulmez<sup>1</sup>

<sup>1</sup>Paediatrics, Case Western Reserve University Hospital, Cleveland, Ohio, USA  
<sup>2</sup>Dermatology, Case Western Reserve University Hospital, Cleveland, Ohio, USA

## Correspondence to

Dr Gurinder Kumar;  
kumargurinder@gmail.com

Accepted 26 March 2021

## SUMMARY

The current case report describes a 13-year-old young boy who presented with purpuric rashes following a completely asymptomatic COVID-19 infection and biopsy-confirmed leucocytoclastic vasculitis, mild haematuria and mild elevation of serum IgA. This case highlights one of the dermatological manifestations of COVID-19 infection which has not been reported so far. Paediatricians should explore the history of this infection when evaluating any child presenting with a vasculitic rash.

## BACKGROUND

Leucocytoclastic vasculitis is a small vessel vasculitis which may occur following:

1. Infections such as HIV, hepatitis B and hepatitis C, varicella, parvovirus B19 and cytomegalovirus.
2. Drugs: antibiotics particularly beta-lactam drugs, non-steroidal anti-inflammatory drugs (NSAIDs), diuretics and so on.
3. Autoimmune disorders: it can occur following autoimmune conditions such as lupus, rheumatoid arthritis, Sjogren's syndrome and inflammatory bowel disease.
4. Malignancies.

Viral infections are known triggers of leucocytoclastic vasculitis. At present, we are dealing with COVID-19 infection, the devastating disease of what has become a pandemic, which started its spread from Wuhan, China. Presentations of COVID-19 have ranged from asymptomatic/mild symptoms to severe illness and mortality. There have been multiple reports in literature about different presentations of COVID-19 in children. There is a spectrum of dermatological and vascular presentations which may range from mild skin rashes to severe arterial strokes.

We are reporting a rare presentation of leucocytoclastic vasculitis following an asymptomatic COVID-19 infection in a young adolescent. To our knowledge, this is the first case report of this particular presentation in a paediatric age group.

## CASE PRESENTATION

A 13-year-old African American boy, previously healthy, presented to the emergency department with a history of skin rashes on both feet and ankles of 1-week duration.

The rash started on his feet and around ankles which spread to his lower legs over time. The rash was petechial and purpuric in nature. It was palpable and non-pruritic. He denied having had a

similar rash before. There was no history of abdominal pain, fever, chills, joint pain or swelling. The child did not have any other symptoms that could be due to a bleeding diathesis, such as easy bruising or mucosal bleeding.

A significant medical history included asymptomatic COVID-19 infection around 4 weeks prior to the onset of rashes which was detected as part of contact screening. On direct questioning, the patient reconfirmed that he did not have any respiratory symptoms or any fevers during the COVID-19 infection.

On physical examination, growth parameters were normal. He was afebrile and his blood pressure was 102/61 mm Hg. His respiratory rate was 16/min and oxygen saturation was 100% in room air.

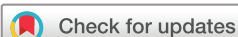His skin examination revealed rashes involving the dorsal feet and lower extremities. There were scattered non-blanching round dark red palpable petechiae and macular skin rashes, few coalescing into purpuric lesions ([figure 1](#)).

## INVESTIGATIONS

A SARS-CoV-2 assay performed using Luminex NxTAG multiplex RTPCR technology detected presence of viral RNA, a month prior to presentation. His complete blood count (including differential count), liver function and renal function were within normal limits. Inflammatory marker evaluation showed normal C reactive protein, procalcitonin and ferritin, but erythrocyte sedimentation rate was mildly elevated to 21 mm/hour (ref range: 0–20). His complements were normal and antinuclear antibody screen was negative. Immunoglobulin profile showed mildly elevated IgA. D-dimers were elevated. [Table 1](#) shows the detailed laboratory work-up done for the child.

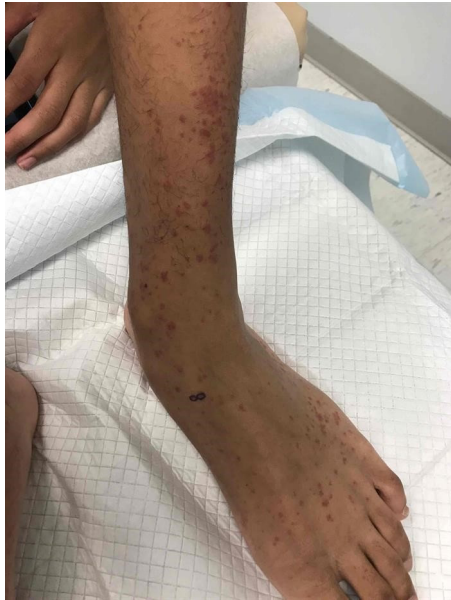Chest X-ray and ECG were not done, since in his physical examination his cardiac and respiratory examinations were benign and he was saturating 100% in room air. Urine analysis showed moderate blood and no proteinuria. An initial working diagnosis of Henoch-Schoenlein purpura (HSP) was considered due to palpable purpura in the lower extremities below his waistline with slight elevation of serum IgA and mild haematuria. He was observed in hospital for 2 days and discharged home in satisfactory condition. However, his rashes persisted and 10 days later, a diagnostic skin biopsy was performed by dermatopathology.

The biopsy suggested small vessel neutrophilic vasculitis. Non-specific, patchy deposition of fibrinogens present in superficial dermis only. [Figure 2](#)



© BMJ Publishing Group Limited 2021. No commercial re-use. See rights and permissions. Published by BMJ.

**To cite:** Kumar G, Pillai S, Norwick P, et al. *BMJ Case Rep* 2021;**14**:e242192. doi:10.1136/bcr-2021-242192



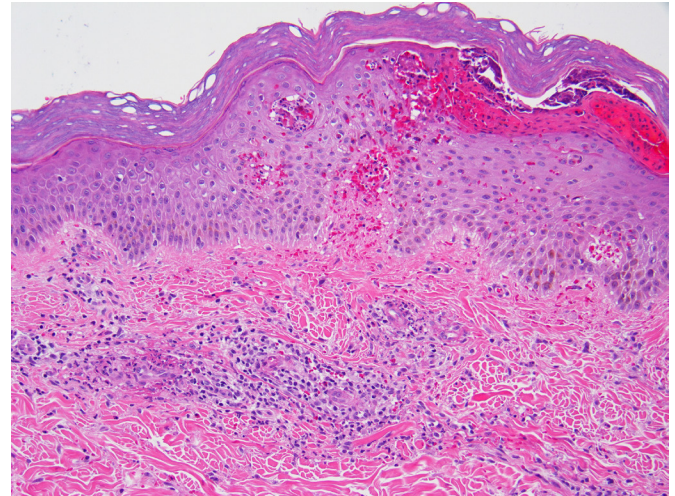
**Figure 1** Rashes over the lower limbs of the child.

shows superficial epidermal necrosis with intraepidermal pustules and associated small vessel neutrophilic vasculitis (H&E, original magnification 20×). **Figure 3** shows small vessel neutrophilic vasculitis at higher power. Immunofluorescence studies did not show any immunoglobulin staining presence including IgA.

**Table 1** Laboratory investigations done for the index child

Lab parameter	Result	Normal value
Complete blood count	Haemoglobin 123 g/L	124–148 g/L
	Platelet count $314 \times 10^9/L$	150–400 $\times 10^9/L$
	White cell count	4.5–13.5 $\times 10^9/L$
	$5.2 \times 10^9/L$	24%–74%
	Neutrophils 38.8%;	29%–49%
	lymphocyte 50%	2%–10%
	Monocyte 7.2%	0.1%–4%
	Eosinophils 3.3%	$\leq 1.9\%$
Basophils 0.7%		
Erythrocyte sedimentation rate	21 mm/hour	$\leq 20$ mm/hour
Procalcitonin	<0.05 ng/mL	<0.5 ng/mL
C reactive protein	<0.5 mg/dL	<0.8 mg/dL
Ferritin	9.6 ng/mL	11.5–300 ng/mL
D-dimer	850 ng/mL	<230 ng/mL
Prothrombin time	15.1 s	9.7–12.9 s
Activated partial thromboplastin time	34 s	25–37 s
International normalised ratio	1.34	0.90–1.10
ANA screen	Negative	
Troponin I	<0.030 ng/mL	<0.120 ng/mL
C3	133 mg/dL	81–163 mg/dL
C4	23 mg/dL	14–46 mg/dL
IgA	278 mg/dL	24–268 mg/dL
IgG	1691 mg/dL	768–1632 mg/dL
IgM	89 mg/dL	41–250 mg/dL
IgE	112.6 IU/mL	1.9–170 IU/mL

ANA, antinuclear antibody.



**Figure 2** Photomicrograph of a punch biopsy of the skin from left medial foot demonstrating superficial epidermal necrosis with intraepidermal pustules and associated small vessel neutrophilic vasculitis (H&E, original magnification 20×).

### DIFFERENTIAL DIAGNOSIS

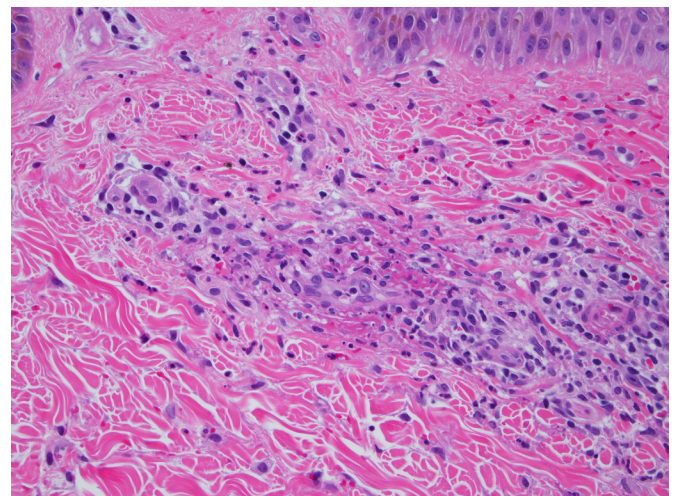
An important differential diagnosis considered was HSP. However, the biopsy of lesion immunofluorescent staining did not show immune IgA deposits which did not support this diagnosis.

### TREATMENT

The child was given a course of oral prednisolone (1 mg/kg per day) for 2 weeks followed by gradual tapering over the next 4 weeks.

In most patients, idiopathic leucocytoclastic vasculitis resolves spontaneously within a few weeks, negating the need for treatment to stop the disease process. Treatment in patients with acute, uncomplicated disease is directed towards the alleviation of symptoms which may be pruritus, pain or local oedema.

- The following measures during the vasculitis can be beneficial:
- ▶ Rest, leg elevation and compression stockings—these may decrease immune complex deposition in the lower extremities, thereby decreasing the progression of vasculitic skin lesions.



**Figure 3** Small vessel neutrophilic vasculitis at higher power (H&E, original magnification 40×).



- ▶ NSAIDs may be useful for pain management.
- ▶ Oral antihistamines can suppress pruritus.<sup>1</sup>

## OUTCOME AND FOLLOW-UP

The child gradually improved but still had some persistent lesions for almost 4 weeks and continues to be on tapering doses of steroids.

## DISCUSSION

The current COVID-19 pandemic is caused by the SARS-CoV-2, which was isolated in December 2019 for the first time in Wuhan (China). Common presentations include fever, fatigue, myalgia, cough, headache, nasal congestion or rhinorrhoea, nausea or vomiting, new loss of taste or smell, sore throat, diarrhoea, abdominal pain, shortness of breath or difficulty breathing, poor appetite or poor feeding. Recent evidence suggests that as many as half of paediatric infections may be asymptomatic. Apart from these features, multiple skin manifestations have been reported in the literature. These include urticarial rashes, maculopapular rashes, papulovesicular exanthem, livedo reticularis and chilblain-like acral vasculitic pattern. In the past few months, there have been multiple systematic reviews and case reports concerning the dermatological manifestations of COVID-19.<sup>2,3</sup>

Variable and heterogeneous skin manifestations in patients with COVID-19 have been described that may appear before, during and after the disease. These may range from mild skin rashes to severe vasculitis manifesting as severe arterial strokes. Tiwari *et al*<sup>4</sup> described a 9-year-old girl with COVID-19-associated arterial ischaemic stroke and multisystem inflammatory syndrome who survived.<sup>4</sup>

Vasculitis refers to the inflammation of blood vessels which leads to tissue destruction with or without organ damage. Leucocytoclastic vasculitis is a small vessel vasculitis which is characterised by immune complex-mediated vasculitis of the dermal capillaries and venules. The main clinical features of cutaneous leucocytoclastic angiitis include palpable purpura, lower extremity location and small vessel involvement.

This vasculitis is idiopathic up to 50% of the cases and the common triggers of secondary leucocytoclastic vasculitis are infections, autoimmune diseases, malignancies and drugs. The pathogenesis of leucocytoclastic vasculitis involves immune complex deposition in small vessel walls along with the activation of the complement system. Neutrophils are recruited, and injury to vessel walls ensues with secondary exudation of erythrocytes, fibrin and serum.<sup>5</sup>

Strong IgA deposition without other antibody deposition is indicative of HSP which was not seen in our index child on immunofluorescence staining of the skin biopsy.

Patients with COVID-19 can develop vasculitis due to endothelial damage caused by viral invasion of endothelium or due to the immune reaction leading to leucocytoclastic vasculitis.<sup>6</sup> It is likely in our case that direct damage of viral invasion resulted in the vasculitic features but not the immune complex deposition seen in autoimmune vasculitis such as HSP. The patient's persistent lesions regardless of oral prednisone also suggest that there is minimal inflammatory reaction but more vascular damage secondary to this severe infection.

There have been case reports of adults presenting with this entity after COVID-19 but none reported in a paediatric age group.<sup>7-9</sup> This might be mostly due to the relative low incidence rate of COVID-19 infection in children. However, asymptomatic infections in children still may cause silent vascular damage to them. Long-term follow-up of this illness in patients with and

without severe manifestation in the future will help us understand the true nature of the viral impact on paediatric COVID-19.

Mayor-Ibarguren *et al*<sup>7</sup> reported an 83-year-old woman with a history of hypertension, transient ischaemic attack, chronic renal impairment and atrial fibrillation who presented with cutaneous vasculitis whose PCR for SARS-CoV-2 was negative but serological qualitative testing for SARS-CoV-2 was positive for IgM and IgG antibodies. The patient responded to a 10-day course of prednisolone and improved clinically.<sup>6</sup> In our index child, the child required a longer course of steroids for the rashes to resolve.

Iraji *et al*<sup>8</sup> also reported a 49-year-old healthy man who presented with purpuric lesions on the legs and abdomen following COVID-19 infection a few weeks prior to his presentation. The biopsy had shown leucocytoclastic vasculitis.<sup>8</sup>

Camprodon Gómez *et al*<sup>9</sup> reported a relatively younger 29-year-old man who presented with purple palpable papules over the lower limbs and abdomen. He had symptomatic COVID-19 infection a month prior to presentation. Although the nasopharyngeal swabs were negative, serology (both IgG and IgM) was positive. The skin biopsy showed leucocytoclastic vasculitis and immunofluorescence stain showing fibrinogen deposition. Interestingly, the authors described the presence of SARS-CoV-2 PCR from a skin biopsy.<sup>9</sup>

One of the limitations of our report is that we could not get the antibody titres for COVID-19 at the time of presentation of rashes in our index child. Though symptoms in our index child started a few weeks after the child was diagnosed positive for COVID-19, it could still be mere a chance that it was triggered by this virus as there are many other causes of the leucocytoclastic vasculitis. However, the temporal relation of the onset of infection with rashes and absence of other signs and symptoms of other infections point towards the possible aetiological agent, which is COVID-19.

To the best of our knowledge, the current case presented is the youngest child reported with leucocytoclastic vasculitis following a SARS-CoV-2 infection. It is remarkable that our patient was completely asymptomatic and did not have any COVID-19 manifestation. Therefore, we suggest that our patient developed a hypersensitivity reaction and vasculitis secondary to COVID-19.

The vascular pathology of COVID-19 is a topic of great interest, and postmortem biopsies of patients with COVID-19 have revealed macrovascular and microvascular thrombosis involving arteries, veins, arterioles, capillaries and venules in all major organs.<sup>10</sup> Endothelial cell inflammation, apoptosis and dysfunction do occur in patients with COVID-19 like other viral infections which contribute to pathological events, including tissue hypoperfusion, injury and thrombosis. However, some patients may have milder manifestations as our index child.

A high index of suspicion is important in the diagnosis of these patients and a skin biopsy may be very helpful.

**Acknowledgements** Stephen C Somach, for the pathology and photography of histological images, Department of Dermatology and Pathology, Metro Health Medical Center, Case Western Reserve University School of Medicine, Cleveland, Ohio, USA.

**Contributors** GK conceptualised and designed the case report, drafted the initial manuscript, and reviewed and revised the manuscript. SP and PN collected data, carried out the initial literature review, and reviewed and revised the manuscript. HB designed the data collection instruments, coordinated and supervised data collection, and critically reviewed the manuscript. All authors approved the final manuscript as submitted and agree to be accountable for all aspects of the work.

**Funding** The authors have not declared a specific grant for this research from any funding agency in the public, commercial or not-for-profit sectors.

## Learning points

- ▶ COVID-19 infections can present with different dermatological manifestations.
- ▶ Leucocytoclastic vasculitis can follow viral infections such as COVID-19 infection. A recent history of confirmed infection could be a clue to aetiology of vasculitis.
- ▶ Asymptomatic children with COVID-19 infection need to be followed up for late cutaneous manifestations such as leucocytoclastic vasculitis.

**Competing interests** None declared.

**Patient consent for publication** Obtained.

**Provenance and peer review** Not commissioned; externally peer reviewed.

This article is made freely available for use in accordance with BMJ's website terms and conditions for the duration of the covid-19 pandemic or until otherwise determined by BMJ. You may use, download and print the article for any lawful, non-commercial purpose (including text and data mining) provided that all copyright notices and trade marks are retained.

**ORCID iD**

Gurinder Kumar <http://orcid.org/0000-0001-5457-1827>

## REFERENCES

- 1 Russell JP, Gibson LE. Primary cutaneous small vessel vasculitis: approach to diagnosis and treatment. *Int J Dermatol* 2006;45:3–13.
- 2 Genovese G, Moltrasio C, Berti E, et al. Skin manifestations associated with COVID-19: current knowledge and future perspectives. *Dermatology* 2021;237:1–12.
- 3 Singh H, Kaur H, Singh K, et al. Cutaneous manifestations of COVID-19: a systematic review. *Adv Wound Care* 2021;10:51–80.
- 4 Tiwari L, Shekhar S, Bansal A, et al. COVID-19 associated arterial ischaemic stroke and multisystem inflammatory syndrome in children: a case report. *Lancet Child Adolesc Health* 2021;5:88–90.
- 5 Baigrie D, Bansal P, Goyal A. Leucocytoclastic Vasculitis. In: *StatPearls*. Treasure Island (FL): StatPearls Publishing, 2020.
- 6 Almashat SA. Vasculitis in COVID-19: a literature review. *J Vasc* 2020;6 <https://www.hilarispublisher.com/abstract/vasculitis-in-covid19-a-literature-review-44973.html>
- 7 Mayor-Ibarguren A, Feito-Rodriguez M, Quintana Castanedo L, et al. Cutaneous small vessel vasculitis secondary to COVID-19 infection: a case report. *J Eur Acad Dermatol Venereol* 2020;34:e541–2.
- 8 Iraj F, Galehdari H, Siadat AH, et al. Cutaneous leukocytoclastic vasculitis secondary to COVID-19 infection: a case report. *Clin Case Rep* 2021;9:830–4.
- 9 Camprodon Gómez M, González-Cruz C, Ferrer B, et al. Leucocytoclastic vasculitis in a patient with COVID-19 with positive SARS-CoV-2 PCR in skin biopsy. *BMJ Case Rep* 2020;13:e238039.
- 10 Becker RC. COVID-19-associated vasculitis and vasculopathy. *J Thromb Thrombolysis* 2020;50:499–511.

Copyright 2021 BMJ Publishing Group. All rights reserved. For permission to reuse any of this content visit <https://www.bmj.com/company/products-services/rights-and-licensing/permissions/>  
BMJ Case Report Fellows may re-use this article for personal use and teaching without any further permission.

Become a Fellow of BMJ Case Reports today and you can:

- ▶ Submit as many cases as you like
- ▶ Enjoy fast sympathetic peer review and rapid publication of accepted articles
- ▶ Access all the published articles
- ▶ Re-use any of the published material for personal use and teaching without further permission

**Customer Service**

If you have any further queries about your subscription, please contact our customer services team on +44 (0) 207111 1105 or via email at [support@bmj.com](mailto:support@bmj.com).

Visit [casereports.bmj.com](http://casereports.bmj.com) for more articles like this and to become a Fellow