



Expanding the Clinical Phenotype of PLECTIN-Related Plectinopathies

Paria Najarzadeh Torbati¹, Mohammad Doosti¹, Payam Sarraf^{2,3}, Reza Boostani⁴, Najmeh Ahangari^{1,5}, Mehran Beiraghi Toosi⁶, Abbas Tafakhori^{2,3}, Meisam Babaei⁷, Soheila Abedini¹, Hadis Malek¹, Samaneh Maskani¹, Mojtaba Safi¹, *Ehsan Ghayoor Karimiani¹

1. Department of Medical Genetics, Next Generation Genetic Polyclinic, Mashhad, Iran
2. Iranian Center of Neurological Research, Neuroscience Institute, Tebran University of Medical Sciences, Tebran, Iran
3. Imam Khomeini Hospital Complex, Tebran University of Medical Sciences, Tebran, Iran
4. Department of Neurology, Mashhad University of Medical Sciences, Mashhad, Iran
5. Mashhad University of Medical Sciences, Mashhad, Iran
6. Pediatric Neurology Department, Ghaem Hospital, Mashhad University of Medical Sciences, Mashhad, Iran
7. Department of Pediatrics, North Khorasan University of Medical Sciences, Bojnourd, Iran

*Corresponding Author: Email: eghayoor@gmail.com

(Received 18 May 2023; accepted 12 Aug 2023)

Abstract

Background: Plectinopathy-associated disorders are caused by mutations in the *PLECTIN* (*PLEC*) gene encoding Plectin protein. *PLEC* mutations cause a spectrum of diseases defined by varying degrees of signs, mostly with epidermolysis bullosa simplex with muscular dystrophy (EBS-MD) and plectinopathy-related disorder is limb-girdle muscular dystrophy type 2Q (LGMD2Q). Here we report three cases with EBS-MD and LGMD2Q disorders analyzed by exome sequencing followed by mutation confirmation.

Methods: A complete clinical examination was done by expert specialists and clinical geneticists in Next Generation Genetic polyclinic, Mashhad, Iran (NGC, years 2020 _2021), Genomic DNA was extracted and evaluated through whole-exome sequencing analysis followed by Sanger sequencing for co-segregation analysis of *PLEC* candidate variants.

Results: We found three cases with the plectinopathy-related disease, two patients with limb-girdle muscular dystrophy type 2Q (LGMD2Q), and the other affected proband suffers from epidermolysis bullosa simplex combined with muscular dystrophy (EBS-MD) with variable zygosity mutations for *PLEC*. Motor development disorder and muscular dystrophy symptoms have different age onset in affected individuals. Patients with EBS demonstrated symptoms such as blistering, skin scars, neonatal-onset, and nail dystrophy.

Conclusion: We report plectinopathy-associated disorders to expand clinical phenotypes in different types of *PLEC*-related diseases. We suppose to design more well-organized research based on comprehensive knowledge about the genetic basis of plectinopathy diseases.

Keywords: Plectinopathy; Genetics; Muscular dystrophy; Myopathy



Introduction

Plectinopathy-associated disorders are caused by mutations in the *PLECTIN* (*PLEC*) gene encoding plectin, a high-weight cytolinker protein expressed in many tissues, including skin and muscle. Plectin is a member of the plakin family of proteins, and it has tissue and organelle-specific transcript isoforms. Therefore, it is a versatile linker protein of cytoskeletal components to target organelles in cells of different tissues (1). Plectin preserves the interactions of intermediate filaments to the plasma membrane attachment sites and plays a vital role in the formation of hemidesmosomes. It also has a substantial role in skeletal muscle function and neuromuscular junctions (2, 3).

PLEC mutations cause a spectrum of diseases defined by varying degrees of signs, mainly with Epidermolysis bullosa simplex with muscular dystrophy (EBS-MD). EBS-MD contains progressive M.D. symptoms and blistering of the skin. Another plectinopathy-related disorder is limb-girdle muscular dystrophy type 2Q (LGMD2Q); patients with LGMD2Q phenotype showed early-onset LGMD without skin abnormalities. Other plectin-related diseases include EBS-pyloric atresia (EBS-PA) and EBS-Ogna (EBS-OG) (2, 4, 5).

Limb-girdle muscular dystrophy type 2Q (LGMD2Q) is caused by mutations in the *PLEC* gene (OMIM #613723). LGMD2Q is an Autosomal Recessive disease with clinical features such as proximal muscle weakness and motor delay development with early onset in childhood, Lumbar Lordosis and late-onset Contracture's symptoms may also be included.

Epidermolysis bullosa simplex with muscular dystrophy (EBS-MD) also is an A.R. disease with (OMIM # 226670); the main symptoms of EBS-MD is skin blistering at birth with progressive muscle weakness, other clinical features like congenital onychodystrophy, mucous membrane involvement can be included (6).

A group of large proteins called Palkin was first identified on their role relating with intermediate filaments (I.F.s) or IF-anchoring structures, desmosomes, and hemidesmosomes. Plectin is the most versatile protein among palkins. The *PLEC* gene located on chromosome 8q24 in humans presents different tissue-specific plectin isoforms (7).

In this study, three unrelated cases with different phenotypes related plectinopathy disorder have been analyzed in order to finding underlying genetics cause. The probands have different types of plectinopathy disorder as follows: index patients (I, II) in the compound heterozygous state affected with LGMD2Q, patient (III) in the homozygous state affected with EBS-MD, in the *PLEC* gene.

Methods

Participants

At the year of 2020, patients suspected to muscular dystrophy were referred to NGC polyclinic for comprehensive genomic assessment and genetic counseling. All referrals were assessed for clinical examination by neurologists.

All patients and their available family members signed written informed consent for clinical data collection, storage of biological samples, experimental analyses, and the publication of relevant findings and images. Blood samples were collected from all participants.

Genetic Study

Genomic DNA was extracted from whole blood using a standard salting-out method. For patient's index (I and III), we performed whole-exome sequencing (WES) analysis, and for patient index (II), at first, we genotyped for DMD and BMD mutations, after negative results, we expanded our analysis with WES. Thus we followed our study with Sanger sequencing for segregation analysis in the affected individuals and parents. We used the Target Enrichment Preparation Kit for Agilent (VersionV6). We used the Illumina HiSeq 4000 system (Illumina, Inc., San Diego,

CA, USA) for Sanger sequencing. FASTQ files were aligned to the human reference sequence (hg19) by Burrows-Wheeler Aligner (BWA), and SAM files were generated. Further, SAM to BAM conversion, BAM file sorting, and removal of duplicate reads were carried out by Picard (<http://picard.sourceforge.net>) after generating VCF files by Genome Analysis Tool Kit (GATK) annotation was performed with Annovar32. Variant prioritization was aided by the tools FATHMM, MutationAssessor, PolyPhen-2, and SIFT. For variant analysis, the gnomAD, GME Variome Project, Iranome, Ensembl Variant Table, ClinVar, and CADD scores were used.

Ethical approval

All procedures performed in studies involving human participants were under the ethical standards of the institutional research committee and with the 1964 Helsinki declaration and its later amendments or comparable ethical standards. Ethics Committee of Mashhad University of Medical Sciences approved the study (IR.MUMS.MEDICAL.REC.1398.757).

Results

Clinical Description

The three affected probands (PI, PII and PIII) were male and the only child of consanguineous with healthy parents from different cities of Iran (Fig. 1). Patients' characteristics and clinical features are shown as Table 1.

Table 1: Clinical features of affected individuals with *PLEC* variant

<i>Phenotype/ Case</i>	<i>Patient I</i>	<i>Patient II</i>	<i>Patient III</i>
Origin	Iran	Iran	Iran
Gender	Male	Male	Male
Consanguinity	Positive	Positive	Positive
Current age	36 yr	11 yr	30 yr
Age onset	22 yr	after childbirth	26 yr
- Contractures, late-onset	Absent	Absent	Present
- Lumbar lordosis	Present	Present	NA
- Muscular dystrophy, limb-girdle	Present	Present	Present
- Proximal muscle weakness	Present	Present	Present
- Generalized muscle weakness	Present	Present	Present
- Muscle atrophy	Present	Present	Present
- Gowers sign	Present	Present	Present
- Difficulty climbing stairs, running, jumping	Present	Present	Present
- Muscle biopsy shows dystrophic features	Present	ND	Present
- DMD and BMD test	ND	Absent	ND
- Delayed motor development	Present	Present	Present
- Increased serum creatine kinase	405	456	Absent
- Onset in early childhood	Absent	Present	Absent
- Rapid progression in adolescence	Present	Present	Present
- Adults may lose ability to walk	Absent	Present	Present

NA Not available, ND Not determined

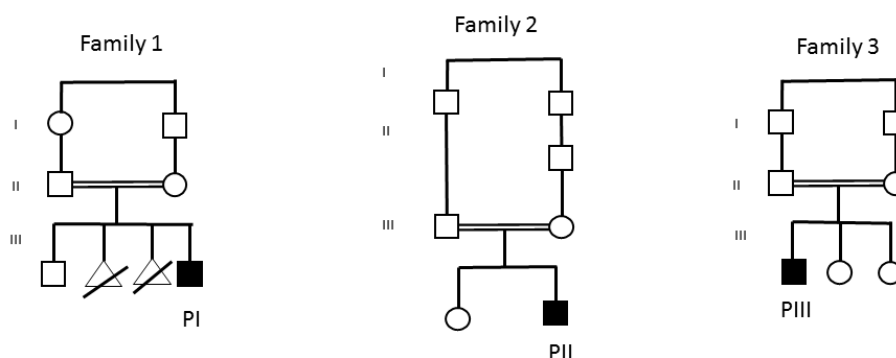


Fig.1: Pedigrees of the families (families 1-3) in whom exome sequencing identified variants in PLEC segregating with the disease. Black-filled symbols represent affected individuals, whereas open symbols represent unaffected family members

Both patients I and II presented with Limb-girdle muscular dystrophy but with, unlike age onset. Early symptoms of muscle weakness for the first patient started at 22 years old (patient I, currently 36 years old), and he can walk with the problem at present with progression in disease, but the second one had after birth onset (patient II, currently 11 years old) and he has lost the ability to walk. Both patients with LGMD2Q showed Lordosis in the lower back and lumbar spine. Increased serum creatine kinase (C.K.) was positive for both patients. About the third affected patient with EBS-MD disorder, he had short stature with slow weight gain, his first symptoms of muscular dystrophy were first noted in adoles-

cence at 26 years old (patient III, currently 30 years old) and gradually progressed, resulting in the inability to walk. Patient III showed elbow and neck contracture; on his neuromuscular examination, reflexes were diminished, and Patient III also presented with skin scars and neonatal-onset generalized blistering, blistering of mucous membranes in the mouth (Fig. 2), nail dystrophy in feet, palmoplantar keratosis (Fig. 3), blistering of mucous membranes in the mouth and palmoplantar keratosis appear intermittently and then resolve

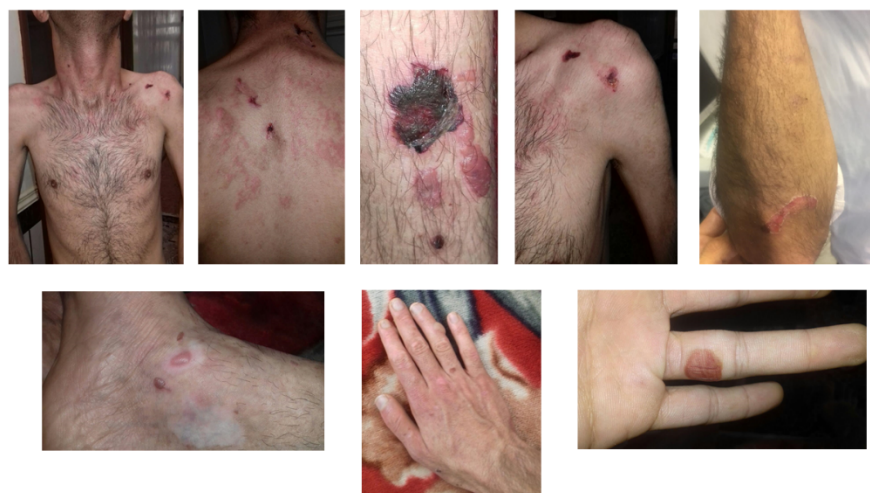

Fig. 2: EBS-MD clinical features with skin scars and neonatal onset generalized blistering, contractures in neck and elbow of patient III

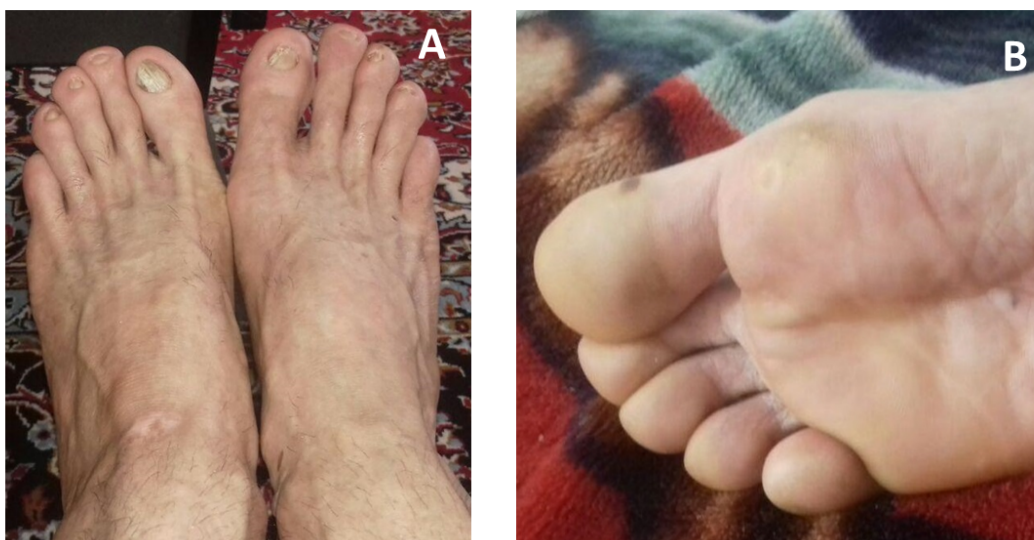

Fig. 3: EBS-MD clinical features of patient III (A): Nail dystrophy (B): palmoplantar keratosis

All three patients showed delayed motor development, proximal muscle weakness progressing to generalized muscles, muscle atrophy, and positive Gowers sign as shown in Table 1.

Genetic findings

To identify the pathogenic mutation, we filtered mutations for finding variants that were pheno-

typically and functionally relevant to the disease. We performed Sanger sequencing for segregation *PLEC* variant to confirm the affected individuals and heterozygous state in the healthy parents. Different in silico prediction tools was used to assess these variants: FATHMM, MutationAssessor, PolyPhen-2, and SIFT and CADD score (Table 2).

Table 2: Pathogenicity and population frequency analysis of *PLEC* variants

<i>Families</i>	<i>F1</i>		<i>F2</i>		<i>F3</i>
PLEC Variants	c.8464C>T p.Arg2822Trp	c.5471G>A p.Arg1824Gln	c.9460C>T p.Arg3154Trp	c.421C>T p.Arg141Cys	c.1812C>T p.Gly604=
Phenotypes	LGMD2Q		LGMD2Q		EBS-MD
FATHMM	Not Present	Not Present	Tolerated	Not Present	Not Present
Mutation Assessor	low	low	Medium	low	low
Polyphen-2	benign	unknown	Possibly Damaging	unknown	unknown
SIFT	Damaging	Damaging	Damaging	Damaging	Not Present
Ensembl	Not Present	0.01	Not Present	Not Present	Not Present
GME	Not Present	Not Present	Not Present	Not Present	Not Present
gnomAD	Allele Count: 10	Allele Count: 8	Allele Count: 88	Allele Count: 4	Allele Count: 1
Iranome	Not Present	Not Present	Allele Count: 8	Not Present	Not Present
CADD Score	13.9	25.00	25.10	25.7	12.26
Pathogenicity Class	VUS	VUS	VUS	VUS	VUS

The variants were not deposited in databases such as the gnomAD, Greater Middle Eastern Variome (GME), Iranome, and Ensembl Variant Table (Table 2).

A graphical view of the PLEC structure and the protein product, as well as the location of the five variants, can be found in Fig. 4.

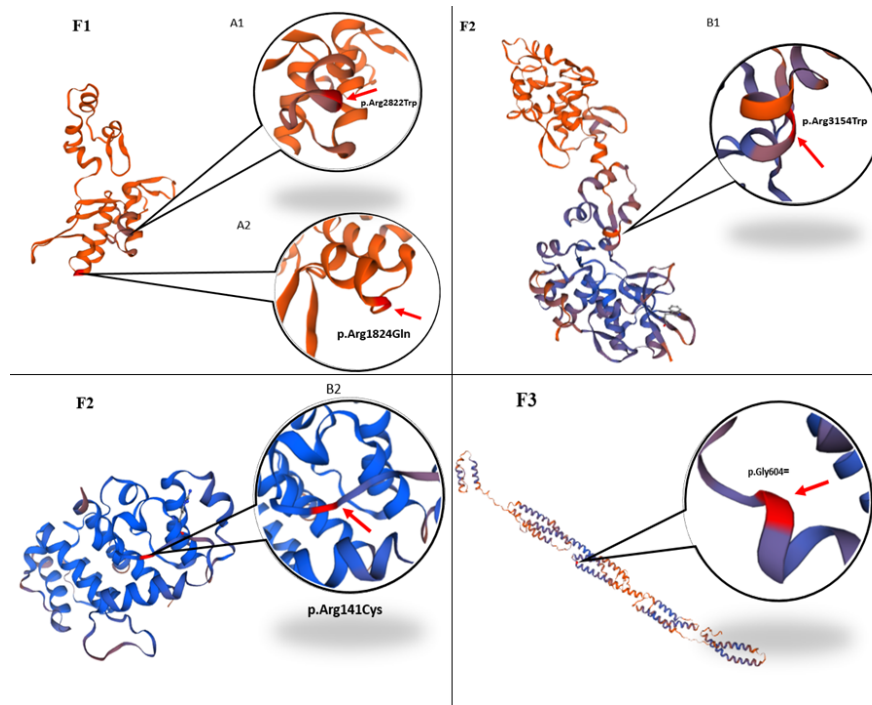


Fig. 4: Graphical view of the location of the five variants identified (A1) PLEC encodes a 32-exon (NM_201380) in heterozygous state (p.Arg2822Trp) and also (A1) PLEC encodes a 31-exon (NM_201380) in heterozygous state (p.Arg1824Gln) as a compound heterozygous mutation. (B1) PLEC encodes a 32-exon (NM_201380) in heterozygous state (p.Arg3154Trp) and also (B2) PLEC encodes a 1-exon (NM_201380) in heterozygous state (p.Arg141Cys) as a compound heterozygous mutation. (C) PLEC encodes a 13-exon (NM_201380) in homozygous state (p.Gly604=)

Discussion

Here, we discussed three unrelated patients from different regions of Iran. Affected individuals have an autosomal recessive plectinopathy associated disorder caused by the *PLEC* variant. Two patients with limb-girdle muscular dystrophy type 2Q (patient I and II). They have compound heterozygous hereditary in *PLEC*. Moreover, the other affected suffers from Epidermolysis bullosa simplex combined with muscular dystrophy (patient III) resulting from homozygous state mutation for *PLEC*.

Motor development disorder and muscular dystrophy symptoms began at late-onset age for patients I and III; unlike them, patient II had an early onset sign related to muscular dystrophy. They have rapid progression in disease, and two of them are unable to walk so far (Table 1). Patient III reported EBS symptoms such as blistering, skin scars, and milia.

Plectin is a big protein and a member of a group of proteins known as the Plakin family. Plectin interacts with I.F.s as a multimodular cytolinker and keeps them at strategic sites for cells organization and functions, including peripheral cell junctions, intracellular structures, and organelles.

Additionally, plectin interacts with other cytoskeletal components such as; actin and microtubules, and this protein also has a key role in the skeletal muscle functions and neuromuscular junctions (8).

8 isoforms named as (1, 1a, 1b, 1c, 1d, 1e, 1f, and 1g) were identified for plectin. All these isoforms have specific functions; for example, plectin (1a) interacts with IFS, supporting the association of plectin deficiencies with skin disorders (9). It was reported that plectin 1f isoform is a sarcolemma-associated protein in skeletal muscle tissue (8).

LGMD2Q is one of four plectin-related diseases caused by a mutation in the *PLEC* gene and clinically identified by an inherited form of muscular dystrophies with proximal or generalized progressive muscle weakness (2).

Andr  et al. showed the importance of plectin in epithelial tissue in plectin knock-out mice. The examination revealed that mice got severe skin blistering combined with a reduction in the number of hemidesmosomes, and in addition, it is elucidated that they had gotten skeletal and heart muscle disorders refer to lack of plectin (9).

Patients that are suffering from EBS-MD have similar clinical features. E.B. was introduced in 1886 for the first time and refers to a group of mechanobullous genodermatoses characterized by varying degrees of skin fragility caused by mutations in different skin structural proteins (10, 11). This disease is known for early-onset blistering and skin fragility and delayed muscular dystrophy onset (12).

According to our study and previous report about *PLEC* related muscular dystrophy (12), and owing compound heterozygous variant in patients I and II, are not caused them to have milder symptoms than the homozygous individual. On the other hand, comparison of these two patients together and with the patient III with variable severity of clinical features and with different age onsets in each type, explains that plectinopathy-associated disorders expand clinical phenotypes in different types of *PLEC* related diseases.

Conclusion

These findings improve current knowledge of the mutation spectrum of the *PLEC*-related plectinopathies. Further studies would be helpful to design more well-organized researches based on comprehensive knowledge about the genetic basis of plectinopathies disorders.

Journalism Ethics considerations

Ethical issues (Including plagiarism, informed consent, misconduct, data fabrication and/or falsification, double publication and/or submission, redundancy, etc.) have been completely observed by the authors.

Acknowledgements

We would like to thank the patients and their family members for participating in this study. This study was funded by Next Generation Genetic Polyclinic, Mashhad, Iran

Conflict of Interest

Authors declare no conflict of interest

References

1. Elliott CE, Becker B, Oehler S, et al (1997). Plectin transcript diversity: identification and tissue distribution of variants with distinct first coding exons and rodless isoforms. *Genomics*, 42:115-25.
2. Gundesli H, Talim B, Korkusuz P, et al (2010). Mutation in exon 1f of *PLEC*, leading to disruption of plectin isoform 1f, causes autosomal-recessive limb-girdle muscular dystrophy. *Am J Hum Genet*, 87:834-41.
3. Kyrova J, Kopeckova L, Buckova H, et al (2016). Epidermolysis bullosa simplex with muscular dystrophy. Review of the literature and a case report. *J Dermatol Case Rep*, 10(3):39-48.
4. Banwell BL, Russel J, Fukudome T, et al (1999). Myopathy, myasthenic syndrome, and epidermolysis bullosa simplex due to plectin

- deficiency. *J Neuropathol Exp Neurol*, 58(8):832-46.
5. Forrest K, Mellerio JE, Robb S, et al (2010). Congenital muscular dystrophy, myasthenic symptoms and epidermolysis bullosa simplex (EBS) associated with mutations in the PLEC1 gene encoding plectin. *Neuromuscul Disord*, 20(11):709-11.
 6. Natsuga K, Nishie W, Shinkuma S, et al (2010). Plectin deficiency leads to both muscular dystrophy and pyloric atresia in epidermolysis bullosa simplex. *Hum Mutat*, 31(10):E1687-98.
 7. Rezniczek GA, Walko G, Wiche G (2010). Plectin gene defects lead to various forms of epidermolysis bullosa simplex. *Dermatol Clin*, 28:33-41.
 8. Rezniczek GA, Konieczny P, Nikolic B, et al (2007). Plectin 1f scaffolding at the sarcolemma of dystrophic (mdx) muscle fibers through multiple interactions with beta-dystroglycan. *J Cell Biol*, 176:965-77.
 9. Andra K, Lassmann H, Bittner R, et al (1997). Targeted inactivation of plectin reveals essential function in maintaining the integrity of skin, muscle, and heart cytoarchitecture. *Genes Dev*, 11(23):3143-56.
 10. Intong LR, Murrell DF (2012). Inherited epidermolysis bullosa: new diagnostic criteria and classification. *Clin Dermatol*, 30:70-7.
 11. Fine JD, Bruckner-Tuderman L, Eady RA, et al (2014). Inherited epidermolysis bullosa: updated recommendations on diagnosis and classification. *J Am Acad Dermatol*, 70:1103-26.
 12. Argyropoulou Z, Liu L, Ozoemena L, et al (2018). A novel PLEC nonsense homozygous mutation (c.7159G > T; p.Glu2387*) causes epidermolysis bullosa simplex with muscular dystrophy and diffuse alopecia: a case report. *BMC Dermatol*, 18:1.