

## ORIGINAL ARTICLE

# The usefulness and safety of Hem-o-lok clips for the closure of appendicular stump during laparoscopic appendectomy

Chang Sik Hue, Jin Su Kim, Ki Hoon Kim, So-Hyun Nam, Kwan Woo Kim

Department of Surgery, Inje University Haeundae Paik Hospital, Inje University College of Medicine, Busan, Korea

**Purpose:** The purpose of this study was to investigate the safety and usefulness of the Hem-o-lok clip for the closure of appendicular stumps and limitations of the Hem-o-lok clip. **Methods:** From May 2010 to August 2011, 105 consecutive patients underwent laparoscopic appendectomies by three surgeons. XL size Hem-o-lok clips were used for the closure of appendicular stumps by one surgeon. The remaining surgeons used double endoloop ligatures. Prospectively collected data from patients who underwent laparoscopic appendectomy due to acute appendicitis were retrospectively reviewed. **Results:** A total of 105 laparoscopic appendectomies were performed. The endoloop group consisted of 66 patients (mean age, 34.6 years; range, 16 to 82 years), while the Hem-o-lok group consisted of 39 patients (mean age, 43.5 years; range, 11 to 88 years). In three cases, the Hem-o-lok clip was not used due to enlargement and severe inflammation of the appendix base. No specific intraoperative or postoperative complications were observed in either group. **Conclusion:** The use of Hem-o-lok clips for the closure of appendicular stumps in laparoscopic appendectomy is a feasible, safe, fast and cost-effective procedure in patients with a mildly to moderately inflamed appendix base of less than 10 mm in diameter.

**Key Words:** Appendicitis, Laparoscopic appendectomy, Hem-o-lok clip, Appendicular stump

## INTRODUCTION

Since the laparoscopic appendectomy was first described in 1983 by Semm [1], it has become a frequently used alternative in the treatment of acute appendicitis.

During laparoscopic appendectomy, the base of the appendix is usually secured by an endoloop ligature or linear

stapler (Endo GIA) [1-5]. Some data suggest that the stapling technique results in the safest closure of the stump, but it is also the most expensive method [5]. In addition, endoloop application requires some technique and a short training period [6]. Recently, in some studies, a non-absorbable Hem-o-lok clip (Weck Closure Systems, Research Triangle Park, Durham, NC, USA) was applied

Received September 3, 2012, Revised October 16, 2012, Accepted October 26, 2012

Correspondence to: Kwan Woo Kim

Department of Surgery, Inje University Haeundae Paik Hospital, Inje University College of Medicine, 875 Haeun-daero, Haeundae-gu, Busan 612-862, Korea

Tel: +82-51-797-0260, Fax: +82-51-797-0276, E-mail: d002045@paik.ac.kr

This paper was presented orally at the 63rd Annual Congress of the Korean Surgical Society.

© Journal of the Korean Surgical Society is an Open Access Journal. All articles are distributed under the terms of the Creative Commons Attribution Non-Commercial License (<http://creativecommons.org/licenses/by-nc/3.0/>) which permits unrestricted non-commercial use, distribution, and reproduction in any medium, provided the original work is properly cited.

as an alternative technique for the closure of appendicular stump in laparoscopic appendectomies because Hem-o-lok clips has the advantages of easy application and low cost compared with the endoloop or stapler [6-9].

More than 450 laparoscopic cholecystectomies are performed every year in our center, and Hem-o-lok clips have been used to close cystic duct in more than 90% of cases.

There were no specific complications related to the use of Hem-o-lok clips in laparoscopic cholecystectomies.

Based on our experience, since May 2010, we have used Hem-o-lok clips for the closure of appendicular stump in laparoscopic appendectomy.

Therefore, the aim of this study was to investigate the safety and usefulness of the Hem-o-lok clip for the closure of appendicular stump and limitations of the Hem-o-lok clip.

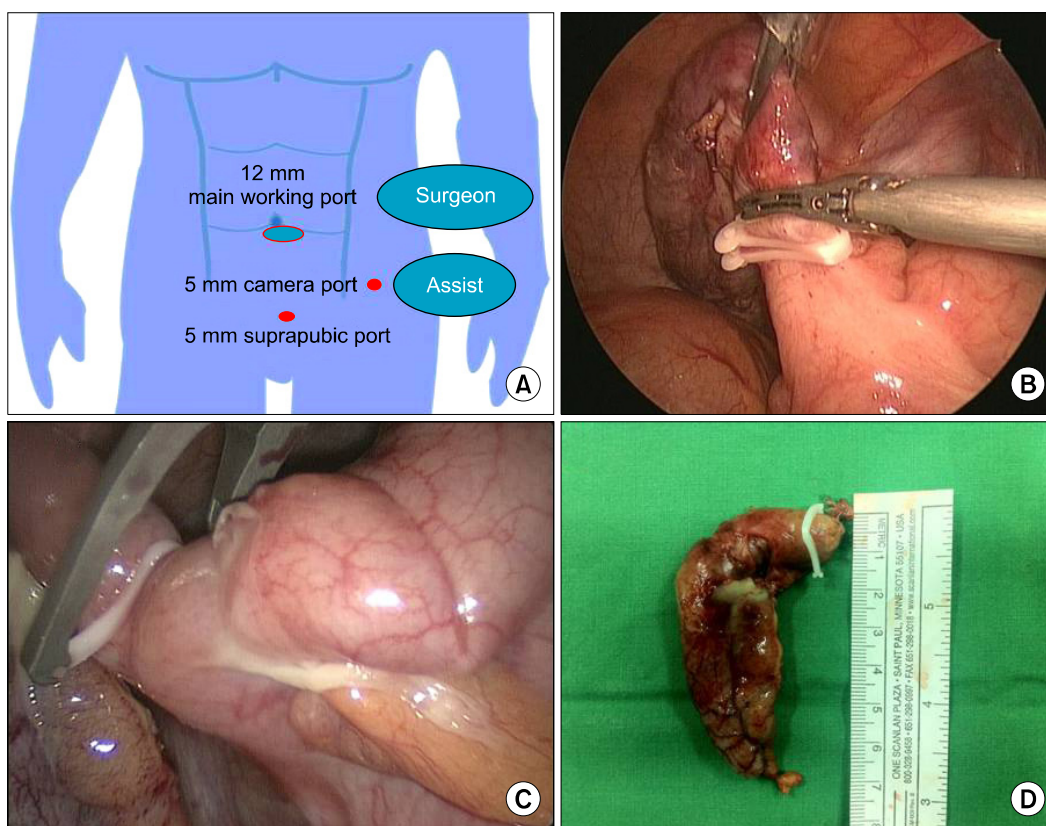
## METHODS

From May 2010 to August 2011, 105 consecutive patients underwent laparoscopic appendectomies by three surgeons. One surgeon used the Hem-o-lok clip whenever possible. The other two surgeons generally preferred to use the endoloop.

All of the surgeons were board-certified and had the same expertise regarding laparoscopic appendectomy.

The XL size (gold color applicator) clip was used (external clip length 17.33 mm, internal length 13.58 mm) for the closure of appendicular stump by one surgeon. The remaining surgeons used proximal double 2-0 polydioxanone (PDS; Ethicon Inc., Somerville, NJ, USA) endoloop ligatures.

We obtained informed consent preoperatively from all patients for the use of Hem-o-lok clips or endoloop ligature for appendicular stump closure.



**Fig. 1.** (A) Position of surgeon and ports. (B) Appendix base of applied double Hem-o-lok clips was transected by harmonic scalpel without third Hem-o-lok clip. (C) Hem-o-lok clip could not be used due to enlarged appendix base. (D) Appendectomy specimen base of same patient was too large in diameter (greater than 10 mm) for safe use of Hem-o-lok clip.

Prospectively collected data from patients who underwent laparoscopic appendectomy due to acute appendicitis were retrospectively reviewed.

Data were analyzed with a  $\chi^2$  analysis and a Student t-test. When appropriate, data were presented as the mean  $\pm$  standard deviation.

Statistical analysis was performed using SPSS ver. 15.0 (SPSS Inc., Chicago, IL, USA). Statistical significance was accepted for P-values of  $< 0.05$ .

### Operative procedure

The patient was positioned in the supine position with the head down and right side up. The surgeon and an assistant stood on the left side, and the monitor was on the right side of patient. A Foley catheter was not routinely inserted in Inje University Haeundae Paik Hospital.

Under general anesthesia, pneumoperitoneum (12 mmHg) was established after a 12-mm port was placed through a 12-mm infraumbilical incision by the open method, and a 5-mm 30-degree laparoscope was subsequently inserted. Under direct vision, one 5-mm port was inserted in the suprapubic area, and one 5-mm port was inserted in the left lower quadrant (anti-McBurney's point). A 5-mm 30-degree laparoscope was then moved to the left side port (Fig. 1A).

An umbilical trocar was used as the main working port, and an additional suprapubic trocar was used as the auxiliary port. The mesoappendix was mobilized and resected with a harmonic scalpel (Ethicon Endo-Surgery Inc., Cincinnati, OH, USA). The proximal base of the appendix was closed using double Hem-o-lok clips, and another clip was placed distally on the appendix, which was transected between the clips. In some cases, a third clip was not used because appendix was transected by a harmonic scalpel (Fig. 1B). The appendix was then removed through the umbilical port. A retrieval bag was sometimes used for large appendix.

## RESULTS

A total of 105 laparoscopic appendectomies were performed; 55 patients were male, and 50 were female (mean

age, 37.8 years; range, 11 to 88 years). The endoloop group consisted of 66 patients (35 male, 31 female: mean age, 34.6 years; range, 16 to 82 years), while the Hem-o-lok group consisted of 39 patients (20 male, 19 female: mean age, 43.5 years; range, 11 to 88 years). The mean postoperative hospital stay was  $5.3 \pm 2.3$  days in the Hem-o-lok group and  $5.2 \pm 1.6$  days in the endoloop group.

The mean diameter of the appendix base in the Hem-o-lok group was 9.9 mm (range, 6 to 11 mm) and 9.7 mm (range, 5 to 15 mm) in the endoloop group.

There was no significant difference in histological characteristics between the two groups (Fig. 2).

In three cases, the Hem-o-lok clip was not used due to an enlarged appendix base (Fig. 1C, D) and severe inflammation of the appendix base; in these patients, the endoloop was used.

No patients in either group required a conversion to an open appendectomy. No intraoperative complications were observed in either group.

One umbilical wound infection occurred in the Hem-o-lok group, and two umbilical wound infections occurred in the endoloop group. All of these wound infections resolved with drainage or oral antibiotic therapy. There were no surgery-related postoperative complications requiring rehospitalization after discharge.

The costs of material were \$29.2 United States Dollar (USD) for one unit containing six Hem-o-lok clips, \$68.2 USD for double endoloop ligatures. The characteristics of both groups are summarized in Table 1.

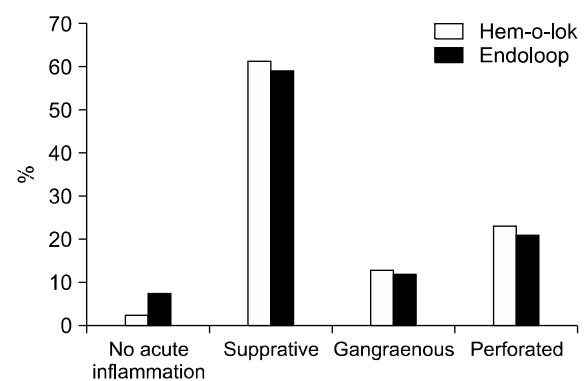


Fig. 2. Histological characteristics of all appendectomy specimens.

**Table 1.** Characteristics of Hem-o-lok and endoloop group of patients

Characteristic	Hem-o-lok clip group	Endoloop group	P-value
No. of patients	39	66	-
Age (yr), mean (range)	43.5 (11-88)	34.6 (16-82)	0.049
Intraoperative complication	0	0	-
Postoperative complication (wound infection)	1	2	-
Appendix diameter (mm), mean (range)	0.99 (6-11)	0.97 (5-15)	0.601
Hospital stay (day), mean (SD)	5.3 (2.3)	5.2 (1.6)	0.096
Conversion to open	0	0	-
Cost (USD)	\$29.2	\$68.2	-

SD, standard deviation; USD, United States Dollar.

## DISCUSSION

Laparoscopic appendectomy has not yet evolved as the gold standard for the treatment of acute appendicitis, unlike laparoscopic cholecystectomy.

However, laparoscopic appendectomy is expected to increase gradually and become the gold standard for the treatment of acute appendicitis because laparoscopic appendectomy has advantages similar to laparoscopic cholecystectomy.

Although the laparoscopic appendectomy surgical technique has been well established, there are many different techniques within procedure, including trocar positioning and the closure of appendicular stump.

Despite these differences, the most important concern in laparoscopic appendectomy is the safety of the method used for the closure of appendicular stump.

Most surgeons have either used a stapler or endoloop to close the appendicular stump [2,10,11]. Recently, some studies have reported the safety of using the Hem-o-lok clip for the closure of appendicular stump [6-9]. Additionally, the safety of using Hem-o-lok clips for the ligation of vessels, ureters, and bile ducts has been documented in over 1,000 surgical procedures [12-14].

Thus, it has been already well known that the use of Hem-o-lok clips is safe, and its application is also easy and fast.

In agreement with other studies, our study also shows that there were no significant differences between the Hem-o-lok group and the endoloop group with respect to intraoperative and postoperative complications. Howev-

er, the Hem-o-lok clip is cheaper than the endoloop or stapler.

Therefore, we believe that questions on the safety, usefulness and cost-effectiveness of Hem-o-lok clips have been conclusively answered.

In this study, among the various methods for the closure of appendicular stump, we analyzed the conditions under which Hem-o-lok clips are preferable.

In total, 39 (92.8%) of 42 patients were able to use the Hem-o-lok clip. The Hem-o-lok clip was not used in three cases because of the appendix base diameter.

Although there was no severe inflammation in the appendix base, the diameter of the appendix base was greater than 10 mm in 2 of 3 patients who received the endoloop, suggesting that Hem-o-lok clips cannot be used in cases with an appendix base greater than 10 mm because the internal length of the XL size clip is 13.58 mm.

However, our results show that the mean diameter of the appendix base in both groups is less than 10 mm, indicating that the Hem-o-lok clip can be used in most laparoscopic appendectomies.

The remaining patient had a severely inflamed appendix base and a diameter of up to 10 mm. As a result, the endoloop was used instead of the Hem-o-lok clip. Unfortunately, a fracture of appendicular stump occurred, and reinforcement suturing was laparoscopically performed to prevent leakage of appendicular stump. In this case, we believe that the stapler should be used for the safe closure of the appendicular stump.

To summarize our results, although various methods for the secure closure of appendicular stumps have been

used in laparoscopic appendectomy, it is important to prioritize treatment methods based on the severity of inflammation in the appendicular base, the diameter of the appendicular base and cost of the material.

In our opinion, if the appendix base diameter is less than 10 mm and the inflammation of the appendix base is mild to moderate, the Hem-o-lok clip should be recommended first. If the appendix base is too large in diameter (greater than 10 mm) for the safe use of the Hem-o-lok clip but the inflammation is not severe, the endoloop could be recommended instead of the Hem-o-lok clip. Stapler use should be limited to cases of severely inflamed appendicular bases that are greater than 10 mm in diameter. Additionally, a perforated appendix was not a consideration because the condition of the base was the most important factor for choosing the material for the appendicular stump closure.

Rickert et al. [15] reported that one advantage of the titanium clip in comparison to other commercially available clips is the size, which allows the closure of an appendix base greater than 10 mm, but the size of the applicator for titanium clip requires a 12.5 mm trocar. Therefore, if the Hem-o-lok clip is produced in a larger size, the diameter of the appendix base will no longer be a concern.

During the study period, we identified two retrograde appendectomies.

Although inflammation of the appendix base was not severe and the diameter was less than 10 mm, it was impossible to perform an antegrade appendectomy due to severe adhesion by perforation of the appendix tip and the retrocolic position of appendix. Therefore, the Hem-o-lok clips were first applied after tunneling the mesoappendix around the appendix base. Subsequently, the appendix base was resected, and mesoappendix was mobilized and resected with a harmonic scalpel (retrograde appendectomy procedure). This procedure resembles the clipping of the cystic duct, which is performed for laparoscopic cholecystectomy. In this situation, the use of an endoloop is impossible. Although the stapler can be used in this case, it is too expensive compared with the Hem-o-lok clip. However, because Hem-o-lok clips are not only inexpensive but also easy to apply, they are a useful material to use, primarily in retrograde appendectomy.

Recently, several studies have reported the safety of us-

ing a single Hem-o-lok clip [8,9]. Single clip was used because the long stump formed by double clipping might become necrotic and could be the cause of a local abscess. Additionally, double clips could increase the risk for intra-abdominal adhesions.

However, the principal method at our center for the closure of the appendix base is double clipping with the Hem-o-lok clips, similar to cystic duct clipping in laparoscopic cholecystectomy. No complications related to the use of double clipping have ever been experienced in laparoscopic cholecystectomy or appendectomy at our center. We also cannot be sure that single clipping is 100% safe because of the possibility of the Hem-o-lok clips slipping or unlocking.

In addition, Delibegovic et al. [16] reported that Hem-o-lok clips caused a milder reaction than endoloop clips. Although a precise comparison cannot be made because this study was performed in a rat model, the reaction in humans is generally similar to but less intense than that observed in experimental animals.

Therefore, decisions on whether to use single clipping or double clipping should be made according to the experience of each center.

In conclusion, the use of Hem-o-lok clips for the closure of appendicular stump in laparoscopic appendectomy is a feasible, safe and cost-effective procedure in patients with a mildly to moderately inflamed appendix base of less than 10 mm in diameter.

Additionally, the use of the Hem-o-lok clip will be helpful in retrograde appendectomy and does not carry a substantial learning curve.

## CONFLICTS OF INTEREST

No potential conflict of interest relevant to this article was reported.

## ACKNOWLEDGEMENTS

This work was supported by Grant from Inje University, 2011.

## REFERENCES

1. Semm K. Endoscopic appendectomy. *Endoscopy* 1983;15:59-64.
2. Arcovedo R, Barrera H, Reyes HS. Securing the appendiceal stump with the Gea extracorporeal sliding knot during laparoscopic appendectomy is safe and economical. *Surg Endosc* 2007;21:1764-7.
3. Kim HO, Yoo CH, Lee SR, Son BH, Park YL, Shin JH, et al. Pain after laparoscopic appendectomy: a comparison of transumbilical single-port and conventional laparoscopic surgery. *J Korean Surg Soc* 2012;82:172-8.
4. Pedersen AG, Petersen OB, Wara P, Ronning H, Qvist N, Laurberg S. Randomized clinical trial of laparoscopic versus open appendicectomy. *Br J Surg* 2001;88:200-5.
5. Kazemier G, in't Hof KH, Saad S, Bonjer HJ, Sauerland S. Securing the appendiceal stump in laparoscopic appendectomy: evidence for routine stapling? *Surg Endosc* 2006;20:1473-6.
6. Delibegovic S, Matovic E. Hem-o-lok plastic clips in securing of the base of the appendix during laparoscopic appendectomy. *Surg Endosc* 2009;23:2851-4.
7. Hanssen A, Plotnikov S, Dubois R. Laparoscopic appendectomy using a polymeric clip to close the appendicular stump. *JLS* 2007;11:59-62.
8. Partecke LI, Kessler W, von Bernstorff W, Diedrich S, Heidecke CD, Patrzyk M. Laparoscopic appendectomy using a single polymeric clip to close the appendicular stump. *Langenbecks Arch Surg* 2010;395:1077-82.
9. Delibegovic S. The use of a single Hem-o-lok clip in securing the base of the appendix during laparoscopic appendectomy. *J Laparoendosc Adv Surg Tech A* 2012;22:85-7.
10. Wagner M, Aronsky D, Tschudi J, Metzger A, Klaiber C. Laparoscopic stapler appendectomy: a prospective study of 267 consecutive cases. *Surg Endosc* 1996;10:895-9.
11. Partecke LI, von Bernstorff W, Karrasch A, Cziupka K, Glitsch A, Stier A, et al. Unexpected findings on laparoscopy for suspected acute appendicitis: a pro for laparoscopic appendectomy as the standard procedure for acute appendicitis. *Langenbecks Arch Surg* 2010;395:1069-76.
12. Tobias-Machado M, Forseto P Jr, Medina JA, Watanabe M, Juliano RV, Wroclawski ER. Laparoscopic radical prostatectomy by extraperitoneal access with duplication of the open technique. *Int Braz J Urol* 2004;30:221-6.
13. Bomfim AC, Andreoni C, Miotto A, Araujo MB, Ortiz V, de Figueiredo LF, et al. The "boatman's knot": a new option for renal hilum ligation during laparoscopic nephrectomy. *Acta Cir Bras* 2005;20:258-61.
14. Schick KS, Huttel TP, Fertmann JM, Hornung HM, Jauch KW, Hoffmann JN. A critical analysis of laparoscopic appendectomy: how experience with 1,400 appendectomies allowed innovative treatment to become standard in a university hospital. *World J Surg* 2008;32:1406-13.
15. Rickert A, Bonninghoff R, Post S, Walz M, Runkel N, Kienle P. Appendix stump closure with titanium clips in laparoscopic appendectomy. *Langenbecks Arch Surg* 2012;397:327-31.
16. Delibegovic S, Iljazovic E, Katika M, Koluh A. Tissue reaction to absorbable endoloop, nonabsorbable titanium staples, and polymer Hem-o-lok clip after laparoscopic appendectomy. *JLS* 2011;15:70-6.